



Universiteit
Leiden
The Netherlands

Vasectomy and vasectomy reversal : development of newly designed nonabsorbable polymeric stent for reconstructing the vas deferens

Vrijhof, Henricus Joesphus Elisabeth Johannes

Citation

Vrijhof, H. J. E. J. (2006, November 2). *Vasectomy and vasectomy reversal : development of newly designed nonabsorbable polymeric stent for reconstructing the vas deferens*. Retrieved from <https://hdl.handle.net/1887/4964>

Version: Corrected Publisher's Version

License: [Licence agreement concerning inclusion of doctoral thesis in the Institutional Repository of the University of Leiden](#)

Downloaded from: <https://hdl.handle.net/1887/4964>

Note: To cite this publication please use the final published version (if applicable).

**Vasectomy and vasectomy reversal; development of newly designed
nonabsorbable polymeric stent for reconstructing the vas deferens**

Proefschrift

ter verkrijging van
de graad van Doctor aan de Universiteit Leiden,
op gezag van de Rector Magnificus Dr. D.D. Breimer,
hoogleraar in de faculteit der Wiskunde en
Natuurwetenschappen en die der Geneeskunde,
volgens besluit van het College voor Promoties
te verdedigen op donderdag 2 november 2006
klokke 13.45 uur.

door

Henricus Josephus Elisabeth Johannes Vrijhof

geboren te Maastricht

in 1958

Promotiecommissie

| | |
|---------------|---|
| Promotoren | Prof. Dr. A.A.B. Lycklama à Nijeholt Prof. Dr. L.H. Koole |
| Referent | Dr. E.J.H. Meuleman |
| Overige leden | Prof. J. Zwartendijk Prof. Dr. F.M. Helmerhorst Dr. A.J.M. Hendrikx Dr. G.R. Dohle |

Thuis gelukkig zijn is het opperste resultaat van alle ambities (Samual Johnson).

Dit proefschrift wordt opgedragen aan
mijn ouders, Denise mijn vrouw en
mijn kinderen Sascha, Thomas en Bob

Contents

Introduction & Aims of the thesis

- Chapter 1** Henricus J.E.J. Vrijhof and August A.B. Lycklama à Nijeholt
The impact of vasectomy technique on spontaneous early recanalization
Submitted for publication
- Chapter 2** Dirk W. De Knijff, Henricus J. E. J. Vrijhof, Joop Arends and
Rudi A. Janknegt .
**Persistence or reappearance of nonmotile sperm after vasectomy: does it
have clinical consequences.**
Fertility Sterility 1997; 67: 332-334
- Chapter 3** Henricus J.E.J. Vrijhof
Vasovasostomy: the technical performance
Review Chapter
- Chapter 4** H.J.E.J. Vrijhof and K.P.J. Delaere
**Vasovasostomy results in 66 patients related to obstructive intervals and
serum agglutinine titres.**
Urologia Internationalis 1994; 53:143-146

- Chapter 5** Henricus J.E.J. Vrijhof and August A.B. Lycklama à Nijeholt
Influence of postvasectomy spermgranulomas, antisperm-antibodies formation and histological alterations of testicular/epididymal tissue on the outcome of vasectomy reversal.
Submitted for publication
- Chapter 6** Eric J. Vrijhof , Adriaan de Bruïne , August A. B. Lycklama à Nijeholt , and Leo H. Koole
A polymeric mini-stent designed to facilitate the vasectomy reversal operation. A model study in rabbits.
Biomaterials 2004; 25: 729-734
- Chapter 7** H. J. E. J. Vrijhof , A. De Bruine , A. H. Zwinderman , A. A. B. Lycklama à Nijeholt and L H. Koole
The use of a newly designed nonabsorbable polymeric stent in reconstructing the vas deferens: a feasibility study in New Zealand white rabbits.
British Journal of Urology Int. 2005 ; 95: 1081-1085.

Chapter 8 H. J. E. J. Vrijhof , A. De Bruine , A. H. Zwinderman , A. A. B. Lycklama à
Nijeholt and L H. Koole

**New nonabsorbable stent versus a microsurgical procedure for vasectomy
reversal: evaluating tissue reactions at the anastomosis in rabbits.**

Fertility Sterility 2005; 84: 743-748.

Chapter 9 Summary and conclusion

Chapter 10 Samenvatting en conclusie

Curriculum vitae

Introduction and aims of the study

How it all started!

A microscopical vasovasostomy is of course a time consuming operation, but those who have done a reversal procedure with a microscope will never revert to a macroscopical procedure again. Operating times vary between 2 –4 hours depending on the use of a one- or two-layer technique and the technical difficulties to encounter. Next to the difficult technical performance, it is frequently annoying that initial good sperm results can decline several months later. The cause of this decline is probably due to secondary stricturing because you initially start with semen samples of satisfying quality. Those patients undergoing a re-vasovasostomy have even a greater chance of developing partial or complete stricturing of the new anastomosis area. That's where our search for an alternative reversal method began.

A permanently present hollow stent in the vas could be the solution. The literature reported on the use of stents especially in the 70's, intravasal suture materials were used and polyglycolic acid as a bioabsorbable material became very popular in this decade. The results were promising but no further reports on this subject were seen in the years to follow. A possible explanation could be that supplementary studies in men were disappointing?

At the end of the 1980's, Berger et.al. restarted the use of a stent and published data from a study in men. His results were promising but not what he expected it to be. It appeared from the literature that nobody ever used a non-absorbable polymeric stent. After contacting several firms in the U.S., a couple of prototypes were realized. The big problem was to create a hollow stent that had small measurements and could also satisfy the condition of allowing sperm passage. We started to look for a suitable animal to test these prototypes and ended up with rabbits. They have an easy accessible vas deferens and the diameter of the vas equals that of men. Next to that, semen is easily obtained from these animals using an artificial vagina system

to collect sperm for an adequate follow-up. The biomaterial prototypes from the US were not successful and so we proceeded our search for a new stent that suited the purpose. We contacted the Technical University of Eindhoven, Eindhoven, The Netherlands and made an appointment at the biomaterials department. After explaining our ideas we were referred to the Center for Biomaterials in Maastricht, The Netherlands. We started to develop this stent using a non-biodegradable material.

Development of a polymeric stent for vasovasostomy

Development of a stent to rejoin two loose ends of the vas deferens requires a biomaterial that must meet several stringent requirements in terms of mechanical strength and biocompatibility. In situ, the stent has to withstand radial compression forces (especially those associated with peristaltic contractions of the vas deferens), to prevent narrowing or even closure of the stent lumen. With respect to the biocompatibility, two requirements can be formulated: (i) the presence of the stent should not evoke incompatibility effects, such as (chronic) inflammation, etc., and (ii) sperm cells should not be injured or damaged upon contacting the inner surface of the stent: epithelialization of the stents luminal surface should occur preferably.

At the onset of this study, it was believed that these requirements could be met with a special type of hydrophilic-hydrophobic copolymers, i.e. those derived from the reactive monomer N-vinylpyrrolidinone (NVP) as the hydrophilic building block, and the reactive monomer n-butyl methacrylate (BMA) as the hydrophobic building block (see fig.1).

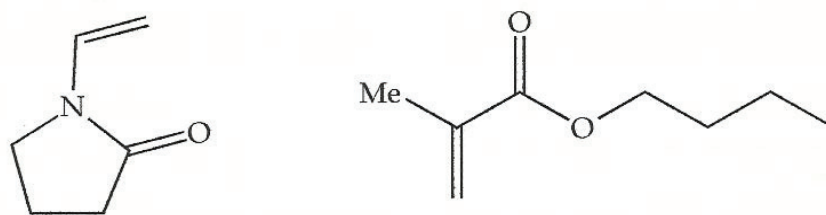


Fig 1. Structural formulas of the NVP (left) and BMA (right) reactive monomers.

Previous research has revealed the excellent biocompatibility (passivity) of such biomaterials, e.g., in contact with blood. Moreover, there is a wide range of NVP-based polymers and copolymers that find use in contact with human tissue (either in the clinic, or in cosmetic products). In our case, the ratio NVP:BMA provides a convenient handle to control the hydrophilicity, as well as the degree of swelling upon immersion in an aqueous environment, of the resulting copolymer. Furthermore, it was clear that the mechanical properties can be fine-tuned by means of physical cross linking of the polymer chains, through introduction of a bifunctional reactive monomer during copolymer synthesis. For clarity: these mechanical properties refer to the swollen (wet) state, in which the stent biomaterial is saturated with water. In the dry state, the NVP-BMA-type copolymers are all hard and glassy materials, which can be machined with high accuracy and reproducibility. Upon absorption of water, however, the materials become more or less flexible and rubbery.

Initially, a small number of prototype stents was manufactured out of a cross-linked version of the NVP-BMA copolymer. A number of preliminary experiments were performed, using the prototype stents and pieces of explanted vas deferens from an animal source. These preliminary experiments revealed two important points:

First, it became clear that joining of the two vas deferens ends by means of a simple intraluminal tube was inadequate. Most likely, such a tube can move along the intraluminal channel, especially as a result of the peristaltic movements of the vas during ejaculation. The stent was designed in such a way that longitudinal movements are prevented. This was realised by a ridge in the middle part of the stent (see fig. 2)

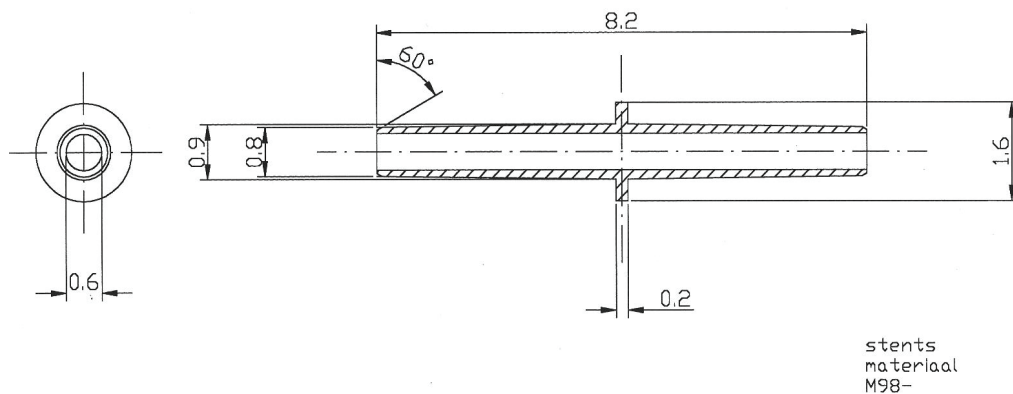


Fig 2. Schematic drawing of the stent for vasovasostomy, as designed and tested during this project.

The two vas deferens ends are joined on each side of the ridge, and connected through three stitches. This principle was used in all animal experiments with the stent for vasovasostomy, as described in this thesis.

Secondly, it became clear that the implantation of the vasovasostomy stent is essentially a three-step procedure, i.e. (i), insertion of the first stent half into the lumen of one of the vas deferens ends, (ii), insertion of the other stent half in the other lumen; (iii), fixation of the vas ends over the stent ridge, by three stitches. It was found that steps (i) and (ii) are difficult to perform when the stent is already equilibrated with water, since the material is too soft and

rubbery. The implantation proceeds conveniently if the stent is implanted in its dry (rather stiff) state, and allowed to absorb water in situ. The implantation must be executed quickly, and dry gloves must be used. This implies that the hydrophilic swelling nature of the biomaterial can be used advantageously during the implantation of the stent. The implantation technique proved to be straightforward; the technique can be taught to the skilled professional surgeon within approximately 1 day.

The experiment

The prototype looked very promising and we started with the set-up of our animal experiment. Collection of semen was of outmost importance to prove that our stent would function adequately. In the middle of the province of Limburg in the Netherlands, we found a rabbit farm specialized in artificial insemination of rabbits. An artificial vagina semen collection system was demonstrated to us. A male and female rabbit were placed just above each other in a small cage but were initially separated from each other. The sexual arousal of these animals was impressing and within a few minutes the male and female rabbits were brought together. They started to cohabitate immediately and it was the experience of the owner of the insemination station at what exact time he had to put the artificial vagina system between the rear legs of the female rabbit. Within seconds the male rabbit ejaculated in the artificial vagina and the semen was collected in a tube that was connected to the artificial vagina. Average volume of the ejaculate varied between 1-1.5 cc. We decided to buy this system and after some practicing we became experts in collecting semen from rabbits. The prototype of the new stent fitted perfectly in the vas deferens of the rabbits and we used 2 rabbits for a pilot. Both produced sperm even after 2 months. What we didn't know was how long it would take a vasectomized rabbit to become azoospermic. This was of importance because when a reversal

procedure would fail, due to complete obstruction, we would know the average time it would take for the animal to become azoospermic. Four rabbits were used for this experiment and after 6 weeks they all became azoospermic. Now it was time to start a randomized comparative study between rabbits that received bilateral stents and rabbits undergoing the conventional microscopic procedure. Together with the animal laboratory, we performed 28 vasovasostomy procedures and collected 142 semen samples. The animals were kept in cages, they were well nourished and postoperative care was taken care off. The animals were sacrificed 4-11 months after the initial operation and vas anastomoses, testes and epididymi were histologically analyzed. The results of our experiments are presented in this book.

Chapter 1

The impact of vasectomy technique on spontaneous early recanalization

Henricus J.E.J. Vrijhof, M.D.,^a and August A.B. Lycklama à Nijeholt, M.D., Ph.D.^b

Department of Urology, Catharina Hospital, Eindhoven, The Netherlands^a

Department of Urology, Leiden University Medical Center, Leiden, The Netherlands^b

Submitted for publication

Introduction

The aim of this review article is to explore from the literature what method of vasectomy produces the lowest risk of early recanalization and which vasectomy technique has the preference in an era where reversal of vasectomy is increasing. It is important to establish what is considered spontaneous recanalization. Early failure, defined as the presence of motile spermatozoa in the ejaculate four months after surgery ¹, is usually attributed to technical error or to early recanalization of the vas. Early failure occurs in about one out of 300 vasectomies^{2,3}. Late recanalization is described as the situation, where initially azoospermia is achieved and pregnancy is recorded afterwards, regardless of the time interval between azoospermia and pregnancy ^{4,5}. Late recanalization is thought to be rare 0.04-0.08% ^{1,3} although in one study the rate of recanalization was 0.6 percent one year after vasectomy ². In general, success after vasectomy is assessed after two consecutive azoospermic specimens ⁶⁻⁸. Persistence of non-motile sperm after two semen analyses does not mean that success is not achieved. Most of the men become azoospermic within 1 year after vasectomy ^{7,9}.

Growing popularity of vasectomy

Vasectomy is a safe and effective method of permanent contraception. In 1995 approximately 494.000 vasectomies were performed in the US (Haws et al)¹⁰. Vasectomy is less expensive and is associated with lower morbidity and mortality than tuba ligation^{11,12}. Hendrix et al.¹³ compared two methods of sterilization: bilateral tuba ligation and vasectomy. Compared were preoperative counseling, operative procedures, post-operative complications, procedure related costs, psychosocial consequences and feasibility of reversal. The complication rate in bilateral tuba ligation is 20 times higher and the mortality rate 12 times higher than in bilateral vasectomy. Tuba ligation is much more expensive compared to vasectomy. In 1987 in the USA a total of 976.000 sterilizations were performed (65% tubal ligation and 35% vasectomies) with an overall cost of \$ 1.8 billion dollars. More than \$ 800 million dollars could have been saved if 80 percent of sterilizations would have been vasectomies, as was the case in 1971. Hendrix et al. concluded that the preferred method of sterilization is vasectomy because it is safe, most efficacious and least expensive. The decline in popularity of tuba ligation is pointed out in a British study by Rowlands and Hannaford¹⁴. They estimated the incidence rates for tuba ligation and vasectomy and how these rates varied with age, geographical area and time. During the studied period from 1992-1999 there was a statistically significant 30% decrease in incidence of tuba ligation. The vasectomy rates did not change in time. Chinese made vasectomy a very popular form of contraception, illustrated by a complete reversal of the ratio male-to-female sterilizations in favor of vasectomy (3: 1)¹⁵. Refining the technique of vasectomy, minimizing trauma, pain and complications, paved the way for the final breakthrough in the popularity of vasectomy. Nevertheless, the success of the vasectomy procedure can be endangered by the markedly increased incidence of postoperative complications in the hands of surgeons that infrequently perform the procedure¹⁶.

Early recanalization or successful vasectomy?

The goal of each vasectomy is to obtain azoospermia. It is generally accepted that one or two azoospermic semen samples, taken 3-6 month after vasectomy, are sufficient for this statement^{17,18,19}. But what if this azoospermia is not achieved and non-motile sperm persist? At what time and at which criteria do we state that recanalization has occurred? Do patients with persistent non-motile sperm have a greater risk for late recanalization then those who had initial azoospermia? In other words, is special clearance (unprotected cohabitation with the presence of non-motile sperm) after one year of follow-up justified? Answering these question is difficult because only a limited number of studies have been published referring to these issues. In a study by Benger²⁰ a survey was obtained from British urologist how they managed persistent quantities of motile and non-motile spermatozoa after vasectomy. There was a 56% response rate and from those responding, 23% never performed a revasectomy in case of persistent non-motile spermatozoa. They concluded from their study that the estimated risk of pregnancy occurring from the presence of non-motile sperm (sperm concentrations of one in 50 to one in 100 high-power fields) is less than the established risk of late recanalization (< 0.04-0.1%). In a more recent (2001) survey¹⁷ among British general surgeons and urologist in the North-West region, protocols for post vasectomy semen follow-up were evaluated. Despite the fact that the majority of the protocols were not evidenced-based, the authors of this survey recommended a guideline that re-emphasized that the presence of non-motile sperm was not an indication for further sperm samples. The British Andrology Society¹⁸ set up a guideline (2002) for the assessment of post vasectomy semen samples. They evaluated seven studies on the subject of non-motile sperm after vasectomy. In their guideline they stated that when non-motile sperm (<10.000/ml) was persistently seen after at least 24 ejaculations, the patient should be advised to discontinue contraception. The Australian Safety and Efficacy Register of

New Interventional Procedures-Surgical (ASERNIP)¹⁹ presented a 187 pages numbered report on post-vasectomy testing to confirm sterility. They recommended that special clearance should be given to patients with two consecutive samples of non-motile sperm $<10.000/\text{ml}$ and not earlier than 7 month after vasectomy.

Whether special clearance or even “normal” clearance in patient with non-motile sperm is justified, depends on the fact whether these patients have an increased risk on pregnancy compared to the patients with initial azoospermia and late recanalization. Philp et al.²¹ reported a late recanalization rate of 0.03% (6 from 16.796 men) and described no pregnancies after special clearance of 310 (2%) men with non-motile sperm ($<10.000/\text{ml}$) after vasectomy. Edwards and Farlow²² reported similar results in 200 patients with non-motile sperm. From these 200 men, 190 were followed-up 12 to 15 months after vasectomy and no pregnancies occurred. Davies et al.²³ reported no pregnancies after special clearance of 151 (2.5%) men with non-motile sperm ($<10.000/\text{ml}$) with a minimum follow-up of 3 years (3-8 years). There is no clear evidence in the literature (pub med search 1970-2005) proving that pregnancies rates are higher in patients with special clearance after two or more non-motile sperm samples ($<10.000/\text{ml}$) compared to pregnancy rates resulting from late recanalization after initial azoospermia. Despite the absence of well designed randomized comparative trials there seems to be a tendency in literature to accept and justify special clearance in case of non-motile sperm and therefore to accept this finding as an appropriate end-point after vasectomy and not as early recanalization²⁴.

The different vasectomy techniques and early recanalization

Author's technique: standing on the right side of the patient, the left vas is trapped between the thumb, index finger and middle finger, the right vas between only thumb and index finger. The left vas is located on top of the thumb, the right vas on the index finger. Lidocaine 2% (2cc) is infiltrated around the vas. A mid-scrotal localization is probably most convenient because in this area the vas is more straight and superficial. A 1 cm longitudinal incision is made and carried down through the vas-sheath until bare vas is exposed. The vas is delivered with a forceps or a clamp. The perivascular artery and veins are dissected from the vas. Preservation of these structures prevents possible complications like bleeding and thus hematoma. A segment of 2-3 cm is then excised, the stumps are occluded using suture material (Vicryl 2.0) and fascial sheath is interposed. The small cutaneous wounds are closed using 4.0 Vicryl Rapide. This technique is one of the many modifications of the conventional technique.

No-scalpel technique

Li ²⁵ presented a no-scalpel technique. This method eliminates the scalpel and results in fewer hematomas and infections. A ring tipped vas deferens clamp is used and placed over the vas deferens after digital fixation of the vas under the median raphe. The skin in the clamp is tightly stretched over the most prominent portion of the vas and a sharp pointed mosquito is punctured through the overlying skin, into the vas sheath and vas wall. The clamp is gently opened until the bare vas wall can be visualized. The blades are turned 180 degrees and the vas is luxated through the puncture opening, divided and occluded.

Several studies compared the no-scalpel technique with the conventional technique and concluded that the no-scalpel technique resulted in a markedly reduced incidence of infection, hematoma and pain^{26,27,28}. The time needed for the no-scalpel technique was 40 percent less. The technique is more difficult and requires intensive hands-on training. Sokal et al.²⁹ presented a multicenter, randomized partially masked controlled study and found no difference in success rates between the conventional and the no-scalpel technique. The no-scalpel

technique had the advantage of shorter operating time with fewer complications and reduced perioperative discomfort. However, Alderman and Morrison³⁰ who reviewed the records of 619 consecutive vasectomies, could not confirm these advantageous claims.

Percutaneous vasectomy

Percutaneous vasectomies have been performed by Li³¹ and Ban³² using a combination of cyanoacrylate and phenol. The vas lumen was punctured with a 22 gauge needle and the position was confirmed injecting methylene blue into the left vas as well as Congo red into the right vas. Injection of 20 micro liters of two parts phenol mixed with one part n-butyl 2-cyanoacrylate mixture via the 22-gauge blunt-tipped needle occluded the lumen. Brown coloring of urine (blue and red) confirmed that both sides were occluded. Chen and co-workers³³ performed vas occlusion in 53 men, using injection of 0.16-0.22 ml polyurethane elastomer. They reported azoospermia rates of 85% after one year and 96% after two years. They stressed the fact that the shape of the intravasal plug was of great importance for successful vasectomy rates. Zambon et al.³⁴ investigated the efficacy of a percutaneous vas occlusion using silicone plugs. Significantly fewer men were azoospermic after vas occlusion than after conventional vasectomy. They concluded that the reliability of percutaneous vas occlusion is poor and should be rejected. In general, using techniques of percutaneous injection of an erosive agent in quite a length of the vas deferens has the disadvantage of permanent irreversibility.

Suture ligatures, clips and cautery

Suture ligatures, still the most common method employed worldwide may result in necrosis and sloughing of the cut end distal to the ligature. On the testicular side a sperm granuloma may develop. If both ends slough, recanalization is more likely to occur³⁵ vasectomy failure rates due to recanalization vary from 1-5 % when only ligatures are applied for occlusion.

When using hemoclips, failure rates are less than 1%^{36,37}. The more equal distributed pressure on the vas wall results in less necrosis and sloughing. Intraluminal cautery, destroying mucosa over at least one cm length, reduces recanalization rates to less than 0.5 %³⁸. Labrecque et al.³⁹ investigated 3761 men who underwent initial vasectomy. The vasectomy failure rates in the clipping and excision group were much higher than in the cautery, interposition and open testicular end group (8.7% versus 0.3%). A prospective, non-comparative multicenter observational study was conducted by Barone et.al⁴⁰. A total of 364 men completed follow-up in this study and were followed for 6 months. Each site used their usual cautery vasectomy technique. The overall failure rate based on semen analysis was 0.8% (95% confidence interval 0.2, 2.3). By 12 weeks 96.4% of participants showed azoospermia or severe oligozoospermia (< 100,000 sperm/mL). The predictive value of a single severely oligozoospermia sample at 12 weeks for vasectomy success at the end of the study was 99.7%. Sokal et.al⁴¹ compared semen analysis data from men following vasectomy using two occlusion techniques. Data on intraluminal cautery came from a prospective observational study conducted at four sites. Data on ligation and excision with fascial interposition came from a multicenter randomized controlled trial that evaluated the efficacy of ligation and excision with versus without fascial interposition. Ninety-seven percent of the men in the cautery study had reached success by 12 weeks, while only 91% in the fascial interposition study had reached success by 14 weeks. The difference in the observed failure rates suggests that vas occlusion techniques that include

cautery are significantly more effective than ligation and excision plus fascial interposition, at least based on semen analysis.

Importance of vas length removed

The length of the vas removed has an impact on the failure rate. Removal of quite long parts, reduces the chance of recanalization¹⁶, but is associated with more complications like hematomas and it impairs successful vasectomy reversal in the future. Hallan and May⁴² studied 30 bilateral vasectomized men. After excision of the vas segment, X-rays were taken to assess the actual radiologic separation of the vas ends. After a median excision of 22.5 mm of vas, the median radiological gap took about 7 mm. They concluded that a very long segment (>7cm) should be excised to achieve a gap greater than that of sperm granulomas associated with vasectomy failures. Therefore they suggested that only short segments can be excised but that additional procedures, like interposition and/or fulguration, are necessary to prevent possible recanalization. In a more recent study by Labrecque et al.⁴³, the length of the vas resected during vasectomy had no influence on the risk of postvasectomy recanalization. They compared a group of spontaneous recanalizations with a group of azoospermic patients and a group of patient with non-motile sperm ($<1 \times 10^6$ /mL). In cases of spontaneous recanalization versus azoospermic patients, the risk ratio (95% confidence interval) of recanalization with an average of segments of <10mm and 10-14mm was 0.6(0.1-2.0) and 0.6 (0.2-1.6) when compared to 15mm or more, respectively. In cases of spontaneous recanalization versus non-motile sperm group the risk ratio was 1.6(0.4-7.7) and 0.6 (0.2-1.7), respectively.

Clenny and Higgins³⁵ evaluated several vasectomy techniques and concluded that removal of at least 15 mm vas is recommended although plain cutting of the vas without removal is effective

as well in combination with adjusted techniques for handling the vas ends like folding, luminal fulguration and proximal fascial interposition.

Role of fascia interposition and/or folding back of vas ends

Interposition of fascia between the cut ends, folding back of the vasal ends and securing one end within Dartos muscle have all been advocated to reduce failure rates. In 1995 Schmidt⁴⁴ presented a series of 6248 vasectomies, all performed by one surgeon. No vasal segment was resected and the intraluminal mucosa of the cut ends was destroyed by fulguration after which the vas sheath was interposed preventing possible recanalization. In a period of 38 years he documented no persistence of sperm and post-vasectomy pregnancies. In 1994 Li et al.⁴⁵ published the results of a series of 2713 vasectomies using 7 different occlusion techniques. Especially the two techniques that used fascia interposition provided the best results. Sokal et.al⁴⁶ performed a well conducted randomized trial to compare the probability of the success of ligation and excision vasectomy with, versus without, fascial interposition. All surgeons performed the vasectomies using the no-scalpel approach to the vas. Participants had a semen analysis two weeks after vasectomy and then every four weeks up to 34 weeks. The primary outcome measure was time to azoospermia. Additional outcome measures were time to severe oligozoospermia (<100 000 sperm/mL) and vasectomy failure based on semen analyses. Recruitment after the planned interim analysis was halted, when 841 men had been enrolled (interim analyses was separately published by Chen-Mok⁴⁷). Fascial interposition decreased time to azoospermia (hazard ratio [HR], 1.35; $P < 0.0001$) and time to severe oligozoospermia (HR, 1.32; $P < 0.0001$) and reduced failures based on semen analysis by about half, from 12.7% (95% confidence interval [CI], 9.7 to 16.3) to 5.9% (95% CI, 3.8 to 8.6) ($P < 0.0001$).

Further recruitment was terminated prematurely. This study was one the first providing data from a randomized prospective trial showing the significant benefit of fascial interposition. Open ended vasectomies have been advocated in the 70'ties. Sperm granuloma development at the testicular open end had the advantage of preventing irreversible damage to the testis, improving the chances of successful reversal, but they provided unacceptable vasectomy failure rates varying from 7-50 percent ^{48,49}. In a larger series by Errey and Edwards ⁵⁰ the risk of spontaneous recanalization was much less. They compared 4330 open-ended vasectomies with 3867 standard vasectomies and spontaneous recanalization was rare in both groups. Haws et al. ¹⁰ provided nation wide data on the numbers of vasectomies, various occlusion techniques, fascial interposition and on protocols for semen follow-up in the United States. About one third of vasectomies in 1995 were no-scalpel vasectomies. The most common occlusion method was ligation and cautery. Less than half of the physicians (48%) interposed fascial sheath over one end ⁵¹.

Discussion

From these studies we conclude that the risk of pregnancy resulting from recanalization in patients with non-motile sperm is no greater than in those with two consecutive azoospermic semen samples^{52,46,9,20,21,22}. Therefore persistence of non-motile sperm after one year of follow-up should not automatically be diagnosed as recanalization but rather as residual sperm higher up in the urogenital tract⁵³. In our practice we perform a semen check-up after 3 months, if this indicates azoospermia or non-motile sperm in a concentration of < 100.000 non-motile sperm; no further semen specimens are analyzed. This is in accordance with the recently published guideline vasectomy of the Dutch Urological Society⁵⁴. The only absolute proof for recanalization is undoubtedly histological investigation of a patent section at the time of the revasectomy. In daily practice this investigation is not applied. We do believe that recurrence of motile sperm during follow-up is evident proof of recanalization. In case of only several motile sperm cells in the ejaculate a repeated semen specimen can be taken 4 weeks later to confirm the persistency of this recurrent and probably enhanced motility of sperm. In such a case revasectomy is indicated.

There seems to be a relationship between the kind of vasectomy procedure and the risk of recanalization. Simple suture ligatures, resulting in necrosis and sloughing of both ends, provides the highest risk of recanalization and should therefore in our opinion be abandoned. The length of the vas resected during vasectomy is still under discussion, fascial interposition and/or folding back of vasal ends are probably of much greater importance. Those who perform vasectomies at regular bases are familiar with the fact that despite excision of a 2 cm vas segment the cut ends are still in close contact with each other. Therefore many surgeons will fall back to additional techniques like interposition or folding back to assure them that these ends will not meet and possibly recanalize. We are convinced that resection of a vas segment

<2cm provides limited contribution in preventing recanalization. Taking in account the studies with greater series it seems that cautery of the abdominal end, over a length of at least 1cm, in combination with interposition of vas sheath and an open-ended testicular side, is the preferred method of choice. These open ended vasectomies have several advantages. Leaving the testicular side open has the possible advantage of less post vasectomy chronic pain due to sperm granuloma formation^{55,56}. Due to the development of sperm granuloma formation at the open testicular end, a pressure release valve can develop, reducing damage to the epididymis resulting in more successful vasectomy reversals. In an era with so many divorces and restored child wish with a new partner, long resection of vas should be carried out with restraint. Although there are from the literature only a limited number of well designed randomized comparative studies in this review, we are convinced that we have to modify our current, previously described, vasectomy technique.

References

1. Alderman PM. The lurking sperm: a review of failures in 8879 vasectomies performed by one physician. JAMA 1988;259:3142-4.
2. O'Brien TS, Cranston D, Ashwin P, Turner E, MacKenzie IZ, Guillebaud J. Temporary reappearance of sperm 12 months after vasectomy clearance. Br J Urol 1995;76:371-2.
3. Philp T, Guillebaud J, Budd J. Complications of vasectomy: review of 16,000 patients. Br. J. Urol.1984;56:745-8.
4. Halder N, Cranston D., Turner E., Mac Kenzie I., Guillebaud J. How reliable is a vasectomy? Long-term follow-up of vasectomised men. Lancet. 2000 Jul 1;356(9223):43-4.
5. Philp T, Guillebaud J, Budd D. Late failure of vasectomy after two documented analyses showing azoospermic semen. BMJ 1984; 289: 77-79
6. Smucker DR, Mahew HE, Nordlund DJ, Hahn WK Jr, Palmer KE. Postvasectomy semen analysis: why patients don't follow-up. J Am Board Fam Pract 1991;4:5-9.
7. Alderman P.M. General and anomalous sperm disappearance characteristics found in a large vasectomy series. Fertil Steril. 1989 May;51(5):859-62
8. The high rate of noncompliance for post-vasectomy semen examination: medical and legal considerations. J Urol. 1990 Aug;144(2 Pt 1):284-6.
9. Edwards I.S. Earlier testing after vasectomy, based on the absence of motile sperm. Fertil Steril. 1993 Feb;59(2):431-6.
10. Haws JM, Morgan GT, Pollack AE, Koonin LM, Magnani RJ, Gargiullo PM. Clinical aspects of vasectomies performed in the United States in 1995. Urology 1998; 52: 685.

11. Smith G.L., Taylor G.P., Smith K.F. Comparative risks and costs of male and female sterilization. *Am J Public Health*. 1985 Apr;75(4):370-4.
12. Torres A., Forrest J.D. The costs of contraception. *Fam Plann Perspect*. 1983 Mar-Apr;15(2):70-2.
13. Hendrix NW, Chauhan SP, Morrison JC. Sterilization and its consequences. *Obst Gynecol Surv* 1999; 54: 766-777.
14. Rowlands S, Hannaford P. The incidence of sterilisation in the UK. *Br J Obstet Gyn* 2003; 110: 819-824.
15. Walsh PC, Retik AB, Stamey TA, Vaughan jr. ED. Surgery of male infertility and other scrotal disorders (M.Goldstein). *Campbell's Urology* sixth edition vol 3; 3114-3149
16. Kendrick JS, Gonzales B, Huber D, Grubb G, Rubin G. Complications of vasectomies in the United States. *J Fam Pract* 1987; 25: 245-248.
17. Sivardeen KA, Budhoo M. Post vasectomy analysis: call for a uniform evidence-based protocol. *Ann R Coll Surg Engl*. 2001; 83:177-9.
18. Hancock P, McLaughlin E; The British Andrology Society. British Andrology Society guidelines for the assessment of post vasectomy semen samples (2002). *J Clin Pathol*. 2002; 55:812-6.
19. The Royal Australian College of Surgeons. Australian Safety and Efficacy Register of New Interventional Procedures-Surgical (ASERNIP). Post-vasectomy testing to confirm sterility: a systematic review. ASERNIP-S report no. 39, 2003.
20. Bengier JR, Swami SK, Gingell JC. Persistent spermatozoa after vasectomy: a survey of British urologists. *Br J Urol*. 1995; 76: 376-379

21. Philp T, Guillebaud J, Budd J. Complications of vasectomy: review of 16,000 patients. *Br. J. Urol.*1984;56:745-8.
22. Edwards I.S, Farlow J.L. Nonmotile sperms persisting after vasectomy: do they matter? *Br. Med. J.* 1979;1:87-8.
23. Davies A.H, Sharp R.J, Cranston D, Mitchell RG. The long-term outcome following special clearance after vasectomy. *Br. J. Urol.*1990;66:211-2.
24. Griffin T, Tooher R, Nowakoski K, Lloyd M, Maddern G. How little is enough? The evidence for postvasectomy testing. *J Urology* 2005; 174: 29-36
25. Li S. Ligation of vas deferens by clamping method under direct vision. *Chin Med J* 1976; 1: 193-198.
26. Li S, Goldstein M, Zhu U, Huber D. The no-scalpel vasectomy. *J Urology* 1999; 145: 341-344.
27. Nirapathpongporn A, Huber DH, Krieger JN. No-scalpel vasectomy at the King's birthday vasectomy festival. *Lancet* 1990; 335: 894-895.
28. Labrecque M, Dufresne C, Barone MA, St Hilaire K. Vasectomy surgical techniques : a systematic review. *BMC* 2004; 24: 2:21
29. Sokal D, Mc Mullen S, Gates D, Dominik R. A comparative study of the no-scalpel and standard incision approaches to vasectomy in 5 countries. The Male Sterilization Investig Team. *J Urology* 1999; 162: 1621-1625.
30. Alderman PM, Morrison GE. Standard incision or no-scalpel vasectomy? *Fam Pract* 1999; 48: 719-721.
31. Li S. Percutaneous injection of vas deferens. *Chin J Urol* 1980; 1: 193-198.
32. Ban SL. Sterility by vas injection method. *Hu Nan Med J* 1980; 5: 49-50

33. Chen ZW, Gu YQ, Liang XW, Wu ZG, Yin EJ, Li-Hong. Safety and efficacy of percutaneous injection of polyurethane elastomer (MPU) plugs for vas occlusion in man. *Int J Andrology* 1992; 15: 468-472.
34. Zambon JV, Barone MA, Pollack AE, Mehta M. Efficacy of percutaneous vas occlusion compared with conventional vasectomy. *Br J Urol* 2000; 86: 699-705.
35. Clenny TL, Higgins JC. Vasectomy techniques. *Americ Fam Phys* 1999; 60: 137-146.
36. Bennett AH. Vasectomy without complication. *Urology* 1976; 7: 184.
37. Moss WM. Sutureless vasectomy, an improved technique: 1300 cases performed without failure. *Fertil Steril* 1974; 27: 1040-1045.
38. Schmidt SS. Vasectomy. *Urol Clinic of North America* 1987; 14: 149.
39. Labrecque M, Nazerali H, Mondor M, Fortin V, Nasution M. Effectiveness and complications associated with two vasectomy occlusion techniques. *J Urology* 2002; 68: 2495-2498.
40. Barone MA, Irsula B, Chen-Mok M, Sokal DCInvestigator study group. Effectiveness of vasectomy using cautery. *BMC Urol* 2004; 19; 4:10
41. Sokal D, Irsula B, Chen-Mok M, Labrecque M, Barone MA. A comparison of vas occlusion techniques: cautery more effective than ligation and excision with fascial interposition. *BMC Urol.* 2004; 27;4(1):12.
42. Hallan RI, May AR. Vasectomy: how much is enough, *Br J Urol* 1988; 62: 377-399
43. Labrecque M, Hoang DQ, Turcot L. Association between the length of the vas deferens excised during vasectomy and the risk of postvasectomy recanalization. *Fertil Steril* 2003; 79: 1003-1007.

44. Schmidt SS. Vasectomy by section, luminal fulguration and fascial interposition: results from 6248 cases. *Br J Urol.* 1995; 76: 373-374.
45. Li SQ, Xu B, Hou YH, Li CH, Pan QR, Cheng DS. Relationship between vas occlusion techniques and recanalization. *Adv Contracept Deliv Syst.* 1994; 10: 153-159.
46. Sokal D, Irsula B, Hays M, Chen-Mok M, Barone MA; Investigator Study Group. Vasectomy by ligation and excision, with or without fascial interposition: a randomized controlled trial [ISRCTN77781689]. *BMC Med.* 2004; 31;2:6.
47. Chen-Mok M, Bangdiwala SI, Dominik R, Hays M, Irsula B, Sokal D. Termination of a randomized controlled trial of two vasectomy techniques. *Control Clin Trials* 2003; 24: 78-84.
48. Shapiro EI, Silber SJ. Open-ended vasectomy, sperm granuloma and postvasectomy orchialgia. *Fertil Steril* 1979; 32: 546-550.
49. Goldstein M. Vasectomy failure using an open-ended technique. *Fertil Steril* 1983; 40: 699-700.
50. Errey BB, Edwards IS. Open-ended vasectomy: an assessment. *Fert Steril* 1986; 45: 843-846.
51. Esho JO, Cass AS. Recanalization rate following methods of vasectomy using interposition of fascial sheath of vas deferens. *J Urology* 1978; 120: 178-179.
52. Halder N, Cranston D., Turner E., Mac Kenzie I., Guillebaud J. How reliable is a vasectomy? Long-term follow-up of vasectomised men. *Lancet.* 2000 1; 356(9223):43-4.

53. Vugt van A.B, Helsdingen van P.J. Velde te J. Sperm analysis following vasectomy: when to perform a revasectomy?
Ned Tijdschr Geneeskd. 17;129(33):1579-82
54. Dohle GR, Meuleman EJ, Hoekstra JW, van Roijen HJ, Zwiers W. Revised guideline 'Vasectomy' from the Dutch Urological Association.
Ned Tijdschr Geneeskd. 2005;149(49):2728-31
55. Myers SA, Mershon CE, Fuchs EF. Vasectomy reversal for treatment of the post-vasectomy pain syndrome. J Urology 1997; 157: 518-520.
56. Nangia AK, Myles JL, Thomas AJ. Vasectomy reversal for the post-vasectomy pain syndrome; clinical and histological evaluation. J Urology 2000; 164: 1939-1942.

Chapter 2

Persistence or reappearance of nonmotile sperm after vasectomy: does it have clinical consequences?

**Dirk W.W. De Knijff^a, Henricus J. E. J. Vrijhof^b, Joop Arends^c and
Rudi A. Janknegt^d.**

Department of Urology, University of Maastricht, Maastricht, The Netherlands^{a, b, d}

Department of Pathology, University of Maastricht, Maastricht, the Netherlands^c

Introduction

In our clinic, we perform two consecutive semen examinations at 6 and 12 weeks after a vasectomy. If the final examination shows azoospermia, the patient is given clearance to have intercourse without contraception.

Recently, we observed that a large portion of the patients had persisting nonmotile sperm even 12 weeks after vasectomy. This resulted in repeated semen examinations and some patients underwent revasectomy. This uncomfortable situation caused us to search for the probable cause and significance of nonmotile sperm and the best way to deal with this clinical problem.

Materials and Methods

Vasectomies were performed by six different urologists. All the procedures were done on an outpatient basis under local anaesthesia with lidocaine 1 %. After luxation of the vas deferens, a 1 to 2 cm long segment of vas deferens was resected and submitted for histological confirmation. During the vasectomy procedure, both vas ends were ligated with vicryl 1.0 and spermatic fascia was interposed. If the semen examination at 12 weeks postvasectomy showed azoospermia, the patient was given clearance to have intercourse without contraception. If residual sperm was found at 12 weeks postvasectomy, semen examinations were repeated until azoospermia was seen. Semen examinations were done by our infertility laboratory. Twenty fields of noncentrifuged semen samples were investigated under the microscope with an x200 magnification.

The vasectomy procedure and the semen analysis have not changed over the last 10 years.

Review of the semen analyses (≥ 12 weeks after vasectomy) was done in 413 patients who underwent vasectomy in the period between April 1st, 1993 and July 31st, 1995. A letter was written to all 413 patients. In the letter, a new semen sample was requested. In an added

questionnaire, we asked for the occurrence of possible pregnancies. Because 62 letters were returned by the postal service, we concluded that 351 patients received our inquiring letter. Despite repeated attempts, we were not able to trace the correct addresses of the remaining 62 patients.

Results

From the 413 patients who underwent a vasectomy, 395 patients delivered a semen sample 12 weeks after vasectomy. Azoospermia was found in 262 of 395 (66%) patients. Nonmotile sperm after vasectomy was found in 130 of 395 (33%) patients who delivered semen 12 weeks after vasectomy. The sperm count varied from 2.30 to $1.65 \times 10^6/\text{mL}$ (nonmotile sperm). Of 130 patients with persisting nonmotile sperm, 91 (70%) men continued to deliver semen samples after 12 weeks postvasectomy. In this group of 91 patients, azoospermia was found in 87 (96%) patients after a mean follow-up of 6.36 months (3 to 21 months). Even a patient with a sperm count of 1.65×10^6 nonmotile sperm 12 weeks after vasectomy achieved azoospermia 10 months postvasectomy. There was no significant difference between the group of patients with azoospermia and the group with nonmotile sperm 12 weeks postvasectomy with regard to mean age and length of resected vas deferens. Table 1 shows data of the group with nonmotile sperm 12 weeks after vasectomy.

Table 1. Patients with nonmotile sperm 12 weeks postvasectomy

| | <i>Mean</i> | <i>Minimum</i> | <i>Maximum</i> |
|---|-------------|----------------|----------------|
| Resected vas (cm) (n=127) | 1.2 | 0.4 | 2.8 |
| Age(years) (n=130) | 38.4 | 28 | 58 |
| Sperm concentration ($\times 10^3/\text{mL}$) (n=130) | 79 | 2.3 | 1.650 |
| Months to azoospermia (n=87) | 6.36 | 3 | 21 |

From the 91 patients with persisting nonmotile sperm, 4 patients underwent revasectomy because of unacceptable duration of persistent nonmotile sperm concentrations. After revasectomy, two patients still had unchanged concentrations of nonmotile sperm 12 weeks after the revasectomy (Table 2). Pathological investigations of the resected specimens at revasectomy showed in only one case a sperm granuloma that could suggest a possible recanalization.

Table 2. Semen analysis of four revasectomy patients (nonmotile sperm)

| <i>Patient</i> | <i>1</i> | <i>2</i> | <i>3</i> | <i>4</i> |
|--------------------------|-------------------|----------|----------|----------|
| | $\times 10^3$ /mL | | | |
| Before vasectomy * | 7.5(10) | 20 (9) | 7.5 (9) | 15(5) |
| 12 weeks after vasectomy | 0 | 20 | 7.5 | 0 |

*values in parentheses are months between first vasectomy and last semen analysis before revasectomy

Only 65 of 351 (18.5%) men replied to the letter and provided a renewed specimen together with their questionnaire. From the 65 men who delivered a further semen sample, 53 (82%) had azoospermia. Nonmotile sperm was found in 12 of 65 men (18.5%). Reappearance of nonmotile sperm after initial azoospermia (at 12 weeks) was found in 5 of 65 men (8%) (Table 3).

Table 3. Five patients with reappearance of nonmotile sperm after azoospermia

| <i>Patient</i> | <i>months to azoospermia*</i> | <i>months to reoccurrence of non motile sperm**</i> | <i>No. of sperm/mL</i> |
|----------------|-------------------------------|---|------------------------|
| 1 | 7 | 12 | 7.500 |
| 2 | 5 | 12 | 20.000 |
| 3 | 7 | 18 | 150.000 |
| 4 | 3 | 20 | 7.500 |
| 5 | 7 | 22 | 7.500 |

* after vasectomy

** after previous azoospermia

The five patients with reappearance of nonmotile sperm (longest follow-up 22 months) did not report any pregnancies. Only one patient in this group had repeated semen examinations (five times) because of persistent nonmotile sperm.

Early recanalization was found in 3 of 395 of the patients (0.75%) who delivered semen samples within 12 weeks after their initial vasectomy (Table 4). One pregnancy occurred among these patients because of the fact that the concerned patient (patient 3) had unallowed unprotected intercourse before his final semen control at 12 weeks postvasectomy.

Table 4. Sperm analysis of three patients with motile sperm*

| <i>Patient</i> | <i>at 6 weeks</i> | <i>at 12 weeks</i> |
|----------------|----------------------|-----------------------|
| | x10 ⁶ /mL | x 10 ⁶ /mL |
| 1 | 7(0) | 12(60) |
| 2 | 13(30) | 5(25) |
| 3 | 0 | 21(50) |

* values in parentheses are percent motile sperm

Discussion

Renewed patency or pregnancy after vasectomy can have several causes. Technical error, early recanalization, and residual motile sperm in the seminal vesicle after vasectomy are causes that can be detected easily by the presence of motile sperm, in various concentrations, in the postvasectomy specimen.

In the literature, a distinction is made between early and late recanalization. Early recanalization can be detected by an increasingly large amount of motile sperm in the postvasectomy specimen. Late recanalization is the presence of motile sperm after the postvasectomy specimen(s) showed azoospermia. Late recanalization can occur several years after vasectomy and usually is detected only after a pregnancy has occurred ¹. All the above mentioned causes of patency and pregnancy refer to motile sperm.

But what about nonmotile sperm? Can nonmotile sperm cause pregnancy? Is the presence of nonmotile sperm a signal that patency of the vas is present, meaning that the patient with nonmotile sperm has a higher risk of causing pregnancy compared with a patient with azoospermia? Persisting nonmotile sperm after vasectomy is a known phenomenon. Philp et al. ² reported no pregnancies after special clearance of 310 (2%) men with nonmotile sperm (<10,000/mL) after vasectomy. Davies et al. ³ also reported no pregnancies after special clearance of 151 (2.5%) men with nonmotile sperm (< 10,000/ mL), with a minimum follow-up of 3 years after vasectomy. Edwards and Farlow ⁴ gave clearance to 200 men with nonmotile sperm (30 patients with 500,000/mL and 2 patients with 24×10^6 /mL).

Of these 200 men, 190 were followed up 12 to 15 months after vasectomy and no pregnancies were reported, even though 5 of 48 men who submitted a semen specimen still had nonmotile sperm. In a study published by Edwards ⁵, patients tested 4 weeks after vasectomy, regardless of the amount of postvasectomy ejaculations, were given clearance if no motile sperm was

found. An important detail in this article is that five cases are mentioned in which the initial tests showed a count of 16×10^6 to 33×10^6 nonmotile sperm. These patients had repeated tests after a few weeks and a marked reduction in numbers of nonmotile sperm was observed. In the same paper, Edwards reported two pregnancies on a total of 3,178 vasectomized men; both patients had a recanalization of the vas deferens proven by motile sperm in the semen analysis. From the above mentioned data, one can conclude that patients with persisting nonmotile sperm postvasectomy have a very low risk of causing pregnancy.

If we search for proof to the contrary, one case report ⁶ can be found in which a patient with a small number of nonmotile sperm after vasectomy caused a pregnancy. Paternity was ascertained by DNA profiling in this case. Even more confusing is the article by Smith et al.⁷ in which they present six cases of DNA-proven fatherhood caused by azoospermic men. They explain this phenomenon by the intermittent production of viable sperm. Still, these few data do not prove that men with nonmotile sperm after vasectomy have a higher risk of causing a pregnancy than azoospermic patients.

In our study, 96% of the patients returned and delivered a semen sample at 6 and 12 weeks postvasectomy. This is a high patient compliance rate compared with the 64% mentioned by Belker et al.⁸ and the 71% mentioned by Edwards ⁵.

In our study, we found that 33% of our patients had nonmotile sperm 12 weeks postvasectomy. Edwards ⁵ found that 42% of his patients had nonmotile sperm between 7 and 14 weeks postvasectomy. From the group of patients with persisting nonmotile sperm that continued to deliver semen samples, 96% became azoospermic in our study.

The persistence of nonmotile sperm in two cases after revasectomy in our study only can be explained by residual sperm in the seminal vesicles or the abdominal part of the vas, because large pieces of the vas were resected at the revasectomy and no recanalization was found after

microscopic investigation of the resected pieces.

Reappearance of nonmotile sperm after azoospermia was found in 8% of the volunteer group. The highest count was 150,000/mL. No pregnancies were found among these patients with a maximum follow-up of 22 months.

In a recent article by O'Brien et al.⁹, temporary reappearance of sperm 12 months after vasectomy is described in six cases (0.6%). The sperm count was <10,000/mL. Unfortunately, the percent motility of the sperm is not mentioned in this article, which is essential information if one is to say anything on the chance of causing pregnancy.

Based on the literature and on our own experience, we assume that men with small amounts ($<1 \times 10^6$) of nonmotile sperm after vasectomy have a very low risk of causing pregnancies. Probably this risk is comparable with the risk that azoospermic men generate pregnancies.

For this reason, we give clearance to patients who have small amounts of nonmotile sperm 12 weeks after vasectomy. Our hypothesis is that persistence and reappearance of nonmotile sperm after vasectomy is caused by release of nonviable residual sperm in the seminal vesicles and the abdominal part of the vas deferens. This is supported by the observation that nonmotile sperm in some cases do not disappear after revasectomy

References

1. Philp T, Guillebaud J, Budd D. Late failure of vasectomy after two documented analyses showing azoospermic semen. *Br. Med. J.* 1984; 289:77-79.
2. Philp T, Guillebaud J, Budd J. Complications of vasectomy: review of 16,000 patients. *Br. J. Urol.* 1984; 56:745-8.
3. Davies AH, Sharp RJ, Cranston D, Mitchell RG. The long-term outcome following special clearance after vasectomy. *Br. J. Urol.* 1990; 66:211-212.
4. Edwards IS, Farlow JL. Nonmotile sperms persisting after vasectomy: do they matter? *Br. Med. J.* 1979; 1:87-88.
5. Edwards IS. Earlier testing after vasectomy, based on the absence of motile sperm. *Fertil. Steril.* 1993; 59:431-436.
6. Thompson JA, Lincoln PJ, Mortimer P. Paternity by a seemingly in vasectomized man. *Br. Med. J.* 1993; 307:299-300.
7. Smith JC, Cranston D, O'Brien T, Guillebaud J, Hindmarsh J, Turner AG. Fatherhood without apparent spermatozoa after vasectomy. *Lancet* 1994; 344:30.
8. Belker AM, Sexter MS, Sweitzer SJ, RafT MJ. The high rate of noncompliance for postvasectomy semen examination: medical and legal considerations. *J. Urol.* 1990; 144:284-286.
9. O'Brien TS, Cranston D, Ashwin P, Turner E, MacKenzie IZ, Gillebaud J. Temporary reappearance of sperm 12 month after vasectomy clearance. *Br.J.Urol.* 1995; 76:371-2.

Chapter 3

Vasovasostomy; the technical performance

Henricus.J.E.J. Vrijhof

Department of Urology, Catharina Hospital, Eindhoven, The Netherlands

Contents

The microsurgical technique.....

What kind of microsurgical instruments do we need?

Review chapter

The microsurgical technique

In the early beginning vasovasostomies were done macroscopically. Macroscopic reapproximation represents the development of an anastomosis done without any type of optical magnification ^{1,2}. Because microscopical reconstructions led to better results compared to macroscopical reconstructions ^{3,4,5,6}, we switched over to the microscopical procedure. Before starting with microscopical reconstructions one should follow a course on microsurgery. Spending a whole week reconstructing blood vessels in rats in a microsurgical-training center in Rotterdam, The Netherlands was a good training. It is important to learn the proper hand and finger positions for holding microsurgical instruments; ergonomic principles to prevent hand and finger tremors and functioning of the various parts of the operating microscope. Optical loupes can be used. Optical loupes with 2.5x to 3.5x are used commonly by surgeons to visualize fine structures in the operating field. Structures more than 3 mm in diameter can be optimally approached with optical loupes. But for smaller structures an operating microscope is absolutely necessary. The disadvantage of optical loupes is the fact that the surgeon must hold his head virtually motionless in order to keep the structures in the operating field in focus. If the power of magnification increases it is even harder to maintain a fixed focus. Operating microscopes provide light that is coaxial to the field of view and offers adequate illumination of the operating field ^{7,8,9}. In contrast with the surgical loupes, focusing of the microscope is done electronically by moving the head of the microscope rather than moving your own head which is time consuming and less precise. Eyepieces are available in several strengths and diopter scales are provided on the eyepiece for individual adjustment. Double vision should be corrected by adjusting the interpupillary distance. This binocular view permits stereoscopic viewing. Most microscopes have binocular tubes that can be adjusted to various angles. We use a diploscope arrangement in our operations. A diploscope configuration is

useful for most microsurgical procedures. The eyepieces of the surgeon are directly opposite the eyepieces of his assistant. Such an arrangement uses a single objective lens and a beam splitter to provide the surgeon and the assistant with one-half of the available light each. The advantage of this system is that the assistant uses the same amount of magnification as the surgeon. The cooperation is in this way more efficient. The magnification changer permits variation in magnification. In our setting it is controlled automatically by a foot pedal. The length of the binocular tubes, the power of the eyepiece, the properties of the magnification changer and the focal length of the objective lens determine magnification. Objective lenses are available in focal length ranging from 150-400mm. For each 25 mm increase in focal length, the objective lens will focus 25 mm farther away from the operating field. Magnification decreases, and the size of the field of view increases, as the focal length of the objective lens increases. If the focal length is too short the surgeon is forced to assume a kyphotic position if it is too long he is required to stand up. This illustrates that optimal care has to be taken for the exact positioning of the microscope because non optimal visualization can be of bother during the entire operation. Good positioning can also be achieved by adjusting the organs in the operating field and prevent unnecessary disturbing reflection from light. Our microscope is mounted on a floor stand and contains a horizontal suspension arm. After macroscopically preparing the operation field the microscope can easily be directed towards the surgeon and his assistant, taking in account the principles of sterility. If the focal length is difficult to install one should also consider in moving the operation table as a possible alternative.

What kind of microsurgical instruments do we need?

First of all the microsurgical instruments should be demagnetized. Because most microsurgical instruments are made of stainless steel (as in our hospital) instruments may become magnetized. The surgeon experiences difficulty in picking up needles with a magnetized instrument. Titanium is an alternative but very expensive. The gloves used should not be too slippery. The movement of the instruments in the hand should be optimally controlled. Gloves that provide a certain roughness provide a more sufficient control of the instruments.

(Supersensitive, Biogel ®). Microsurgical instruments are extremely delicate. Dropping such an instrument could lead to irreversible damage. Therefore the instruments are kept in a special tray designed for protection. Tip covers are useful and highly recommended. Having your own instruments is an advantage, because providing these instruments to other surgeons could invariably lead to damage or loss. During the procedure the instruments should be cleaned and the deposition of blood clot between the blades prevented. Cleaning can be done in water using a surgical sponge and dried. Using round handles for the instruments makes it easier to manipulate compared to flat handles. Pro- and supination is simplified so the needle can be passed easier through the tissue. There are various needle holders. You have nonlocking and locking needle holders. We prefer the nonlocking holders because it prevents groove movements if you want to reposition the needle holder. Next to that, uncontrolled unlocking may give rise to tear through the tissue and may influence the water tightness eventually. In performing an operation we need 2 needle holders, 3 or 4 forceps, preferably Harms forceps with platforms on the end of each blade for easy pick up of needles, 2 scissors (cutting tissue and trimming vessel ends and cutting ligatures), vas dilator (judging elasticity and dilation to ease introduction of the needle) and an approximator. We use a Silber folding approximation clamp. During the

operation we use bipolar cautery to prevent damage to the anastomosis and vascularity of the vas.

Underneath the area of the newly developed anastomosis, we place a blue flexible thin plastic slip. The advantages are multiple: less reflection of light, reduced distraction from the surrounding tissues, perfect overview over the anastomosis due to less disturbance of blood flow over the operation field and finally no hooking of the needles in the surrounding tissues with facilitates pulling through of the loops of the sutures. We use 8.0 prolene sutures double armoured with flat needles (30-150 micrometer) allowing the surgeon to hold the needle more securely. Important is that the forearms are supported by the table to prevent any form of tremor. We always use double armoured sutures so that we can be sure that the needle goes from the inside through the mucosal edges towards the outside of the vas wall. We start at 6 o'clock, and this first suture is tied. Then we place 3 or 4 additional sutures anti-clockwise at the corresponding area's (3, 12 and 9 o'clock) of the vas. These separate sutures are covered to prevent strangulation of the loop ends. After placing all the sutures there is a final check to be sure that the position of the sutures is congruent over both vas ends so that torsion is prevented. Magnification for tying the sutures can be reduced which makes it much easier to perform. To check the water tightness of the anastomosis, we compress the area of the epididymis if no sperm leakage is observed we end the operation. If there is still some leakage we place an additional serosal suture at the place of the leakage. A final check is done for hemostasis and the vas is replaced in the scrotal area. Tunica dartos is closed with 4.0 Vicryl and the skin is closed with 4.0 Vicryl Rapide. A tight short with drapes at the wound area is attached and after a final wound check at the end of the day the patient is dismissed from the hospital. At 2 weeks there is a wound inspection and the first semen check will be done 5 weeks later. Semen analyses will be done with an interval of three months. If the quality of the sperm after 1 year

remains poor and insufficient for a spontaneous pregnancy, the couple is send to the gynecologist for IUI, IVF or ICSI or in case of azoospermia a renewed vasectomy reversal is considered.

References

1. Fenster H., McLoughlin M.G. Vasovasostomy: is the microscope necessary. *Urology* 18; 60, 1981
2. Lee L., McLoughlin M.G. Vasovasostomy; a comparison of macroscopic and microscopic techniques at one institution. *Fertil. Steril.* 33:54, 1980
3. Silber S.J. Perfect anatomical reconstruction of the vas deferens with a new microscopic surgical technique. *Ibid* 28: 72, 1977
4. Silber S.J. Microsurgery in clinical urology. *Urology* 6: 150, 1975
5. Silber S.J. Perfect anatomical reconstruction of the vas deferens with a new microscopic surgical technique. *Fert. Steril.* 31: 309, 1979
6. Silber S.J. Vasectomy and its microsurgical reversal. *Urol. Clin.north. am* 5; 573, 1978
7. Horenz P. The operating microscope. I. Optical principles, illumination and support systems. *J. Microsurg.* 1:364, 1980
8. Horenz P. The operating microscope. II. Individual parts, handling, assembling, focusing and balancing. *J. Microsurg.* 1:419, 1980
9. Horenz P. The operating microscope. III. Accessories. *J. Microsurg.* 2:22, 1980

Chapter 4

Vasovasostomy results in 66 patients related to obstructive intervals and serum agglutinin titres

H.J.E.J. Vrijhof and K.P.J. Delaere

Department of Urology, De Wever Hospital, Heerlen, The Netherlands

Urologia Internationalis 1994; 53:143-146

Introduction

Vasectomy is a very popular form of birth control. The request for vasovasostomy procedures is growing due to the increasing prevalence of divorce and remarriage. However, the number of reversal procedures in this hospital has not increased over the last decade. The aim of the study was to investigate the results of vasovasostomy procedures in relation to duration of obstruction and preoperative serum agglutinin titres. Obstructive interval is defined as the period between vasectomy and refertility. In previous studies the correlation between obstructive intervals and pregnancy rates has been demonstrated ^{1,2}. Especially in the study of Kabalin and Kessler ² a 5-year obstructive interval seems to be a critical barrier in achieving acceptable pregnancy and patency rates. Even with obstructive intervals exceeding 10 years, pregnancy can still occur ¹.

Materials and Methods

A total of 82 primary vasovasostomy procedures were performed between January 1983 and December 1991 and 66 patients were admitted to the study. Sixteen patients were lost to follow-up. Average age was 37 years (26-59) and the mean follow-up was 54 months (5-105). After the medical history had been obtained and clinical examination (to exclude sperm granulomata) had been carried out, sperm agglutinating antibodies in serum were determined by means of a standard tray agglutination test (TAT). In this procedure, heat inactivated serially diluted samples were incubated with donor sperm. These samples were then placed in microchamber trays under paraffin oil at 37°C. After 2 h the results were read using an inverted microscope.

Obstruction intervals were subdivided in categories varying from 0-2, 2-5, 6-10 and more than 10 years after vasectomy. Bilateral vasovasostomy was performed in 62 patients. One patient

underwent a unilateral reversal procedure and in 3 others a bilateral vasoepididymostomy was carried out.

The patients were operated on by different surgeons and the macroscopic procedure was more often performed than the microscopic (62% vs. 38%). All the anastomoses were constructed with double-ended prolene 7.0 one-layer sutures. Microsurgical vasoepididymostomy was performed by using an end-to-end anastomotic method. In 53% (n = 35) of the patients an internal splint running through the anastomosis of the vas deferens and leaving the scrotum, was left in situ for 24 h. Postoperative semen analyses were determined 2 months, 6 months and 1 year after reversal or until pregnancy occurred. Sperm counts were subdivided into 4 groups: 0, < 10, 10-20, > 20 millions/ml. Those patients who had recurrence of sperm in the semen after a 1-year follow-up, but had not reported pregnancy, were contacted by telephone.

Results

There were various reasons for regaining fertility. In 50% (n = 33) of all cases the desire to have a child with a new partner, resulting from a previous divorce, was reason for a reversal procedure. The wish to have more children within the same marriage accounted for 35% (n = 24) see (table 1).

Table 1. *Reasons for vasectomy reversal*

| | <i>Patients</i> | |
|----------------------------------|-----------------|----------|
| | <i>n</i> | <i>%</i> |
| Divorce and remarriage | 33 | 50 |
| Child died | 3 | 5 |
| Wife died | 3 | 5 |
| Desire for (an) additional child | 24 | 35 |
| Other | 3 | 5 |

Patency was described as the recurrence of sperm in the ejaculate after vasal reconstruction. Postoperative sperm counts were correlated to duration of obstruction (table 2).

Table 2. Obstructive interval compared with postoperative sperm concentrations in 66 patients

| <i>Obstructive interval years</i> | <i>n</i> | <i>Sperm concentrations, million/ml</i> | | | |
|-----------------------------------|----------|---|---------------------------|------------------------------|------------------------------|
| | | <i>0.10⁶</i> | <i><10⁶</i> | <i>10-20. 10⁶</i> | <i>>20.10⁶</i> |
| 0-2 | 3 | - | - | 1(33%) | 2(67%) |
| 2-5 | 28 | - | 6(21%) | 6(21%) | 16(58%) |
| 6-10 | 27 | 7(26%) | 5(18%) | 3(11%) | 12(45%) |
| >10 | 8 | 3(37.5%) | 3(37.5%) | - | 2(25%) |

As the latter became shorter the mean sperm count rose significantly. The fact that a patency rate of 100% occurred if the time to reversal was less than 5 years (fig. 1) was a remarkable finding. As the obstruction period became longer, the number of failures rose. An overall patency rate of 84.8% was achieved. Taking a 5-year obstruction interval under review, a pregnancy rate of approximately 67% (fig. 1) was obtained. Obviously there is a clear discrepancy between patency and pregnancy rates probably due to low postoperative sperm counts and/or circulating antisperm antibodies. Nevertheless, pregnancy occurred in 25% (2/8) of the patients with obstructive intervals of longer than 10 years.

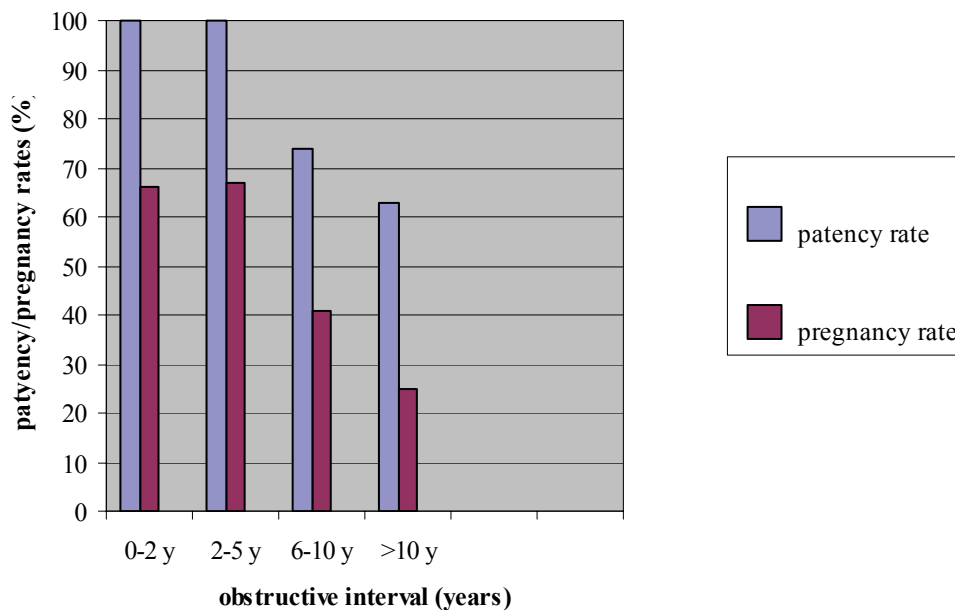


Fig 1. Obstructive interval versus patency and pregnancy rate in 66 patients

Preoperative antisperm antibodies in serum were determined in 35 patients. Despite the fact that a limited number of patients were studied, it seemed obvious that there was a correlation between the titre and the appearance of pregnancy after reversal (table 3). With serum agglutinin titres of $< 1/32$ there was a significantly better chance of obtaining pregnancy. Nevertheless, pregnancy occurred in 23% (3/13) of the patients with an agglutinin titre of 1/64. No pregnancies were recorded from the 2 patients with agglutinin titres of 1/256.

Table 3. Preoperative serum sperm agglutination titres correlated with pregnancy rates in 35 patients

| <i>Agglutination Titres</i> | <i>Patients</i> | <i>Pregnancies</i> | |
|---------------------------------|-----------------|--------------------|----------|
| | | <i>n</i> | <i>%</i> |
| Negative | 10 | 8 | 80 |
| 1/4 | 4 | 2 | 50 |
| 1/16 | 3 | 2 | 66 |
| 1/32 | 3 | nil | nil |
| 1/64 | 13 | 3 | 23 |
| 1/256 | 2 | nil | nil |

Discussion

This study illustrates once more that there is an obvious relation between the duration of the obstructive interval and postoperative pregnancy rates. Previous studies have illustrated the same phenomenon. Silber ³ indicated in his study in 1977 that patients with intervals of 10 years or more had poor chances for fertility. Nevertheless, we believe that such long intervals should not deter a surgeon from performing a reanastomosis. An important prognostic factor is whether the vas fluid coming from the testicular vas end contains spermatozoa. Belker and Bennett ⁴ suggested that the fluid obtained intraoperatively from the testicular vas end should be examined microscopically to decide whether vasovasostomy or vasoepididymostomy should be performed. In this series we only observed macroscopically if fluid was coming from the testicular end and no microscopical examination was carried out. The use of an internal splint during the operation has frequently been discussed. Several studies reported on the use of an absorbable polyglycolic acid tube stent in rats and dogs ^{5, 6}. There seemed to be a superior re-epithelialization and closer return of the vas to normal morphology in polyglycolic stented anastomoses, than in anastomoses created with the conventional two-layer technique.

Reduction of perivasaal inflammatory reaction (probably due to sperm leakage), ease of anastomosis with satisfactory approximation of vasaal ends and maintaining luminal patency, are several other advantages claimed for with this stent. In the present series a prolene 0 wire was used as a splint and it was carried up through the proximal end of the vas deferens and then led into the distal part where it left the vas transmurally through a hollow medical needle. In this way the creation of the anastomosis with double-ended prolene 7.0 was facilitated. The use of a carbon dioxide (CO₂) laser in creating an anastomosis has been previously described by several authors. Rosenberg ⁷ presented his results with this technique in 1988. He demonstrated postoperative sperm counts of over 20 million/ml in 86% of the patients and a pregnancy rate of 43% in the group of patients operated on within 10 years of the vasectomy.

The influence of antisperm antibodies upon fertility after vasectomy is a well-known phenomenon. Matson et al.⁸ noticed the fact that conception rates were reduced in those couples in whom the presence of IgG or IgA+IgG antisperm antibodies occurred in seminal fluid. Meinertz et al.⁹ also stressed the finding that especially the occurrence of 19A in the seminal fluid was associated with low conception rates. Aitken et al.¹⁰ described the capacity of antibodies to stimulate or suppress sperm/oocyte fusion. In vasovasostomized patients they saw a higher stimulating effect on this fusion than in patients with primary infertility. In their series they observed no correlation between the titre of antisperm antibodies and the ability of these antibodies to influence sperm function.

The significance of white blood cells in the ejaculate remains a point of further investigation. Barratt et al.¹¹ documented the white blood cell types in the ejaculates of vasovasostomized men and noticed that those men without antisperm antibodies had a predominance of suppressor/cytotoxic T cells over helper/inducer T cells. Witkin and Goldstein ¹² also viewed the fact that a decrease in suppressor/cytotoxic T cells may lead to a condition in which the formation

of antisperm antibodies is stimulated. Broderick et al.¹³ investigated the immunological status of 55 patients before and after vasectomy reversal. Those men who had greater quantities of sperm-surface antibodies in their vasal fluid had significantly lower motility percentages.

Spermatic granulomas are thought to have a certain impact on the development of immobilizing antibodies. Alexander and Schmidt¹⁴ performed a study on 77 vasovasostomized men and found more sperm-immobilizing antibodies in patients with granulomas than in those without. In the previously mentioned study of Broderick et al.¹³, only 2 out of 12 patients (with significant sperm-surface antibodies) had granulomas. In a review article by Cos et al.¹⁵ the presence of a sperm granuloma at the site of ligation after vasectomy might be interpreted as a pressure relief valve. Those patients, who underwent a reversal procedure, including removal of their granulomas before reanastomosis, had an explicit good quality sperm in their ejaculum.

These studies illustrate once more that the opinions on this subject still differ. We maintain our policy of performing reversal procedures even in patients with considerably raised preoperative serum titres of antisperm antibodies.

References

1. Belker AM, Thomas AJ., Fuchs EF, Konnak JW, Sharlip ID: Results of 1,469 microsurgical vasectomy reversals by the vasovasostomy study group.
J Urol 1991; 145:505-511.
2. Kabalin IN, Kessler R: Macroscopic vasovasostomy reexamined.
Urology 1991; 38:135-138.
3. Silber SJ: Pregnancy after vasovasostomy for vasectomy reversal: A study of factors affecting long-term return of fertility in 282 patients followed for 10 years.
Human Reprod 1989; 4: 318-322.
4. Belker AM, Bennett AH. Applications of microsurgery in urology.
Surg Clin North Am 1988; 68: 1157-1162.
5. Flam TA, Roth RA, Silverman ML, Gagne RG: Experimental study of hollow, absorbable polyglycolic acid tube as stent for vasovasostomy.
Urology 1989; 33:490-494.
6. Berger RE, Jessen JW, Patton DL, Bardin ED, Bums MW, Chapman WH: Studies of polyglycolic acid hollow self-retaining vasal stent in vasovasostomy.
Fertil Steril 1989; 51 :504-508.
7. Rosemberg SK: Further clinical experience with CO2 laser in microsurgical vasovasostomy. Urology 1988; 32:225-227.
8. Matson PL, Junk SM, Masters RW, Pryor JP, Yovich JL: The incidence and influence upon fertility of antisperm antibodies in seminal fluid following vasectomy reversal. Int J Androl 1989; 12:98-103.

9. Meinertz H, Linnet L, Fogh-Andersen P, Hjort T. Anti-sperm antibodies and fertility after vasovasostomy: A follow-up study of 216 men. *FertilSteril*1990; 54:315-321.
10. Aitken RJ, Parslow JM, HargreaveTB, Hendry WF: Influence of antisperm antibodies on human sperm function. *Br J Urol* 1988; 62:367-373.
11. Barratt CLR, Harrison PE, Robinson A, Cooke ID: Antisperm antibodies and lymphocyte subsets in semen -Not a simple relationship. *Int J Androl* 1990; 13:50-58.
12. Witkin SS, Goldstein M: Reduced levels ofTsuppressor/cytotoxic lymphocytes in semen from vasovasostomized men: Relationship to sperm autoantibodies. *J Reprod Immunol* 1988; 14:283-290.
13. Broderick GA, Tom R, McClure RD: Immunological status of patients before and after vasovasostomy as determined by the immunobead antisperm antibody test. *J Urol*1989; 142:752-755.
14. Alexander NJ, Schmidt SS: Incidence of antisperm antibody levels and granulomas in men. *Fertil Steril*1977; 28:655-657 .
15. Cos LR, Valvo JR, Davis RS, Cockett ATK: Vasovasostomy: Current state of the art. *Urology* 1983; 28:567-575.

Chapter 5

Influence of postvasectomy spermgranulomas, antisperm-antibodies formation and histological alterations of testicular/epididymal tissue on the outcome of vasectomy reversal.

Henricus.J.E.J. Vrijhof^a, August .A.B. Lycklama a Nijeholt^b

Department of Urology, Catharina Hospital, The Netherlands^a

Department of Urology, Leiden University Medical Centre, Leiden, The Netherlands^b

Submitted for publication

Introduction

The success of a vasectomy reversal depends on several factors. A well known factor is the obstructive interval which is the time period between vasectomy and reversal. Other factors are length of the vas resection during vasectomy and occurrence of vasal fluid from the testicular end at the time of reversal as well as fertility status of the partner and the partner's age. In this review article we will focus on the influence of sperm granuloma, antisperm antibody formation and tissue damage to epididymis and testis on the final outcome of a vasectomy reversal. Many studies were contradictory on this subject raising uncertainty on their importance. Ligation of the testicular end at the time of vasectomy will lead to an enhancement of epididymal pressure sometimes resulting in granuloma formation as well as antisperm antibody production. This raise in pressure will eventually lead to tissue damage of epididymis and testis. What is the impact of a pressure release valve like a sperm granuloma on this sequence and what is the influence of this tissue damage on the vasovasostomy result? Do open-end vasectomies at the testicular side prevent these histological alterations and how do open-end vasectomies versus obstructive vasectomies affect antisperm antibody formation?

Role of sperm granuloma

Sperm granulomas are present in 10-30% of men undergoing a reversal procedure ¹. Sperm granulomas play an important role in the regulation of chronic obstruction in the male reproductive tract. A sperm granuloma is a complex network of multiple minimal epithelialized channels that help to prevent high intraluminal pressure in the obstructed ducts. Obstructive vasectomy induces a rise in pressure affecting the epididymis and efferent ductules. These structures become markedly distended and then adapt to reabsorb large volumes of testicular fluids and sperm products. In time all vasectomized men will develop blow outs of the epididymis or efferent ducts. Sperm granulomas may develop at the site of the disruption and secondary epididymal or efferent duct obstruction may result. These events are the reason why vasectomy reversal is less successful if the obstruction interval increases. Sperm granulomas on the other hand may prevent this progressive damage to the epididymis and efferent ducts because these granulomas may act as pressure valves protecting the epididymis and efferent ducts from further deterioration. Above mentioned processes are extensively described in numerous animal studies ²⁻⁷. From these studies there is little doubt that epididymal and testicular obstruction due to vasectomy will eventually lead to rupturing of epididymal tubules and formation of granulomas in these animals. Because it is difficult to obtain human tissue specimens there is only limited information on morphologic changes of human testes and epididymidis after vasectomy, but spermatic granulomas are reported ⁸.

Spermatic granulomas do probably have an impact on the development of immobilizing antibodies. Alexander and Schmidt ⁹ performed a study on 77 vasovasostomized men and found more sperm-immobilizing antibodies in patients with granulomas than in those without (67% versus 48%). In contrast, in a study performed by Broderick et al.¹⁰, only 2 out of 12 patients with significant sperm-surface antibodies had granulomas. In a review article ¹¹, the

presence of a sperm granuloma at the site of ligation after vasectomy might be interpreted as a pressure release valve. Those patients, who underwent a reversal procedure, including removal of their granulomas before reanastomosis, had an explicit good quality sperm in their ejaculum. These findings that men with sperm granuloma at the site of ligation had better intraoperative sperm quality and improved patency (81%) and pregnancy rates (53%) were previously described by Silber ^{12,13} . These outcomes were conflicting with the results of the Vasovasostomy Study Group ¹⁴ who presented the results of 1469 microsurgical vasectomy reversals. The presence of bilateral sperm granulomas at the vasectomy sites had no beneficial effect on the patency ($p=0.050$) or pregnancy rates ($p=0.150$). In a more recent paper by Boorjian et al. ¹⁵ the role of sperm granulomas on the outcome of 213 vasectomy reversals was investigated. They described better patency rates in men with granulomas then in those without (95% versus 78%). It is remarkable that there are no more recent literature data (pub med search 1998-2005) on the role of sperm granuloma as a possible mediator in successful vasectomy reversals. If the presence of sperm granulomas is important for increased success rates after vasovasostomy remains a question.

Could open-ended vasectomies induce sperm granuloma formation at the testicular end and could it thus have a beneficial effect on vasectomy reversals as it works as a pressure release valve? If so, could open-ended vasectomies be a solution to prevent increased pressure in the epididymis and subsequent bursting of epididymal tubules leading to granuloma formation within the epididymis and ductal obstruction. Shapiro and Silber ¹⁶ studied the development of granuloma formation in larger series of patients with open ended vasectomy. In a group of 410 patients from Ottawa, 97% developed a sperm granuloma at the non-ligated testicular vas end. In a second group of 23 patients from St Louis, all patients developed sperm granulomas at the testicular end. Despite this possible beneficial granuloma effect, Goldstein ¹⁷ stressed the fact

that open ended vasectomies could lead to higher vasectomy failure rates and therefore should be applied with the utmost precaution. In a larger series by Errey and Edwards¹⁸ this risk of spontaneous recanalization was weakened. They compared 4330 open-ended vasectomies with 3867 standard vasectomies and spontaneous recanalization was rare in both groups. Essential was that the abdominal end was covered by vas sheath. All studies¹⁹⁻²³ published in the last fifteen years on the subject of open-ended vasectomy indicated reduction of epididymal congestion and post vasectomy orchialgia, but none of these studies gave definitive prove of a beneficial effect on vasovasostomy results in terms of patency and pregnancy rates. A well designed comparative study, between patients who had closed-ended or open-ended vasectomies before vasectomy reversal, is mandatory on this subject, taking into account that the outcome of vasectomy reversal is multifactorial.

Development of antisperm-antibodies

Presence of T suppressor/cytotoxic cells and formation of antisperm antibodies

Vasectomy may also induce local and systemic immune effects. Regarding the local effects, chronic epididymal obstruction results from inspissated sperm, damaging the efferent ducts leading to leakage, granuloma formation and fibrosis. Intraductal phagocytosis (with degradation of sperm) produces soluble antigens that pass the damaged transverse epithelial tight junctions due to distension and leakage. Inoculations of the immune system with these sperm antigens will result in activation of the humoral immunity system leading to antisperm antibody production. Obstructive vasectomy results in such a violation of the blood-testis barrier resulting in detectable levels of serum antisperm antibodies in 60-80 percent of men after vasectomy. Some data indicate diminishing of antibody titers in serum two or more years after vasectomy, others indicate persistent titers²⁴⁻²⁷.

Next to the humoral immune system there is a cell mediated immune system. This involves the killing of antigens by phagocytes, cytotoxic lymphocytes and natural killer cells. The T cell lymphocytes are responsible for cell mediated immunity. After recognizing the antigen, the T cell lymphocytes order the B cell lymphocytes to produce antisperm antibodies. There are two subtypes of T cells (helper and suppressor) which are of importance in cell mediated immunity at the male genital area. The most important are the T suppressor/cytotoxic cells which occur mainly at the area of rete testis and efferent tubules. The existence of the T suppressor /cytotoxic cells at these locations could, as a theory, suppress any immune reaction and could probably play an important role in the prevention of antisperm antibody production ²⁸. In a study by Witkin and Goldstein a group of non vasectomized men were compared with men who had undergone both a vasectomy and a microsurgical vasovasostomy. Antisperm antibodies were detected in sperm, in seminal fluid and/or in serum of all the vasovasostomy patients but in none of the controls. Damage to the integrity of the excurrent ducts may induce alterations in T cell regulation, leading to a decrease in T suppressor/cytotoxic cells creating formation of auto antibodies to sperm-specific antigens ²⁹.

Consequences of antisperm antibodies in semen

Only few (4%) vasectomized men have antibodies detectable in seminal plasma ³⁰.

After vasovasostomy sperm agglutinins may appear in the seminal plasma of some men, provided that antisperm antibodies were detectable in serum before operation. Thus, systemically and/or locally produced antisperm antibodies do enter the obstructed part of the male genital tract in vasectomized men. This was confirmed in a study on motile epididymal spermatozoa obtained from men during vasovasostomy ³¹. It was found that the antisperm antibodies detected with the mixed antiglobulin reaction (MAR) were bound to the sperm

surface at the epididymis level of the male genital tract. One year after operation the MAR-results on ejaculates were almost identical to the results obtained with epididymal spermatozoa. Thus, the binding of antisperm antibodies, takes place primary at the level of the epididymis. A study with split ejaculates from different compartments, did not exclude however, that additional binding may take place at the level of the prostate and the seminal vesicles ³².

Linnet et.al. ³³ pointed out the significance of antisperm antibodies for pregnancy rates. They found a pregnancy rate of 85% among vasovasostomized men without antisperm antibodies in seminal plasma; however the mere presence of antisperm antibodies in seminal fluid, using the tray agglutination test (TAT), reduced the pregnancy rate to 14%. These results were confirmed by several other studies on this subject. Parslow et.al ³⁴ found that the presence of antisperm antibodies in seminal plasma after vasectomy reversal was associated with diminished fertility only if the titer in the TAT exceeded 16, nevertheless even with higher titers, conceptions occurred. Studying serum antisperm antibodies, the same group ³⁵ observed that pregnancy was significantly less likely when the preoperative serum antisperm antibody titer in the TAT was high, 512 or more.

Matson and co-workers ³⁶ found reduced conception rates in those couples in whom the presence of IgG or IgA+IgG antisperm antibodies occurred in seminal fluid. Meinertz et al. ³⁷ reported on 216 vasovasostomized men who were tested with the mixed antiglobulin reaction for IgA, IgG and secretory IgA antisperm antibodies bound to the sperm membrane. Free antisperm antibodies were analyzed with the gelatine agglutination test and the TAT. In a subgroup with only IgG response, the rate of conception was 85.7%, while 42.9% of men, who also had IgA on the sperm, achieved pregnancy. When 100% of the sperm was covered with IgA, the conception rate decreased to 21.7%. The combination of IgA on all sperm and a serum titer ≥ 256 was associated with zero conception. Aitken et al. ³⁸ described the impact of

antibodies to stimulate or suppress sperm/oocyte fusion. In vasovasostomized patients they saw a higher stimulating effect on this fusion than in patients with primary infertility. In their series they observed no correlation between the antisperm antibodies titers in serum and seminal plasma and the ability of these antibodies to influence sperm function.

The significance of white blood cells in the ejaculate after vasovasostomy remains a point of further investigation. Barratt et al.³⁹ documented the white blood cell types in the ejaculates of vasovasostomized men and noticed that those men without antisperm antibodies had a predominance of suppressor/cytotoxic T cells over helper/inducer T cells. As previously said, Witkin and Goldstein²⁹ also viewed the fact that a decrease in suppressor/cytotoxic T cells may lead to a condition in which the formation of antisperm antibodies is stimulated.

Histological changes of testis and epididymis after vasectomy and vasectomy reversal

Animal studies

Postvasectomy histological changes in rats were discussed by Turner et al.⁴⁰ who described the importance of certain proteins in testis and epididymis (cysteine-rich secretory protein, prostaglandin D2 synthetase, phosphatidylethanolamine-binding protein) in the maturation and possible agglutination of sperm cells after vasovasostomy. The interstitial tissue in the epididymis was much more densely occupied by lymphocytic cells than in sham operated controls, suggesting that sperm material might have escaped the lumen, provoking an inflammatory reaction.

The relationship between development of antisperm antibodies after unilateral vasectomy and the occurrence of testicular damage on the non-vasectomized side was studied by Chehval et al.⁴¹. They performed a unilateral vasectomy in rats and described a relationship between the onset of antisperm antibodies after 30 days of obstruction and the occurrence of testicular

changes on the contra lateral side. They concluded that epididymal and/or testicular tissue damage after vasectomy does not only depend on high pressure in the epididymis but also on deposition of systemic circulating immune complexes as seen in the healthy non-obstructed side.

Johnson and Howards ⁴² investigated the effect of increased intraluminal pressure in the testis and epididymis after vasectomy in hamsters. They described mainly an increase in pressure in the epididymis and not in the testis. The pressures measured in the cauda epididymis, two weeks after vasectomy, were significantly higher ($p < 0.0005$) compared to normal controls. Due to distension of the epididymis, ruptures were seen, illustrating the limitation in distensibility of the epididymis and its reabsorptive capacity. They could not find change in weight of the testes compared to normals four weeks after vasectomy. The effect of vasectomy on the epididymis in rats was also extensively studied by Flickinger et.al. ³. Increased pressure in the epididymis is not generally transmitted towards the seminiferous tubules. The epididymal interstitium shows microscopic changes indicative of chronic inflammation with infiltration of lymphocytes, macrophages and plasma cells. Rats that have these tissue changes also have higher antisperm antibodies in serum. Due to these pressures the epididymal ducts will burst with escape of spermatozoa leading to an immune response and granuloma formation.

Whether testicular alterations after vasectomy are reversible by vasovasostomy was studied by Flickinger et.al. ⁴³. A group of Lewis rats was vasectomized and testicular weight and morphological alterations were described. Especially as time after vasectomy went by the testicular alterations enhanced. As a vasovasostomy procedure was advanced, the progression of these testicular changes was reduced but not reversed. Smaller testicles after vasectomy showed severe alterations in the seminiferous tubules compared to heavier testicles that presented with a normal morphology. Testicular alterations were graded for light microscopy

by use of a semiquantitative testicular biopsy score count (TBSC). As a result, the degree of morphologic changes corresponded closely to the testicular weight. A similar study in Lewis rats was performed by Herr et al.⁴⁴. Testicular weight, histology and antisperm antibodies were studied, using enzyme-linked immunosorbent assay (ELISA). Animals with altered testes after vasectomy showed significantly greater mean absorbance values in ELISA, compared to animals without testicular alterations. Animals with a positive antisperm antibody response were seen in the group with testicular alterations but also in the group without testicular damage. Compared to the sham group, the level of antisperm antibodies in the vasectomized and vasovasostomized animals was significantly higher. Animals that had a successful reversal procedure (in terms of sperm count) showed even after 4 months similar elevated concentrations of antisperm antibodies compared to the vasectomized rats. The group of animals with small testes after vasectomy showed severe microscopic alterations consisting of depletion of germ cells. Seminiferous tubules lacked all stages of germ cells and thus were composed almost entirely of Sertoli cells. Animals with normal sized testes showed no morphological changes and resembled those of the sham group. These findings were confirmed by Neaves⁴⁵, who also examined histological changes on the testes in rats after vasectomy.

Vasovasostomy results, in terms of semen quality, were significantly better in animals that had a vasocystostomy as a contraceptive method compared to animals that had a vasectomy (100% versus 36 %). This is due to the epididymal and testicular changes after vasectomy. In 19 out of 26 rabbits (73%) some degree of disruption of the germinal epithelium of the testis was seen, however no testicular alterations were seen in the vasocystostomy group. Also the epididymis of vasectomized rabbits showed significant tissue changes in 42%. Especially fibrosis was seen in the caput and corpus area. In the vasocystostomy group only one granuloma was seen in the

cauda epididymis. Pressure release thanks to the vasocystostomy was of importance in the prevention of epididymal and testicular tissue damage ⁴⁶.

Human studies

Studies on the effect of interstitial testicular fibrosis on vasovasostomy results in men are sparse. Jarow et al. ⁴⁷ took testis biopsies from men undergoing vasectomy reversal and healthy volunteers. The morphometric analyses of these specimens revealed a significant increase in thickness of seminiferous tubular walls mean cross-sectional tubular area and a reduction in the mean number of Sertoli cells and spermatids. Focal interstitial fibrosis was only seen in the vasectomy group and not in the controls. They observed a significant ($p<0.01$) correlation between interstitial fibrosis and successful vasectomy reversal. In continuation of this study, Jarow et al. ⁴⁸ pointed out that there was no association between testicular histologic changes and immune status of vasectomized men.

In two more or less identical studies by Shiraishi et al. ^{49,50} men obtained a testis biopsy at the time of vasectomy reversal. Significant increase in interstitial fibrosis was seen as obstructive intervals became longer. Interstitial fibrosis and not the extent of germ cell differentiation, measured by the proliferative cell nuclear antigen expression (PCNA), were important in the successful outcome of the vasectomy reversal. In a recent study by Raleigh et al. ⁵¹ 34 men receiving testicular biopsies at the time of vasectomy reversal were compared with 10 normal controls. Biopsies were examined for testicular germ cell populations and testicular fibrosis. Patients undergoing a vasectomy reversal had a significant decrease in germ cells in the later stages of spermatogenesis and had a significant increase (2.7 fold) in interstitial fibrosis. Both changes correlated strongly with the obstructive interval and the final outcome of the

vasectomy reversal. From these studies it seems obvious that testicular change do occur after vasectomy and that these changes do have an influence on the outcome of vasectomy reversal.

Discussion

Sperm granulomas, antisperm antibodies and tissue damage to epididymis and/or testis after vasectomy are all related to one another. Nevertheless each anomaly itself has a certain impact on the results of vasectomy reversal.

Regarding the literature, sperm granuloma will develop eventually in all men who had a vasectomy. From animal studies it is clear that sperm granulomas act as pressure relieve valves preventing further tissue damage to epididymis and testis. Otherwise the appearance of sperm granuloma induces the production of antisperm antibodies that still might damage the epididymal and testicular tissues. No study in men has been published with prove that the existence of sperm granuloma do improve vasovasostomy results. Several studies on the subject of open-ended vasectomies look promising on the reduction of epididymal pressure rise preventing damage to the ductules and thus antisperm antibody formation.

Concerning antisperm antibodies, a strong relationship between the appearance of sperm granuloma and antisperm antibodies is apparent. The importance of these antisperm antibodies in vasectomy reversal remains unclear. It is clear from studies published in literature, that higher antisperm antibodies titers in serum before vasectomy reversal do have an adverse effect on sperm quality. It is obvious that antisperm antibodies in serum do not influence the sperm motility. It is the antibodies in seminal plasma that interfere with sperm motility. Measuring of antisperm antibody titers in serum does not automatically indicate that ‘immobilizing antisperm antibodies’ are present in semen. Unfortunately we can not determine the influence of antisperm antibodies on sperm as long as the patient is still in a vasectomy status.

When considering vasectomy reversal, the relevance of these antisperm antibodies in daily practice is still unclear. Do higher antisperm antibody titers restrain physicians from performing a reversal procedure? We think not, because the only alternative is assisted reproductive techniques (ART). This alternative treatment is invasive for wife and man and much more expensive^{52,53}.

From animal studies we know that tissue damage is mainly occurring in the epididymis due to tubular rupturing, fibrosis and eventually obstruction. The testis is not always protected from these increased pressures. Interstitial fibrosis and increased seminiferous wall thickness are the most frequently described changes in testicular parenchyma in men. Despite the fact that the numbers of studies (and patients in these studies) are limited, we are convinced that testicular damage eventually occurs. With longer obstructive intervals more damage to the tissues will be seen, with an adverse effect on patency and pregnancy rates. But then again, who takes testis biopsies before vasectomy reversal and measures the amount of interstitial fibrosis and germ cell differentiation? Our knowledge of the influence of tissue changes in the testis on the outcome of vasectomy reversal is still limited. The importance of these tissue changes in men remains unclear due to the fact that from an ethical point of view these studies are hard to perform.

Reviewing the literature, some form of pressure release of the epididymis after vasectomy will have a beneficial effect on vasovasostomy results. The fear that open ended vasectomy results in a higher failure rate (in terms of azoospermia) seems not justified. If so, open-ended vasectomy could be the technique of choice in an era with growing numbers of divorces and renewed wish to have a child. But how can we be sure that if we leave the testicular end open that reactive fibrosis will not completely occlude this testicular end? How can we investigate the development of a possible sperm granuloma at this end and how can we be sure that this

works as a pressure relieve valve? A comparative study between open-ended and closed-ended vasectomy has to be performed to prove this hypothetical beneficial effect of open-ended vasectomy on vasovasostomy outcomes.

References

1. Walsh PC, Retik AB, Stamey TA and Vaughan Jr. ED. Surgery of male infertility and other scrotal disorders. Campbell's Urology sixth edition vol 3; 3114-3149.
2. Sun YB., Qiu Y. and Wang ZX. Vasectomy and spermatic granuloma in hamsters. Contraception 1992; 45: 177-185.
3. Flickinger CJ, Howards SS, Herr JC. Effects of vasectomy on the epididymis. Microsc. Res. Tech. 1995; 30:82-100.
4. Mc Donalds SW, Lockhart A, Gormal D, Bennett NK. Changes in the testes following vasectomy in the rat. Clin. Anat. 1996; 9:296-301.
5. Caldwell JC, McCadey J, Kerr R, Bennett NK, McDonald SW. Cell recruitment to the sperm granuloma which follows vasectomy in the rat. Clin. Anat 1996; 9: 302-308.
6. Itoh M, Miyamoto K, Satriotomo I. Takeuchi Y. Spermatic granuloma are experimentally induced in epididymides of mice receiving high-dose testosterone implants. A light-microscopic study. J. Androl. 1999; 20:551-558.
7. McGinn JS, Sim I, Bennett NK, McDonald SW. Observations on multiple sperm granulomas in the rat epididymis following vasectomy. Clinic. Anat. 2000; 13: 185-194.
8. Flickinger CJ. The effects of vasectomy on the testis. N. Engl. J. Med. 1985; 313: 1283-1285.
9. Alexander NJ, Schmidt SS. Incidence of antisperm antibody levels and granulomas in men. Fertil Steril 1977; 28:655-65.
10. Broderick GA, Tom R, McClure RD. Immunological status of patients before and after vasovasostomy as determined by the immunobead antisperm antibody test. J. Urology 1989; 142: 752-755

11. Cos LR, Valvo JR, Davis RS, Cockett ATK. Vasovasostomy: Current state of the art. *Urology* 1983; 28:567-575.
12. Silber SJ. Reversal of vasectomy and the treatment of male infertility. Role of microsurgery, vasoepididymostomy and pressure induced changes of vasectomy. *Urol. Clin.North Am.* 1981; 8: 53-62.
13. Silber SJ. Sperm granuloma and reversibility of vasectomy. *Lancet* 1977; 2: 588-589.
14. Belker AM, Thomas AJ, Fuchs EF, Konnak JW, Sharlip ID. Results of 1469 microsurgical vasectomy reversals by the vasovasostomy study group. *J. Urol.* 1991; 145: 505-511.
15. Boorjian S, Lipkin M., Goldstein M. The impact of obstructive interval and sperm granuloma on outcome of vasectomy reversal. *J Urol.* 2004; 171:304-6.
16. Shapiro EI. and Silber SJ. Open-ended vasectomy, sperm granuloma and postvasectomy orchialgia. *Fertil. Steril.* 1979; 32: 546-550
17. Goldstein M. Vasectomy failure using an open-ended technique. *Fertil Steril.* 1983; 40:699-700
18. Errey BB and Edwards IS. Open-ended vasectomy: an assessment. *Fert. Steril.* 1986; 45:843-846
19. Edwards IS. Open-ended vasectomy *Adv. Contracept. Deliv. Syst.* 1988; 4: 195-224
20. Schmidt SS. Vasectomy failure and open-ended vasectomy. *Fert.Steril.* 1985; 44: 557-558
21. Temmerman M, Cammu H, Devroey P, Ad Amy JJ. Evaluation of one-hundred open-ended vasectomies. *Contraception* 1986; 33; 529-532
22. Denniston GC and Kuehl L. Open-ended vasectomy: approaching the ideal technique. *J. Am. Board Fam Pract.*1994; 7: 285-287

23. Gade J and Brasso K. Sperm granulomata. *Ugeskr.Laeger.* 1990; 152: 2282-2284
24. Fuchs EF, Alexander N. Immunologic considerations before and after vasovasostomy. *Fertil. Steril.* 1983; 40: 497.
25. Lepow IH, Crozier R. Vasectomy: immunologic and pathophysiologic effects in animals and man. New York. Acad. Press, 1979
26. Shulman S, Zappi E, Ahmed U, Davis JE. Immunologic consequences of vasectomy. *Contraception* 1972; 5:269-278.
27. Ansbacher R. Vasectomy: sperm antibodies. *Fert.Ster.* 1973; 24:788-792.
28. Mahi-Brown CA, Yule TD, Tung KSK. Evidence for active immunological regulation in prevention of testicular autoimmune disease independent of the blood-testis barrier. *Am J Reprod Immunol Microbiol.* 1988; 16:165-70.
29. Witkin SS, Goldstein M. Reduced levels of Tsuppressor/cytotoxic lymphocytes in semen from vasovasostomized men; relationship to sperm autoantibodies. *J. Reprod. Immunology* 1988; 14: 283-290.
30. Linnet L, Hjort T. Sperm agglutinins in seminal plasma and serum after vasectomy, correlation between immunological and clinical findings. *Clin. Exp. Immunol.* 1977; 30:413-420.
31. Meinertz H., Linnet L., Wolf H., Hjort. T. Antisperm antibodies on epididymal spermatozoa. *Am. Journ. Reprod. Immunology.* 25: 158-162, 1991
32. Meinertz H. Antisperm antibodies in split ejaculates. *Am. Journ. Reprod. Immunology.* 26:110-113, 1991
33. Linnet L. Fogh-Andersen P, Hjort T. Association between failure to impregnate after vasovasostomy and sperm agglutinins in semen. *Lancet* 1: 117-119, 1981

34. Parslow J.M, Royle M.G, Kingscott M.M.B, Wallace DMA., Hendry WF. The effects of sperm antibodies on fertility after vasectomy reversal. *Am. J.Reprod. Immunology.* 3:28-31, 1983
35. Royle MG, Parslow JM, Kingscott MMB, Wallace DMA, Hendry WF. Reversal of vasectomy; The effects of antisperm antibodies on subsequent fertility. *Br. J. Urology.* 53: 654-659, 1981
36. Matson PL, Junk SM, Masters RW, Pryor JP, Yovich JL. The incidence and influence upon fertility of antisperm antibodies in seminal fluid following vasectomy reversal. *Int J Androl.* 1989; 12:98-103.
37. Meinertz H, Linnet L, Fogh-Andersen P, Hjort T. Anti-sperm antibodies and fertility after vasovasostomy: A follow-up study of 216 men. *FertilSteril*1990;54:315-321.
38. Aitken RJ, Parslow JM., HargreaveT.B, Hendry WF. Influence of antisperm antibodies on human sperm function. *Br J Urol* 1988;62:367-373.
39. Barratt CLR, Harrison PE., Robinson A, Cooke ID. Antisperm antibodies and lymphocyte subsets in semen -not a simple relationship. *Int J Androl* 1990;13:50-58.
40. Turner, TT, Riley, TA, Vagnetti, M., Flickinger, C.J, Caldwell JA, Hunt, DF. Postvasectomy alterations in protein synthesis and secretion in the rat caput epididymis are not repaired after vasovasostomy. *Journal of Andrology* 21: 276-290,2000
41. Chehval MJ, Doshi R, Kidd CF., Winkelmann T. and Chehval V. Antisperm autoantibody response after unilateral vas deferens ligation in rats: when does it develop? *J. Androl.* 2002; 23: 669-673
42. Johnson AL and Howards SS. Intratubular hydrostatic pressure in testis and epididymis before and after vasectomy. *Am. J. Physiology* 228:556, 1975

43. Flickinger C J, Herr JC, Howards SS, Caloras D, Scott Yarbrow E, Spell DR, Gallien TN.
The influence of vasovasostomy on testicular alterations after vasectomy in Lewis rats.
The Anatomical Record, 217: 137-145, 1987
44. Herr JC, Flickinger CJ, Howards SS, Scott Yarbrow E, Spell DR, Caloras D, Gallien TN.
The relation between antisperm antibodies and testicular alterations after vasectomy and
vasovasostomy in Lewis rats. Biology of Reproduction 37: 1297-1305, 1987
45. Neaves WB. The effect of vasectomy on the testes of inbred Lewis rats.
Journal of Reproductive Fertility 54: 405-411, 1978
46. Hooker RH. Changes in the testes and epididymis of rabbits following long term
vasectomy or vasocystostomy: correlation with results of vasovasostomy. Biology of
Reproduction 22: 297-306, 1980
47. Jarow JP, Budin RE, Dym M, Zirkin BR, Noren S, Marshall FF. Quantitative pathologic
changes in the human testis after vasectomy. A controlled study. N Engl J Med. 1985 Nov
14; 313(20):1252-6.
48. Jarow JP, Goluboff ET, Chang TS, Marshall FF. Relationship between antisperm
antibodies and testicular histologic changes in humans after vasectomy. Urology. 1994
Apr;43(4):521-4.
49. Shiraishi K, Takihara H. and Naito K. Influence of interstitial fibrosis on
spermatogenesis after vasectomy and vasovasostomy Contraception 2002; 65: 245-249
50. Shiraishi K, Takihara H. and Naito K. Quantitative analysis of testicular interstitial
fibrosis after vasectomy in humans. Aktuelle Urol. 2003 Jul; 34(4):262-4.

51. Raleigh D, O'Donnel L, Southwick GJ, de Kretser DM, Mc Lachlan RI. Stereological analysis of the human testis after vasectomy indicates impairment of spermatogenic efficiency with increasing obstructive interval. *Fertil Steril.* 2004 Jun;81(6):1595-603.
52. Pavlovich CP and Schlegel PN. Fertility options after vasectomy: a cost-effective analysis. *Fer. Ster.* 67; 133-141, 1997
53. Garceau L, Henderson J, Davis LJ, Petrou S, Henderson LR, Mc Veigh E, Barlow DH, Davidson LL. Economic implications of assisted reproductive techniques ; a systematic review. *Hum. Reprod.* 17: 3090-3109, 2002

Chapter 6

A polymeric mini-stent designed to facilitate the vasectomy reversal operation. A model study in rabbits.

**Eric J. Vrijhof ^a, Adriaan de Bruïne ^b, August A. B. Lycklama à Nijeholt ^c
and Leo H. Koole ^d**

Department of Urology, Catharina Hospital, Eindhoven, The Netherlands ^a

Department of Pathology, Academic Hospital of Maastricht, Maastricht, The Netherlands ^b

Department of Urology, Leiden University Medical Centre, Leiden, The Netherlands ^c

Centre for Biomaterials Research University of Maastricht, Maastricht, The Netherlands ^d

Introduction

Vasectomy has become widely accepted as a safe and reliable method for contraception¹⁻³.

Worldwide, more than 40 million couples rely on vasectomy to prevent pregnancy. The procedure is fast and reliable, and the long-term complication rates are low, i.e., in the range 0.08 – 0.10 %. The popularity of vasectomy has induced, however, an increasing demand for its reversal operation, which is known as vasovasostomy. In essence, vasovasostomy is bilateral microsurgical rejoining of the loose ends of the vas deferens. A recent population-based study by Holman et al.⁴, which was performed on a large cohort of vasectomy patients (>28,000) in Western Australia, showed that the population rates of vasectomy are stable, while the incidence of seeking a reversal has increased. The most important factors are: age, being single, being divorced, and being separated. Age appears to be an important factor: for men who had the vasectomy between 20 and 24 years of age, it was found that 11 % seek reversal within the first 15 years. For the cohort 25 – 29 years, this percentage was 6⁴.

Compared to vasectomy, vasovasostomy is a technically demanding operation. Modern microsurgical techniques, pioneered by Silber, represent the golden standard^{5,6}. From literature, it can be concluded that the rates for patency and maternity are in the range 85–90 % and 50–60 %, respectively. Scarification and stricturing are believed to be the major causes of failure. According to Silber's original concept, the anastomoses are made in two layers. Some urologists prefer a modified one-layer technique, which is easier to perform, quicker, and believed to induce less scarification and stricturing. Fischer and Grandmyre compared the two techniques, and found that the patency rates are comparable⁷. However, the mean operation time was 167 min for the two-layer technique, and 96 min for the modified one-layer procedure. There have been several attempts to improve the technique for vasovasostomy further. For example, Seaman reported preliminary experiments with a laser technique to

facilitate vasovasostomy surgery⁸, and Rothman et al. described a clinical trial with an absorbable polymeric stent for vasectomy reversal⁹. The absorbable stent, however, resulted in lower patency rates (81 % vs. 90 %), and lower pregnancy rates (22 % vs. 51 %), as compared to two-layer microscopic vasovasostomy.

Herein, we report our first experience with a new vasovasostomy technique, which is based on the use of a non-absorbable polymeric hollow mini-stent. This device is implanted to keep both vas deferens lumens open and exactly in line. We postulated that use of the ministent will decrease the risk for scarification and stricturing, provided that the biomaterial is sufficiently biocompatible. Furthermore, it was anticipated that the mini-stent will facilitate the operation. Biodegradability was considered to be of minor importance.

At the onset of this study, we decided to use a biomaterial on the basis of NVP. Poly (NVP) is well-known for its excellent biocompatibility and safety. For example, NVP-containing copolymers were found to adhere to porcine intestine to create a hydrophilic surface for cell adhesion and growth. As in our previous work¹⁰, we copolymerized NVP with n-butylmethacrylate (BMA)^{11,12}. These copolymers do not dissolve in water, and the NVP/BMA ratio provides a means to control the hydrophilicity and the degree of swelling. Furthermore, the material was cross linked by incorporating tri (ethyleneglycol) dimethacrylate in the reaction mixture. The exact composition was chosen on the basis of two criteria and a series of preliminary experiments. The criteria were:

- * The material must have sufficient rigidity in the dry state to allow for precision machining.
- * Immersion in water must lead to considerable softening, keeping the dimensions virtually unchanged.

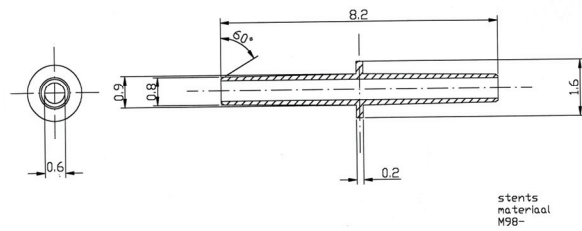



Fig 1. Design of the polymeric mini-stent. **a**, Computer-generated picture, showing the tapered ends and the ridge in the middle of the mini-stent. The ridge is sandwiched between both ends of the vas deferens, thus preventing migration of the mini-stent. **b**, Exact geometry (millimetres).

We postulated that the phenomenon of softening and swelling could be utilized, especially to facilitate implantation of the mini-stent. A procedure consisting of three steps was developed:

- * First, one half of the mini-stent is carefully inserted into the lumen of the vas deferens, i.e, till the end of the vas reaches the ridge. The rigidity of the biomaterial is advantageous for this step; softening of the stent-half starts after its positioning in the vas lumen.
- * Secondly, the other stent half is inserted into the lumen of the other vas end. Again, this is facilitated by the hardness of the dry stent-half. It is essential to perform this step immediately after the first one, in order to avoid premature softening.

* Thirdly, sutures are placed, such that the ridge is sandwiched between both vas ends.

The third step should be performed 2 - 3 minutes later than the second one, to enable softening of the ridge prior to suturing.

We verified, in a small number of ex vivo pilots that preceded the animal experiments, that this three-step implantation technique is feasible in practice. Vas material from both rabbit and human origin was used in these pilots; size and structure of human and rabbit vas deferens are highly comparable.

Materials and Methods

Polymere synthesis and mini-stent manufacture.

All reactive monomers were purchased from Aldrich, and were purified by distillation in vacuo. 1-Vinyl-2-pyrrolidinone (25.83 g, or 232.4 mmol), n-butyl methacrylate (14.22 g, or 100.0 mmol), and tri(ethyleneglycol) dimethacrylate (191 mg, or 666 μ mol) were transferred into a 100-mL round bottom flask. The radical initiator 2, 2'-azobis (2-methylpropionitrile) (AIBN, 24.0 mg, or 146 μ mol) was added and the contents of the flask were thoroughly mixed. The reaction mixture was transferred into several Teflon® tubes, and the polymerization was executed as described ¹¹. The polymerization reaction proceeded smoothly and reproducibly. A specimen of the material (weight: 0.86 g) was incubated in distilled water (25 mL, 25 °C) for a period of 1 week. Water uptake and swelling were observed during the first 12 h; no further changes occurred afterwards. After the week of incubation, the aqueous medium was separated and lyophilized. The residue was dissolved in 1 mL of D₂O, and subjected to analysis by ¹H NMR spectroscopy at 400 MHz. Only a trace of residual NVP was detected; back-calculation revealed that the original sample contained less than 10 mg of NVP, which is approximately 1 % of the monomer that was present originally. It was established in a separate control

experiment that no free NVP evaporates during lyophilization. A conversion rate of approximately 99 % is not exceptional for laboratory-scale bulk polymerizations. The biomaterial was obtained as cylindrical rods, which were slightly opaque. The rods were cut in pieces of approximately 20-mm length, which were machined on a computer-controlled lathe/mill system (Boley, Eslingen, Germany; type: BDN 160 R). A 1.00-mm hole was first drilled along the cylindrical axis of the specimen. A straight steel wire was fitted into the hole, to reinforce the delicate material during machining toward the desired shape.

Animal experiments.

All animal experiments were done according to the Principles of Laboratory Animals Care [prepared by the National Institutes of Health (NIH Pub. No. 85-23 rev. 1995)]. The study was approved by the Animal Experimental Committee of the University of Maastricht. All animals were male New Zealand white rabbits, aged between 6 and 12 months at the start of the experiments. Animals were anesthetized through intramuscular injection of ketamine (0.5 mL/kg) and xylazine (0.5 mL/kg). During the operation, a mixture of ketamine and xylazine (2 : 1) was administered intravascularly at a rate of 0.2 mL per 30 min. Animals were placed in a dorsal position, shaved, and sterilized. A transverse skin incision was made over both spermatic funiculi. The spermatic internal fascia was opened, and the vas deferens, lying loose within the funiculus, was easily luxated leaving the scrotal contents in situ. The vas was cut in a transverse way, and reconstructed immediately. Mini-stents were implanted bilaterally in the first group, after which both vas ends were approximated with three sutures of one-layer Prolene® 8.0 overlying the stent (a microscope was used). The second group underwent microscopical reconstruction with 4 to 5 one-layer Prolene® 8.0 sutures. For both groups, the vas was replaced within its funiculis and the spermatic internal fascia and overlying skin were closed

with 4.0 Vicryl[®]. Postoperatively, the animals received Temgesic (0.1 mL/kg) for a maximum of 48 h.

Semen samples were collected several days before the operation, and at regular time intervals after the operation, vide infra. The samples were obtained with the help of an artificial vagina system, as is normally used in agricultural artificial insemination stations for rabbits. At the time of sacrifice, the animals were deeply anesthetised, and then euthanised by an overdose injection of pentobarbital. Explanted *vas deferens* specimens (with or without mini-stent) were subjected to standard histopathological analysis (light microscopy, staining with hematoxylin and eosin).

Results and Discussion

Thirty-two male rabbits were included. First, semen analyses of all animals were performed; bundant numbers of sperm cells were found in almost every case (Tables 1 and 2). Vasectomy was performed on a small control group of 4 rabbits, with the aim to determine how much time is needed to obtain azoospermia. To the best of our knowledge, this information is not available in the literature. Semen analyses after 6 weeks and after 3 months showed complete azoospermia in all four cases. The four animals were then sacrificed. The remaining 28 rabbits were randomized over two equal groups. The first group underwent vasovasostomy with the mini-stent. One animal in this group died unexpectedly, soon after the operation, because of a gastric hair-ball. The second group underwent conventional vasovasostomy, i.e. using one-layer microscopic surgery. We also lost one animal in this group, because of pneumonia. At least 4 post-operative semen analyses were performed for each animal; in each case the last sample

was obtained just prior to sacrifice and autopsy. The results of these analyses are compiled in Tables 1 and 2.

Table 1. *Sperm cell concentrations measured for the rabbits with two implanted mini-stents.*

| Number | Sperm cells per mL, preoperative (millions) | Postoperative semen analysis at weeks | Mean number of sperm cells per mL, post-operative (millions) | Final number of sperm cells per mL (millions) |
|-------------------------|---|---------------------------------------|--|---|
| Mini-Stent Group | | | | |
| 1 | 160 | 4, 6, 9, 12 | 115 | 209 |
| 2 | 107 | 2, 4, 10, 13 | 403 | 710 |
| 3 | 1400 | 8, 12, 16 | 445 | 871 |
| 4 | 316 | 7, 13, 25, 37, 42 | 774 | 770 |
| 5 | 261 | 7, 17, 31, 36, 41 | 454 | 520 |
| 6 | 205 | 7, 17, 17, 31, 36, 41 | 540 | 1268 |
| 7 | 300 | 14, 31, 33, 38, 41 | 439 | 375 |
| 8 | 54 | 7, 22, 28, 31, 33 | 361 | 423 |
| 9 | 755 | 17, 24, 27, 28 | 663 | 425 |
| 10 | 845 | 17, 24, 27, 29 | 505 | 690 |
| 11 | 193 | 13, 23, 26, 28 | 395 | 371 |
| 12 | 125 | 13, 23, 26, 28 | 327 | 187 |
| 13 | 980 | 11, 21, 25, 26 | 569 | 76 |
| Average | 439 | - | 461 | 530 |
| s.d. | 418 | - | 162 | 326 |

Table 2. *Sperm cell concentrations measured for the rabbits in the control group, on which conventional end-to-end vasovasostomy was performed.*

| Number | Sperm cells per mL, preoperative (millions) | Postoperative semen analysis at weeks | Mean number of sperm cells per mL, post-operative (millions) | Final number of sperm cells per mL (millions) |
|-------------------------|---|---------------------------------------|--|---|
| End-to-end Group | | | | |
| 1 | 850 | 8, 14, 26, 38, 42 | 410 | 651 |
| 2 | 760 | 8, 14, 26, 38, 42, 44 | 300 | 233 |
| 3 | 324 | 7, 13, 25, 37, 41 | 312 | 360 |
| 4 | 785 | 7, 13, 26, 37, 42 | 651 | 960 |
| 5 | 414 | 7, 23, 37, 42, 47 | 531 | 258 |
| 6 | 625 | 7, 13, 25, 37 | 570 | 570 |
| 7 | 766 | 13, 30, 37, 40 | 437 | 450 |
| 8 | 249 | 13, 31, 37, 40 | 380 | 439 |
| 9 | 889 | 16, 23, 26, 28 | 420 | 620 |
| 10 | 324 | 16, 23, 26, 28 | 641 | 520 |
| 11 | 477 | 15, 22, 26, 29, 30 | 441 | 1267 |
| 12 | 283 | 15, 25, 28, 30 | 270 | 215 |
| 13 | 325 | 15, 22, 28, 40 | 492 | 430 |
| Average | 544 | - | 450 | 536 |
| s.d. | 240 | - | 123 | 298 |

The mini-stent remained patent in all 13 cases (Table 1). There was generally a high concentration of living sperm cells in the semen samples which were taken prior to autopsy.

Preoperatively, the average sperm cell concentration in this group was 439 million / mL with

a very high spread (s.d. = 418 million / mL). Prior to autopsy, this average was 530 million / mL (s.d. = 326 million / mL). Using the Student's t-test (two-tailed distribution, paired), it followed that $p = 0.525$, i.e. the sperm counts in the two series are not significantly different. Histopathology of the explants showed that mini-stent is well-tolerated in the rabbit vas deferens. Signs of a mild inflammatory response were usually seen in the surrounding tissue. Most likely, this is a normal reaction to the presence of a foreign polymeric biomaterial. Remarkably, the epithelium that constitutes the highly curved lumen of the normal vas deferens, adapts to the presence of the mini-stent (Figure 2). None of the implants were surrounded by a fibrous capsule. In many cases, sperm cells were observed inside the lumen of the mini-stent (Figure 2d). Rabbit # 13 was matched with a female partner, in order to establish whether the mini-stent allows actual propagation. The female became pregnant, and gave birth to eight young rabbits after 4 weeks of pregnancy.

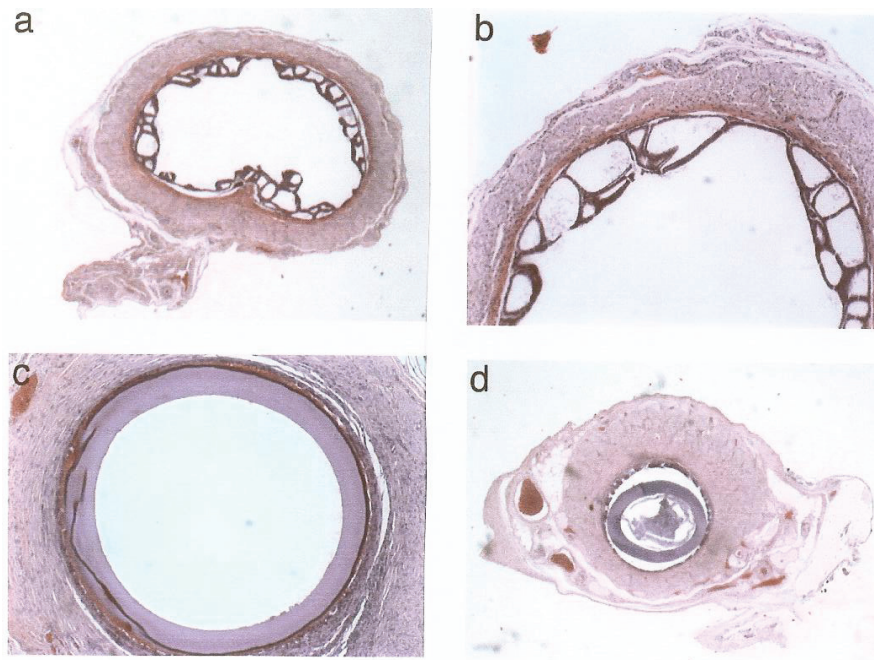


Fig 2 Histology of the vas deferens explants (light microscopy, staining with haematoxylin and eosin). **a, b**, Normal rabbit vas deferens (transverse view at two different enlargements), showing the pronounced curvature of the epithelium. All cell nuclei, especially those of the smooth muscle cells in the outer layers of the vas deferens, are clearly visible. **c**, Transverse view of a representative explant that contains a mini-stent. This section was cut in the central part; note that the epithelium lies as a circular band adjacent to the exterior surface of the mini-stent. **d**, View as in c, but now cut close to the proximal end. Here, the vas lumen is wider than the stent, thus leaving an interstitial space around the stent. Spermatozoa were observed in the lumen of the mini-stent, as well as in the interstitial space

The data in Table 2 show that all end-to-end operations were also successful. In this group, the average sperm cell concentration prior to the operation was 544 million / mL (s.d. = 241 million / mL). Prior to the different autopsies this average was 536 million / mL (s.d. = 298 million / mL). These data reflect that conventional end-to-end vasovasostomy is a well-established technique. The operation is associated with a very

high rate of success, provided that the skilled surgeon can work in a suitable infrastructure and with adequate equipment.

Both methods led to 100 % patency, and the ultimate sperm counts were generally very high. Using the Student's t-test (two-tailed distribution, paired) to compare the arrays of sperm counts (prior to autopsy) for two groups, a p-value of 0.961 was found. This indicates that the outcome of both groups is not statistically different at all.

It was experienced that vasovasostomy with use of the mini-stent was faster and easier to perform. The data in Table 3 show that the bilateral operation is accelerated by approximately 30 min, due to the use of the mini-stent. For the mini-stent group, an average operation time of 98 min was found (s.d. = 16 min). For the end-to-end group, this average was 132 min (s.d. = 19 min). Based on the Student's t-test (two-tailed distribution, paired), it can be concluded that the operation times for the two groups are statistically different ($p < 0.0005$).

Table 3. Operation times measured during the vasovasostomy operations of this study.

| End-to-end group | | Mini-stent group | |
|-------------------------|-------------------------|-------------------------|-------------------------|
| Rabbit number | Operation time (min) | Rabbit number | Operation time (min) |
| 1 | 142 | 7 | 98 |
| 2 | 148 | 8 | 92 |
| 3 | 131 | 9 | 110 |
| 10 | 168 | 11 | 111 |
| 13 | 123 | 12 | 62 |
| 14 | 131 | 15 | 111 |
| 16 | 142 | 17 | 75 |
| 21 | 139 | 18 | 83 |
| 23 | 111 | 25 | 105 |
| 24 | 99 | 26 | 113 |
| 29 | 121 | 27 | 98 |
| 30 | 149 | 28 | 107 |
| 31 | 112 | 32 | 109 |
| | | | |
| Average | 132 | - | 98 |
| s.d. | 19 | - | 16 |

The patency rate for microsurgical vasovasostomy in humans is approximately 85-90 %^{4,13,14}. Most probably, the higher patency rates in our model can be ascribed to the fact that the rejoining of the vas deferens was performed immediately after dissectioning; the time interval between vasectomy and vasovasostomy in clinical practice is usually in the order of several years.

Recently, it has become clear that vasovasostomy is the therapy of choice for obstructive azoospermia after vasectomy¹⁵. Kolettis et al. showed that the cost per living birth after vasovasostomy is approximately 31,000 US \$, while the cost per living birth after epididymal sperm aspiration / intracytoplasmic sperm injection is around 51,000 US \$¹⁶. More recently, Heidenreich et al. also concluded that vasovasostomy is preferred over its alternatives^{17,18}. Our next step is to investigate the utility of the mini-stent in humans.

The two questions to be answered are, evidently:

1. Is implantation of the mini-stent in humans as successful as conventional vasovasostomy, in terms of short-term and long-term complication rates?
2. Is the use of the mini-stent cost-effective because of shorter operation time?

Moreover, the mini-stent may provide an alternative option in those cases where conventional vasovasostomy has failed, e.g. as a result of stricturing at the anastomosis.

The mini-stent may also offer new possibilities to execute vasovasostomies under less stringent circumstances (a microscope is not necessary), e.g. in clinics in developing countries.

Conclusion

This animal study indicates that the vasovasostomy operation can be simplified and accelerated by using a polymeric hollow mini-stent. From the perspective of biomaterials science, it is encouraging that the novel NVP-based hydrophilic biomaterial can, apparently, enable transport of spermatozoa, which are notoriously vulnerable, through the anastomosis.

References

1. Swingl P, Guess HA. Safety and effectiveness of vasectomy. *Fertil. Steril.* 2000; 73: 923-936.
2. Hendrix NW, Chauhan S, Morrison JC. Sterilisation and its consequences. *Obstet. Gynecol. Survey* 1999; 54: 766-777.
3. Cox B, Sneyd MJ, Paul D, Delahunt B, Skegg DCG. Vasec tomy and the risk of prostate cancer. *JAMA* 2002; 287: 3110-3115.
4. Holman CDJ, Wisniewski ZS, Semmens JB, Rouse IL, Bass AJ. Population-based outcomes after 28,246 in-hospital vasectomies and 1902 vasovasostomies in Western Australia. *Brit. J. Urol. Int.* 2000; 86: 1043-1049.
5. Silber SJ. Vasectomy reversal. *N. Engl. J. Med.* 1977, 296: 886-887.
6. Silber SJ. Perfect anatomical reconstruction of the vas deferens with a new microscopic surgical technique. *Fertil Steril.* 1977; 28: 72-77.
7. Fischer MA, Grantmyre JE. Comparison of modified one- and two-layer microsurgical vasovasostomy. *Br. J. Urol. Int.* 2000; 85: 1085 – 1088.
8. Seaman EK. The application of laser techniques to vasectomy reversal surgery. *J. Clin. Laser Med. Surg.* 1998; 16: 45-48.
9. Rothman I, Berger RE, Cummings P, Jessen J, Muller CH, Chapman W. Randomised clinical trial of an absorbable stent for vasectomy reversal. *J. Urol.* 1997; 157: 1697-1700.
10. Kao F, Manivannan G, Sawan, SP. UV curable bioadhesives: copolymers of N-vinylpyrrolidone. *J. Biomed. Mater. Res. (Applied Biomater.)* 1997; 34: 191-196.

11. Hanssen JHL, Wetzels GMR, Benzina A, van der Veen FH, Lindhout M, Koole LH. Metallic wires with an adherent lubricious and blood-compatible polymeric coating and their use in the manufacture of novel slippery-when-wet guidewires. *J. Biomed. Mater. Res. (Applied Biomater.)* 1999; 48: 820-828.
12. Peerlings CCL, Hanssen JHL, Bevers RTJ, Boelen EJH, Stelt BJ, Korthagen EJM, Koole LH. Heparin release from slippery-when-wet guidewires for intravascular use. *J. Biomed. Mater. Res. (Applied Biomater.)* 2002; in press.
13. Jokelainen OS, Rintala E, Koskimies AI, Ranniko S. Vasovasostomy – a 15-year experience. *Scand. J. Nephrol.* 2001; 35: 132-135.
14. Huang JC, Hsieh ML, Huang ST, Tsui KH, Lai RH, Chang PL. Microsurgical vasectomy reversal: ten years' experience in a single institute. *Chang Gung Med. J.* 2002; 25: 453-457.
15. Pavlovich CP, Schlegel PN. Fertility options after vasectomy: a cost-effectiveness analysis. *Fertil. Steril.* 1997; 67: 133-141.
16. Kolettis PN, Thomas AJ. Vasoepididymostomy for vasectomy reversal: a critical assessment in the era of intracytoplasmic sperm injection. *J. Urol.* 1997; 158: 467-470.
17. Heidenreich A, Altmann P, and Engelmann UH. Microsurgical vasovasostomy versus microsurgical sperm aspiration/testicular extraction of sperm combined with intracytoplasmic sperm injection. *Eur. Urol.* 2000; 37: 609-614.
18. Heidenreich A, Altmann P, Neubauer S, Engelmann UH. Die microchirurgische Vasovasostomie im Zeitalter der modernen Reproduktionsmedizin. *Urologe (A)* 2000; 39: 240-245.

Chapter 7

The use of a newly designed nonabsorbable polymeric stent in reconstructing the vas deferens: a feasibility study in New Zealand white rabbits

**H. J. E. J. Vrijhof^a, A. De Bruine^b, A. H. Zwinderman^c, A. A. B. Lycklama à Nijeholt^d,
L H. Koole^e**

Department of Urology, Catharina Hospital, Eindhoven, The Netherlands^a

Department of Pathology, University Hospital of Maastricht, Maastricht, The Netherlands^b

Department of Medical Statistics, University of Leiden, Leiden, The Netherlands^c

Department of Urology, Leiden University Medical Centre, Leiden, The Netherlands^d

Centre for Biomaterials Research, University of Maastricht, Maastricht, The Netherlands^e

Introduction

The mean operation time for a bilateral microscopical procedure is 2 hours and 30 minutes ¹.

It is generally accepted that the microscopical reconstruction leads to better patency- and pregnancy rates than the macroscopical procedure ²⁻⁴. We use a one-layer anastomosis because the duration of surgery would be considerably less than a two-layer anastomosis and according to several authors a two-layer anastomosis has little if any additional benefit over a one-layer anastomosis ^{5,6}.

Apart from the technical aspects of the procedure, obstruction interval between vasectomy and reversal, and the presence of antisperm antibodies, determine the patency and pregnancy rates ⁷⁻¹². Technical failure of human vas deferens reconstruction mainly occurs several weeks to months after surgery usually as a result of stricturing of the anastomosis. These strictures occur because of granuloma formation, and traction on or devascularization of the vas wall, which eventually leads to sperm leakage. Absorbable hollow stents have been used to simplify the procedure and prevent this sperm leakage. By preventing sperm extravasation, there is less perivasal inflammation, reducing secondary stricturing at the site of the anastomosis. Despite contradictory published results, absorbable stents might have the disadvantage of migrating easily and absorbing rapidly (10-14 days), leading to early denudation of the anastomosis, with possible stricturing. Non-absorbable hollow stents made of inert biomaterial, with a design that prevents migration, might improve patency rates by providing a permanent open lumen at the site of the anastomosis.

To reduce the operative duration and to improve patency rates, we developed an “easy to perform technique” with a newly-designed hollow nonabsorbable polymeric stent. This hydrophilic stent, with auto-dilating capacity, could help to prevent secondary stricturing of the

anastomotic area. The present randomized comparative study between stent and conventional microscopic reconstruction was designed to study the effects of both reconstructive techniques on the anastomosis area and semen quality, so the transected vas deferens was immediately repaired. This eliminated the influence of obstruction time resulting from vasectomy. Thus the purpose of this study was to investigate the use of a newly designed nonabsorbable polymeric stent in the reconstruction of the vas deferens, comparing it to the conventional microscopic reconstruction in a randomized study in rabbits.

Materials and methods

New Zealand White rabbits (32) were used, the experiments being conducted according to the Principles of Laboratory Animals Care (prepared by the National Institutes of Health, NIH Pub. No. 85-23 rev. 1995). Anaesthesia was induced by an intramuscular injection with ketamine 0.5ml/kg and xylazine 0.5 ml/kg, and maintained by an intravenous mixture of ketamine/xylazine (2:1, 0.2ml/30min) during surgery. The rabbit was placed supine and a transverse skin incision made over both spermatic funiculi. The spermatic internal fascia was opened and the vas deferens, lying loose and next to the funiculus, was easily luxated, leaving the scrotal contents *in situ*. The vas deferens was cut transversely and reconstructed immediately. The rabbits were randomized either to microscopic reconstruction with four or five one-layer 8/0 nonabsorbable polypropylene sutures (Prolene, Ethicon Inc., Somerville, NJ) or had stents placed bilaterally, after which both ends of the vas deferens were approximated with three 8/0 Prolene sutures, overlying the stent. Water tightness was checked in both procedures by milking sufficient epididymal contents towards the anastomosis area. The vas deferens was repositioned, and the fascia and overlying skin closed with 4/0 synthetic

absorbable polyglactin suture. After surgery the rabbits received narcotic analgesia (temgesic 0.1 ml/kg) for up to 48 hours.

Semen was obtained before surgery to establish the presence of sperm, and at regular intervals (2-47 weeks) after surgery; at least four semen samples were taken from each rabbit. The semen was collected with an artificial vagina system normally used in agricultural artificial insemination for rabbits. The sperm characteristics consisted of total sperm count, mean motility and progressive motile sperm density (PMSD). After the final semen analysis, the rabbits were killed and patency assessed histologically at the site of the anastomosis.

In the dry state the stent has some stiffness that facilitates its placement. Shortly after introduction, the stent starts to absorb seminal and serous fluids, which alter the mechanical characteristics and make the stent more flexible and elastic. The construction material of the stent was N-vinylpyrrolidone and n-butylmethacrylate, and the bifunctional cross-linking agent was tetraethyleneglycol dimethacrylate. These reactive substances were polymerised using 2,2'-azobisisobutyronitrile as the radical initiator. Thus the stent comprises a hydrophilic biocompatible material containing a hydrophilic and a hydrophobic component, at a molar ratio of 2:3. The hydrophilic component provides the rubbery characteristics of the material after insertion into the vas deferens. To facilitate the rejoining of the two loose ends of the vas deferens over the stent, a specific shape of the stent was developed. The stent is a hollow tube which is conical at both ends, facilitating insertion in the vas deferens ends. The total length of the stent is 8.2mm. The outside diameter, at the site of the central ridge is 1.6mm and the internal diameter is 0.6mm. This ridge, in the middle of the stent, prevents the stent from migrating from its original anastomotic area (fig. 1).

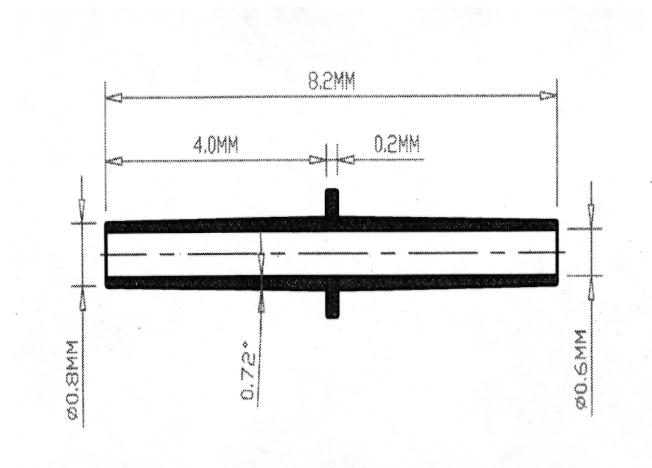
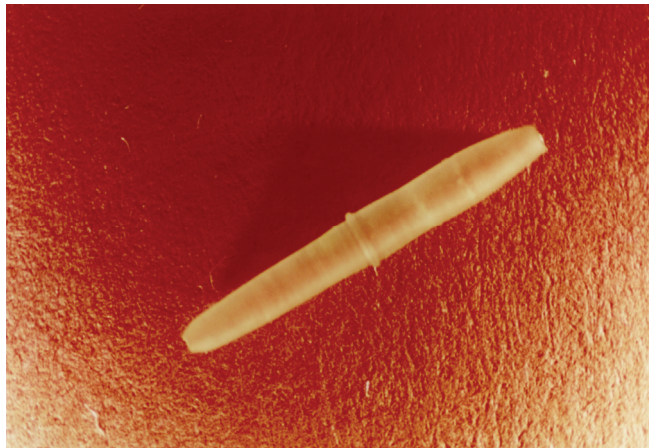


Fig 1. Configuration and dimensions of the polymeric stent

Results

Four rabbits had a vasectomy to evaluate the mean time needed to gain azoospermia in case a reconstruction would lead to a total obstruction. Before sterilization, semen was analysed to establish the presence of sperm in all four rabbits. The semen analysis was repeated after 6-7 weeks and 3 months; all four rabbits were azoospermic at the first semen control and remained azoospermic during follow-up; the rabbits were then killed.

In all, 28 rabbits were used to compare the conventional microscopic reconstructive procedure (“conventional group”) and vasovasostomy using the biocompatible hollow stent (“stent group”). Two rabbits died soon after surgery (pneumonia and gastric hair ball), one in the stent group and the other in the conventional group, so only 26 rabbits (13 stents and 13 conventional) were evaluable. The 26 rabbits provided 141 semen specimens; 26 before surgery and 115 after surgery. To establish whether the polymeric stent allows actual propagation, one rabbit was matched with a female, and after 4 weeks of pregnancy, eight healthy young rabbits were born.

Total sperm count (or concentration):

The total sperm counts before surgery (table1) did not differ significantly between groups (P=0.08, Mann-Whitney U-test). After surgery, there was a significant difference between conventional and stented rabbits in the increased concentrations during the follow-up (P=0.050, linear regression analysis with random effects); the total sperm count increased in both treatment groups, but more in the stent group (fig.2). The mean sperm counts during follow-up did not differ significantly (table 1).

Table1. Sperm analyses before and after conventional one-layer microscopic reconstructions and stented reconstructions of the vas deferens in rabbits

| Variable | Stent | Conventional |
|---------------------------------|------------------------------|------------------------------|
| <i>Mean (median,range) [SD]</i> | | |
| Before surgery | | |
| Total sperm count, millions/ml | 439 (261, 54-1400) [418] | 544 (477,249-88900 [240.6] |
| Motility % | 75 (80, 50-950 [12.9] | 68 (75, 20-900 [18.4] |
| PMSD, millions/ml | 164 (81, 0-560) [193.4] | 212 (164, 0-556) [180.7] |
| After surgery | | |
| Total sperm count, millions/ml | 459 (445, 114.8-776) [163.9] | 450 (437, 270.3-651) [122.8] |
| Motility % | 25 (32, 0.2-51) [18.6] | 40 (43, 2.7-70) [17.9] |
| PMSD, millions/ml | 45 (43, 0.2-128) [46.2] | 78 (71, 0.1-175) [50.6] |

Motility:

The motility measurements before surgery (table 1) did not differ significantly between both groups ($P=0.29$, Mann-Whitney *U*- test). After surgery (table 1), motility decreased during the first 0-12 weeks in both groups ($P<0.001$), but increased significantly thereafter ($P=0.002$). There was no significant difference between groups (fig.2B) in this decrease or increase in the course of motility ($P=0.11$, non-linear regression with random effects).

Progressive motile sperm density (PMSD):

The PMSD before surgery (table 1) did not differ significantly between groups ($p=0.45$, Mann-Whitney *U*-test); after surgery, the PMSD decreased initially ($p=0.002$) followed by a slight but insignificant increase ($p=0.061$). There was no significant difference between conventional and stented rabbits (fig. 2C) in this decrease/increase ($p=0.71$, non-linear regression with random effects)

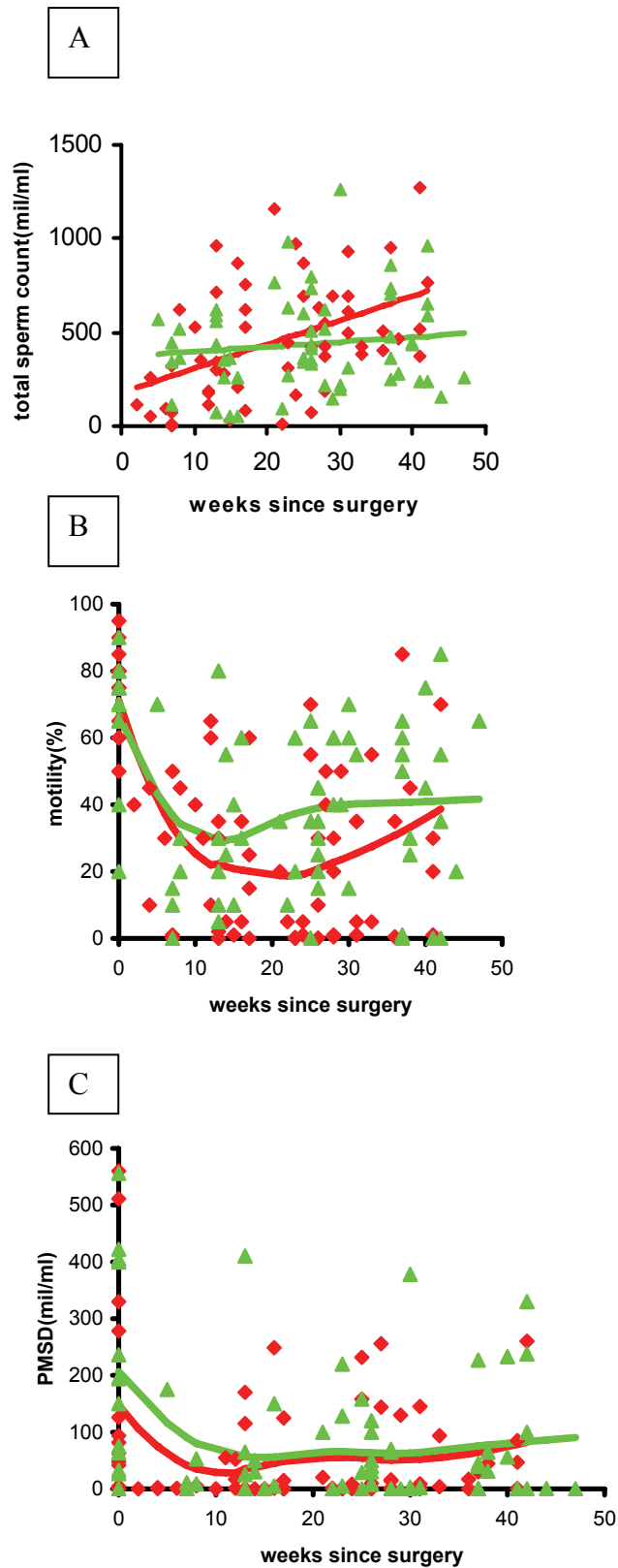


Fig 2. The available **A**, sperm counts; **B**, motility results; and **C**, PMSD results after surgery. The red (stented group) and green (conventional group) lines are regression lines with follow-up time, estimated using random-effect linear regression analysis to account for the correlation between repeated measures in the same animal. In **B** and **C** spline functions were used to estimate the regression lines nonparametrically.

Histological features:

All conventional and stented reconstructed vasovasostomies, were evaluated histologically. Histological sections in the stented group were taken at a mean (range) of 41 (39-44) weeks after the initial operation, vs 42 (40-47) weeks in the conventional group.

In five of 13 conventional reconstructed vasa deferentia there was partial obstruction (>50% narrowing of the original lumen diameter) but with sufficient patency. In the stented group there was no partial or complete obstruction. In all 13 stented rabbits there was flattening and atrophic changes of the epithelium of the vas deferens wall, and eosinophilic inflammatory reaction (fig.3). The atrophy was probably a result of the pressure of the stent wall against the vas deferens wall. All the proximal and distal transverse luminal sections contained sperm cells, showing good patency.

Operation time:

The mean (range) operative duration was 132 (99-168) min in the conventional and 98 (62-113) min in the stented group ($p<0.001$), giving a mean reduction of 34 min.

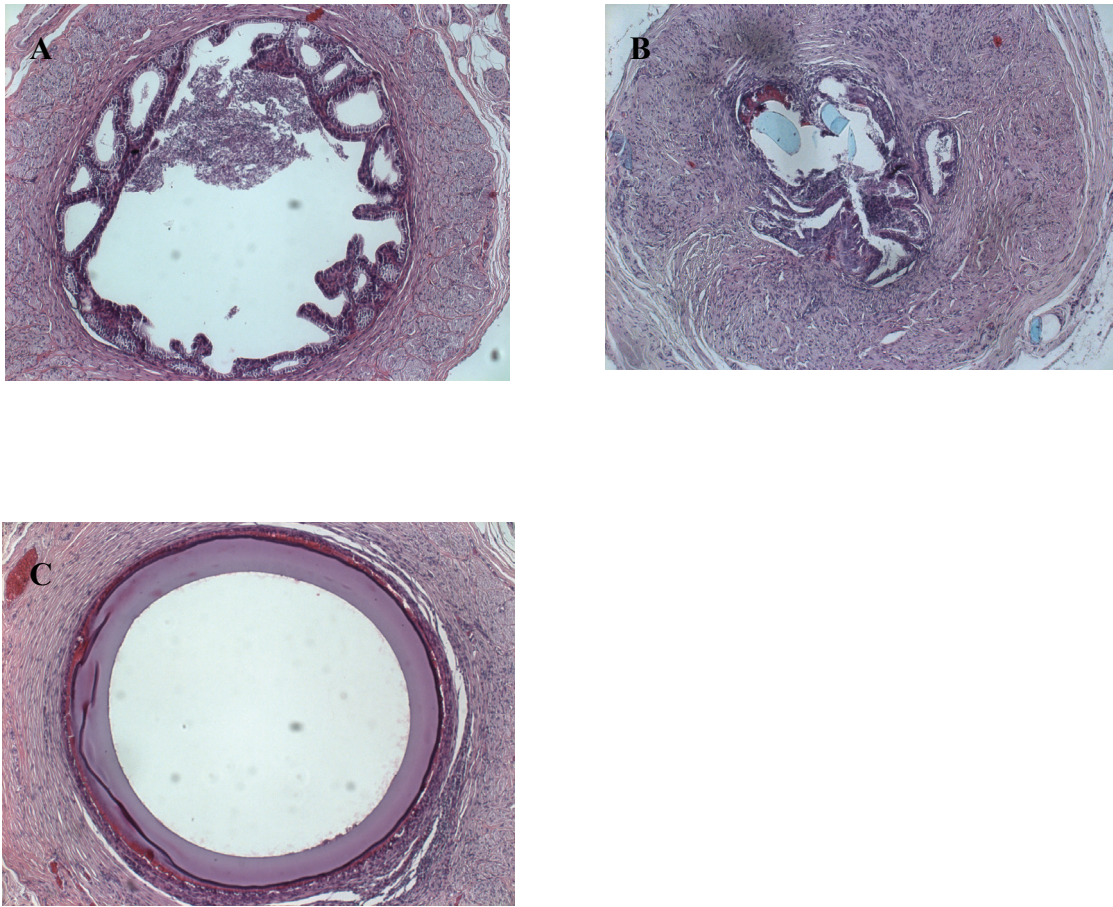


Fig 3. Hematoxylin and eosin-stained transverse sections of rabbit vas deferens in various presentations. **A**, section of a normal vas deferens with wide lumen, containing sperm in the centre. **B**, severe stenosis after a conventional (end-to-end) sutured microscopic reconstruction, note 8/0 Prolene sutures running through anastomosis (light blue remnants). **C**, stent in situ, note the epithelial flattening

Discussion

Temporary exteriorized stents

Most previous studies on exteriorized stents used a temporary stent that was removed after several days or weeks after surgery¹³⁻¹⁵. Temporary stented reconstructions have disadvantages: because the stents are exteriorized they provide a greater risk for sperm leakage and infection; this could lead to sperm granuloma, antisperm antibody formation, vasitis and loss of patency from scar tissue formation.

Absorbable intravasal stents

In the early 1980s more studies were reported using absorbable material as an intravasal stent. Redman¹⁶ used an intraluminal stent of catgut in 20 patients and achieved an overall pregnancy rate of 65%; the successful group included three patients who had a vasectomy >10 years earlier. Montie et. al.¹⁷ reported a study in a dog model; one group had a conventional sutured vasovasostomy with 6/0 silk and another three groups were reconstructed with intraluminal stents using either 3/0 polyglycolic acid or 3/0 chromic catgut, using different types of approximation sutures. The best results were with the chromic catgut stents, and 6/0 catgut sutures for the anastomosis. Silk sutures resulted in severe granuloma formation and should therefore be rejected as a suturing material.

Absorbable hollow stents were created to simplify the procedure and reduce operating time; these created perfect alignment of the vas deferens ends, and after 2-4 weeks most stents were dissolved. Nuwayser et.al.¹⁸ were amongst the first to develop such a stent; they used starch, collagen and polyester as stent materials. The best results were seen in the polyester group, with patency in all 19 samples and rapid absorption at 10-14 days. The histological assessment showed excellent healing at the anastomotic site, with the presence of normal epithelium and

no stricturing. There was plentiful sperm in the lumen, with normal sperm morphology. Flam et.al.¹ used an absorbable hollow polyglycolic acid stent, and described advantages of ease of anastomosis, reduction of perivascular inflammation as a result of minimal extravasation of sperm, maintenance of luminal patency, and satisfactory approximation of the vas deferens ends after placing of the stent. Remarkably, they reported more perivascular inflammation at the anastomotic site of an unstented control group. This sperm leakage and inflammatory reaction could increase the risk of late scarring. Hollow, biflanged, hydrolysable, self-retaining stents of polyglycolic acid were used by Berger et al.¹⁹ in a randomized prospective comparative study between a stented and a modified two-layer vasovasostomy group in rats and dogs. The outcome suggested better patency rates in the stented group (80% vs 20%).

By contrast Rothman et.al.²⁰ in 1997 reported an extensive prospective randomized study comparing a microscopic two-layer vasovasostomy with an absorbable polyglycolic acid stent in 116 men who had a vasectomy reversal. In all, 64 men had a stented reconstruction and 52 were repaired with a two-layer microscopic reconstruction. Paternity rates were significantly better in the unstented group. A bias in this study was the incomplete follow-up; in many cases only one semen sample was investigated per subject after surgery, and this undermines a well documented comparison of patency rate. Nevertheless, information (by letter, telephone or outpatients visits) on paternity was available for 95% of patients, showing significantly better results in the non-stented group (51 vs 22%).

Non-absorbable stent

Because of these conflicting results with absorbable hollow stents, we decided to assess the present stent, a permanent, non-absorbable inert polymeric stent made of biomaterials with a different configuration. We considered that the non-absorbable property of this stent and the

inertness of the material would provide a permanent open lumen of the vas deferens at the site of the anastomosis. By contrast with previously discussed animal studies, we decided to provide a longer follow-up with more frequent semenanalyses. In the present study there were no significant differences in the outcome of the total sperm count, motility and PMSD between groups. The present study is the first to use a non-absorbable polymeric hollow stent, with results similar to the one-layer vasovasostomy technique. There was no late stricturing in the stented group; the benefit of this is stressed by Carbone et al.²¹ and Belker²², who described the adverse effect of partial obstruction on the final outcome of a vasectomy reversal. In humans, the procedure should be easy and can be done by a surgeon not necessarily skilled in microscopy. Further investigations will be conducted in men to support the present findings with this polymeric stent.

References

1. Flam AT, Roth RA, Silverman ML, Gagne GR. Experimental study of hollow, absorbable polyglycolic acid tube as stent for vasovasostomy. *Urology* 1989; 33: 490-49
2. Donovan Jr JF. Microscopic vasovasostomy: current practice and future trends. *Microsurgery* 1995; 16: 325-332.
3. Cos LR, Valvo JR, Davis RS, Cockett ATK. Vasovasostomy, current state of the art. *Urology* 1983; 22: 567-575
4. Kabalin JN and Kessler R. Macroscopic vasovasostomy re-examined. *Steril Fertil* 1991; 36:135-138
5. Fuse H, Kimura H, Katayama T. Modified one-layer microsurgical vasovasostomy in vasectomized patients. *Int Uro Nephrol* 1995; 27: 451-456
6. Fischer MA, Grantmyre JE. Comparison of a modified one- and two-layer microsurgical vasovasostomy. *Br J Urol* 2000; 85: 1085-1088
7. Flickinger CJ, Vagnetti M, Howards SS, Herr JC. Antisperm autoantibody response is reduced by early repair of a severed vas deferens in the juvenile rat. *Fertil Steril* 2000; 73:229-237
8. Aitken RJ, Parslow JM, Hargreave TB, Hendry WF. Influence of antisperm antibodies on human sperm function. *Br J Urol* 1988; 62: 367-373
9. Silber SJ. Pregnancy after vasovasostomy for vasectomy reversal: a study of factors affecting long-term return of fertility in 282 patients followed for 10 years. *Human Reprod* 1989; 4: 318-322
10. Meinertz H, Linnet L, Andersen PL, Hjort T. Antisperm antibodies and fertility after vasovasostomy a follow-up of 216 men. *Fertil Steril* 1990; 54: 315-321

11. Vrijhof HJ, Delaere KP. Vasovasostomy results in 66 patients related to obstructive intervals and serum agglutinin titres. *Urol Int* 1994; 53: 143-146
12. Belker AM, Thomas Jr AJ, Fuchs EF, Konnak JW, Sharlip ID. Results of 1469 microsurgical vasectomy reversals by the vasovasostomy study group. *J Urol* 1991; 145: 505-511
13. Urry RL, Thompson J, Cockett ATK. Vasectomy and vasovasostomy.II. A comparison of two methods of vasovasostomy: silastic versus chromic stents. *Fertil. Steril* 1976; 27: 945-950
14. Lawrence EL, Witherington R. Splinted vasovasostomy, comparison of polyglycolic acid and polypropylene sutures. *Urology* 1978; 11: 260-265
15. Shessel FS, Lynne CM, Politano VA. Use of exteriorized stents in vasvasostomy. *Urology* 1981; 17: 163-165
16. Redman JF. Clinical experience with vasovasostomy utilizing absorbable intravasal stent. *Urology* 1982; 20: 59-61
17. Montie JE, Stewart BH, Levin HS. Intravasal stents in canine subjects. *Fertil Steril* 1973, 24: 877-883
18. Nuwayser ES, Wu TC, Hotchkiss RS, Farcon EE, Hulka JJ, Mohr K, Poddar A. An absorbable artificial vas deferens for vasovasostomy. *Trans Am Soc Artif Int Organs* 1975; 21: 523-530
19. Berger RE, Jessen JW, Patton DL, Bardin ED, Burns MW, Chapman WH. Studies of polyglycolic acid hollow self retaining vasal stent in vasovasostomy. *Fertil Steril* 1989;51: 504-508
20. Rothman I, Berger RE, Cummings P, Jessen J, Muller CH, Chapman W. Randomized clinical trial of an absorbable stent for vasectomy reversal . *J Urol* 1997; 157: 1697-1700

21. Carbone Jr DJ, Shah A, Thomas AJ, Agarwal A. Partial obstruction, not antisperm antibodies, causing infertility after vasovasostomy. J Urol 1998; 159: 827-830
22. Belker AM. Editorial: evaluation of partial anastomotic obstruction after vasovasostomy and predictors of success after vasoepididymostomy. J Urol 1998; 159: 835

Chapter 8

New nonabsorbable stent versus a microsurgical procedure for vasectomy reversal: evaluating tissue reactions at the anastomosis in rabbits.

Eric J. Vrijhof ^a, Adriaan de Bruine^b, Aeilko Zwinderman ^c, August. A.B. Lycklama à Nijeholt^d, and Leo Koole ^e

Department of Urology, Catharina Hospital, Eindhoven, The Netherlands ^a

Department of Pathology, University Hospital of Maastricht, Maastricht, The Netherlands ^b

Department of Medical Statistics, University of Leiden, Leiden, The Netherlands ^c

Department of Urology, Leiden University Medical Centre, Leiden, The Netherlands ^d

Centre for Biomaterials Research, University of Maastricht, Maastricht, The Netherlands ^e

Introduction

Several factors influence the clinical result of a vasovasostomy, including surgical technique, antisperm-antibodies, long-term high intravasal and epididymal pressure after vasectomy, and the obstruction interval between the vasectomy and reversal ¹⁻³.

Moreover, complications can occur locally in the anastomosis area, such as the development of scar tissue and granuloma formation. These reactions are mostly due to traction and/or devascularization of the vas wall, eventually leading to sperm leakage which compromises the anastomosis ⁴. Several weeks to months after the reversal procedure, stricturing in the anastomosis area can develop, resulting in a partial or complete stenosis. Initial patency will be compromised due to this stricturing. Several studies indicate that a large proportion of vasovasostomy failures are the result of inadequate sperm passage and/or testicular/epididymal tissue damage. Most of the sperm in the ejaculate passes from the epididymis to the vesicles at the time of the intercourse ⁵. As a result, a poor anastomosis will have a deleterious effect on fertility ^{4,6}. Because of this risk of obstruction, but also because of the time required for a microsurgical anastomosis, we started to develop a technique with a hollow non-absorbable polymeric stent.

The use of this hydrophilic stent, with autodilating capacity, could theoretically help to prevent the secondary stricturing of the anastomosis area. It was assumed that narrowing of the anastomosis by fibrosis would be prevented because of the solid structure of the stent. Local sperm leakage could be prevented by the use of an intraluminal stent covering the anastomosis. A very important issue in favor of using a stent is proven inertness of the biomaterial stent, limiting inflammatory reaction in the vas wall that would probably impair patency. Because of the permanent position of the implanted stent, any intraluminal migration would expose the anastomotic site leading to possible secondary stricturing. To prevent this,

the stent was constructed with a central ridge to avoid migration.

The aim of this study was to examine the histological consequences of a stented vasovasostomy at the site of the anastomosis. Because we performed an immediate reconstruction after transection, we did not examine the effect of a prolonged obstruction on the tissue of testes and epididymi. We studied the testicular and epididymal tissues for possible tissue changes in those rabbits with partially or fully obstructed vas deferens at the time that they were sacrificed either in the stented group or in the conventional group.

The microscopical reconstruction was performed using a single layer anastomosis so that operating time would be reduced considerably compared to a two-layer anastomosis. The beneficial effect of a two-layer anastomosis over a one-layer anastomosis is still under discussion^{7,8}. Finally, the histologic results were correlated with the clinical semen outcomes.

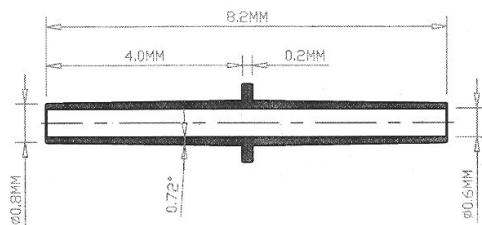

Materials and Methods

We used a total of 30 New Zealand White rabbits for this study. All animal experiments were conducted according to the Principles of Laboratory Animals Care (prepared by the National Institutes of Health, NIH Pub. No. 85-23 rev. 1995). These rabbits (age ranging between 1/2 to 1 year) were chosen because of their easily accessible vas deferens, situated in a stretched prepubic area. Proven patency was a condition for being admitted to this study.

Two rabbits acted as normal controls and 28 rabbits were included in a randomized comparative study between the conventional microsurgical procedure and the vasovasostomy using the newly developed biocompatible hollow stent. During follow-up two rabbits died soon after the operation; one because of pneumonia and the other of a gastric hair ball. Eventually, 26 rabbits (13 stents and 13 microscopically sutured) were available for examination.

The stent itself consists of biocompatible material and has several physical characteristics to simplify the insertion into the vas. In the dry state the stent has certain stiffness and is conically shaped at both ends to facilitate the introduction. After 1 to 2 minutes it starts to absorb seminal en serous fluids. This initiates swelling of the stent which then becomes more flexible. There is a transverse ridge in the middle part of the stent to prevent the stent from migrating from its original anastomosis area (fig 1).

Fig 1. Configurations and measurements of the polymeric stent.



The stent was constructed of n-vinylpyrrolidone, n-butylmethacrylate, and the bifunctional cross-linking agent tetraethyleneglycol dimethacrylate. These reactive substances were polymerized using 2,2'-azobisisobutyronitrile (AIBN) as the radical initiator. The stent thus comprises a hydrophilic and a hydrophobic component in a 2:3 molar ratio. The hydrophilic component of biocompatible material provides the rubbery characteristics of the material after insertion into the vas deferens.

Ketamine 0.5 mL/kg and xylazine 0.5 mL/kg were injected IM to induce anaesthesia; anaesthesia was maintained by a mixture of ketamine/xylazine (2:1) 0.2 mL/30 min. IV throughout the operation. The rabbit was placed in a supine position and a transverse skin incision was made over both spermatic funiculi. The spermatic internal fascia was opened and the vas deferens, lying loose and next to the funiculus, was easily exposed leaving the scrotal contents in situ. The vas was cut transversally and reconstructed immediately. The animals were randomized either for bilateral microscopical reconstruction with 4 to 5 one-layer prolene 8-0 sutures or for placement of stents bilaterally. Both vas ends were approximated with three 8-0 prolene sutures overlying the stent. The vas was repositioned underneath the funiculus and the spermatic internal fascia and overlying skin were closed with 4.0 vicryl. During the postoperative period the animals obtained buprenorfin 0.1 mL/kg IM for a maximum of 48 hours.

Semen for semen analysis was obtained 3-4 days before the operation. After the operation at least 4 to 5 semen samples were taken per animal with time intervals of 7-10 weeks. For collection of semen, an artificial vagina system was used, which is normally applied in agricultural artificial insemination stations for rabbits. Sperm parameters that were collected were: total sperm count (mil/ml), average motility (%) and progressive motile sperm density (PMSD; mil/ml).

Histological examinations were performed on the rabbits, including the two normal rabbits that acted as normal controls. The autopsies were performed shortly after taking the final semen sample. Histological sections in the stented group were taken at an average of 41 weeks (39-44) after the initial operation versus 42 weeks (40-47) in the conventional group. The vasa deferentia, the testes, and the epididymi were excised and fixed in neutral buffered 4% formalin and paraffin embedded for further sectioning. Multiple tissue segments of each vas deferens were taken: one from the anastomosis area (stent or conventional) and four segments immediately proximal and distal to the anastomosis. Two to three samples were taken from the testes and epididymi for evaluation of histological changes after both procedures. All samples were cut at 4µm thickness, and slides were stained with hemotoxylin/eosin and were microscopically examined by the same pathologist.

Results

Morphologic findings in stented rabbits:

During excision of the anastomotic areas, for further histological examination, minimal adhesions of the anastomosis site were seen with its surrounding tissue. In one case there was a migration of the stent. The stent was found 2 cm more distally and proved to be patent. Microscopy showed that the stented rabbits all had patent vasa on either side of the implant, without any signs of complete or partial stenosis. After extensive examination two groups of stented animals could be distinguished (fig 2);

- The first group of 11 stented rabbits showed a very similar histological pattern among all cases at the site of the stent. A minor subepithelial inflammatory reaction within the vas wall, adjacent to the stent, was noted. This reaction consisted mainly of

eosinophilic granulocytes, incidental macrophages, and in one case histiocytes. The mainly eosinophilic infiltrate did not appear to lead to destruction of the stent or invasion of the vas wall. The testes and epididymi appeared to be normal and all the transverse sections through the stent demonstrated patency.

- The second group consisted of two rabbits. One had a major transmural histiocytic reaction to the stent and the other presented with severe eosinophilic infiltration involving the epithelium, resulting in epithelial destruction and atrophy. In both cases the testes and epididymi appeared to be normal.

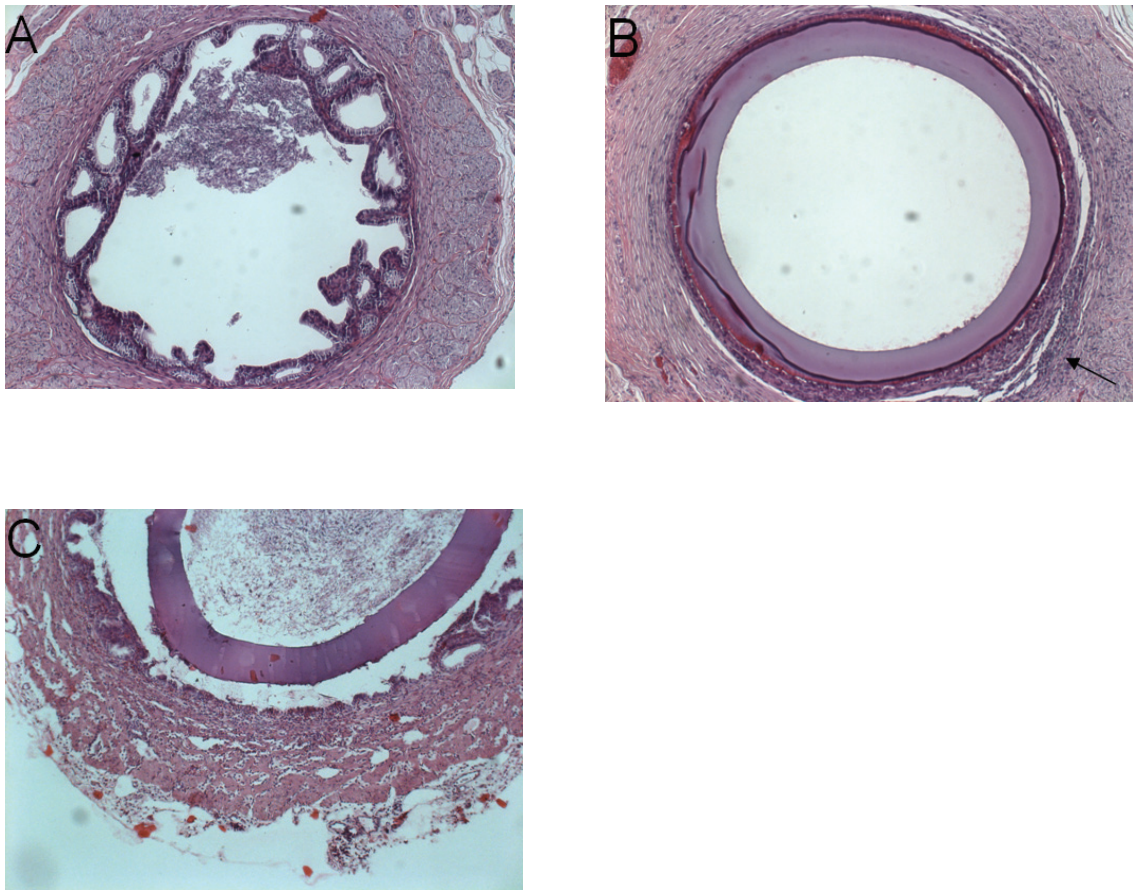


Fig 2. Hematoxylin & eosin stained sections through vas deferens of sten- reconstructed animals at the anastomosis area.

- A:** transverse section through normal vas deferens away from the stent area.
B: stent lying adjacent to the vas wall with epithelial flattening and the presence of paraluminal eosinophilic reaction (arrow).
C: detailed section of a severe histiocytic transmural reaction.

Morphologic findings in the microscopically sutured rabbits:

Surgical excision of the anastomosis area subjectively revealed more adhesions compared to the stent group. All the anastomoses were patent, as proven by the finding that all transverse sections of the vas distal to the anastomosis contained sperm cells. Remarkable was the fairly large number of partial obstructions in this group. We divided these rabbits in two groups (fig 3).

- The first group consisted of eight rabbits that presented with normal anastomotic site and normal vas diameters. Histologically, complete recovery of the epithelial layers was found without stricturing of the anastomosis. Except for one rabbit, who developed chronic epididymitis with lymphocytic infiltrates, all the testes and epididymi tissue segments appeared normal with no distension of the tubules compared to normal controls. The tubules were fully filled with sperm.
- The second group of five rabbits presented with partial obstruction. Transmural infiltration of lymphocytes and histiocytes was seen, resulting in fibrotic reaction with collagen dispositions and stricturing. Severe foreign body reactions were seen at the site of the sutures. Despite these partial obstructions, the parenchyma of testes and epididymi appeared normal.

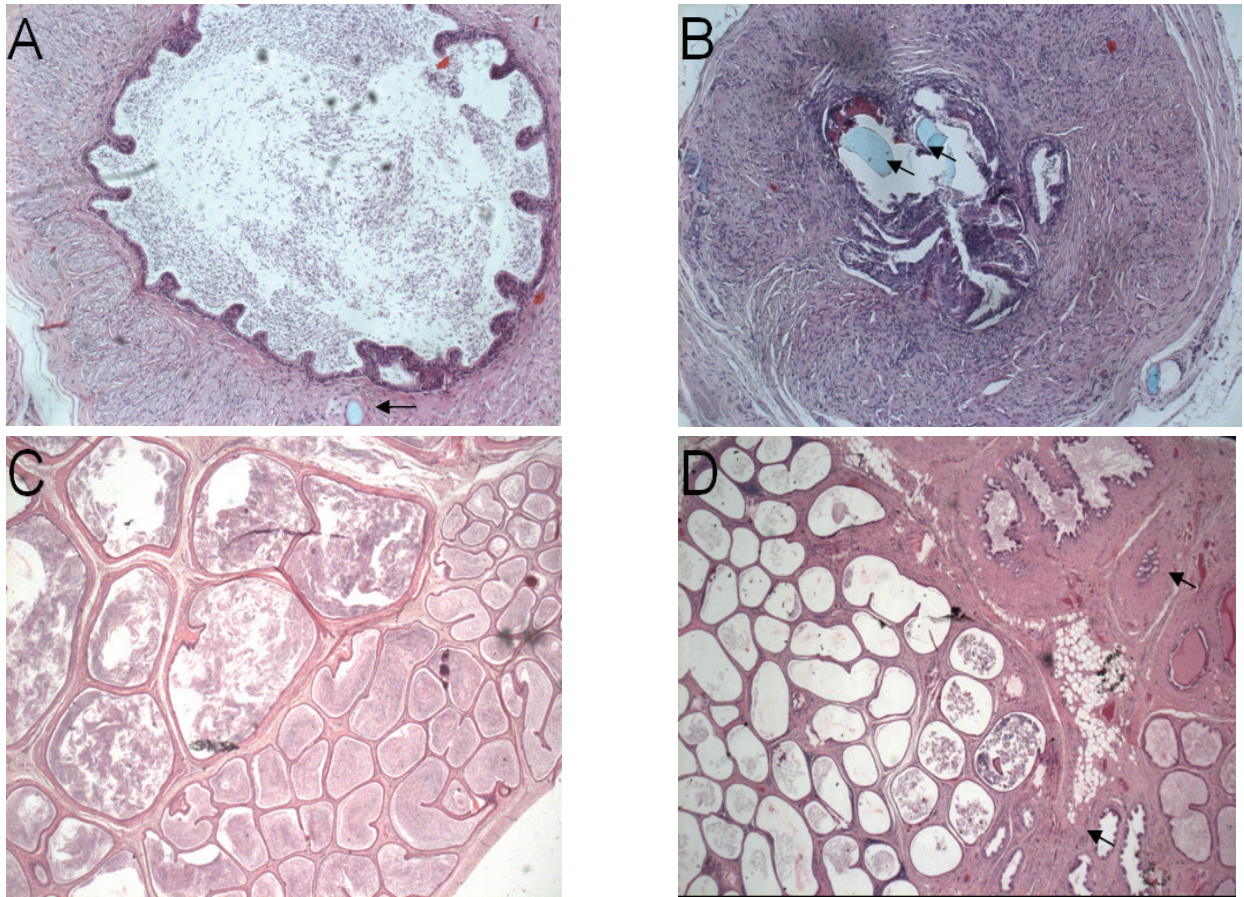


Fig 3. Various histologic sections of vas deferens and epididymis in conventionally microscopically reconstructed animals using 8.0 prolene sutures.

- A: normal anastomoses with no stricturing and complete recovery of epithelial layer; remnants of prolene sutures are seen (arrow).*
- B: severe stenosis with paraluminal fibrotic reactions and intraluminal remnants of prolene sutures (arrows).*
- C: normal epididymis, tubules filled with sperm cells.*
- D: chronic epididymitis with histiocytes, lymphocytes and edema showing thickening of intertubular stromal spaces (arrows).*

Morphologic findings in relation to clinical outcome after vasovasostomy:

All the vasa were patent in both the stent group and the conventional group. All the animals underwent a preoperative semen analysis to prove their patency. The 26 animals treated, provided 141 semen specimens (26 presurgery and 115 postsurgery). The specimens were taken at regular intervals from 2 weeks to 47 weeks after surgery. Mean, median, minimum, maximum and standard deviation levels were measured for total sperm count, motility and progressive motile sperm density (PMSD) in both groups. Following surgery, there was a statistically significant difference between conventionally and stent-treated animals with respect to the total sperm count ($p=0.050$, linear regression analysis with random effects). The average total sperm count or concentration increased in both groups, but more so in the stent group. When calculating the average postsurgery motility per animal, we initially observed a decrease in motility which later on improved. Overall no statistical significant difference in motility between the conventionally and stent-treated animals was noted ($p=0.11$, non-linear regression with random effects). This same course was seen for the average PMSD concentrations, again showing no statistical differences between the two groups ($p=0.71$, non-linear regression with random effects).

Discussion

Influence of partial or total anastomotic obstruction after vasectomy reversal.

Surgeons are aware of the fact that secondary stricturing of the anastomosis is detrimental for patency rates. In searching Pubmed for this subject (1980-2004) only a limited number of articles are found discussing this problem. Carbone et al ⁴ described the role of partial obstruction causing infertility after vasovasostomy. It is a general believe that persistent infertility after vasectomy reversal is highly attributed to the presence of antisperm antibodies. In this study 20 patients obtained a vasectomy reversal, 14 of them were believed to have a partial obstruction based on mild to moderate epididymal fullness by palpation. All the patients had a significant binding of antisperm antibodies to the sperm surface. These 14 patients underwent a repeat vasectomy reversal and revealed markedly improved semen motility (mean of 4.4% to a mean of 52.3%). Sperm concentration levels increased from 17.1 to 35.8x10⁶/ml. The overall antisperm antibodies binding did not change after re-vasovasostomy. These results led to the conclusion that the poor sperm quality after the first vasectomy reversal was mainly the result of partial obstruction and not the mere presence of antisperm antibodies. Royle and Hendry ⁹ explored the scrota of 32 men who had a failed vasectomy reversal resulting in azoospermia or extreme oligozoospermia. Of 23 men who had azoospermia 12 patients had a completely blocked anastomosis. After repeat vasovasostomy normal sperm counts were produced in 10 of the 12 patients.

The importance of total or partial obstruction after vasectomy reversal was also highlighted in several other studies. The main message of all these studies was that microsurgical vas reconstruction following failed vasectomy reversal, due to total or partial obstruction, is associated with high patency and pregnancy rate at short-term follow-up ¹⁰⁻¹³.

Prevention of total or partial obstruction of the anastomosis is crucial for good patency

rates. Therefore it is of extreme importance that the first reconstruction is technically successful. Stricture of the anastomosis is very often technically difficult to repair frequently forcing a surgeon to perform vasoepididymostomy with less favorable results.

Biodegradable stents versus suture ligatures.

In the literature stents used for vasovasostomy are all biodegradable. The reason for most authors for using such a stent was that a perfect alignment of the vas ends was obtained and possible leakage was prevented. Several studies tried to prove that intraluminal stenting showed less stricture than sutured anastomosis. Flamm et al.¹⁴ presented a study using polyglycolic acid stents in the reconstruction of vas deferens in rats. One side underwent a microscopic conventional sutured reconstruction with interrupted 10-0 Dermalon, and continuity of the collateral vas was restored with an absorbable polyglycolic acid stent. After 6 weeks the stent was degraded and just a slight mucosal inflammation was left. Narrowing of the anastomoses occurred in both groups but was more present in the non-stented group in combination with more perivasal inflammation and late cicatrization, probably due to extravasation of sperm. Flamm et al. pointed out that prevention of sperm leakage at the site of the anastomosis was of importance in preventing secondary stricturing.

Montie et al.¹⁵ also used absorbable material as an intravasal stent. They described the histological effects in dogs in the wall of the vas deferens at the site of the anastomosis. They compared a conventional sutured vasovasostomy (6-0 silk) with intraluminal stents using either 3-0 Dexon (polyglycolic acid synthetic absorbable stent) or 3-0 chromic catgut using different types of approximation sutures. In the silk group, severe granuloma formation and local inflammatory reactions were seen. Minimal intraluminal tissue reaction in the vas wall was seen after reconstruction with an intravasal chromic catgut stent as well as with chromic catgut as approximation sutures.

Nuwayser et.al.¹⁶ experimented with different materials. They used starch, collagen and polyester as a stent in an animal study. Polyester biodegradable stents demonstrated the best results with 100% patency and rapid absorption within 10-14 days. The anastomosis site showed excellent healing with normal vas epithelium and no stricture. Finally Berger et al.¹⁷ presented a stent study in rats and dogs using a polyglycolic acid absorbable stent. They compared a stented vasovasostomy group with a modified two-layer technique. Scanning electron microscopy showed superior re-epithelialization and normalization of morphology in the stented group.

In all the above-mentioned studies superior healing of the anastomosis was seen with stents compared to suture ligatures.

Why a non-absorbable polymeric stent?

Histological alterations of the vas anastomosis were observed in our study. Especially borderline inflammatory reactions of the vas were seen in the stent group with a subepithelial eosinophilic and histiocytic reaction. In the conventional microsurgical sutured group, more partial obstructions due to severe fibrotic changes in the anastomotic area were noted. The idea of developing a nonabsorbable stent was born from the concept that stricturing at the site of the microsurgical sutured anastomosis was caused by sperm leakage owing to lack of water tightness, eventually leading to sperm granuloma development and cicatrization. This leakage could possibly be prevented by a permanent stent in situ covering the anastomosis.

Our study is the first to investigate a nonabsorbable polymeric stent in the reconstruction of the vas deferens. Despite the fact that slight inflammatory reactions in the vas wall of the stented group were observed, we assume that these minor reactions are less relevant than the fibrotic stricturations occurring from the conventional microscopic one or two layer reconstructions. Absorbable stents are generally not made of inert polymeric biomaterial.

With the dissolving of these absorbable stents the anastomosis area is exposed within several weeks. It is our believe that even after the absorption of the stent the anastomosis area is still at risk of stricturation owing to the fact that the anastomosis area is still biologically active or that the inflammatory respons to resolve the stent, could cause secondary stricturing of the anastomosis. The permanent position of a nonabsorbable biocompatible polymeric stent at the site of the anastomosis could prevent any danger of secondary stricturation and thus provide persistent patency. The development of inert biocompatible materials justifies the consideration of permanent stent implants. Therefore we will continue to investigate this stent in human studies.

References

1. Silber S J. Microscopic vasectomy reversal. *Fertil Steril* 1977; 28: 1191-202.
2. Vrijhof HJEJ, Delaere KPJ. Vasovasostomy results in 66 patients related to obstructive intervals and serum agglutinin titres. *Urol Int* 1994; 53:143-6,
3. Belker AM, Thomas AJ, Fuchs EF, Konnak JW, Sharlip ID. Results of 1,469 microsurgical vasectomy reversals by the Vasovasostomy Study Group. *J Urol* 1991; 145: 505-11.
4. Carbone DJ, Shah A, Thomas A J, Agarwal A.. Partial obstruction, not antisperm antibodies, causing infertility after vasovasostomy. *J Urol* 1998; 159: 827-36.
5. Freund M, Davis JE. Disappearance rate of spermatozoa from the ejaculate following vasectomy. *Fertil Steril* 1969; 20: 163-70.
6. Belker AM. Editorial: Evaluation of partial anastomotic obstruction after vasovasostomy and predictors of success after vasoepididymostomy. *J Urol* 1998; 159: 835-36.
7. Fuse H, Kimura H, Katayama T. Modified one-layer microsurgical vasovasostomy in vasectomized patients. *Int. Urol. Nephrol.* 1995;27: 451-56.
8. Fischer MA, Grantmyre JE. Comparison of a modified one- and two-layer microsurgical vasovasostomy. *BJU Int* 2000; 85:1085-88
9. Royle MG, Hendry WF. Why does vasectomy reversal fail? *BJU Int* 1985; 57: 780-3
10. Hernandez J. Sabanegh ES. Repeat vasectomy reversal after initial failure: overall results and predictors for success. *J Urol* 1999; 161: 1153-56
11. Fox M. Failed vasectomy reversal: is a further attempt using microsurgery worthwhile? *BJU Int.* 2000; 86: 474-8

12. Paick JS, Park JY, Park DW, Park K, Son H, Kim SW. Microsurgical vasovasostomy after failed vasovasostomy. *J Urol* 2003; 169: 1052-55
13. Matthews GJ, McGee KE, Goldstein M. Microsurgical reconstruction following failed vasectomy reversal. *J Urol* 1997; 157: 844-6
14. Flam TA, Roth RA, Silverman ML, Gagne RG. Experimental study of hollow, absorbable polyglycolic acid tube as stent for vasovasostomy. *Urology* 1989; 33: 490-4
15. Montie JE, Stewart BH, Howards SL. Intravasal stents for vasovasostomy in canine subjects. *Fertil Steril* 1973; 24: 877-83
16. Nuwayser ES, Wu TC, Hotchkiss RS, Farcon EE, Hulka JJ, Mohr K, et al. An absorbable artificial vas deferens for vasovasostomy. *Trans Am Soc Artif Intern Organs*. 1975; 21: 523-30
17. Berger RE, Jessen JW, Patton DL, Bardin ED, Burns MW, Chapman WH. Studies of polyglycolic acid hollow self-retaining vasal stent in vasovasostomy. *Fertil Steril* 1989; 51: 504-8

Chapter 9

Summary & conclusion

Chapter 1

Objective: To give an overview of the different vasectomy techniques utilized and try to explore from the literature what method of vasectomy could give the lowest risk of early recanalization. What is the exact definition of early recanalization. Should persistent non-motile spermatozoa after vasectomy primarily be considered as early recanalization or as a succesful vasectomy outcome? In this review we also try to provide answers to this problem.

Results: The no-scalpel technique has, besides lower complication rates, no advantages compared to the conventional technique. Simple ligatures of the vasal ends provide, due to sloughing, the highest chance of recanalization (1-5%). Cautery of a vasal segment over a length of more than 1 cm and interposition of fascial sheath, together with the technique of folding back of vasal ends, brings the best results. Resection of long segments is probably not necessary to improve results. Resection of long segments provides more complications and reduces the opportunities of vasectomy reversal. Percutaneous vasectomies using silicone plugs should be rejected.

Leaving the testicular side open at the time of vasectomy could be advantageous. Open ended vasectomies could be of benefit when considering future vasectomy reversal. Sperm granuloma development at the testicular-end in open vasectomies has the advantage of preventing irreversible damage to the testis, improving the chances of successful reversal. The sperm granuloma development could act as pressures relieve valve also reducing postvasectomy epididymal congestive pain.

Besides two consecutive samples of azoospermia, persistent non-motile sperm ($<10.000/\text{ml}$) should also be considered as a criterion for success. Early recanalization is defined as persistence of motile sperm four months after vasectomy.

Conclusion(s): Well designed randomized trials have to be conducted to prove that open-ended vasectomy, without resection of long segments and cautery of the abdominal end over at least 1 cm in combination with fascial interposition, is probably the method of choice in an era where the incidence of divorces are high and the chances of a restored child wish with a new partner is considerable. Persistent non-motile sperm ($<10.000/\text{mL}$) seven months after vasectomy should be defined as a successful outcome and not as early recanalization.

Chapter 2

Introduction: We determined the percentage of patients with nonmotile sperm 12 weeks after vasectomy and estimated the time needed for eventual azoospermia in these patients. We also recorded the percentage of patients with recurrence of nonmotile sperm after initial azoospermia post-vasectomy.

Materials & Methods: A review was done of the semen analysis of vasectomies performed in a 2-year period. Vasectomies were performed in an outpatient department of the University Hospital of Maastricht. Semenanalysis were performed in a group of volunteers from 4 months until 24 months after vasectomy. Amount and motility of sperm in postvasectomy semen samples were recorded. All the men were referred by the general practitioner for vasectomy.

Results: Nonmotile sperm was found in 33% of the patients 12 weeks after vasectomy. The mean time to azoospermia was 6.36 months. Nonmotile sperm after initial azoospermia was found in 5 of 65 patients.

Conclusions: Azoospermia as a criterion for sterility leads to unnecessary prolonged semen analysis in a large percentage of the vasectomized patients. Reappearance of nonmotile sperm was found in an unexpectedly high percentage.

Chapter 3

This review chapter starts with a description of the microscopical vaovasostomy technique. The role of optical loupes versus microscopes is discussed. Details of the microscope like length of binocular tubes, power of the eyepiece and the power of the magnification changer are reviewed. Optimal care has to be taken for the exact positioning of the microscope because non optimal visualization can be of bother during the entire operation. The use of high quality surgical instruments is of utmost importance for a successful vasovasostomy. Various microsurgical instruments are described and their mechanical properties and functions are discussed.

Chapter 4

Introduction: In this series we present the results of a retrospective analysis of 66 vasovasostomy procedures performed between 1983 and 1991.

Materials & Methods: Obstructive intervals and serum antisperm antibodies were correlated with pregnancy and patency rates.

Results: With obstructive intervals of less than 5 years a patency rate of 100% (31/31) was obtained. Even more than 10 years after reversal, pregnancy occurred in 25% (2/8) of the patients. Preoperative serum antisperm antibodies were correlated with pregnancy rates. Patients with a high agglutinin titre of 1/64 obtained a pregnancy rate of 23% (3/13). Those men who had no circulating antisperm antibodies in their blood had a significantly better chance in obtaining pregnancy (pregnancy rate 80%). In this study we accounted for an overall pregnancy rate of 51.5% (34/66) versus an overall patency rate of 84.8% (56/66).

Conclusion: Neither long obstructive intervals nor high antisperm antibody titres should dissuade a surgeon from performing a vasovasostomy procedure

Chapter 5

Objective: In this review article we want to investigate the current opinions regarding the influence of post vasectomy sperm granuloma, antisperm antibodies development and subsequent epididymal and/or testicular tissue changes on vasovasostomy results.

Methods: literature search was performed using MEDLINE database on factors influencing outcome of vasectomy reversal.

Results: Sperm granulomas occur in 10-30% of men who underwent a vasectomy. These sperm granulomas develop mainly at the epididymal area. Increased epididymal pressure leads to tubular ruptures causing fibrosis of the epididymal ductules and possible obstruction. Rupturing of these epididymal tubules is the probable cause of antisperm antibodies formation.

Depositions of these humoral immune complexes in the epididymis and/or testis area have a complementary negative effect on these tissues. Open-ended vasectomies could have a beneficial effect on the prevention of granuloma formation at the epididymal area. Granuloma formation at the testicular open vasectomy end will eventually lead to reduced pressures in the epididymis, preventing further damage. Despite these advantageous aspects of open-ended vasectomy no scientific study has proven up to now that better vasovasostomy results are obtained with this open-ended technique. Human and animal studies suggest that vasectomy causes changes in interstitial tissues of the epididymis with much more densely occupied fibers. Testis tissue is less frequently damaged due to obstruction than the epididymis region. Probably a lot of pressure is already released at the epididymal area as described previously. If changes in the testis occur, it results in increased seminiferous wall thickness, focal interstitial fibrosis and changes in the interstitial area. It is unclear whether these changes are reversible after vasovasostomy? From animal studies we know that progression of these changes are probably reduced but not reversed. Animals with smaller testicles after vasectomy showed more severe

changes of the seminiferous tubules and higher levels of antisperm antibodies were measured. The effects of tissue damage to the epididymis and testis on vasovasostomy results in men remains still unclear. Literature on this subject is rare and describes small series. Although it seems obvious, until now no well designed study is performed to verify whether these tissue alterations have a detrimental effect on semen quality after vasectomy reversal.

Conclusion: Open-ended vasectomies could have a beneficial effect on the prevention of epididymal and testicular tissue changes, granuloma formation and antisperm-antibodies production. Despite these advantageous aspects of open-ended vasectomy no scientific study has proven up to now, that better vasovasostomy results are obtained with this open-ended technique.

Chapter 6

Introduction: Vasectomy has become popular since it is the safest surgical method for contraception. It is known that approximately 6 % of the men that undergo vasectomy will seek reversal (vasovasostomy). This operation is, however, technically demanding and relatively time-consuming. This study was based on the hypothesis that a polymeric mini-stent can facilitate and accelerate vasovasostomies.

Materials&Methods: A mini-stent was manufactured out of a cross linked hydrogel biomaterial, which was synthesized from N-vinyl-pyrrolidinone (NVP), n-butylmethacrylate, and (triethyleneglycol) dimethacrylate. The device was tested in 28 rabbits, which were divided over two equal groups. In one group, the vasa deferentia were dissected and reanastomosed via microsurgical one-layer technique (end-to-end group). In the other group, the vasa deferentia were dissected and reattached through implantation of a mini-stent.

Results: Sperm counts revealed 100 % patency in both groups, i.e. all vasovasostomies were successful. It was experienced that the operation was easier and faster in the case of the mini-stent, probably since the mini-stent keeps the lumens of both vas ends exactly in line during suturing.

Conclusion: This study demonstrates the feasibility of the mini-stent. Further work is necessary to evaluate the utility of this approach for clinical vasovasostomies.

Chapter 7

Objective(s): To investigate the use of a newly designed stent in the reconstruction of the vas deferens

Materials and Methods: In 26 New Zealand White rabbits, 13 conventional one-layer microscopic reconstructions were compared with 13 stented reconstructions of the vas deferens. The newly designed nonabsorbable polymeric stent was shaped to facilitate the rejoining of the two loose ends of the vas deferens, using a central ridge to prevent migration. Semen was collected before and after surgery, using an artificial vaginal system (26 samples before and 115 samples after surgery). The individual and average total sperm count, motility and progressive motile sperm density (PMSD) were compared after surgery for both groups. After the final semen analysis, rabbits were killed and patency was assessed histologically at the site of the anastomosis.

Results: After an initial decline, the mean total sperm count increased in both groups. The increase was significantly larger ($p=0.05$) in the stented rabbits. The mean motility and PMSD showed no significant differences between both groups ($p=0.11$ and 0.71 respectively). Histological examination of the anastomosed area showed partial obstruction ($>50\%$ narrowing of the original lumen) in five of the 13 conventionally treated rabbits, with no strictures in the

stented group. Despite the narrowing in the conventional group the patency rates were not affected. The mean (range) operating time for the conventional and stented groups was 132 (99-168) and 98 (62-113) min, respectively ($p < 0.001$)

Conclusion: The total sperm counts, motility and PMSD showed no or little difference after surgery between the conventional and stented rabbits. The stented reconstruction was easy, had no secondary stricturing and reduced the operating time.

Chapter 8

Objective: To investigate whether a newly designed non absorbable polymeric stent for the reconstruction of the vas deferens provided less stricturing at the site of the anastomosis in comparison with the conventional microsurgical reconstruction of the vas deferens.

Design: Prospective randomized study in 26 rabbits, comparing the one-layer microscopical sutured procedure with a biocompatible stent.

Setting: University animal laboratory center

Interventions: Pre- and postoperative average total sperm count, motility and progressive motile sperm density levels (PMSD) were measured. Histological sections were taken from the area of the anastomosis, testes and epididymis after final semen analysis.

Main outcome measures: Rates of stricture and semen parameters

Results: The vas deferens of the rabbits that received a stent, showed an inflammatory reaction within the vas wall, adjacent to the stent. Transmural histiocytic or eosinophilic reactions were seen in 2/13 (15%) of the stented animals, with atrophy of the epithelium. Histological cross-sections of the stented vas deferens demonstrated patency. Microscopically sutured rabbits showed more partial obstructions at the site of the anastomosis 5/13 (38%) with transmural infiltration of lymphocytes and histiocytes. Despite these partial obstructions the vasa were

patent. There was a statistically significant difference in favor of the stent with respect to the total sperm count ($p=0.05$). No differences were seen in motility ($p=0.057$) or PMSD's ($p=0.13$).

Conclusions: The newly developed stent provided patency rates comparable with the conventional one-layer microscopic procedure but showed significantly less stricturing of the anastomoses.

Chapter 10

Samenvatting & conclusies

Hoofdstuk 1

Inleiding: In dit overzichtsartikel geven we een beschouwing van de diverse vasectomie technieken en daarnaast proberen we aan de hand van literatuurgegevens aan te geven welke vasectomie vorm het laagste risico heeft op vroege rekanalisatie. Wat is de precieze definitie van vroege rekanalisatie? Moeten persisterende non-motiele zaadcellen na vasectomie geduid worden als vroege rekanalisatie of als een geslaagde vasectomie. In dit overzichtsartikel proberen we ook op die vraag een antwoord te geven.

Resultaten: De niet-scalpel techniek heeft, behoudens lagere complicatie kansen, geen evidente voordelen boven de conventionele techniek. Eenvoudige onderbinding van de vasa deferentia e uiteinden leidt tot necrotiseren van deze uiteinden en geeft het grootste risico op rekanalisatie (1-5%). Coaguleren van een vas uiteinde over een lengte van meer dan 1cm en interpositie van weefsel tussen deze uiteinden in combinatie met omklappen van de vasa, geeft het geringste risico op rekanalisatie. Excisie van een lang vas segment is niet nodig en levert geen voordelen op. Het verwijderen van lange vas deferens stukken tijdens de vasectomie geeft uiteindelijk meer complicaties en verkleint de mogelijkheid op een eventuele vas deferens reconstructie. Het gebruik van silicone plugs om een vasectomie te doen moet worden afgeraden. Het open laten van het testiculaire vas deferens uiteinde ten tijde van de vasectomie zou mogelijk voordelen kunnen opleveren. De zogenaamde ‘open-ended’ vasectomie zou het voordeel hebben dat de kans op een succesvolle vasovasostomie wordt verruimd. Aan het testiculaire vas uiteinde kan zich een spermagranuloom ontwikkelen welke op zijn beurt weer als een decompressieklep kan fungeren. Het voordeel is dat onomkeerbare beschadigingen aan testis en epididymis zouden kunnen worden voorkomen waardoor er een verbeterde kans ontstaat op een succesvolle vas deferens reconstructie. Bijkomend voordeel van deze decompressie techniek is, dat er minder post-vasectomie stuwingspijnen van de epididymis worden beschreven.

Behoudens twee opeenvolgende spermacontroles met azoospermie is de aanwezigheid van persisterende non-motiele zaadcellen ($<10.000/\text{ml}$) ook een criterium voor een succesvolle vasectomie. Vroege rekanalisatie wordt gedefinieerd als persisterende motiele zaadcellen vier maanden na een vasectomie.

Conclusie: Goed opgezette gerandomiseerde trials zijn nodig om aan te tonen dat ‘open-ended’ vasectomie zonder verwijdering van grote delen vas, in combinatie met coagulatie van het abdominale vas uiteinde over een lengte van 1cm en weefsel interpositie en omklappen, de methode is die mogelijk de voorkeur heeft. Deze methode is vooral van belang gezien de toename van het aantal echtscheidingen met nadien herstel van kinderwens. Persisterende non-motile zaadcellen ($<10.000/\text{ml}$) zeven maanden na vasectomie kunnen beschouwd worden als een succesvolle vasectomie en niet als vroege rekanalisatie.

Hoofdstuk 2

Inleiding: In dit onderzoek werd het percentage patienten bepaald met non-motile spermatozoa 12 weken na vasectomie en tevens werd gekeken naar de tijd die nodig was bij deze patienten om uiteindelijk een vasectomie te bereiken. Daarnaast hebben we een registratie verricht van het aantal patienten dat een terugkomst heeft ontwikkeld van non-motiele spermatozoa nadat bij deze patienten aanvankelijk een azoospermie werd vastgesteld.

Materialen en methoden: Er werd een overzicht verricht van zaadanalyses bij vasectomie patienten over een periode van twee jaar. De vasectomies werden poliklinisch verricht aan de afdeling urologie van het Academisch Ziekenhuis te Maastricht. Semenanalyses werden verricht in een groep vrijwilligers vanaf 4 tot 24 maanden na de vasectomie. Onderzocht werden de concentratie van het aantal spermatozoa en de motiliteit. Alle patienten werden via de huisarts verwezen voor een vasectomie.

Resultaten: De aanwezigheid van non-motiele spermatozoa werd bij 33% van de patienten 12 weken na de vasectomie nog vastgesteld. Azoospermie werd uiteindelijk bereikt gemiddeld 6.36 maanden na de vasectomie. De terugkomst van non-motiele zaadcellen na aanvankelijke azoospermie werd bij 5 van de 65 patienten vastgesteld.

Conclusie: Azoospermie als absoluut criterium voor steriliteit na vasectomie leidt tot onnodig langdurige zaadcontroles bij een groot percentage van de vasectomie patienten. Terugkomst van non-motiele zaadcellen werd vastgesteld in een onverwacht groot aantal patienten.

Hoofdstuk 3

Dit overzichtsartikel handelt over de microchirurgische verrichte vasovasostomie. De rol van van een loup-bril versus de operatie microscoop wordt bediscussieerd. Details van de microscoop waaronder oculairen, vergrotingsfactor en scherptediepte worden gedetailleerd beschreven. Belangrijk is dat de microscoop ten tijde van de vasovasostomie optimaal voor de chirurg wordt gepositioneerd. Insufficiente positionering leidt tot suboptimale visus en is gedurende de gehele ingreep tot last. Het gebruik van hoogwaardige microchirurgische instrumenten is absoluut noodzakelijk. De verschillende microchirurgische instrumenten worden beschreven en hun mechanische eigenschappen evenals hun functies worden belicht.

Hoofdstuk 4

Inleiding: In deze studie presenteren we de resultaten van een retrospectieve analyse van 66 vasovasostomie operaties welke verricht werden tussen 1983 en 1991.

Materialen en Methoden: Obstructie intervallen (periode tussen vasectomie en herstel) en serum antisperma-antilichamen werden gerelateerd aan doorgankelijkheids- en zwangerschaps percentages.

Resultaten: Bij obstructie intervallen korter dan 5 jaren werd een doorgankelijkheidspercentage gemeten van 100% (31/31) in deze studie. Zelfs bij obstructieintervallen van meer dan 10 jaar werd nog een zwangerschapspercentage van 25% vastgesteld (2/8). Preoperatief bepaalde antisperma antilichamen werden gecorreleerd aan de zwangerschapspercentages. Die mannen die preoperatief geen antisperma antilichamen in hun bloed hadden, hadden een aanmerkelijk hogere kans op het verkrijgen van een zwangerschap (80%). In deze studie werd een overall zwangerschapspercentage vastgesteld van 51.5% (34/66) en een doorgankelijkheidspercentage van 84,8% (56/66).

Conclusie: Langdurige obstructie intervallen of hoge antisperma antilichamen titers zouden een chirurg er niet van moeten weerhouden om een vasovasostomie te verrichten.

Hoofdstuk 5

Inleiding: In dit overzichtsartikel hebben we gekeken naar de actuele opinies over de invloeden van postvasectomie spermagranulomen en antisperma-antilichaam vorming op de resultaten van een vasovasotomie. Zowel spermagranulomen als antisperma antilichamen hebben een schadelijke invloed op de epididymis en testis. Heeft schade toegebracht aan de epididymis of testis, ten gevolge van de vasectomie eveneens invloed op het resultaat van een vasovasostomie?

Resultaten: Sperma granulomen komen voor bij 10-30% van de mannen die een vasectomie hebben ondergaan. Deze sperma granulomen komen vooral voor op epididymis niveau. Verhoogde drukken in de epididymis leiden tot rupturering van de tubuli waardoor fibrosering ontstaat van de ductuli met als gevolg verder obstructie. Rupturering van deze epididymale tubuli is zeer waarschijnlijk de oorzaak van het ontstaan van antisperma-antilichamen. Het neerslaan van deze immune complexen in de epididymis en/of testis hebben een additioneel

negatief effect op deze weefsels. Open-ended vasectomie (het openlaten van het testiculaire uiteinde ten tijde van de vasectomie) zou mogelijk een gunstig effect kunnen hebben op het voorkomen van deze epididymale granulomen. Granuloom vorming aan het testiculaire uiteinde kan leiden tot afname van druk in de epididymis doordat deze als een uitlaatklep fungeert als de druk te hoog wordt. Hierdoor kan verdere schade aan de epididymis voorkomen worden. Ondanks deze mogelijke voordelen van een open-end vasectomie is er tot op heden nog nooit een goede wetenschappelijke studie verricht waarbij onomstotelijk is komen vast te staan dat er betere vasovasostomie resultaten worden bereikt met deze techniek. Zowel studies in de mens als in dier tonen aan dat een vasectomie weefsel verandering geeft in interstitieel weefsel van de epididymis met een toenemende weefseldichtheid. Testis weefsel is minder vaak aangedaan door obstructie dan epididymaal weefsel. Mogelijk dat al veel overdruk via de epididymis wegstroomt ten gevolge van rupturering aldaar. Indien er door de druk toch weefsel veranderingen optreden in de testis dan zijn dat vooral verdikkingen in de wand van de tubuli seminiferi en locale interstitiele fibrose. Zijn deze weefsel veranderingen omkeerbaar na een vasovasostomie? Dieren studies hebben aangetoond dat verder progressie van deze afwijkingen wordt afgeremd echter de veranderingen die al zijn opgetreden zijn niet meer om te keren. Dieren met kleinere testikels enige tijd na vasectomie hebben ernstigere afwijkingen in hun tubuli seminiferi dan beesten met normale testikels na vasectomie. Ook hebben beesten met kleinere testikels een aanmerkelijke hogere concentratie van antisperma antilichamen. Het effect van weefsel beschadiging aan de testis en epididymis op vasovasostomie resultaten is nog altijd onduidelijk. Literatuur over dit onderwerp is bijzonder schaars en beschrijft kleine series. Hoewel het voor de hand lijkt te liggen is er echter tot op heden geen enkele goed opgezette studie voor handen die bewijst dat deze weefsel veranderingen een negatieve invloed hebben op de zaadkwaliteit na vasovasostomie.

Conclusie: Open-end vasectomien kunnen mogelijk een gunstig effect hebben op het voorkomen van weefselbeschadigingen aan testis en epididymis, granuloom vorming en antisperma-antilichaam vorming. Ondanks deze voordelige effecten van een open-end vasectomie is er tot op heden nog nooit een studie geweest die heeft aangetoond dat er betere vasovasostomie resultaten worden verkregen met een open-end vasectomie.

Hoofdstuk 6

Inleiding: Vasectomie heeft vooral aan populariteit gewonnen doordat de vasectomie een veilige en betrouwbare vorm van anticonceptie bleek te zijn. Het is bekend dat circa 6% van de mannen die een vasectomie hebben ondergaan dit ongedaan willen laten maken (vasovasostomie). Deze procedure is een tijdrovende technisch hoogstaande behandeling. De hypothese achter deze studie was dat een polymeren mini-stent de ingreep eenvoudiger zou maken en daardoor minder tijdrovend.

Materialen en methoden: De mini-stent werd gemaakt van cross-linked hydrogel biomateriaal wat gemaakt was van N-vinyl-pyrrolidinone (NVP), n-butylmethacrylate en (triethyleneglycol) dimethacrylate. Deze stent werd getest op 28 konijnen welke verdeeld werden over twee groepen. In de ene groep werden de vasa deferentia transversaal gekliefd en gereaanastomoseerd met een microscopische one-layer anastomose (end-to-end groep). In de andere groep werden eveneens de vasa deferentia dwars gekliefd en deze werden gereconstrueerd met behulp van de implantatie van deze mini-stent.

Resultaten: Zaadanalysen toonden aan dat er 100% doorgankelijkheid (patency) werd bereikt in beide groepen m.a.w. alle vasovasostomien waren succesvol. Het bleek dat de anastomose makkelijker en sneller te creëren was in de mini-stent groep doordat na plaatsing van de stent, het vas uiteinde perfect in een lijn lagen gedurende het hechten.

Conclusie: Deze studie laat zien dat deze mini-stent geschikt lijkt voor het uitvoeren van een vasovasostomie. Toekomstige studies in de mens zullen de haalbaarheid van een dergelijke stent in een klinische situatie moeten aantonen.

Hoofdstuk 7

Inleiding: Doel van de studie was om de effectiviteit van een volledig nieuw ontworpen niet-resorbeerbare polymere stent te onderzoeken voor de reconstructie van een zaadleider.

Materialen en methoden: Uiteindelijk konden er 26 konijnen gebruikt worden voor een vergelijkende studie waarbij er 13 conventionele microscopische reconstructies werden vergeleken met 13 stent reconstructies. Een specifieke stentvorm van dit hydrofiele biocompatibele materiaal werd ontwikkeld om beide vas uiteinden makkelijker naar elkaar toe te brengen. Een centrale richel werd gecreëerd om migratie van de stent te voorkomen. Semen analyses werden gedaan zowel voor als na de operatie waarbij een kunstvagina werd gebruikt om het zaad op te vangen. (26 semen analyses voor en 115 na de ingreep). Postoperatief werden alle individuele en gemiddelde sperma concentraties (mil/ml) als wel motiliteitspercentages(%) en PMSD's (progressieve motiele sperma dichtheid) vergeleken in beide groepen. Niet lang na de laatste zaadanalyse werden de konijnen geofferd en werd de doorgankelijkheid tevens histologisch onderzocht ter plaatse van de anastomose.

Resultaten: Nadat aanvankelijk de gemiddelde sperma concentraties kort na de ingreep daalden zagen we uiteindelijk een toename van de deze gemiddelde sperma concentraties in beide groepen. De toename van de gemiddelde sperma concentraties was statistisch significant beter in de stent groep ($p=0.05$). De gemiddelde motiliteit en PMSD toonden geen statistisch significant verschil in beide groepen (motiliteit $p=0.11$ en PMSD $p=0.71$). Histologisch onderzoek toonde aan dat er meer gedeeltelijke obstructie ($>50\%$ vernauwing van het lumen)

werd gezien in de conventionele microscopische groep (38%) versus géén vernauwing in de stent groep. Ondanks de grotere aantallen vernauwingen in de conventionele groep werden er geen verschillen in doorgankelijkheid aangetoond. De gemiddelde operatieduur in de stent groep van 98 min (62-113 min) was significant ($p < 0.001$) korter dan die van de conventionele groep 132min(99-168).

Conclusie: De postoperatieve sperma concentraties, motiliteitspercentages en PMSD's toonden weinig tot geen verschillen aan tussen beide groepen. De stent reconstructies waren makkelijker uitvoerbaar, minder tijdrovend en toonden geen secundaire vernauwingen aan ter hoogte van de anastomose.

Hoofdstuk 8

Inleiding: Om te onderzoeken of een nieuw ontworpen niet resorbeerbare polymeren stent voor het herstel van de zaadleider, minder vernauwingen gaf ter plaatse van de anastomose vergeleken met de conventionele microscopische reconstructie. Het betrof een prospectieve gerandomiseerde studie in 26 konijnen waarbij een éénlagige microscopische reconstructie werd vergeleken met een reconstructie waarbij gebruik werd gemaakt van een niet-resorbeerbare biocompatibele polymeren stent.

Materialen en methoden: Pre en postoperatieve gemiddelde sperma concentraties, motiliteit en progressieve motiele sperma concentraties (PMSD) werden bepaald. Histologisch onderzoek werd verricht van de anastomose, epididymis en testis kort nadat de laatste semencontrole heeft plaatsgevonden.

Resultaten: De vasa deferentia van konijnen die eens stent kregen toonden een ontstekingsreactie in de wand van het vas deferens daar waar de stent tegen het epitheel van het vas deferens lumen was gelegen. Transmurale histiocytair of eosinofiele reacties in combinatie

met atrofie van het epitheel werden gezien in 2/13 (15%) konijnen die een stent hadden gekregen. Histologisch onderzoek van transverse coupes van het vas deferens toonden doorgankelijkheid aan. Konijnen die microscopisch werden gereconstrueerd toonden meer partiele obstructies aan op de plaats van de anastomose 5/13 (38%) vergeleken met conventionele microscopische reconstructies. Tevens werd ter plekke transmurale infiltratie van lymfocyten en histiocyten gezien. Ondanks deze gedeeltelijke vernauwingen waren de vasa deferentiae toch goed doorgankelijk. Er bleek een statisch significant voordeel te zijn voor de stent groep als het ging om de sperma concentraties ($p=0.050$). Geen verschillen werden gezien in motiliteit ($p=0.057$) of PMSD ($p=0.13$).

Conclusie: De nieuw ontwikkelde stent gaf vergelijkbare doorgankelijkheid vergeleken met de conventionele microscopische reconstructie maar toonde aanmerkelijk minder secundaire stricturering ter plaatse van de anastomose.

Curriculum vitae

The author of this thesis was born on the 27th of February 1958 in Maastricht. After graduation from the St. Maartens College (Atheneum-B) in Maastricht, he completed his medical studies at the Catholic University of Nijmegen and obtained his medical degree (doctoraalexamen) in February 1984.

He worked as a resident (AGNIO) at the surgical department of the University Hospital of Maastricht from 1986-1988 (Prof. Dr. J.M. Greep†, surgeon) and continued his formal training (AGIO) in urology at the University Hospital of Maastricht in 1988. His surgical part of the training was performed at the De Wever Hospital te Heerlen from (1989-1991, opleider, Dr. J.D.K. Munting, surgeon). The urological part of the training was conducted from 1991-1993 at the De Wever Hospital in Heerlen (opleider, Dr. K.P.J. Delaere, urologist) and from 1993-1995 at the University Hospital of Maastricht (opleider, Prof.Dr. R.A. Janknegt). He worked part-time as a junior Staff member at the University Hospital of Maastricht (Department of Urology) and part-time as a urologist at the Catharina Hospital in Eindhoven (1995-1999). In 1999 he continued working full-time as a urologist at Catharina Hospital in Eindhoven. At present, he is still working at this same hospital. In 1986 he married Denise Steffens and together they have three children, Sascha, Thomas and Bob.