Cover Page

Universiteit Leiden

Leiden University Repository

The handle http://hdl.handle.net/1887/37049 holds various files of this Leiden University dissertation.

Author: Gooskens, Jairo
Title: Molecular and clinical insights into seasonal and pandemic influenza
Issue Date: 2015-12-02

Chapter 3

Severe influenza resembling hemorrhagic shock and encephalopathy syndrome

Gooskens J [1], Kuiken T [4], Claas ECJ [1], Harinck HI [2], Thijssen JCP [1], Baelde HJ [3], Kroes ACM [1]

Journal of Clinical Virology **2007**; *39: 136–40*

1 Department of Medical Microbiology
Leiden University Medical Center, Leiden, the Netherlands
2 Department of Intensive Care
Leiden University Medical Center, Leiden, the Netherlands
3 Department of Pathology
Leiden University Medical Center, Leiden, the Netherlands
4 Department of Virology
Erasmus University Medical Center, Rotterdam, the Netherlands

Abstract

Influenza-associated encephalopathy is a clinically diverse syndrome and severe cases are not well documented outside Japan. Clinical, pathological and molecular aspects are described of two fatal cases presenting during 2004 and 2005 winter seasons in the Netherlands. Results showed that severe influenza can resemble hemorrhagic shock and encephalopathy syndrome, and proper testing for influenza virus should be considered in similar cases. The failure to detect viral replication in non-pulmonary organs including the brain would support the pathogenesis of this syndrome is based on proinflammatory cytokine responses.

Introduction

Neurological impairment during acute human influenza is defined as influenza-associated encephalopathy (IAE). Patients with IAE have rarely been documented in Europe and North America after the 1957 pandemic [2, 5, 9, 20] and recent clinical presentations are variable [12, 26]. In contrast, cases have frequently been described among Japanese children, characterized by rapidly progressive coma (often <24 h) and high mortality rates (50–100 annually from 1995 to 2000) [19, 21]. Viral RNA detection in cerebrospinal fluid has been reported [6], but is considered a rare finding [7, 20]. Neuroinvasion is therefore disputed as a cause of neurological symptoms, whereas an indirect role for proinflammatory cytokines is suggested as a more likely explanation [15, 26]. Neuroinvasion of avian influenza virus (A/H5N1) has been confirmed in animal models and is suggested for human cases [4]. Distinct clinical forms of encephalopathy associated with acute human influenza include Reye's syndrome, encephalitis, acute necrotizing encephalopathy [19] and the hemorrhagic shock and encephalopathy syndrome (HSE) [22]. We report two patients with IAE and unusual symptoms of hemorrhage, multiple organ failure and shock, admitted to our hospital during the 2003–2004 and 2004–2005 winter seasons. Pathological and molecular studies were performed on tissue specimens following autopsy in one case.

Case reports

Patient 1. A previously healthy 9-year-old girl was found somnolent in the morning with evidence of recent haematemesis. She had a 3-day history of sore throat, cough and 38.5 °C fever, with nausea, vomiting and fever exceeding 40 °C during the previous night. There was no influenza vaccination or acetylsalicylic acid ingestion. During medical transportation she developed coma and required intubation. On admission, the Glasgow Coma Scale was 3 with signs of respiratory distress, endotracheal hemorrhage, epistaxis and diarrhea. Physical examination revealed a temperature of 37.4 °C and blood pressure of 100/40 mmHg. There was no nuchal rigidity, papilledema, pathological reflexes, petechiae, rash or mucous membrane abnormalities. Laboratory examination revealed hypoxia (85% O2 during mechanical ventilation), combined respiratory and metabolic acidosis (pH 7.18, lactate 2.6 mmol/l), low white blood cell count (WBC 3200 mm^{-3} , 59% lymphocytes), renal failure (creatinine 197 µmol/l, urea 9.5 mmol/l) and elevated LDH (752 U/l) and CPK (1455 U/l). She developed anemia (haemoglobin 9.0 to 4.4 mmol/l), leucopenia (WBC 600 mm^{-3}), thrombocytopenia (31×10^9 l^{-1}), coagulopathy (PTT 31.5 s, aPTT 88.6 s, fibrinogen 1.2 g/l and D-dimer >5000 µg/l), elevated liver enzymes (ASAT 193 U/l, ALAT 39 U/l), glucose (11.8 mmol/l) and amylase (2045 U/l). Chest radiograph showed bilateral infiltrate formation and computed tomography (CT) of the brain appeared normal. Cerebrospinal fluid was not obtained due to coagulopathy. Rapid influenza antigen testing (nasal wash), influenza serology (complement fixation), and viral throat cultures were negative. PCR of throat and nasal wash specimens was positive for influenza A virus and negative for influenza B virus, human respiratory syncytial virus, parainfluenza virus 1–4, human metapneumovirus, rhinovirus, *Mycoplasma sp.* and *Chlamydophila sp.* [17, 23, 24]. Viral culture from nasal wash revealed an influenza virus, characterized by duplicate haemagglutination inhibition tests as influenza A/H3N2/Fujian/411/02-like virus according to standard methods [13, 16] using turkey erythrocytes and four haemagglutinating units of virus. Multiple blood and other bacterial cultures were negative. Her condition rapidly deteriorated despite broad-spectrum antibiotic treatment, dexamethasone and drotrecogin-alfa. She died within 24 hours due to shock, multiple organ failure and disseminated intravascular coagulation (DIC). No autopsy was performed. This case occurred in the midst of the community influenza season in December 2003.

Patient 2. A 17-year-old male adolescent with a stable ventricular septal defect became progressively somnolent following a 1-day history of flu-like symptoms, diarrhea and

neck pain. There was no influenza vaccination or acetylsalicylic acid ingestion. During admission, he progressed into coma (Glasgow Coma Scale 10 to 3) without respiratory symptoms. Profuse hemorrhagic secretions were retrieved during intubation. Physical examination revealed a temperature of 33.7 °C, blood pressure of 90/50 mmHg and skin mottling. There was no nuchal rigidity, papilledema, pathological reflexes, petechiae, rash or mucous membrane abnormalities. Laboratory results revealed 100% oxygen saturation (breathing 5 l oxygen), severe lactic acidosis (pH 6.78, lactate 15.7 mmol/l), leukocytosis 31,200 mm^{-3}, haemoglobin 9.5 mmol/l, progressive coagulopathy (thrombocyte count 88×10^9 l^{-1}, PTT 19.0 s, aPTT 98.6 s, fibrinogen 1.3 g/l), renal failure (creatinine 288 µmol/l, urea 12.6 mmol/l), and elevated liver enzymes (ASAT 108 U/l, ALAT 25 U/l), glucose (22.4 mmol/l), thyroid-stimulating hormone (14.630 mU/l), LDH (1210 U/l) and CPK (1782 U/l). Toxicology screening was negative. Chest radiograph and electrocardiography appeared normal. CT of the brain was normal, but revealed sphenoid and maxillary sinusitis. Cerebrospinal fluid was not obtained due to coagulopathy. Multiple blood and other bacterial cultures were negative. His condition rapidly deteriorated despite broad-spectrum antibiotic treatment, dexamethasone and drotrecogin-alfa. He died within 24 hours due to progressive multiple organ failure, DIC and shock. Autopsy was performed following parental permission. PCR detected influenza A virus [23] from fresh pulmonary and sinus tissue specimens, but not from pleural and pericardial fluid obtained during autopsy. PCR was negative for other respiratory viruses. Influenza virus cultured from sinus tissue was antigenically characterized as influenza A/H3N2/Wyoming/003/03-like virus. This case occurred in the midst of the community influenza season in February 2005.

Pathological and molecular analysis

Pathology. Autopsy (patient 2) and tissue preparation was performed according to standard procedures, taking precautions to minimize RNA degradation (rapid tissue preparation and fixation to minimize autolysis) and to prevent contamination (separate autopsy of the brain; individual tissue processing in separate cassettes; solitary tissue cutting by sterile microtome and disposable blades). Macroscopic findings included edematous lungs with hemorrhagic pleural fluid. Microscopic examination did not detect encephalitis, necrosis or other abnormalities in the pons, striatum, mesencephalon, hippocampus, cerebellum or four ventricle biopsy specimens. Pulmonary tissue revealed multifocal hemorrhage, bronchitis and early diffuse alveolar damage.

The liver contained no fatty changes and other organs had no major abnormalities. *Streptococcus pneumoniae, Neisseria meningitidis*, herpes simplex virus, varicella-zoster virus and enterovirus were excluded by PCR or polysaccharide antigen testing on post-mortem cerebrospinal fluid. Fresh specimens were not available for further molecular testing.

Immunohistochemistry. Formalin-fixed paraffin-embedded (FFPE) tissue sections of 4 µm were deparaffinized, hydrated and treated with pronase for 10 min at 37 °C. The monoclonal mouse-anti-Influenza A nucleoprotein (IgG2a, Hb65, ATCC) was diluted in PBS/0.1% BSA and incubated with the section for 1 h at room temperature, and bound antibody was detected with an alkaline phosphatase labeled (AP) goat-anti-mouse IgG2a. AP was revealed with fast red chromogen substrate resulting in pink/red precipitate. Focal specific nuclear staining was mainly observed in pulmonary bronchial epithelium cells and in very few cells in the alveoli (type undetermined), but not in other organs **(Table 1)**.

Molecular analysis of viral expression. RNA was extracted from alternate clinical and negative control FFPE tissue sections. Ten 4 µm sections were deparaffinized (xylene), rehydrated and digested overnight at 50 °C in 200 µl lysis buffer (500 µg/ml proteinase K (Roche, Mannheim, Germany) in 20mM Tris (pH 7.4), 1mM EDTA (pH 8.0), 2% SDS). RNA was isolated (TRIzol reagent, Invitrogen, Carlsbad, CA, USA), precipitated (2-propanol, 3 µl of 2 mg/ml glycogen), washed (500 µl of 75% ethanol), dried and re-suspended (60 µl). Purity and quantity of extracted RNA was measured (NanoDrop Technologies, Wilmington, USA). OD 260/280 ratios were ≥1.8 for most sections indicating high purity [3] except for brain tissues with OD ratios <1.8. In addition, the RNA concentration extracted from brain specimens was somewhat lower. Influenza PCR was performed using previously published primers and probe with an equine arteritis virus internal control [23, 17]. Influenza A RNA was detected in all organs **(Table 1)**. A molecular assay was developed for detection of influenza mRNA indicating viral replication. The primers 851FLUA-M2s 5'-GAGYCTTCTAACCGAGGTC and 852FLUA-M2as 5'-CAACAACAAGCGGGTCAC amplified an 83 bp spliced fragment of M2 mRNA as confirmed by sequence analysis **(Figure 1)**, and a 771 bp unspliced fragment of M1 mRNA or viral RNA. The optimized assay was performed using the Qiagen OneStep RT-PCR kit (Qiagen, Hilden, Germany) with 0.2mM dNTP's, 3.5mM MgCl2, 30 pmol each primer and 10 µl extracted RNA. Cycling conditions were 30 min at 50 °C (cDNA synthesis) and 45 cycles (95 °C, 30 s; 51 °C, 30 s; 30 s at 72 °C). PCR product was

analyzed by gel electrophoresis. Spliced M2 mRNA was detected in pulmonary tissue, but not in other organs (Table 1). The sensitivity of the PCR to detect influenza mRNA is unknown and especially difficult to determine in fixed specimens. Spliced M2 mRNA was consistently detected from fixed pulmonary tissue. In addition, spliced mRNA was consistently detected down to a 1:3125 dilution in controls of influenza infected MRC-5 cells, with the knowledge that mRNA is a low abundant messenger.

Table 1. Molecular and immunohistochemical detection of influenza A RNA, antigen and spliced mRNA in paraffin-embedded tissue specimens.

Paraffin-embedded specimens	Influenza A PCR (Ct value)	Influenza B PCR (Ct value)	Influenza A expression		Multiplex EAV spike (Ct value) [g]	Concentration of total extracted RNA (ng/µl)	RNA/protein OD ratio [h] (260/280)
			Antigen	M2 mRNA			
nControl (fixed lung) [a]	–	–	–		27.2	81	1.8
Heart	+ (36.9)	–	–	–	28.0	83	1.8
nControl (fixed lung)	–	–	–		27.3	92	1.8
Liver	+ (37.5)	–	–	–	27.6	289	1.8
nControl (fixed lung)	–	–	–		27.5	90	1.8
Kidney	+ (35.6)	–	–	–	26.2	118	1.8
nControl (fixed lung)	–	–	–		27.1	74	1.8
Mesencephalon	–	–	–	–	27.2	8.9	1.6
nControl (fixed lung)	–	–	–		27.2	69	1.8
Pons	+ (37.6)	–	–	–	26.6	18	1.7
nControl (fixed lung)	–	–	–		28.1	66	1.9
Lung	+ (24.8)	–	+	+	30.1	545	1.8
nControl (fixed tonsil) [a]	–	–	–	–	26.8	114	1.8
nControl (isotype/omission) [b]			–				
Influenza B control (fixed) [c]	–	+ (33.3)	–		26.6	51	1.7
Influenza A control (fixed) [d]			+				
Influenza A control (culture) [e]				+			
Influenza A control (culture) [f]	+ (33.1)	–					

Ct, cycle threshold; M2, matrix gene segment encoding influenza M2 protein; EAV, equine arteritis virus.

a Fixed negative controls, paraffin-embedded pulmonary (cynomolgus macaques) and tonsil (human) tissues.

b Fixed negative controls, isotype- and omission controls.

c Fixed influenza B control, post-mortem paraffin-embedded lung tissue from a patient with influenza B pneumonia.

d Fixed influenza A antigen positive control, paraffin-embedded pulmonary tissue of an experimentally infected cat with influenza A (04-7992-2).

e mRNA positive control, RNA extracted from MRC-5 human lung cells infected by influenza A virus (field isolate).

f Influenza A RNA positive control, RNA extracted from supernatant of LLC-MK2 cells infected by influenza A virus (field isolate).

g Co-amplification with EAV spike as internal control revealed no evidence for inhibition.

h High OD 260/280 ratios (≥1.8) indicate purity of the RNA (Chung et al., 2006).

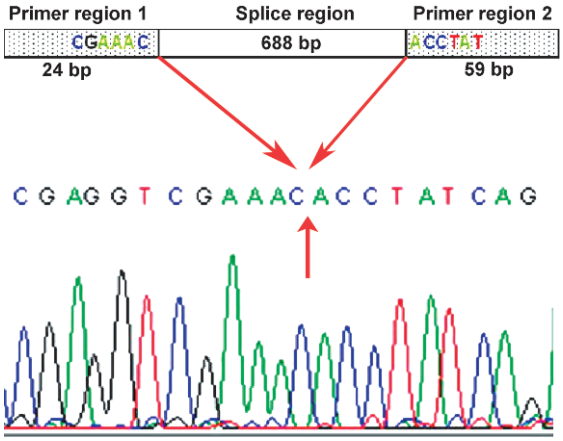

Figure 1. Sequence analysis of the 83 bp M2 mRNA PCR product amplified from RNA extracted from MRC-5 human lung cells infected with influenza A virus (field isolate).
M2 mRNA was confirmed by detection of spliced influenza matrix gene RNA. The splice site (arrow) corresponds to position C51-A740 (A/New York/206/2005; Gen-Bank Accession number CY006132).

Discussion

Two patients with IAE are described, who had rapidly progressive coma during acute influenza infection. The clinical findings and outcome differed substantially from recent Dutch cases with IAE [18, 26]. Although fatal cases of IAE occurred in Japan, fatal cases of IAE have not been documented in the Netherlands after the 1957 pandemic, when 68 patients (mainly children) died during a 3-month period [25].

Clinical similarities to recent Japanese cases include sudden high fever, vomiting or diarrhea, early onset and rapid progression of coma, multiple organ failure and haemodynamic shock [15]. Comparable laboratory results include thrombocytopenia, prolonged coagulation tests and elevated levels of transaminases, LDH and CPK. Differences in our cases include a higher age (most Japanese cases <5 years old), lack of documented convulsions and absence of convincing brain CT abnormalities. Acute necrotizing encephalopathy was excluded in both patients by brain CT [14]. In addition, influenza A RNA was isolated from brain tissue of patient 2. Influenza RNA has not been reported in brain tissue or cerebrospinal fluid of patients with acute necrotizing encephalopathy. Reye's syndrome is considered unlikely as the patients received no

acetylsalicylic acid, were hyperglycemic, and had only mildly elevated liver enzyme levels. The absence of hepatic fatty changes and neural inflammatory cell infiltration also excludes Reye's syndrome and encephalitis as the cause of coma in patient 2.

Importantly, clinical symptoms of both patients strongly resembled HSE using the described criteria [1, 11]. Criteria for HSE for patient 1 were not met due to unavailability of cerebrospinal fluid and the solitary elevated hepatocellular enzyme levels without clear evidence for hepatic dysfunction. Criteria for HSE for patient 2 were not met because of the modest reduction of haemoglobin levels and the solitary elevated hepatocellular enzyme levels without clear evidence for -hepatic dysfunction. Hepatocellular enzyme profiles reflected rhabdomyolysis rather than hepatic dysfunction in both patients. HSE is a severe syndrome with unknown aetiology [10], and associations with acute influenza are confined to Japan. Similar to Japanese findings [22], we detected influenza RNA in multiple organs including the brain taken at autopsy from patient 2. In contrast to Japanese findings, we found no evidence of viral replication in nonpulmonary tissues containing influenza RNA, which could be explained by residual deposition of disseminated influenza RNA from replication elsewhere (lungs) or by the presence of undetectable low-level influenza antigen and mRNA in these non-pulmonary tissues. This would further implicate proinflammatory cytokine responses in the pathogenesis of this syndrome. The rapid clinical deterioration in both patients suggests that antiviral therapy will have little chance of success in hospitalized patients presenting with advanced stage of IAE and HSE-like symptoms. Antiviral intervention during early stages of influenza-like illness might have altered the outcome of the patients described. Additional supportive and immunomodulating therapeutic measures during hospital admission have been suggested [8]. The protective role of influenza vaccination during early stages of childhood, to prevent rare IAE and HSE-like complications during later stages of childhood or adolescence, remains to be determined.

In conclusion, severe influenza can resemble HSE syndrome, emphasizing the need for appropriate diagnostic efforts to demonstrate influenza virus infections in similar cases. Molecular detection of influenza mRNA can be used to detect local influenza replication in archival and clinical specimens.

Conflict of interest

There was no financial support for the study. None of the authors have associations that might pose a conflict of interest.

Acknowledgements

Influenza immunostaining was kindly performed by D. van Riel and influenza antigen characterization by haemagglutination inhibition testing was performed by Dr. G.F. Rimmelzwaan, Department of Virology, Erasmus Medical Center, WHO National Influenza Center. Brain tissue specimens were reviewed for neuropathological characteristics by Dr. A.C. Jobsis and Dr. S.G. van Duinen, Department of Pathology, Leiden University Medical Center. We thank Prof. W.J. Spaan and Dr. H.C. van Leeuwen, Department of Medical Microbiology, Leiden University Medical Center, for helpful suggestions and advice.

References

1. Bacon CJ, Hall SM. Haemorrhagic shock encephalopathy syndrome in the British Isles. *Arch Dis Child* **1992**; 67: 985–93.

2. Bhat N, Wright JG, Broder KR, *et al*. Influenza Special Investigations Team. Influenza-associated deaths among children in the United States, 2003-2004. *N Engl J Med* **2005**; 353: 2559–67.

3. Chung JY, Braunschweig T, Hewitt SM. Optimization of recovery of RNA from formalin-fixed, paraffin-embedded tissue. *Diagn Mol Pathol* **2006**; 15: 229–36.

4. de Jong MD, Bach VC, Phan TQ, *et al*. Fatal avian influenza A (H5N1) in a child presenting with diarrhea followed by coma. *N Engl J Med* **2005**; 352: 686–91.

5. Flewett TH, Hoult JG. Influenzal encephalopathy and postinfluenzal encephalitis. *Lancet* **1958**; 2: 11–5.

6. Fujimoto S, Kobayashi M, Uemura O, *et al*. PCR on cerebrospinal fluid to show influenza-associated acute encephalopathy or encephalitis. Lancet **1998**; 352: 873–5.

7. Ito Y, Ichiyama T, Kimura H, *et al*. Detection of influenza virus RNA by reverse transcription-PCR and proinflammatory cytokines in influenza-virus-associated encephalopathy. *J Med Virol* **1999**; 58: 420–5.

8. Kawashima H, Togashi T, Yamanaka G, *et al*. Efficacy of plasma exchange and methylprednisolone pulse therapy on influenza-associated encephalopathy. *J Infect* **2005**; 51: E53–6.

9. Kirton A, Busche K, Ross C, Wirrell E. Acute necrotizing encephalopathy in Caucasian children: two cases and review of the literature. *J Child Neurol* **2005**; 20: 527–32.

10. Levin M, Hjelm M, Kay JD, *et al*. Haemorrhagic shock and encephalopathy: a new syndrome with a high mortality in young children. *Lancet* **1983**; 2: 64–7.

11. Levin M, Pincott JR, Hjelm M, *et al*. Hemorrhagic shock and encephalopathy: clinical, pathologic, and biochemical features. *J Pediatr* **1989**; 114: 194–203.

12. Maricich SM, Neul JL, Lotze TE, *et al*. Neurologic complications associated with influenza A in children during the 2003-2004 influenza season in Houston, Texas. *Pediatrics* **2004**; 114: e626–33.

13. Masurel N, Ophof P, de Jong P. Antibody response to immunization with influenza A/USSR/77 (H1N1) virus in young individuals primed or unprimed for A/New Jersey/76 (H1N1) virus. *J Hyg (Lond)* **1981**; 87: 201–9.

14. Mizuguchi M, Abe J, Mikkaichi K, *et al*. Acute necrotising encephalopathy of childhood: a new syndrome presenting with multifocal, symmetric brain lesions. *J Neurol Neurosurg Psychiatry* **1995**; 58: 555–61.

15. Morishima T, Togashi T, Yokota S, *et al*; Collaborative Study Group on Influenza-Associated Encephalopathy in Japan. Encephalitis and encephalopathy associated with an influenza epidemic in Japan. *Clin Infect Dis* **2002**; 35: 512–7.

16. Palmer DF, Dowdle WR, Coleman MT, Schild GC. Haemagglutination inhibition test. In: *Anonymous: Advanced laboratory techniques for influenza diagnosis. Procedural guide. Atlanta: US Department of Health, Education and Welfare* **1975**; 25–62.

17. Scheltinga SA, Templeton KE, Beersma MF, Claas EC. Diagnosis of human metapneumovirus and rhinovirus in patients with respiratory tract infections by an internally controlled multiplex real-time RNA PCR. *J Clin Virol* **2005**; 33: 306–11.

18. Smidt MH, Stroink H, Bruinenberg JF, Peeters M. Encephalopathy associated with influenza A. *Eur J Paediatr Neurol* **2004**; 8: 257–60.

19. Sugaya N. Influenza-associated encephalopathy in Japan. *Semin Pediatr Infect Dis* **2002**; 13: 79–84.

20. Steininger C, Popow-Kraupp T, Laferl H, *et al*. Acute encephalopathy associated with influenza A virus infection. *Clin Infect Dis* **2003**; 36: 567–74.

21. Sugaya N, Takeuchi Y. Mass vaccination of schoolchildren against influenza and its impact on the influenza-associated mortality rate among children in Japan. *Clin Infect Dis* **2005**; 41: 939–47.

22. Takahashi M, Yamada T, Nakashita Y, *et al*. Influenza virus-induced encephalopathy: clinicopathologic study of an autopsied case. *Pediatr Int* **2000**; 42: 204–14.

23. Templeton KE, Scheltinga SA, Beersma MF, Kroes AC, Claas EC. Rapid and sensitive method using multiplex real-time PCR for diagnosis of infections by influenza a and influenza B viruses, respiratory syncytial virus, and parainfluenza viruses 1, 2, 3, and 4. *J Clin Microbiol* **2004**; 42: 1564–9.

24. Templeton KE, Scheltinga SA, Graffelman AW, *et al*. Comparison and evaluation of real-time PCR, real-time nucleic acid sequence-based amplification, conventional PCR, and serology for diagnosis of Mycoplasma pneumoniae. *J Clin Microbiol* **2003**; 41: 4366–71.

25. van Geer I, Mulder J. Asian influenza mortality in 1957. *Ned Tijdschr Geneeskd* **1958**; 102: 1208–11.

26. van Zeijl JH, Bakkers J, Wilbrink B, Melchers WJ, Mullaart RA, Galama JM. Influenza-associated encephalopathy: no evidence for neuroinvasion by influenza virus nor for reactivation of human herpesvirus 6 or 7. *Clin Infect Dis* **2005**; 40: 483–5.