



Universiteit
Leiden
The Netherlands

Molecular analysis of the HPJ-JT syndrome and sporadic parathyroid carcinogenesis

Haven, C.J.

Citation

Haven, C. J. (2008, May 28). *Molecular analysis of the HPJ-JT syndrome and sporadic parathyroid carcinogenesis*. Retrieved from <https://hdl.handle.net/1887/12960>

Version: Corrected Publisher's Version

License: [Licence agreement concerning inclusion of doctoral thesis in the Institutional Repository of the University of Leiden](#)

Downloaded from: <https://hdl.handle.net/1887/12960>

Note: To cite this publication please use the final published version (if applicable).

Chapter 5

Loss of parafibromin immuno-reactivity is a distinguishing feature of parathyroid carcinoma.

Clin. Cancer Res. 2004 Oct 1;10(19):6629-37.

Loss of Parafibromin Immunoreactivity Is a Distinguishing Feature of Parathyroid Carcinoma

Min-Han Tan,^{1,12} Carl Morrison,⁴ Pengfei Wang,¹ Ximing Yang,⁵ Carola J. Haven,⁶ Chun Zhang,¹ Ping Zhao,² Maria S. Tretiakova,⁷ Eeva Korpi-Hyövalti,⁸ John R. Burgess,⁹ Khée Chee Soo,¹⁰ Wei-Keat Cheah,¹¹ Brian Cao,² James Resau,³ Hans Morreau,⁶ and Bin Tean Teh¹

¹Laboratories of Cancer Genetics, ²Antibody Technology, and ³Analytical, Cellular and Molecular Microscopy, Van Andel Research Institute, Grand Rapids, Michigan; ⁴Department of Pathology, Ohio State University Medical Center, Columbus, Ohio; ⁵Division of Surgical Pathology, Northwestern University, Chicago, Illinois; ⁶Department of Pathology, Leiden University Medical Center, Leiden, the Netherlands; ⁷Department of Pathology, University of Chicago, Illinois; ⁸Department of Internal Medicine, Seinäjoki Central Hospital, Finland; ⁹Department of Diabetes and Endocrine Services, Royal Hobart Hospital, University of Tasmania, Australia; ¹⁰Department of General Surgery, Singapore General Hospital, Singapore; ¹¹Department of Surgery, National University Hospital, Singapore; and ¹²Department of Medicine, Alexandra Hospital, Singapore

ABSTRACT

Purpose: A reliable method for diagnosing parathyroid carcinoma has remained elusive over the years, resulting in its under-recognition and suboptimal therapy. Obtaining an accurate diagnosis has become an even more pressing matter with recent evidence that germline *HRPT2* gene mutations are found in patients with apparently sporadic parathyroid carcinoma. There is a high prevalence of *HRPT2* gene mutations and biallelic inactivation in parathyroid carcinoma. We hypothesize that loss of parafibromin, the protein product of the *HRPT2* gene, would distinguish carcinoma from benign tissue.

Experimental Design: We generated a novel antiparafibromin monoclonal antibody and performed immunostaining on 52 definite carcinoma specimens, 6 equivocal carcinoma specimens, 88 benign specimens, and 9 hyperparathyroidism-jaw tumor (HPT-JT) syndrome-related adenomas from patients with primary hyperparathyroidism from nine worldwide centers and one national database.

Received 3/11/04; revised 5/11/04; accepted 5/18/04.

Grant support: The study was funded internally by the Van Andel Research Institute (Grand Rapids, Michigan). The costs of publication of this article were defrayed in part by the payment of page charges. This article must therefore be hereby marked advertisement in accordance with 18 U.S.C. Section 1734 solely to indicate this fact.

Requests for reprints: Bin Tean Teh, Van Andel Research Institute, 333 Bostwick Avenue NE, Grand Rapids, Michigan 49503. Phone: 616-234-5296; Fax: 616-234-5297; E-mail: bin.teh@vai.org.

©2004 American Association for Cancer Research.

Results: We report that the loss of parafibromin nuclear immunoreactivity has 96% sensitivity [95% confidence interval (CI), 85–99%] and 99% specificity (95% CI, 92–100%) in diagnosing definite carcinoma. Inter-observer agreement for evaluation of parafibromin loss was excellent, with unweighted kappa of 0.89 (95% CI, 0.79–0.98). Two equivocal carcinomas misclassified as adenomas were highlighted by parafibromin immunostaining. One of these tumors has since recurred, satisfying criteria for a definite carcinoma. Similarly, eight of nine HPT-JT syndrome-related adenomas showed absent nuclear immunoreactivity.

Conclusions: Parafibromin is a promising molecular marker for diagnosing parathyroid carcinoma. The similar loss of parafibromin immunoreactivity in HPT-JT syndrome-related adenomas suggests that this is a pivotal step in parathyroid tumorigenesis.

INTRODUCTION

Primary hyperparathyroidism is a common disorder, diagnosed with increasing frequency (1). The prevalence of parathyroid carcinoma has ranged in various studies from <1 to 5% of cases of primary hyperparathyroidism (1, 2) with especially high rates reported in Japan (3) and Italy (4). The causes of this variation are unclear but may reflect a true geographical difference, referral bias, or differences in the histologic criteria used. Apart from the presence of local invasiveness or metastasis, there is no definitive standard for pathologic diagnosis of parathyroid carcinoma; in the absence of these features, such a diagnosis may have subjective elements (1, 2, 5). As a result of this difficulty in recognition, up to 86% of cases are not initially recognized intra-operatively even in expert institutions and receive inadequate surgical resection (6). The diagnosis of carcinoma is often retrospectively made after relapse (2, 7), when treatment options are limited. In one series, half of all recurrent or metastatic carcinomas were initially diagnosed as benign (8). Indeed, it has been concluded by some authors that systematic diagnosis of parathyroid carcinoma may rest upon ongoing postoperative follow-up of patients who have undergone resection of apparently benign adenomas (9, 10). About 20% of patients with an apparently sporadic carcinoma may be manifesting a forme fruste of hyperparathyroidism-jaw tumor (HPT-JT) syndrome (11), a hereditary multitumor syndrome characterized by *HRPT2* gene mutations (12). In this light, an accurate diagnosis is even more critical. Timely diagnosis would allow definitive surgery and targeted genetic screening of individuals and their families (13). From a clinical viewpoint, it is unsatisfactory to rely on tumor extension for diagnosis, as early recognition and treatment by en-bloc resection are the main determinants of prognosis (2, 3, 6, 14).

The *HRPT2* gene is a recently identified tumor suppressor gene in parathyroid carcinoma, encoding a novel protein product named parafibromin (15). Somatic *HRPT2* gene mutations occur

in 66 to 100% of sporadic parathyroid carcinomas, and biallelic inactivation is present in the majority of these cases (11, 16). We thus hypothesized that loss of parafibromin immunoreactivity would distinguish parathyroid carcinoma from benign pathologies of primary hyperparathyroidism.

Studies of Diagnostic Markers. The quest for a definitive method for diagnosis started in earnest 30 years ago, when initial histopathologic guidelines for the diagnosis of carcinoma described uniform sheets of cells arranged in a lobulated fashion separated by fibrous trabeculae, capsular or vascular invasion, and the presence of mitotic figures (17). Unfortunately, mitotic features, fibrous bands, and uniform sheets of cells were found not to be pathognomonic for parathyroid carcinoma (5, 14). As a result of the limited applicability of these guidelines, many adjunct investigations for parathyroid carcinoma have been studied, including electron microscopy, immunohistochemistry, DNA flow cytometry, and *in situ* hybridization (2). Immunohistochemical markers that have been studied include retinoblastoma tumor suppressor gene protein (pRb), calcium-sensing, Ki-67, cytokeratin-14, p27, mdm2, Bcl-2, cyclin D1, p53, and p21 (5, 18–24). However, many markers have not been shown to be useful in this regard (19).

The most extensively studied marker to date is the retinoblastoma tumor suppressor gene *RB* and the *RB* protein (pRb). Contrary to initial reports, recent evidence suggests that loss of heterozygosity is not specific to parathyroid carcinoma. Studies of pRb immunostaining have also yielded conflicting results. Some studies have reported that it may be a helpful marker (25, 26), but several other studies have contradicted these findings (22, 23). A recent review of *RB* gene abnormalities in parathyroid carcinoma concluded that no definitive conclusion could be drawn with regards to pRb staining (26).

Other markers studied include cell cycle-associated antigens. Erickson *et al.* (21) and Stojadinovic *et al.* (19) report that although carcinomas, relative to adenomas, have a lower percentage of p27-positive nuclei, there is a considerable overlap in staining percentages. Stojadinovic *et al.* also report that a multiple-marker phenotype including p27, Bcl-2, Ki-67, and mdm2 was useful in defining a subset of benign tumors but that carcinoma displayed a complex range of multi-marker phenotypes, some of which were not specific. Furthermore, DNA cytometry was shown to be of prognostic but not diagnostic use. It distinguishes a subset of parathyroid carcinomas that are aneuploid and that may behave in a more aggressive fashion (27–29) but is not specific (2, 3, 30, 31) or sensitive (27–30).

In summary, despite many studies over the years, diagnosing parathyroid carcinoma remains a major challenge for the expert pathologist. As there is a high prevalence of *HRPT2* gene mutations in parathyroid carcinoma (11, 16), we investigated parafibromin immunoreactivity as a means of differentiating parathyroid cancer from benign tissue, including adenomas, hyperplasias, and multiple endocrine neoplasia types 1 (MEN1)-associated tumors. As the prevalence of parathyroid carcinoma varies geographically for uncertain reasons (2), we selected a geographically diverse, multi-center approach, with a variety of pathologies that may be encountered in the evaluation of primary hyperparathyroidism. As histologic criteria varies because of the lack of standard guidelines, gold-standard criteria of invasion or metastasis was imposed on case selection for stand-

ardization. We additionally stained adenomas from patients from HPT-JT syndrome, in view of a common expression profiling signature distinguishing these adenomas and carcinomas from other types of benign tissue that we recently reported (32).

MATERIALS AND METHODS

Patient Samples. We conducted a multi-center, retrospective study involving anonymized formalin-fixed, paraffin-embedded parathyroid specimens from primary hyperparathyroidism cases. The participating centers were Ohio State University, Leiden University Medical Center (Netherlands), Northwestern University, University of Chicago, Seinäjoki Central Hospital (Finland), Singapore General Hospital (Singapore), National University Hospital (Singapore), Shared Pathology Informatics Network (West Michigan), and University of Tasmania (Australia). The study was reviewed and approved by the Van Andel Institute Institutional Review Board.

A total of 160 specimens were examined. One hundred and twenty-three full sections were studied, including sporadic primary carcinomas ($n = 19$), sporadic metastatic tissue ($n = 1$), sporadic equivocal carcinomas ($n = 2$), sporadic adenomas ($n = 50$), sporadic primary hyperplasia ($n = 25$), MEN1-associated tumors ($n = 13$), HPT-JT primary carcinoma ($n = 1$), HPT-JT adenomas ($n = 7$), and normal tissue ($n = 5$). A tissue array containing an additional 37 specimens obtained from the Dutch National Pathology Database (PALGA) was also studied: sporadic primary carcinomas ($n = 23$), sporadic metastatic tissue ($n = 7$), sporadic equivocal carcinomas ($n = 3$), HPT-JT primary carcinoma ($n = 1$), HPT-JT adenomas ($n = 2$), and normal tissue ($n = 1$). Triplicate tissue cores with a diameter of 0.6 mm, as selected by a pathologist (H. M.), were taken from each specimen (Beecher Instruments, Silver Spring, MD) wherever possible, and a standard procedure was used to array tissue cores on a recipient paraffin block (33). The full sections of all arrayed specimens were examined (H. M.) to ensure concordance with criteria. In all cases (both full sections and arrays), lesions were diagnosed as definite carcinomas only if vascular invasion, invasion of surrounding tissue, or distant metastasis were evident. Equivocal carcinomas were defined as tumors exhibiting histopathologic features of carcinoma without the presence of vascular invasion, invasion of surrounding tissue, or distant metastasis (22, 28). Clinicopathologic data for the definite and equivocal carcinoma cases, following reclassification as described below, are shown in Table 1. In summary, 52 definite carcinoma specimens were obtained from 48 patients; multiple specimens from single patients were obtained at separate clinical events. 49 of 52 definite carcinoma specimens had surrounding tissue or vascular invasion on histopathologic examination. For 25 specimens from 21 patients with available data, 19 specimens were from 15 patients who initially or eventually developed metastases, 5 specimens were from 5 patients who relapsed locally, and only 1 patient, who was followed up for 1 year, did not have local or systemic relapse during follow-up. Twenty-eight arrayed definite carcinoma specimens had been further characterized previously (5): 10 of 28 were cystic; 4 of 28 trabecular; 19 of 28 had fibrotic bands; 8 of 28 had >1 of 10 mitoses/high power field; 14 of 28 showed positive cyclin D1

Table 1 Clinicopathologic data and evaluation of immunostaining for carcinoma specimens

Patient	Histo-pathological assessment of carcinoma	Tumor location	Presence of local or vascular invasion at initial surgery	Presence of metastasis at initial surgery	Clinical progression during follow-up	Presence of metastasis or relapse during clinical history	Parafibromin immunoreactivity
1	Definite	Primary, local	Y	N	Local relapse	Y	Diffuse staining/intensity 3
2	Definite	Primary, local	N	N	Metastasis	Y	Diffuse loss
3	Definite	Primary, local	Y	N	Unknown	Unknown	Focal loss
4	Definite	Primary, local	Y	N	Unknown	Unknown	Focal loss
5	Definite	Primary, local	Y	N	Local relapse	Y	Focal loss
6	Definite	Primary, local	Y	N	Local relapse	Y	Focal loss
7	Definite	Metastasis, initial	Y	Y	Metastasis	Y	Focal loss
8	Definite	Primary, local	Y	N	Unknown	Unknown	Focal loss
9	Definite	Metastasis, initial	N	Y	Metastasis	Y	Diffuse loss
10	Definite	Relapse, local	Y	N	Local relapse	Y	Diffuse loss
11	Definite	Metastasis, initial	Y	Y	Metastasis	Y	Diffuse loss
12	Definite	Metastasis, initial	Y	Y	Metastasis	Y	Focal loss
12	Definite	Metastasis, relapse	Y	Y	Metastasis	Y	Diffuse loss
12	Definite	Metastasis, initial	Y	Y	Metastasis	Y	Diffuse loss
13	Definite	Primary, local	Y	N	Unknown	Unknown	Diffuse loss
14	Definite	Metastasis, relapse	Y	Y	Metastasis	Y	Diffuse loss
15	Definite	Metastasis, initial	Y	Y	Metastasis	Y	Focal loss
16	Definite	Primary, local	Y	N	Unknown	Unknown	Focal loss
17	Definite	Metastasis, initial	Y	Y	Metastasis	Y	Focal loss
18	Definite	Primary, local	Y	N	No relapse	N	Focal loss
19	Definite	Primary, local	Y	N	Metastasis	Y	Diffuse staining/intensity 2
20	Definite	Primary, local	N	N	Local relapse	Y	Diffuse loss
21	Definite	Primary, local	Y	N	Unknown	Unknown	Diffuse loss
22	Definite	Primary, local	Y	N	Unknown	Unknown	Focal loss
23	Definite	Primary, local	Y	N	Unknown	Unknown	Diffuse loss
24	Definite	Primary, local	Y	N	Unknown	Unknown	Diffuse loss
25	Definite	Primary, local	Y	N	Unknown	Unknown	Focal loss
26	Definite	Primary, local	Y	N	Unknown	Unknown	Diffuse loss
27	Definite	Primary, local	Y	N	Unknown	Unknown	Diffuse loss
28	Definite	Primary, local	Y	N	Unknown	Unknown	Focal loss
29	Definite	Primary, local	Y	N	Unknown	Unknown	Diffuse loss
30	Definite	Primary, local	Y	N	Unknown	Unknown	Focal loss
31	Definite	Primary, local	Y	N	Unknown	Unknown	Diffuse loss
32	Definite	Primary, local	Y	N	Unknown	Unknown	Focal loss
33	Definite	Primary, local	Y	N	Metastasis	Y	Focal loss
33	Definite	Metastasis, relapse	Y	Y	Metastasis	Y	Focal loss
34	Definite	Metastasis, initial	Y	Y	Metastasis	Y	Diffuse loss
34	Definite	Metastasis, relapse	Y	Y	Metastasis	Y	Diffuse loss
35	Definite	Primary, local	Y	N	Unknown	Unknown	Focal loss
36	Definite	Metastasis, initial	Y	Y	Unknown	Y	Diffuse loss
37	Definite	Primary, local	Y	N	Unknown	Unknown	Diffuse loss
38	Definite	Primary, local	Y	N	Unknown	Unknown	Focal loss
39	Definite	Primary, local	Y	N	Metastasis	Y	Focal loss
40	Definite	Primary, local	Y	N	Unknown	Unknown	Diffuse loss
41	Definite	Metastasis, initial	Y	Y	Unknown	Y	Diffuse loss
42	Definite	Primary, local	Y	N	Unknown	Unknown	Diffuse loss
43	Definite	Primary, local	Y	N	Unknown	Unknown	Diffuse loss
44	Definite	Primary, local	Y	N	Unknown	Unknown	Focal loss
45	Definite	Metastasis, initial	Y	Y	Unknown	Y	Diffuse loss
46	Definite	Primary, local	Y	N	Unknown	Unknown	Focal loss
47	Definite	Primary, local	Y	N	Unknown	Unknown	Focal loss
48	Definite	Primary, local	Y	N	Unknown	Unknown	Diffuse loss
49	Equivocal	Local	N	N	No relapse	N	Diffuse staining/intensity 3
50	Equivocal	Local	N	N	No relapse	N	Diffuse staining/intensity 3
51	Equivocal	Local	N	N	No relapse	N	Diffuse staining/intensity 1
52	Equivocal	Local	N	N	Unknown	Unknown	Focal loss
53	Equivocal	Local	N	N	Unknown	Unknown	Diffuse loss
54	Equivocal	Local	N	N	No relapse	N	Focal loss

staining; 20 of 27 showed positive calcium-sensing receptor staining; 14 of 22 had loss of heterozygosity of chromosome 1q (*HRPT2* gene loci); 13 of 22 had loss of heterozygosity at chromosome 11q (*MEN1* gene loci); Ki-67 index ranged from

0.1 to 27.5. All HPT-JT adenomas had been sequenced previously (15, 33) and confirmed to have *HRPT2* gene mutations. All *MEN1* tumors had been confirmed previously to have *MEN1* gene mutations.

Monoclonal Antibody Generation and Validation. We first generated a novel murine monoclonal antibody to parafibromin targeting the peptide RRPDRKDLLGYLNC, corresponding to amino acid positions 87 to 100. BALB/c mice were immunized with intraperitoneally administered keyhole limpet hemocyanin-conjugated synthetic peptides in complete Freund's adjuvant, followed by two additional injections in incomplete Freund's adjuvant at an interval of 2 weeks. After a month, injections without adjuvant were administered both intravenously and intraperitoneally. Spleen cells were fused with P3X63AF8/653 myeloma cells 3 days after the final injection. An immunofluorescence assay was used to screen positive hybridomas with COS7 cells transfected with a green fluorescent protein (GFP)-HRPT2 DNA fusion construct, validated by ELISA, subcloned to establish stable monoclonal antibody-secreting hybridomas, and revalidated by ELISA. The antibody was purified by fast performance liquid chromatography in a protein G affinity column.

Indirect immunofluorescence was used to show antibody specificity (Fig. 1). HEK293 cells transfected with a GFP-HRPT2 DNA fusion construct and control cells transfected with GFP-empty vector were fixed by immersion in cold acetone/methanol (1:1) for 10 minutes and rehydrated through 70% ethanol, 50% ethanol, and PBS. Anti-parafibromin antibody was applied and washed off, followed by Rhodamine Red-conjugated goat antimouse IgG (Jackson ImmunoResearch Lab, West Grove, PA) at 1:100 dilution for 1.5 hours at 37°C. Nuclei were counterstained with 4',6-diamidino-2-phenylindole. In addition, Western blotting was done on COS7 cells transfected with empty pcDNA3 vector and pcDNA3-HRPT2 (Fig. 2). To further characterize parafibromin immunoreactivity, we did immunohistochemical studies in a variety of formalin-fixed paraffin-embedded human tissues, including lung, kidney, testis, thyroid, adrenal, thymus, and lymph nodes.

Immunohistochemistry. Immunohistochemistry was done with standard procedures: deparaffinized 5- μ m sections were steamed in citrate buffer (pH 6) for 30 minutes. Sections were incubated in succession with 0.3% hydrogen peroxide in water for 30 minutes; 5% goat serum for 30 minutes; Avidin D solution for 15 minutes (SP2001, Vector Labs, Burlingame, CA); biotin solution for 15 minutes (SP2001, Vector Labs); primary antibody diluted in diluting buffer (M35, Biomedica Corp., Foster City, CA) at 10 μ g/mL for 1 hour; biotinylated goat antimouse antibody (BA-9200, Vector Labs) at 6 μ g/mL for 1 hour; streptavidin-biotinylated horseradish peroxidase complex (Vectastain Elite kit, PK-6100, Vector Labs) for 30 minutes; diaminobenzidine tetrahydrochloride for 5 minutes and counterstained in hematoxylin for 3 seconds. Sections were washed in 2 cycles of PBS (pH 7.4) between each step. Positive controls were transfected COS7 cells expressing parafibromin. Negative controls included experiments omitting primary antibody and experiments with primary antibody preabsorbed with a 20-fold excess of immunizing peptide. A random selection of duplicate slides were stained by a Dako LV-1 automated immunostainer (Dako, Carpinteria, CA) by a separate author (C.M.) in another laboratory.

Pathologic Evaluation. Slide sections were examined independently by two blinded investigators (C. M. and J. R.). The tissue array was examined unblinded by two investigators, who reached a common agreement. The staining pattern of each specimen was classified in three categories: diffuse positive, focal loss, or diffuse loss. Diffuse positive staining was defined as staining of all parathyroid tissue nuclei; heterogeneity of staining without loss was included in this category. Focal loss was defined as the absence of nuclear staining in variably sized regions. Diffuse loss was defined as the absence of nuclear staining in all tumor tissue. Where staining was diffuse, the overall staining intensity was evaluated on a semi-quantitative

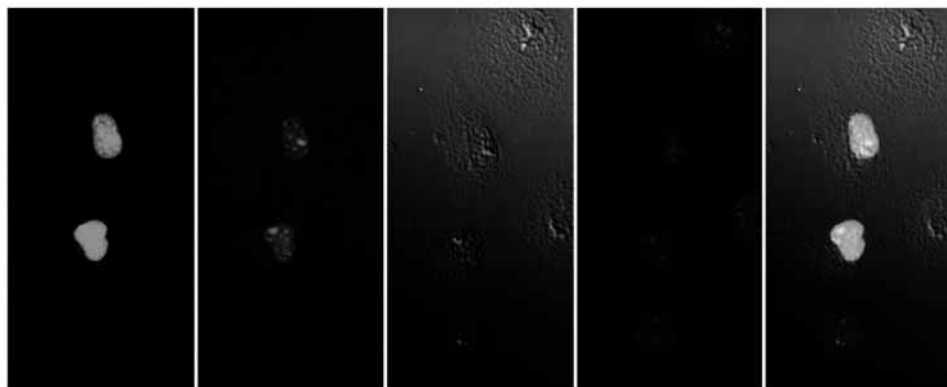


Fig. 1 Confocal images demonstrating co-localization of the GFP-parafibromin fusion protein with anti-parafibromin antibody within the nuclei of transfected HEK293 cells. From left, GFP-parafibromin fusion protein expression (green); anti-parafibromin monoclonal antibody binding, as detected by secondary Rhodamine-Red goat antimouse antibody (red); Nomarski image of cells; 4',6-diamidino-2-phenylindole staining of nuclei (blue); superimposition of all images demonstrating co-localization within nuclei. All images captured with a Zeiss LSM510 META laser-scanning confocal microscope.

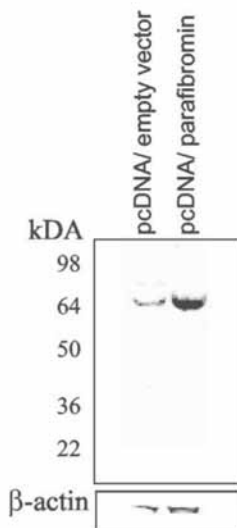


Fig. 2 Western blot showing an increase in parafibromin expression in COS7 cells transfected with pcDNA3-HRP2, compared with cells transfected with empty vector, as detected by anti-parafibromin antibody. β -Actin is shown as control.

scale of 1 to 3, with 1 representing weak staining, 2 moderate staining, and 3 strong staining. A third pathologist (H.M.) provided the tie-breaking assessment, where there was observer disagreement. Calculation of sensitivity and specificity were based on the differentiation of carcinomas from the sporadic benign proliferations of adenoma and hyperplasia. All statistical calculations took into account pathologic reclassification of specimens. Unweighted kappa statistics were used to calculate the inter-observer agreement as to the presence of loss of immunoreactivity, and the calculations were restricted to the full tissue sections that were examined unblinded. Evaluation of all full sections ($n = 123$), including MEN1-related tumors, HPT-JT adenomas, and normal tissue were included in this calculation. Confidence intervals for sensitivity and specificity were calculated by the efficient score method with continuity correction described by Newcombe (35). H&E stained slides of the benign specimens that at least one pathologist assessed as having loss ($n = 6$) were re-evaluated by two independent pathologists.

Sequence Analysis. The ScanProSite program (36) was used to search the PROSITE Release 18.26 database.¹³

RESULTS

Antibody Characterization. The anti-parafibromin monoclonal antibody co-localized with GFP-parafibromin fusion protein in the nuclei of transfected HEK293 cells (Fig. 1). Control cells transfected with GFP-empty vector did not show staining (data not shown). Western blotting done on transfected COS7 cells and empty vector control showed increased intensity of a single crisp band with the expected molecular mass (Fig. 2). We examined a range of human tissues to characterize its range of immunoreactivity and observed that parafibromin immunoreactivity was present in all organs but was cell-type specific (data not shown). Parafibromin was localized to the nucleus in all tissue examined. Controls with antibody pre-absorbed with a 20-fold excess of immunizing peptide did not show any immunoreactivity.

Sequence Analysis. Analysis of the peptide sequence of parafibromin showed the presence of bipartite nuclear localization signal domains at residues 76 to 92 and 393 to 409.

Parathyroid Tissue Immunohistochemistry. We report that parathyroid carcinoma may be distinguished from other benign pathologies by the loss of parafibromin nuclear immunoreactivity (Fig. 3). Table 1 shows individual case evaluation alongside clinicopathologic data for carcinoma cases, and Table 2 shows a summary of the evaluation of all specimens. Eleven benign cases from the adenoma, hyperplasia, and MEN1 tumor groups displayed heterogeneity of staining without absence of parafibromin immunoreactivity, and these were classified as diffusely positive. Loss of parafibromin immunoreactivity for arrayed carcinoma specimens was independent of tissue architecture, frequency of mitoses, Ki-67 index, loss of heterozygosity, cyclin D1 and calcium-sensing receptor immunostaining results. The assay had a calculated sensitivity of 96% [95% confidence interval (CI), 85–99%] and specificity of 99% (95% CI, 92–100%) for differentiating parathyroid carcinoma from sporadic benign proliferations (Table 3). Table 3 also shows the calculated positive predictive values and negative predictive values with confidence intervals for common estimates of prevalence (1% in countries of low reported prevalence, ref. 1; 5% in countries of high reported prevalence, such as Japan and Italy, ref. 3, 4). The data showing inter-observer variation is presented in Table 4. There was exceptional inter-observer agreement with regards to the blinded assessment of any immunoreactivity loss, with an unweighted kappa statistic of 0.89 (95% CI, 0.79–0.98). Agreement with regards to staining pattern was also excellent, with an unweighted kappa statistic of 0.77 (95% CI, 0.65–0.89). The H&E-stained sections of benign specimens that had at least one investigator assess as having a loss of parafibromin immunoreactivity ($n = 6$) were re-evaluated by two pathologists. Two adenomas from separate institutions received revised diagnoses of equivocal, but highly probable, carcinoma based on severe architectural atypia, nuclear atypia, and abundant mitotic figures. Neither case had a family history of parathyroid disease. One of these two cases (Patient 20) had a local relapse on follow-up, and was re-classified as a definite carcinoma. Another specimen, diagnosed previously as met-

¹³ Swiss Institute of Bioinformatics server, Geneva, Switzerland; <http://www.expasy.ch>.

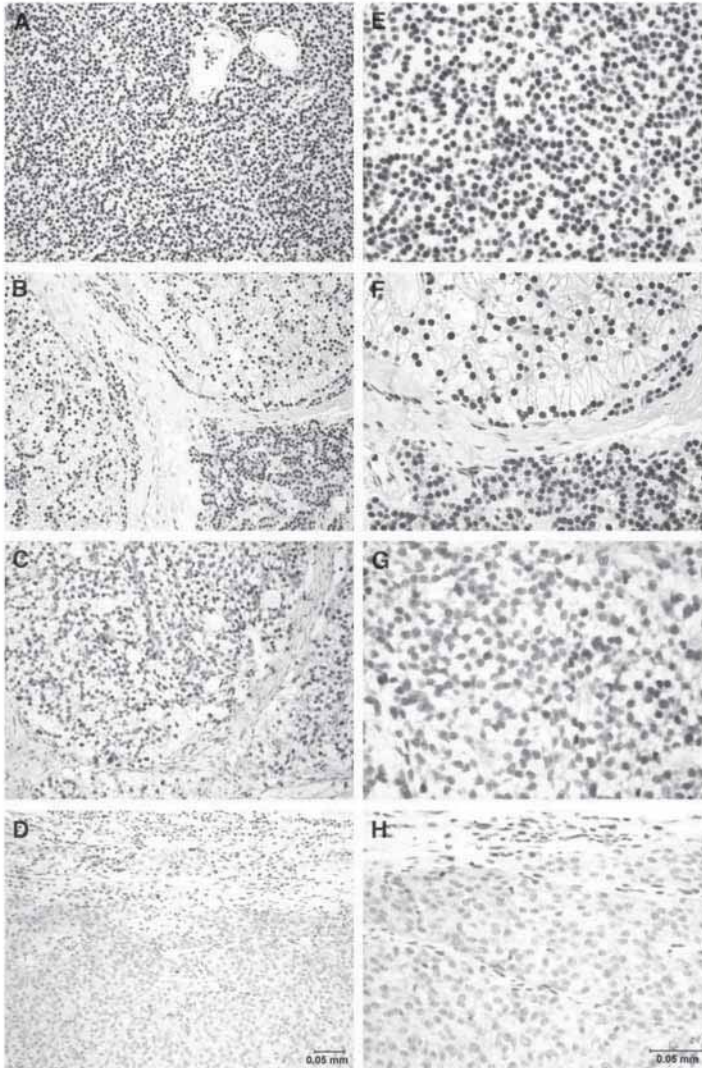


Fig.3 Immunohistochemical staining representing the various staining patterns manifested in the different pathologies through parafibromin immunostaining. *A-D*, magnification, 200 \times . *A*, diffuse staining (primary parathyroid hyperplasia); *B*, diffuse staining (sporadic adenoma with a rim of normal tissue); *C*, focal loss (parathyroid carcinoma); and *D*, diffuse loss (parathyroid carcinoma). *E-H*, higher magnifications of the respective parathyroid pathologies at a magnification of 400 \times . All images were taken with a Spot Insight Camera on a Nikon Eclipse E600.

astatic carcinoma, showed diffuse nuclear immunoreactivity and was shown by parathyroid hormone immunostaining (37) to be of non-parathyroid origin. All but one HPT-JT adenomas exhibited loss of parafibromin immunoreactivity; the remaining one was evaluated as diffusely weak staining by one investigator and by the other as diffuse loss. It is impor-

tant to note that reclassification has been incorporated into all tables and statistical calculations.

DISCUSSION

This is the first study on parafibromin, the protein product of the *HRPT2* tumor suppressor gene. Our results localize hu-

Table 2 Summary of specimen evaluation

Pathology	Total (N = 159)	Loss of immunoreactivity		Diffuse staining		
		Diffuse loss (%)	Focal loss (%)	1 (%)	2 (%)	3 (%)
Definite carcinoma (sections)	22	9 (41)	11 (50)	0 (0)	1 (5)	1 (5)
Definite carcinoma (array)	30	17 (57)	13 (43)	0 (0)	0 (0)	0 (0)
Equivocal carcinoma (sections)	3	0 (0)	0 (0)	1 (33)	0 (0)	2 (67)
Equivocal carcinoma (array)	3	1 (33)	2 (67)	0 (0)	0 (0)	0 (0)
HPT-JT adenomas (sections)	7	4 (57)	2 (29)	1 (14)	0 (0)	0 (0)
HPT-JT adenomas (array)	2	2 (100)	0 (0)	0 (0)	0 (0)	0 (0)
Sporadic adenomas	48	0 (0)	0 (0)	0 (0)	17 (35)	31 (65)
Sporadic primary hyperplasias	25	0 (0)	1 (4)	2 (8)	7 (28)	15 (60)
MEN1-related tumors	13	0 (0)	0 (0)	0 (0)	2 (15)	11 (73)
Normal tissue	6	0 (0)	0 (0)	0 (0)	1 (17)	5 (83)

man parafibromin to the nucleus, which is consistent with peptide sequence analysis, cellular fractionation studies,¹⁴ and immunohistochemistry in a variety of tissues. Parafibromin shares 32% identity with yeast protein cdc73p (15), which is also a nuclear protein and part of the Pafl complex mediating cell cycle regulation and transcription (38). Its function in humans is currently unknown.

Pathologic Assessment. This study shows that parafibromin immunoreactivity is a promising adjunct for differentiating carcinoma from benign tissue. Parathyroid carcinoma is often not recognized, even after histologic examination (2, 7). With the approximately 20% (3 of 15) possibility that apparently sporadic parathyroid carcinoma may be a manifestation of hereditary HPT-JT syndrome (11), making an accurate diagnosis is now paramount. To our knowledge, no other immunohistochemical marker for parathyroid carcinoma has been previously assessed in a study of similar size or geographical diversity. The loss of parafibromin immunoreactivity was true regardless of architecture, presence of mitotic figures, loss of heterozygosity, or immunostaining for Ki67, *CASR*, and cyclin D1. In addition, this study successfully detected the misclassification of two equivocal carcinomas among 50 adenomas, one of which subsequently recurred locally, demonstrating that parathyroid malignancy is often under-recognized.

In the assessment of the value of a diagnostic assay, the positive predictive values and negative predictive value are the most relevant clinically (39). These depend on the prevalence of a disease within a certain population, as well as the sensitivity and specificity. With an estimated prevalence of 1% of primary hyperparathyroidism cases, parafibromin immunostaining has a positive predictive value of 49% (95% CI, 10–100%) and a negative predictive value of 100% (95% CI, 100–100%, with rounding). In countries with a prevalence of 5%, such as Japan and Italy (3, 4), the positive predictive value and negative predictive value would be 83% (95% CI, 36–100%) and 99% (95% CI, 99–100%), respectively. Should these values be validated in additional studies, parafibromin immunostaining is likely to be a helpful diagnostic adjunct for the pathologist. Whereas definite carcinomas may be

recognized on the definitive criteria of invasion or metastasis, tumors that have histopathologic features of malignancy but lack tumor extension represent challenging clinical and pathologic problems. Levin (40) distinguished between “typical” and “atypical adenomas.” Others have chosen to label this group as “equivocal carcinomas” (22, 28). We prefer the terminology “equivocal carcinoma” in the research and clinical setting, as gold-standard pathologic criteria does not accommodate a localized parathyroid carcinoma (2, 27, 40). Considering such patients as having “equivocal carcinomas” is also logical clinically, because they are followed up in a similar fashion as patients with definite parathyroid carcinoma (27, 41). Thus, this terminology is more appropriate in view of the potential malignant behavior of these group of tumors, the under-recognition of carcinoma, and the fact that current gold-standard diagnostic criteria of malignancy of invasion or metastasis is limited to advanced disease. Our results support the view that this entity termed “equivocal carcinoma” is heterogeneous (40). Of the five cases initially diagnosed as equivocal carcinomas, three displayed loss of parafibromin immunoreactivity. No cases showing parafibromin immunoreactivity relapsed. In addition, two cases initially diagnosed as adenomas were subsequently reclassified pathologically as equivocal carcinomas after parafibromin immunostaining and re-evaluation. One case relapsed locally on follow-up and was reclassified clinically as a definite carcinoma. The

Table 3 Calculated diagnostic value indices

Diagnostic indices	Value/%
Sensitivity (95% CI)	96 (86–99)
Specificity (95% CI)	99 (92–100)
Positive predictive value at 1% prevalence (95% CI)	49 (10–100)
Negative predictive value at 1% prevalence (95% CI)	100 (100–100)
Positive predictive value at 5% prevalence (95% CI)	83 (36–100)
Negative predictive value at 5% prevalence (95% CI)	100 (99–100)

Table 4 Results of blinded individual observer evaluation for all sections (N = 123)

Staining patterns	Pathologist 1		
	Diffusely positive	Focal loss	Diffuse loss
Pathologist 2			
Diffusely positive	92	1	1
Focal loss	3	8	1
Diffuse loss	0	5	12

¹⁴ C. Zhang, D. Pappas, M-H. Tan, C. N. Qian, J. D. Chen, D. Kong, C. F. Gao, H. M. Koo, M. Weinreich, B. O. Williams, B. T. Teh, unpublished results.

classification of this case by parafibromin immunoreactivity shows a utility exceeding that of current gold-standard criteria, which is restricted to advanced disease. From a clinical point of view, such a utility is highly desirable, as current gold-standard criteria only define advanced disease, but surgical intervention is most appropriate with localized disease (2, 3, 6, 14). In addition, this result suggests that parafibromin loss occurs at an early stage.

Adenomas with *HRPT2* mutations also shows diffuse loss of parafibromin immunoreactivity in our study. These occur at a very low frequency in sporadic parathyroid adenomas (15, 16). However, the loss of parafibromin immunoreactivity is useful in detecting these tumors. For patients with HPT-JT syndrome who are at high risk of carcinoma, deliberate total prophylactic parathyroidectomy has been considered (42). Whether radical surgery will benefit the rare patient who has had a somatic *HRPT2* mutation detected in a parathyroid adenoma remains uncertain.

HRPT2 Mutation and Parafibromin Loss. Fifty of fifty-two definite parathyroid carcinomas displayed loss of parafibromin immunoreactivity. This is consistent with the high rate of somatic *HRPT2* gene mutations with biallelic inactivation reported in sporadic parathyroid carcinoma (11, 16). HPT-JT syndrome is characterized by *HRPT2* gene mutations, and patients with HPT-JT syndrome have a high risk of parathyroid carcinoma (15, 16). In conjunction with microarray studies showing a common gene signature for parathyroid carcinomas and HPT-JT-related adenomas, the loss of parafibromin immunoreactivity in both groups suggests that parafibromin down-regulation is an early and pivotal step in parathyroid tumorigenesis. It was interesting that focal expression of parafibromin was retained in a small subset of parathyroid adenomas with documented *HRPT2* gene mutations. It was observed that in tumors with focal loss of parafibromin immunoreactivity, parafibromin expression was markedly higher near blood vessels and margins (both internal and external) such as fibrous septa and capsular tissue (data not shown). Whether the antibody was binding to wild-type or mutant parafibromin remains uncertain. A small subset of carcinomas display normal parafibromin expression. This may be because of alternative tumorigenic mechanisms, and there is evidence that at least one additional tumor suppressor gene may exist on chromosome 13q (25, 43–46). A recent study of two such candidate genes, *RB* and *BRC42*, did not identify any mutations in seven specimens of parathyroid carcinoma (47). Parathyroid carcinoma is a rare manifestation in *MEN1* (48, 49), but our study showed normal parafibromin expression in *MEN1*-related benign tumors.

Study Limitations. The evaluation of immunohistochemically stained slides is inherently subjective, with considerable observer dependence. To address this, two observers independently evaluated the slides. The calculated inter-observer agreement was excellent for assessment of parafibromin loss, with a kappa statistic of 0.89. However, one limitation of our study was the risk of subconscious bias. Although the diagnoses were blinded, vascular or local tissue invasion may have been visible on inspection. However, we conclude that any biases are unlikely to be substantial as the majority of benign cases stain with either moderate or strong intensity, rather than with weak staining (Table 2). Additionally, adenomas with HPT-JT mutations were uniformly diagnosed with loss of parafibromin immunoreactivity, whereas adenomas without these mutations were not.

CONCLUSION

Parafibromin immunostaining is a promising adjunct for the diagnosis of parathyroid carcinoma, an often unrecognized entity that may be hereditary (11). This recognition of carcinoma is critical for genetic screening (13), and our results provide direct evidence that carcinoma may not be recognized during initial histopathologic evaluation. Because en-bloc resection constitutes definitive therapy for parathyroid carcinoma and 86% of carcinomas may not be detected intraoperatively (6), studying the intra-operative assessment of parafibromin immunoreactivity through ultrarapid immunostaining (50) would be logical. Finally, the shared loss of parafibromin between parathyroid carcinoma and HPT-JT-related adenomas, alongside evidence of a common gene expression signature (32), suggests novel tumorigenesis pathways mediated by the *HRPT2* gene.

ACKNOWLEDGMENTS

The authors dedicate this report to the late Dr. J. J. Shepherd of the University of Tasmania.

REFERENCES

- Grimelius L, Johansson H. Pathology of parathyroid tumors. *Semin Surg Oncol* 1997;13:142–54.
- Shane E. Clinical review 122: parathyroid carcinoma. *J Clin Endocrinol Metab* 2001;86:485–93.
- Obata T, Okamoto T, Kanbe M, Iihara M. Functioning parathyroid carcinoma: clinicopathologic features and rational treatment. *Semin Surg Oncol* 1997;13:134–41.
- Favia G, Lumachi F, Polistina F, D'Amico DF. Parathyroid carcinoma: sixteen new cases and suggestions for correct management. *World J Surg* 1998;22:1225–30.
- Haven CJ, van Puijtenbroek M, Karperien M, Fleuren GJ, Morreau H. Differential expression of the calcium sensing receptor and combined loss of chromosomes 1q and 11q in parathyroid carcinoma. *J Pathol* 2004;202:86–94.
- Hundahl SA, Fleming ID, Fremgen AM, Menck HR. Two hundred eighty-six cases of parathyroid carcinoma treated in the U.S. between 1985–1995: a National Cancer Data Base Report. The American College of Surgeons Commission on Cancer and the American Cancer Society. *Cancer (Phila)* 1999;86:538–44.
- Dotzenrath C, Goretzki PE, Sarbia M, Cupisti K, Feldkamp J, Rother HD. Parathyroid carcinoma: problems in diagnosis and the need for radical surgery even in recurrent disease. *Eur J Surg Oncol* 2001;27:383–9.
- Sandelin K, Tullgren O, Farnebo LO. Clinical course of metastatic parathyroid cancer. *World J Surg* 1994;18:594–8; discussion 599.
- Hara H, Oyama T, Kimura M, et al. Cytologic characteristics of parathyroid carcinoma: a case report. *Diagn Cytopathol* 1998;18:192–8.
- Wells SA Jr, DeBenedetti MK, Doherty GM. Recurrent or persistent hyperparathyroidism. *J Bone Miner Res* 2002;17(Suppl 2):N158–62.
- Shattuck TM, Valimaki S, Obata T, et al. Somatic and germ-line mutations of the *HRPT2* gene in sporadic parathyroid carcinoma. *N Engl J Med* 2003;349:1722–9.
- Jackson CE, Norum RA, Boyd SB, et al. Hereditary hyperparathyroidism and multiple ossifying jaw fibromas: a clinically and genetically distinct syndrome. *Surgery* 1990;108:1006–12; discussion 1012–3.
- Weinstein LS, Simonds WF. *HRPT2*, a marker of parathyroid cancer. *N Engl J Med* 2003;349:1691–2.
- Clayman GL, Gonzalez HE, El-Naggag A, Vassilopoulos-Sellin R. Parathyroid carcinoma: evaluation and interdisciplinary management. *Cancer (Phila)* 2004;100:900–5.
- Caprari JD, Robbins CM, Villablanca A, et al. *HRPT2*, encoding parafibromin, is mutated in hyperparathyroidism-jaw tumor syndrome. *Nat Genet* 2002;32:676–80.

16. Howell VM, Haven CJ, Kahnoski K, et al. HRPT2 mutations are associated with malignancy in sporadic parathyroid tumours. *J Med Genet* 2003;40:657-63.
17. Schantz A, Castleman B. Parathyroid carcinoma. A study of 70 cases. *Cancer (Phila)* 1973;31:600-5.
18. Naccarato AG, Marcocci C, Miccoli P, et al. Bel-2, p53 and MIB-1 expression in normal and neoplastic parathyroid tissues. *J Endocrinol Invest* 1998;21:136-41.
19. Stojadinovic A, Hoos A, Nissan A, et al. Parathyroid neoplasms: clinical, histopathological, and tissue microarray-based molecular analysis. *Hum Pathol* 2003;34:54-64.
20. Erickson LA, Jin L, Papotti M, Lloyd RV. Oxyphil parathyroid carcinomas: a clinicopathologic and immunohistochemical study of 10 cases. *Am J Surg Pathol* 2002;26:344-9.
21. Erickson LA, Jin L, Wollan P, Thompson GB, van Heerden JA, Lloyd RV. Parathyroid hyperplasia, adenomas, and carcinomas: differential expression of p27Kip1 protein. *Am J Surg Pathol* 1999;23:288-95.
22. Farnebo F, Auer G, Farnebo LO, et al. Evaluation of retinoblastoma and Ki-67 immunostaining as diagnostic markers of benign and malignant parathyroid disease. *World J Surg* 1999;23:68-74.
23. Lloyd RV, Carney JA, Ferreiro JA, et al. Immunohistochemical analysis of the cell cycle-associated antigens Ki-67 and retinoblastoma protein in parathyroid carcinomas and adenomas. *Endocr Pathol* 1995;6:279-87.
24. Vargas MP, Vargas HI, Kleiner DE, Merino MJ. The role of prognostic markers (MIB-1, RB, and bel-2) in the diagnosis of parathyroid tumors. *Mod Pathol* 1997;10:12-7.
25. Cryns VL, Thor A, Xu HJ, et al. Loss of the retinoblastoma tumor-suppressor gene in parathyroid carcinoma. *N Engl J Med* 1994;330:757-61.
26. Cetani F, Pardi E, Viacava P, et al. A reappraisal of the Rb1 gene abnormalities in the diagnosis of parathyroid cancer. *Clin Endocrinol (Oxf)* 2004;60:99-106.
27. Levin KE, Chew KL, Ljung BM, Mayall BH, Siperstein AE, Clark OH. Deoxyribonucleic acid cytometry helps identify parathyroid carcinomas. *J Clin Endocrinol Metab* 1988;67:779-84.
28. Bondeson L, Sandelin K, Grimelius L. Histopathological variables and DNA cytometry in parathyroid carcinoma. *Am J Surg Pathol* 1993;17:820-9.
29. August DA, Flynn SD, Jones MA, Bagwell CB, Kinder BK. Parathyroid carcinoma: the relationship of nuclear DNA content to clinical outcome. *Surgery* 1993;113:290-6.
30. Obara T, Fujimoto Y, Kanaji Y, et al. Flow cytometric DNA analysis of parathyroid tumors. Implication of aneuploidy for pathologic and biologic classification. *Cancer (Phila)* 1990;66:1555-62.
31. Sandelin K, Auer G, Bondeson L, Grimelius L, Farnebo LO. Prognostic factors in parathyroid cancer: a review of 95 cases. *World J Surg* 1992;16:724-31.
32. Haven CJ, Howell VM, Eilers PHC, Dunne R, Takahashi M, van Puijnenbroek M, Furge KA, Tan MH, Kievit J, Fleuren GJ, Robinson BG, Delbridge LW, Philips J, Nelson AE, Krause U, Dralle H, Hoang-Vu C, Gimm O, Morreau H, Marsh DJ, Teh BT. Gene expression of parathyroid tumors: molecular subclassification and identification of the potential malignant phenotype. *Cancer Research* (in press).
33. Kononen J, Bubendorf L, Kallioniemi A, et al. Tissue microarrays for high-throughput molecular profiling of tumor specimens. *Nat Med* 1998;4:844-7.
34. Haven CJ, Wong FK, van Dam EW, et al. A genotypic and histopathological study of a large Dutch kindred with hyperparathyroidism-jaw tumor syndrome. *J Clin Endocrinol Metab* 2000;85:1449-54.
35. Newcombe RG. Two-sided confidence intervals for the single proportion: comparison of seven methods. *Stat Med* 1998;17:857-72.
36. Gattiker A, Gasteiger E, Bairoch A. ScanProsite: a reference implementation of a PROSITE scanning tool. *Appl Bioinformatics* 2002;1:107-8.
37. Sawady J, Mendelsohn G, Sirota RL, Taxy JB. The intrathyroidal hyperfunctioning parathyroid gland. *Mod Pathol* 1989;2:652-7.
38. Shi X, Chang M, Wolf AJ, et al. Cdc73p and Paf1p are found in a novel RNA polymerase II-containing complex distinct from the Srbp-containing holoenzyme. *Mol Cell Biol* 1997;17:1160-9.
39. Jaeschke R, Guyatt GH, Sackett DL. Users' guides to the medical literature. III. How to use an article about a diagnostic test. B. What are the results and will they help me in caring for my patients? The Evidence-Based Medicine Working Group. *JAMA* 1994;271:703-7.
40. Levin KE, Galante M, Clark OH. Parathyroid carcinoma versus parathyroid adenoma in patients with profound hypercalcemia. *Surgery* 1987;101:649-60.
41. Goshen O, Aviel-Ronen S, Dori S, Talmi YP. Brown tumour of hyperparathyroidism in the mandible associated with atypical parathyroid adenoma. *J Laryngol Otol* 2000;114:302-4.
42. Marx SJ, Simonds WF, Agarwal SK, et al. Hyperparathyroidism in hereditary syndromes: special expressions and special managements. *J Bone Miner Res* 2002;17(Suppl 2):N37-43.
43. Dotzenrath C, Teh BT, Farnebo F, et al. Allelic loss of the retinoblastoma tumor suppressor gene: a marker for aggressive parathyroid tumors? *J Clin Endocrinol Metab* 1996;81:3194-6.
44. Pearce SH, Trump D, Wooding C, Sheppard MN, Clayton RN, Thakker RV. Loss of heterozygosity studies at the retinoblastoma and breast cancer susceptibility (BRCA2) loci in pituitary, parathyroid, pancreatic and carcinoid tumours. *Clin Endocrinol (Oxf)* 1996;45:195-200.
45. Kytola S, Farnebo F, Obara T, et al. Patterns of chromosomal imbalances in parathyroid carcinomas. *Am J Pathol* 2000;157:579-86.
46. Yoshimoto K, Endo H, Tsuyuguchi M, et al. Familial isolated primary hyperparathyroidism with parathyroid carcinomas: clinical and molecular features. *Clin Endocrinol (Oxf)* 1998;48:67-72.
47. Shattuck TM, Kim TS, Costa J, et al. Mutational analyses of RB and BRCA2 as candidate tumour suppressor genes in parathyroid carcinoma. *Clin Endocrinol (Oxf)* 2003;59:180-9.
48. Dionisi S, Minisola S, Pepe J, et al. Concurrent parathyroid adenomas and carcinoma in the setting of multiple endocrine neoplasia type 1: presentation as hypercalcemic crisis. *Mayo Clin Proc* 2002;77:866-9.
49. Sato M, Miyauchi A, Namiura H, et al. A newly recognized germline mutation of MEN1 gene identified in a patient with parathyroid adenoma and carcinoma. *Endocrine* 2000;12:223-6.
50. Richter T, Nahrig J, Komminoth P, Kowolik J, Werner M. Protocol for ultrarapid immunostaining of frozen sections. *J Clin Pathol* 1999;52:461-3.

