



Universiteit
Leiden
The Netherlands

Molecular discrimination of sessile rectal adenomas from carcinomas for a better treatment choice: integration of chromosomal instability patterns and expression array analysis

Lips, E.H.

Citation

Lips, E. H. (2008, June 19). *Molecular discrimination of sessile rectal adenomas from carcinomas for a better treatment choice: integration of chromosomal instability patterns and expression array analysis*. Retrieved from <https://hdl.handle.net/1887/12962>

Version: Corrected Publisher's Version

License: [Licence agreement concerning inclusion of doctoral thesis in the Institutional Repository of the University of Leiden](#)

Downloaded from: <https://hdl.handle.net/1887/12962>

Note: To cite this publication please use the final published version (if applicable).

CHAPTER 7

**Concluding remarks and implications
for further research**

Molecular staging of large sessile rectal tumors

In this thesis, we sought to apply molecular analysis for a better preoperative evaluation of large sessile, often villous, rectal tumors that might be added to analyses by standard histology, endorectal ultrasound, and MRI/CT. Such combinations of analyses should lead to an optimal treatment strategy for the individual patient and thus a more informed choice of a sparing transanal endoscopic microsurgery (TEM) or a more radical total mesorectal excision (TME). Five genomic markers were identified; together, these build a rectal cancer progression model. These markers were able to discriminate rectal adenomas from rectal carcinomas. Most importantly, they might be able to identify the aggressiveness of rectal tumors, which could not be identified by alternative means. We also showed that SNP array analysis is feasible for small, formalin-fixed, paraffin-embedded (FFPE) biopsies, which is a prerequisite for a possible future clinical application.

The next step will now be to determine the sensitivity and specificity of the proposed genomic test. This test should assess numerical aberrations of chromosomes 1q, 8q, 13q, 17p, 18q, and 20q in combination with immunohistochemistry (IHC) for SMAD4 and p53 on at least three preoperative biopsies per tumor. Chromosome 1q is added to address the possibility of lymph node metastasis. Those analyses should be performed in parallel and supplementary to standard preoperative procedures involving histology and imaging techniques.

A possible decision scheme could be envisaged as outlined in Figure 1. In this scheme, a distinction is made between presumed adenomas and carcinomas. Several additional research questions are also posed. In the case that imaging does not identify invasion beyond the muscularis mucosae and standard histology shows villous adenoma (either low- or high-grade dysplastic), the genomic profile might guide further treatment. When less than two “malignant” aberrations (including IHC results) are found, the chance to find carcinoma (T1 or more) in the final resection specimen is low, and so TEM can be safely chosen.

However, a tumor with two or more “malignant” aberrations (including IHC) presents a higher chance of containing a carcinoma focus. The latter profile would still rule out TME, since imaging did not identify malignancy. A TEM procedure preoperatively combined with additional therapies (neoadjuvant chemotherapy, radiotherapy, treatment with small molecules such as receptor tyrosine kinase inhibitors, etc.) should be discussed in order to prevent local recurrences of TEM-operated T1 carcinomas. In cases of recurrence after TEM for a carcinoma, immediate salvage therapy by TME seems possible. A prerequisite is an intensive follow-up every 3-4 months to diagnose local recurrences at an early stage. However, prior TEM procedures may have adverse effects on a subsequent TME treatment (1). Also, patients’ satisfaction is impeded by this unexpected histopathological finding and the need for additional surgery (2).

When preoperative histology and imaging both indicate a carcinoma, the golden standard is TME combined with preoperative radiotherapy, although alternatives are currently under discussion (as discussed later in this chapter). When imaging shows an adenoma but histology shows an (intramucosal) carcinoma, the tumor is considered to be an adenoma with high-grade dysplasia (according to current WHO guidelines) and will fall into the adenoma decision branch.

Considerations for rectal cancer treatment

As mentioned before, TME in combination with preoperative radiotherapy is the golden standard for carcinomas. The introduction of this method has led to a decline in recurrence rates for rectal cancer (3). Analyses of T1 and T2 patients of the TME trial showed that local recurrences are rare in this group, and radiotherapy does not have added value (3). Also, major surgery with lymphadenectomy implies over-treatment in most early-cancer patients, as lymph node metastasis percentages are low in T1 tumors. For these reasons, local resection with TEM is tempting. Local excision is also preferred for patients at high risk for complications involved in a major surgery. TEM for those patients would imply a major step in reducing morbidity associated with TME surgery and radiotherapy. However, recurrence rates after local excision for carcinomas are considerable, ranging from 0-14% for T1 tumors to 0-50% for T2 tumors (4). The addition of adjuvant chemoradiotherapy to local excision can diminish these figures (5). The frequency of local recurrence is significantly higher for patients with incomplete resection margins (6). Lymph node metastasis is not frequent in these early carcinomas, but percentages ranging from 10% for T1 cases up to 40% for T2 cases are observed (4).

Lezoche *et al.* evaluated the use of TEM for T2 and T3 tumors following neoadjuvant therapy as an alternative to major surgery (7). Local recurrence and survival figures were comparable to conventional surgery. The advantages of such a treatment are low morbidity and good quality of life after treatment. However, the authors claim that this approach should only be applied to selected patients with small lymph node-negative tumors that respond to neoadjuvant radiochemotherapy. The results of randomized clinical trials should be evaluated before application of such experimental treatments.

The above mentioned developments in rectal cancer treatment stress the necessity for accurate staging. In a current study by our group, T1 carcinomas with a local recurrence are compared with recurrence-free samples to search for applicable invasion markers. For LN metastasis, additional markers should be found in a large series containing many lymph node-positive samples. It should be investigated for which T1 tumors, identified after TEM, a wait and see option could be safely chosen to spare those patients the adverse side effects of TME surgery. For T1 and T2 carcinomas, identified by preoperative evaluation, TEM

combined with neoadjuvant therapy might be considered as an alternative to the TME procedure in the near future.

Improvements in imaging

Endorectal ultrasound (ERUS) seems to be the most suitable method to assess the T stage accurately in superficial lesions (8, 9). ERUS is especially feasible for superficial rectal tumors. For more advanced stages, CT or MRI is better in assessing tumor invasion depth. ERUS also proved able to discriminate rectal adenomas from invasive carcinomas, and T1 from T2 stages. However, ERUS is not feasible in 11-34% of rectal tumors, depending on the location of the tumor. Another serious problem of ERUS is over-staging, with a recent manuscript showing 4% over-staging (10). This underlines again the importance of finding new preoperative parameters for rectal cancer staging.

MRI with ultrasmall superparamagnetic iron oxide (USPIO) might offer a new diagnosis modality for positive lymph node detection. The first studies of MRI combined with USPIO have now been performed, but the results need to be confirmed in other studies (11,12, 13).

Conclusion

Recent advances in rectal tumor treatment have shown the need for accurate staging. This thesis showed the potential of molecular markers to be used in the staging of early rectal tumors. Together with new developments in preoperative imaging, the aggressive behavior of the tumor to be resected might be determined more precisely. Thus, future diagnostics will involve a combination of standard histopathology, new imaging modalities, and molecular markers. This will be a step towards “tailor-made” treatments for rectal lesions.

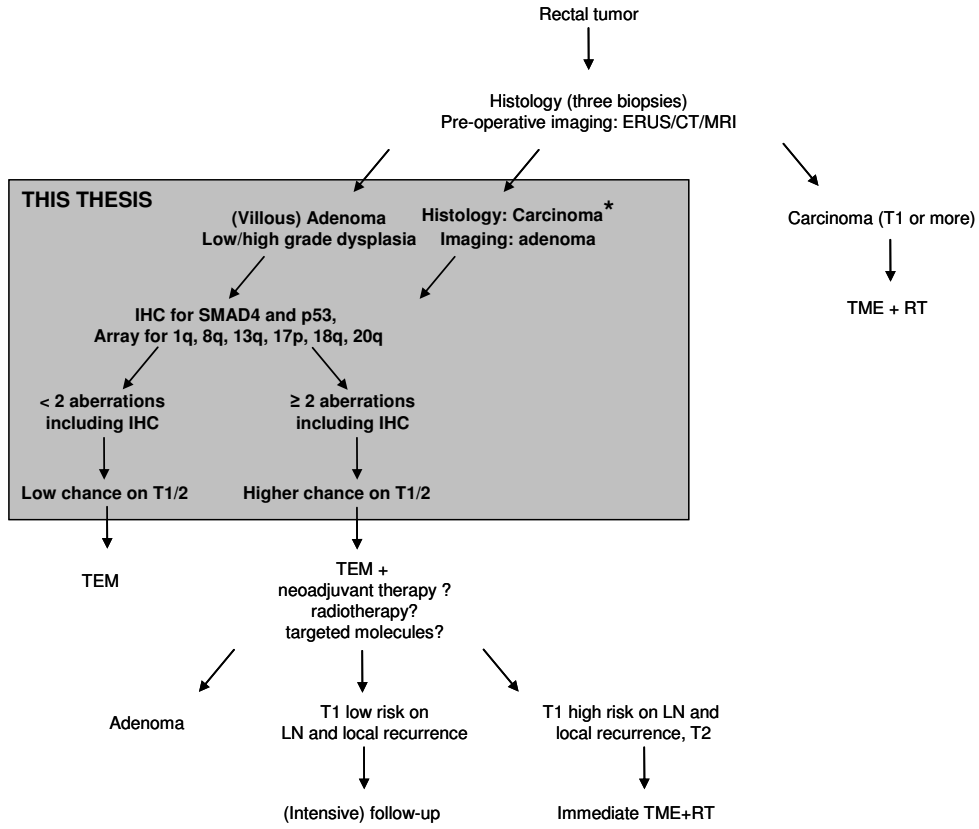


Figure 1. Possible future scenario for treatment of rectal tumors.

* Formerly intramucosal carcinoma or carcinoma in situ.

References

1. Hahnloser D, Wolff BG, Larson DW, et al.: Immediate radical resection after local excision of rectal cancer: an oncologic compromise? *Dis Colon Rectum* 48:429-437, 2005
2. Doornebosch PG, Tollenaar RA, Gosselink MP, et al.: Quality of life after transanal endoscopic microsurgery and total mesorectal excision in early rectal cancer. *Colorectal Dis* 9:553-558, 2007
3. Kapiteijn E, Marijnen CA, Nagtegaal ID, et al.: Preoperative radiotherapy combined with total mesorectal excision for resectable rectal cancer. *N Engl J Med* 345:638-646, 2001
4. Maslekar S, Beral DL, White TJ, et al.: Transanal endoscopic microsurgery: where are we now? *Dig Surg* 23:12-22, 2006
5. Sengupta S, Tjandra JJ: Local excision of rectal cancer: what is the evidence? *Dis Colon Rectum* 44:1345-1361, 2001
6. Quirke P, Durdey P, Dixon MF, et al.: Local recurrence of rectal adenocarcinoma due to inadequate surgical resection. Histopathological study of lateral tumour spread and surgical excision. *Lancet* 2:996-999, 1986
7. Lezoche E, Guerrieri M, Paganini AM, et al.: Long-term results in patients with T2-3 N0 distal rectal cancer undergoing radiotherapy before transanal endoscopic microsurgery. *Br J Surg* 92:1546-1552, 2005
8. Beets-Tan RG, Beets GL: Rectal cancer: review with emphasis on MR imaging. *Radiology* 232:335-346, 2004
9. Bipat S, Glas AS, Slors FJ, et al.: Rectal cancer: local staging and assessment of lymph node involvement with endoluminal US, CT, and MR imaging--a meta-analysis. *Radiology* 232:773-783, 2004
10. Doornebosch PG, Bronkhorst PJ, Hop WC, et al.: The Role of Endorectal Ultrasound in Therapeutic Decision-Making for Local vs. Transabdominal Resection of Rectal Tumors. *Dis Colon Rectum*, 2007
11. Harisinghani MG, Barentsz J, Hahn PF, et al.: Noninvasive detection of clinically occult lymph-node metastases in prostate cancer. *N Engl J Med* 348:2491-2499, 2003
12. Koh DM, Brown G, Temple L, et al.: Rectal cancer: mesorectal lymph nodes at MR imaging with USPIO versus histopathologic findings--initial observations. *Radiology* 231:91-99, 2004
13. Bellin MF, Roy C, Kinkel K, et al.: Lymph node metastases: safety and effectiveness of MR imaging with ultrasmall superparamagnetic iron oxide particles--initial clinical experience. *Radiology* 207:799-808, 1998