



Universiteit
Leiden
The Netherlands

Non-invasive diagnosis and follow-up of right ventricular overload

Henkens, I.R.

Citation

Henkens, I. R. (2008, November 20). *Non-invasive diagnosis and follow-up of right ventricular overload*. Retrieved from <https://hdl.handle.net/1887/13265>

Version: Corrected Publisher's Version

License: [Licence agreement concerning inclusion of doctoral thesis in the Institutional Repository of the University of Leiden](#)

Downloaded from: <https://hdl.handle.net/1887/13265>

Note: To cite this publication please use the final published version (if applicable).

I

INTRODUCTION

Introduction

Right ventricular overload can be described as a situation in which the normal limits of right ventricular dimensions or stroke work are exceeded. Such a condition can be of sudden onset, leading to acute overload (e.g. in pulmonary embolism) or of gradual onset, leading to subacute or chronic right ventricular overload. Theoretically, right ventricular overload can be limited to volume or pressure overload alone, but in general these conditions accompany one another to a certain extent. To understand the effect of the dominant mechanism of overload, i.e. pressure or volume overload, one must be familiar with the normal anatomy and function of the right ventricle. Suspecting right ventricular overload is the first step towards its diagnosis. Using the correct tools will assure adequate diagnosis, and will allow for unambiguous follow-up of the observed abnormalities. It is important to be familiar with the natural history of right ventricular overload. This introduction will focus on normal and pathological right ventricular anatomy before and after surgery, prenatal and postnatal physiology, pathophysiology, functional assessment, and the consequences of right ventricular failure.

General anatomy of the right ventricle

The right ventricle, positioned in the thoracic cavity directly behind the sternum, lies to the front and to the right of the left ventricle. In series with the left ventricle, the right ventricle generates the same output directed towards the lungs, aimed at blood re-oxygenation. Blood enters the right ventricular cavity once it passes the tricuspid annulus, and leaves the right ventricular cavity through the pulmonary valve. The three cusps of the tricuspid valve are connected to the septum, and the anterolateral and posterolateral walls of the right ventricle by their chordae tendinae and papillary muscles [1]. The semilunar cusps of the pulmonary valve resemble the cusps of the aortic valve, closing passively as blood pressure in the pulmonary artery exceeds right ventricular pressure. The right ventricle has three characteristic properties, which allow it to be distinguished morphologically from the left ventricle. Firstly, the right ventricle is identified by its tricuspid atrio-ventricular valve with one septal insertion, whereas the left ventricle with its bicuspid mitral valve has two opposing groups of papillary muscles inserted in the free wall. Secondly, the right ventricle has a trabeculated myocardium, especially towards the apex. The left ventricular myocardium, in contrast, is more solid. Finally, the right ventricle contains a muscular band of heart tissue running from the base of the anterior papillary muscle to the interventricular septum, called the septomarginal trabeculae or moderator band [1]. These characteristics often help identify

the right ventricle in echocardiography or magnetic resonance imaging in situations where both ventricles are comparable in size due to right ventricular overload. The right ventricle, by many physicians overlooked or seen as a separate entity, in fact shares many features with the left ventricle. Contained by the pericardial sac, the ventricles contract virtually at the same time, activated by their common conductance system and individual bundle branches and Purkinje fibers. The sole right ventricular bundle branch is often affected in right heart disease. However, in the general population too, depending on the age group observed, a right bundle branch block can be found in otherwise healthy subjects [2-4]. The interventricular septum is an essential part of both ventricles' contractile system [5]. Under physiological conditions, however, the left ventricle intracavitary pressure exceeds that of the right ventricle by far during systole (and by little during diastole), generating a globular shape of the left ventricular, with the right ventricle almost wrapped around it [6]. The fibrous skeleton of the heart, lying mainly around the heart valves, not only functions as an electrically inert barrier between atria and ventricles, but also forms a solid base when ventricular contraction brings the apex inward [7]. The muscle array of the heart, aligned for optimal conduction times and contraction efficiency, is such that during contraction the heart shortens along its longitudinal axis, and twists at the same time, effectively wringing most of the blood out of the ventricular cavities [8]. Since the pulmonary circulation is a low-resistance system, right ventricular oxygen consumption per gram of myocardium is normally only approximately half of left ventricular oxygen consumption per gram of myocardium [9-11]. Generally speaking, the left ventricle is predominantly supplied by the left coronary artery, while the right coronary artery generally supplies the right atrium and sinus node, the right ventricle, and the left ventricular wall and part of the apex [9, 11].

Anatomy in tetralogy of Fallot

Patients with a tetralogy of Fallot have four explicit coinciding features of the heart, first reported by Etienne-Louis Arthur Fallot in 1888. Dr. Fallot was able to understand the clinical consequences of the observed four cardiac abnormalities: a ventricular septum defect under the aortic root, a right ventricular outflow tract obstruction (with a generally abnormal pulmonary valve and underdeveloped pulmonary vasculature), an 'overriding' aorta (the aorta is positioned more rightward, receiving blood from both ventricles), and right ventricular hypertrophy (Figure 1). Consequently, blood can travel freely between both ventricles in favor of the pulmonary or systemic circulation, depending on vascular resistance, and the right ventricular outflow tract pressure gradient [12, 13]. The fact that there is relatively uninhibited flow between the ventricles signifies that there is a pressure equilibrium between

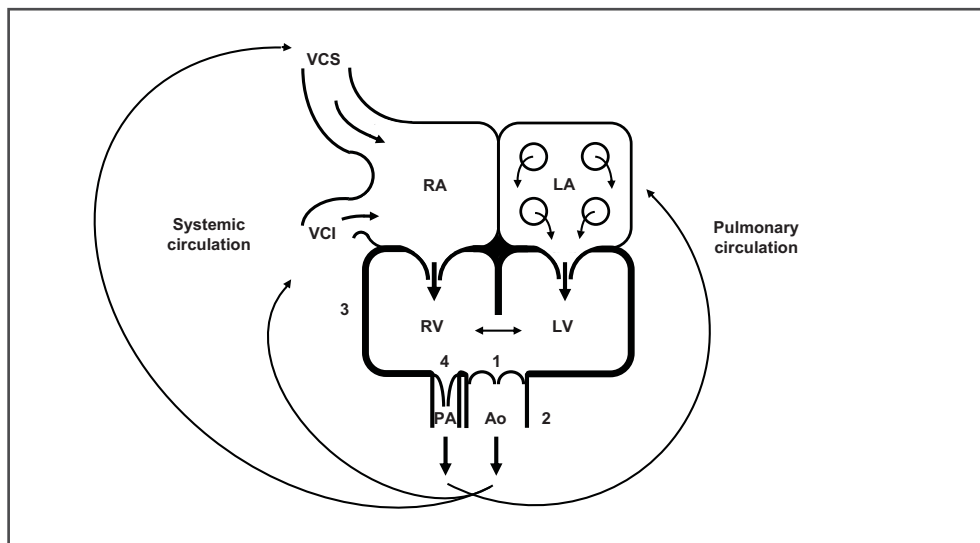


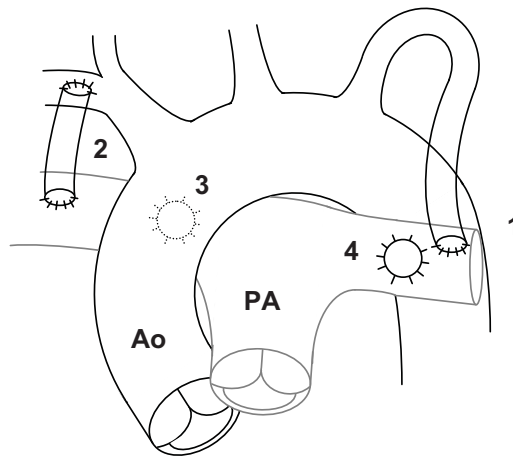
Figure 1

Schematic outline of the Fallot anatomy and circulation: there is a ventricular septal defect (1) located under the aorta (2), which 'overrides' the septum and hence there is a pressure equilibrium between the right and left ventricle, preventing loss of prenatal right ventricular hypertrophy (3: right ventricular wall thickness equals left ventricular wall thickness). The degree of right ventricular outflow tract stenosis (4: infundibular and pulmonary valve stenosis) then determines the balance between the pulmonary and systemic circulation. RA=right atrium, LA=left atrium, RV=right ventricle, LV=left ventricle, PA=pulmonary artery, Ao=aorta, VCI=inferior vena cava, VCS=superior vena cava. Shortly after birth Fallot patients may present as 'blue babies' in cases where (sub)pulmonary stenosis is severe, and desaturated blood will flow towards the systemic circulation more easily. In patients with a less severe (sub)pulmonary stenosis, pulmonary blood flow may exceed systemic blood flow, but there may also be a more or less 'balanced circulation'. In the latter situation, the pressure gradient over the right ventricular outflow tract - i.e. the pressure drop, - is such that equal volumes of blood flow through the pulmonary and systemic circulation. Only in situations where pulmonary vascular resistance increases, will pink babies present with cyanosis. This is typically the case during feeding, or when a baby is crying. In the case of feeding, heart rate increases and systemic vascular resistance decreases, allowing desaturated blood to flow more easily towards the systemic circulation. A similar phenomenon occurs during crying, when a rise in intrathoracic pressures increases pulmonary vascular resistance even more.

the ventricles, which inhibits postnatal decline of relative right ventricular muscle mass [14]. This explains the right ventricular hypertrophy in Fallot patients. Due to the septal defect and an incomplete or malalignment of the endocardial cushions, the aorta is said to override the septum. The aorta therefore directly receives a mix of blood from the right and left ventricle (Figure 1).

Early surgical correction in tetralogy of Fallot

The objective of early surgical correction is to separate the pulmonary and systemic circulation, and to relieve right ventricular outflow tract stenosis, in order to prevent right ventricular failure [12]. There has been considerable progress in surgical techniques over the years. Initially, Fallot patients would often receive a systemic-to-pulmonary-artery shunt [15]. These shunts were designed to increase pulmonary blood flow, allowing the pulmonary vasculature to mature in anticipation of final correction at a later age [16]. Several shunts have been used (Figure 2), but the modified Blalock shunt (a side-to-side artificial shunt between the subclavian artery and the pulmonary artery) is probably the most practical shunt. The modified Blalock shunt does not require sacrifice of the subclavian artery, since it does not directly compromise the original vasculature. Furthermore, blood flow can be controlled better, and the shunt can be occluded more easily at a later stage, either by percutaneous intervention or by surgical intervention [12, 13, 17].

**Figure 2**

Schematic representation of the surgical palliative shunts used early in life for augmentation of pulmonary blood flow. The classic Blalock-Taussig shunt (1) requires sacrifice of the distal subclavian artery with an end-to-side anastomosis on the pulmonary artery (left or right). The upper limb supplied by the subclavian artery will receive blood from collateral vessels. The modified Blalock-Taussig shunt (2) is an artificial graft implanted end-to-side between the subclavian and pulmonary artery. There are several advantages over the classic Blalock-Taussig shunt: flow is easier to control by choice of the graft diameter; there is no need to sacrifice the vessel supporting the upper limb, and it is more easily occluded or resected at a later stage. The aorto-pulmonary Waterston (3) and Potts (4) shunts are no longer in use due to the often massive flow over a difficult-to-control shunt.

Subsequent corrective surgery then consisted of relieving (sub)pulmonary stenosis, ventricular septal defect closure, and closure of the artificial shunt [17]. Historically, the infundibulum was approached transventricularly, allowing the surgeon a clear view of the muscular subpulmonary obstruction [18, 19]. Often, the incision over the right ventricle was extended over the pulmonary valve, and subsequently closed with a patch. This patch relieved right ventricular outflow tract stenosis, and hence decreased right ventricular afterload. At the same time though, pulmonary regurgitation was created, inducing long-term volume-loading of the right ventricle [20].

Nowadays, complete surgical correction is often performed without prior palliative surgery, and the right ventricular outflow tract is approached through the right atrium [21], without the need for a patch in the right ventricular outflow tract [12, 13, 22]. The one-step surgical correction of tetralogy of Fallot patients is expected to result in a better long-term outcome in these patients, but definite results are still awaited, since this approach did not really catch on until approximately twenty-five years ago.

Late surgical correction in tetralogy of Fallot

After total correction in early childhood, patients are left with an incompetent pulmonary valve which becomes progressively insufficient, inducing volume loading of the right ventricle [20, 23, 24]. As a consequence, the right ventricle dilates, and the tricuspid valve often becomes insufficient. Even in the absence of right ventricular outflow tract stenosis, and with normal pulmonary vascular resistance, right ventricular stroke work is necessarily much higher than normal. Hence, adult patients with tetralogy of Fallot generally present with right ventricular dilatation and hypertrophy. Especially dilatation is thought to be detrimental to right ventricular function, characterized by poor right ventricular ejection fraction, and limited exercise capacity [25]. Furthermore, dilated right ventricles, associated with prolonged QRS duration, predispose to fatal arrhythmias [24, 26-28]. Surgical reintervention aimed at preservation and possibly restoration of right ventricular function has received much attention in the past ten to fifteen years [29-32]. After the initial success of pulmonary valve replacement with respect to positive right ventricular remodeling [32], well-being [33, 34], and exercise capacity [25, 35], there has been much debate regarding the optimal timing of pulmonary valve replacement [15, 30, 36, 37].

Although surgical pulmonary valve replacement is an intervention with low mortality [29], there is considerable associated morbidity. Since the use of a homograft is preferred over the use of a mechanical pulmonary valve with the need for long-term anticoagulant therapy [38], (surgical) reintervention for pulmonary valve replacement is anticipated in all of these

patients [39-41]. Apart from pulmonary valve replacement, patients often require resection of the aneurysm in the region of the right ventricular outflow tract, possibly dilatation or resection of a persistent peripheral pulmonary artery stenosis (either congenital or as a consequence of a prior palliative shunt), closure of a residual ventricular septal defect, and/or tricuspid annuloplasty or valvuloplasty [36, 42]. Although reports of repeated pulmonary valve replacement are encouraging [43, 44], available long-term follow-up of cryopreserved homograft in adult Fallot patients indicate that these patients will likely require multiple reinterventions [40].

For patients meeting the criteria, there is currently also the possibility of percutaneous pulmonary valve replacement, a minimally invasive procedure with good short-term results in expert centres [39, 45-50].

Anatomy in pulmonary arterial hypertension

Patients with pulmonary arterial hypertension can roughly be divided in those with congenital heart disease related pulmonary arterial hypertension, and those with post-natal onset of pulmonary arterial hypertension, without congenital heart disease [51-54]. The latter group of patients has a normal anatomy at birth and will not be discussed here. Pulmonary arterial hypertension associated with congenital heart disease is a consequence of an incompletely separated pulmonary and systemic circulation, allowing volume and/or pressure overload of the pulmonary circulation [6, 55, 56]. So-called pre-tricuspid shunts (i.e. atrial septal defect, aberrant pulmonary venous return) generally cause volume loading of pulmonary circulation, whereas post-tricuspid shunts (ventricular septal defect, persistent ductus arteriosus, and oversized palliative shunts) may cause both volume and pressure loading of the pulmonary circulation, depending on associated congenital abnormalities or surgical interventions (Figure 2 and 3) [57]. There is a strong association between excessive volume loading of the pulmonary circulation ($Q_p:Q_s > 1.5$) and the prevalence of late pulmonary arterial hypertension. However, there is by no means a cause-effect relationship, and even in the presence of pulmonary arterial hypertension late shunt closure may be beneficial in patients [58, 59]. The right ventricle is often dilated, and hypertrophied in volume loading of the pulmonary circulation, due to an increased right ventricular stroke volume [12]. Increased pulmonary artery pressures may reflect an increased pulmonary vascular resistance in the presence of a near-normal right-sided cardiac output, but may also reflect the necessarily increased driving pressure in the setting of a supra-normal right-sided cardiac output [60]. A careful measurement of $Q_p:Q_s$ is therefore essential before increased pulmonary artery pressures are explained as a consequence of increased pulmonary vascular resistance.

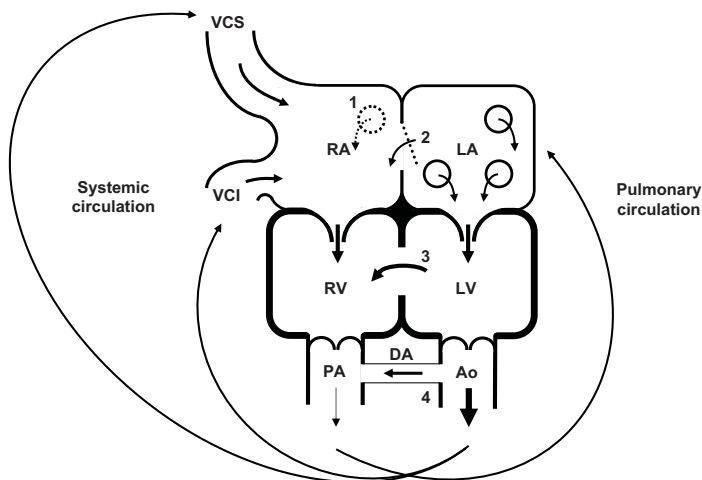


Figure 3

Schematic representation of the foetal situation in which pre-tricuspid and post-tricuspid shunts are not yet harmful to the right ventricle or the pulmonary circulation.

RA=right atrium, LA=left atrium, RV=right ventricle, LV=left ventricle, PA=pulmonary artery, Ao=aorta, VCI=inferior vena cava, VCS=superior vena cava.

Pre-tricuspid shunts primarily induce right ventricular volume loading. Anomalous pulmonary venous return (1) to the right atrium is of no consequence before birth. However, once the patent oval foramen (dotted line between RA and LA) closes after birth, the right ventricle undergoes volume loading, since much of the blood that is pumped into the pulmonary circulation, directly returns to the right atrium. There is therefore a discrepancy in pulmonary flow (Q_p) and systemic flow (Q_s): $Q_p > Q_s$. The same is true when there is an atrial septal defect (2). The higher left atrial pressure will allow blood to flow into the right atrium, again causing volume loading of the right ventricle. A small atrial septal defect with a $Q_p:Q_s < 1.5:1$ will rarely cause any symptoms, yet larger shunts are associated with long-term right ventricular dysfunction. Interestingly, when left ventricular diastolic function decreases with age, the atrial shunt may increase due to increased filling pressures. Patients may therefore only present in their forties or fifties.

Post-tricuspid shunts directly induce right ventricular pressure loading. The degree of additional volume loading is inversely related to the resistance of the right ventricular outflow tract and pulmonary circulation. Apart from the surgically created shunts (Figure 2) the ventricular septal defect (3) and persistent ductus arteriosus (4) are the most common congenital causes of right ventricular pressure load and pulmonary arterial hypertension. Initially, the pulmonary blood flow may be many times that of the systemic circulation ($Q_p \gg Q_s$). As pulmonary vascular resistance rises due to vasoconstriction and progressive pulmonary vascular damage, blood flow becomes more balanced. As long as the fixed pulmonary vascular resistance is substantially lower than systemic vascular resistance, patients may still effectively increase oxygen delivery by increasing cardiac output. Eventually, however, pulmonary vascular resistance may supersede systemic vascular resistance, and an increase in cardiac output will not necessarily lead to an increase in oxygen uptake, and therefore not to an increase in oxygen delivery either.

In contrast, in post-tricuspid shunting without a significant pressure-drop between systemic and pulmonary circulation, there is direct pressure overload of the pulmonary vasculature, which may lead to irreversible changes in the pulmonary arterioles within months to years [57, 61, 62].

In the face of congenital heart disease associated pulmonary arterial hypertension, surgical correction is often considered impossible, with the exception of patients who qualify for heart transplantation [54, 63-65].

Prenatal physiology

Early in intrauterine life, the right ventricle is essentially the left ventricle's equal (Figure 4). The presence of an open oval foramen and ductus arteriosus allow the separated chambers to function more or less as one, propulsing approximately 90% of the placenta-oxygenated blood into the systemic circulation, bypassing the non-ventilated lungs. Shortly after birth, the circulation is changed dramatically in response to the presence of intra-alveolar oxygen

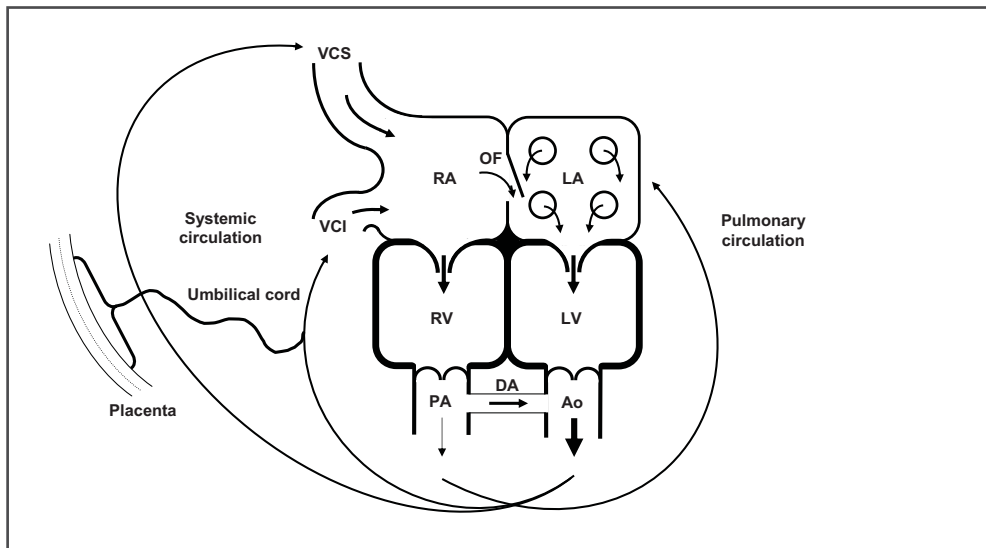
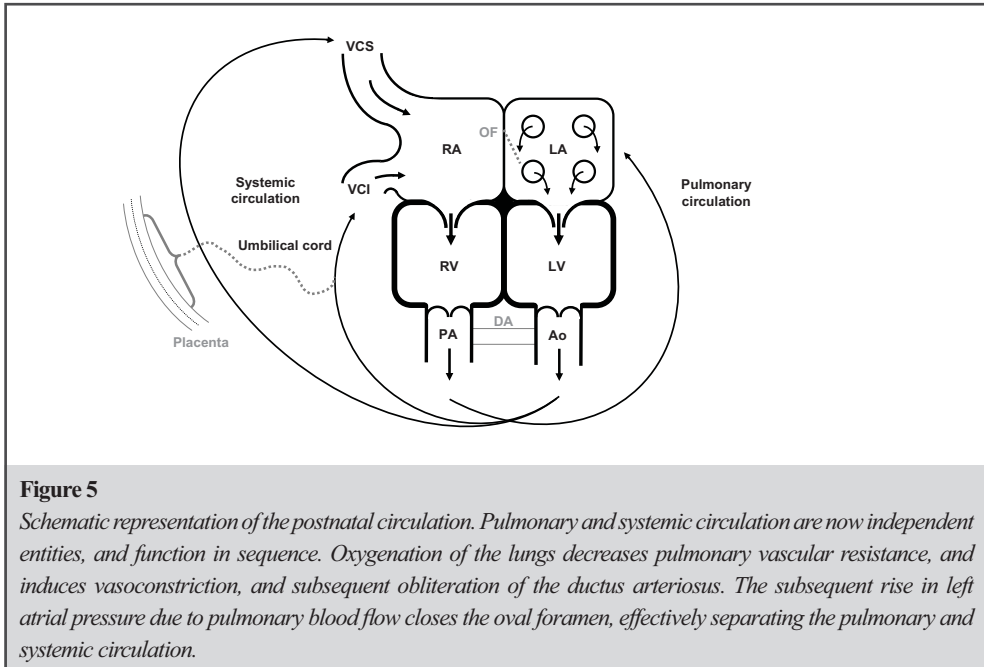


Figure 4

Schematic representation of the intra-uterine circulation. Pulmonary and systemic circulation are not yet independent entities, but function in parallel. Blood oxygenated by the placenta enters the heart through the right atrium, and then flows either into the right ventricle, or passes through the oval foramen into the left atrium and then into the left ventricle. Over 90% of the blood leaving the ventricles subsequently flows towards the systemic circulation, either directly through the left ventricle, or through the ductus arteriosus. The right and left ventricle are essentially performing as one, and as such are equally thick-walled, and perform similar stroke work.



[66, 67]. The latter decreases pulmonary vascular resistance almost instantly, allowing blood to flow through the lungs, which increases pulmonary venous pressure by enough to close the oval foramen, preventing oxygen-poor systemic venous blood entering the left ventricle. At the same time, the smooth muscle cells in the ductus arteriosus contract, preventing further flow between the systemic and pulmonary circulation (Figure 5).

Postnatal physiology

After approximately 6-12 weeks, the pulmonary circulation will have reduced its resistance from several times that of the systemic circulation before birth to a fraction of the vascular resistance of the systemic circulation [68]. The reduction in afterload is believed to induce both atrophy and a certain degree of apoptosis of the right ventricle [14, 68]. The persistent right ventricular hypertrophy after birth is one of the explanations for the observed better survival in patients with pulmonary arterial hypertension related to congenital heart disease [14]. As discussed above, both ventricles roughly perform similarly in the antenatal period when systemic and pulmonary circulations are situated in parallel. Once the circulations are separated after birth, the right heart soon delivers no more than a fraction of the work the left ventricle delivers [11, 69, 70]. Under normal conditions the right ventricle is therefore

thin-walled, and exercise will be limited by left ventricular performance. The self-regulatory nature of the coronary arteries is such that coronary venous blood is virtually always oxygen-depleted [11]. Nevertheless, in contrast to left coronary artery flow - which is predominantly diastolic due to systemic pressures in the left ventricular cavity during systole - right coronary flow is both systolic and diastolic, since systemic pressures in the right ventricular cavity do not exceed systemic pressures under physiologic conditions [71].

Pathophysiology

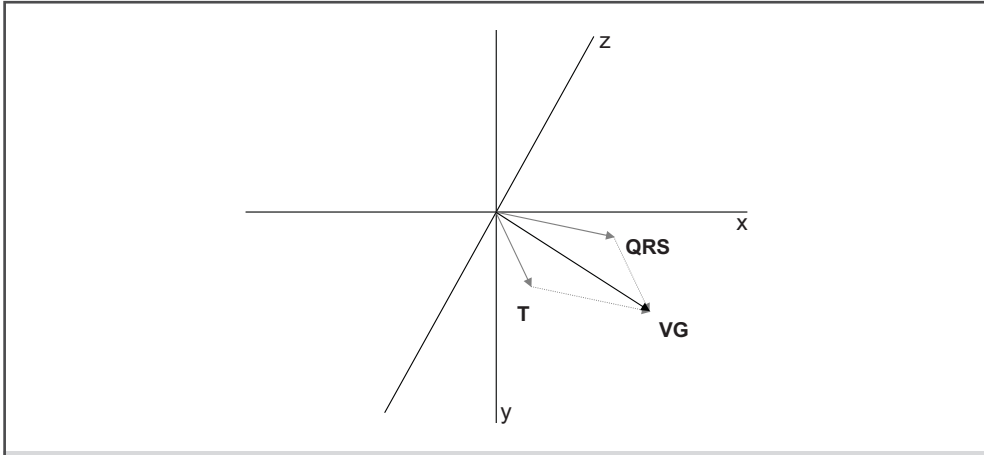
Although patients with a Fontan circulation prove that a right ventricle is not paramount for adequate systemic oxygen delivery in patients with a univentricular heart, the latter is only true for Fontan patients with a physiological pulmonary vascular resistance [13, 56, 72]. Furthermore, exercise capacity is markedly impaired in patients without an adequate right ventricle supporting the pulmonary circulation [25]. When pulmonary vascular resistance increases, pulmonary driving pressure needs to increase in order to maintain pulmonary flow [71]. This situation demands increased right ventricular performance, and induces right ventricular hypertrophy [73]. Resting cardiac output is generally maintained at rest until end-stage pulmonary arterial hypertension is present [60]. However, the fixed pulmonary vascular resistance in pulmonary arterial hypertension patients generally precludes an increase in cardiac output to normal physiological limits, because the right ventricle is unable to increase pulse pressure enough [74, 75]. Unable to adequately increase stroke volume [75], patients with pulmonary arterial hypertension will not reach normal exercise levels due to inadequate oxygen delivery, and virtually always present with excessive exertional dyspnea [76]. Furthermore, mean right coronary artery driving pressure decreases with an increasing right ventricular systolic pressure, since right coronary artery perfusion mimics left coronary artery perfusion, which is predominantly diastolic [71]. Impaired stroke volume may therefore paradoxically decrease right ventricular myocardial oxygen supply in the face of an already increased right ventricular oxygen demand [71]. Diastole therefore becomes even more important as right ventricular pressure overload progresses. However, the compromised cardiac output induces reflex noradrenergic activation [77], effectively decreasing net diastolic duration per heart beat. Patients with right ventricular pressure overload are therefore at risk of ischemia at higher heart rates. Even without macrovascular right coronary artery flow impairment, ischemia may therefore present as a result of a mismatch between oxygen supply and demand [78]. Patients with pulmonary arterial hypertension due to congenital heart disease have a few important differences in the heart, exercise hemodynamics, and blood, that explain their overall better survival compared to patients with other forms of pulmonary

arterial hypertension [79-81]. Firstly, the fact that pulmonary arterial hypertension is present from birth, prevents right ventricular atrophy to normal wall-size limits. Theoretically, muscles fibers that do not atrophy or go into apoptosis are better suited for the job than right ventricular muscle fibers that have to undergo compensatory hypertrophy later in life [14]. Patients with a post-tricuspid shunt related pulmonary arterial hypertension often have a much higher pulmonary vascular resistance than patients with pulmonary arterial hypertension of different etiology [54, 82-84]. Nevertheless, right ventricular peak pressure may be higher in pulmonary arterial hypertension patients without congenital heart disease [60], since the ventricles function in sequence, rather than partially in parallel (Figure 3 and 5). This is easily understood when considering what the right ventricle is required to do in order to increase output twofold. At a given fixed pulmonary vascular resistance of $800 \text{ dynes}\cdot\text{s}\cdot\text{cm}^{-5}$ with pulmonary artery pressures of 84/40 mmHg (mean 55 mmHg), and a pulmonary venous pressure of 5 mmHg, cardiac output is 5 L/min. To increase cardiac output to 10 L/min, the right ventricle needs to double the transpulmonary gradient (=mean pulmonary artery pressure – pulmonary venous pressure). To achieve a mean pulmonary artery pressure of 105 mmHg, pulmonary artery pressures would need to be in the order of 160/80 mmHg. In contrast, a patient with congenital heart disease associated pulmonary arterial hypertension would not be able to achieve such an increase in pulmonary perfusion pressure, since the post-tricuspid shunt serves as a pop-off valve, effectively shunting right ventricular blood into the systemic circulation, proportionate to the pressure difference between the right and left ventricle. In the face of a systemic circulation that is still able to decrease its vascular resistance with exercise, the shunt may be quite large. This explains the deep hypoxemia that can be observed in patients with pulmonary arterial hypertension related to uncorrected congenital heart disease [35, 51, 54-56, 72, 83]. An important hematological disorder is present in all patients with congenital heart disease associated pulmonary arterial hypertension and normal renal function: erythrocytosis due to an increased erythropoietin drive. This enables these patients to secure oxygen delivery despite lower arterial oxygenation [56, 85, 86]. Furthermore, erythropoietin enhances exercise capacity [86] not only by increasing hemoglobin levels, but likely also by inducing neovascularization through its anti-apoptotic, mitogenic, and angiogenic effects [87-90]. Importantly, an “anti-pulmonary hypertensive” effect is also attributed to erythropoietin, given the observed beneficial effect on the pulmonary vasculature as well [91]. The atrioseptostomy procedure, regarded as a rescue-procedure or a bridge to transplantation renders a similar situation [92]. Hence, it is understandable that patients surviving the procedure, tend to live longer, despite lower arterial oxygenation [93].

Functional assessment of right ventricular function

A patient will almost always present with complaints of dyspnea associated with inadequate oxygen delivery as a result of right ventricular overload. Patients often complain of fatigue, and approximately one in two patients experiences chest pain on exertion, likely related to right ventricular ischemia [6, 71, 78]. Furthermore, patients with right ventricular overload may complain of palpitations or recurrent (pre-)syncope due to supraventricular or ventricular arrhythmias [76]. Also, patients may experience peripheral edema and ascites. Once there is considerable right ventricular diastolic dysfunction and/or tricuspid regurgitation, right atrial pressure tends to rise [60]. Furthermore, once the right ventricle fails to secure left ventricular preload, systemic blood pressure falls [94, 95], and renal perfusion becomes suboptimal. Hence, the renin-angiotensin-aldosterone system is activated, which leads to sodium and water retention [52, 76]. As in left-sided heart failure, patients with end-stage right ventricular failure may experience spectacular weight gain in just a few days as a result of fluid retention. In patients with congenital heart disease related pulmonary arterial hypertension, cyanosis may be observed, as well as hour-glass like fingernails [55, 85]. In patients with systemic sclerosis, sclerodactyly and even digital ulcers may be observed [52, 76]. Raynaud's phenomenon is also common in these patients, although rare in pulmonary arterial hypertension patients without connective tissue disease [76, 96, 97]. In other pulmonary arterial hypertension patients there may be no abnormalities at all, apart from peripheral edema. On chest examination a right ventricular 'heave' may be felt in the left 3rd and 4th intercostal space; although not very sensitive, this is a highly specific sign of right ventricular hypertrophy [97]. On auscultation, with increased right ventricular pressure load, tricuspid regurgitation is heard more easily, since the gradient over the tricuspid valve increases likewise [98]. There is often a loud second heart sound, and in case of right ventricular volume loading, there is often a split second heart sound due to the increased time necessary for propulsing a larger stroke volume than the left ventricle. In case of a right bundle branch block, the splitting of the second heart sound may be even more prolonged, since activation of the right ventricular myocardium then depends on cell-to-cell activation instead of diffuse activation by the Purkinje fibers [99]. In adult Fallot patients, a pulmonary regurgitation murmur is almost always present due to the incompetent pulmonary valve. A louder regurgitation murmur generally denotes a larger pressure gradient, but more important is the duration of the regurgitation murmur: the shorter the duration, the sooner a pressure equilibrium is reached between the pulmonary artery and right ventricle. A regurgitation murmur of a short duration is therefore more serious than a regurgitation murmur that lasts throughout the diastole [100].

The electrocardiogram is no less important in evaluation of patients with suspected right

**Figure 6**

Schematic depiction of the ventricular gradient (VG) as a summation of net QRS and net T electrical activity. QRS and T vectors each depict net electrical activity, measured three-dimensionally, with a magnitude and direction. Summation of these vectors renders the ventricular gradient, i.e. the net electrical force of the whole myocardium. Depending on both individual magnitude and orientation of QRS and T vectors, the resultant vector depicting the ventricular gradient will be larger or smaller.

heart overload than it is in evaluation of patients with suspected left heart overload [26, 68, 101-107]. There is an increased incidence and prevalence of atrial fibrillation and atrial flutter in patients with right heart overload [26, 108-110]. Especially in Fallot patients with post-surgical scars in the right atrium and/or in the right ventricle, a range of arrhythmias may be observed [111, 112]. The majority of patients with right heart overload will present in sinus rhythm, however. Established markers of compromised cardiac function in left heart disease, resting heart rate [113], heart rate variability [114], and heart rate response with exercise [115-119], are likely just as important in right heart disease. Important markers of right heart disease are the heart rate at rest, since this likely reflects reflex noradrenergic activation in response to cardiac output [120]; i.e. heart rate will be higher in patients with poor stroke volume (*Chapter IX*). In severe right heart overload, a rightward deviation of the electrical axis of the heart is almost always present, with the exception of patients with a large ventricular septal defect, who mostly have a leftward oriented heart axis. That the standard 12-lead ECG contains more information than meets the eye, is explained in *Chapter V*, *Chapter VI*, and *Chapter VII*. In short, ventricular depolarization is characterized on the ECG by the QRS complex, whereas ventricular repolarization is characterized by the T wave. Both QRS complex and T wave have amplitudes during a certain amount of time (mV·ms). The ECG is therefore a simple representation of three-dimensionally moving electrical wave fronts. Both QRS complex and

T wave can be represented by a vector, reflecting the orientation and magnitude of these wave fronts (Figure 6). The *ventricular gradient*, i.e. the resultant vector of the individual QRS and T vectors, defines the net magnitude and orientation of the electrical wave fronts of the ventricles during one cardiac cycle. Interestingly, the *ventricular gradient* is highly stable, and to a large extent independent of activation order [121]. Nevertheless, there are considerable gender differences in the *ventricular gradient*, and heart rate also influences the *ventricular gradient* within individuals [122]. An increased PR-interval, and/or QRS duration may be observed in right heart overload, as a consequence of increased fibrosis [123, 124]. Typically, a right bundle branch block may be a sign of right ventricular overload, although there is a relatively high prevalence of right bundle branch block in the general population without right heart disease [2-4]. Conventionally, voltage criteria for right atrial enlargement are based on a 'P pulmonale', a P wave ≥ 0.25 mV in lead II, or a P wave with an amplitude of

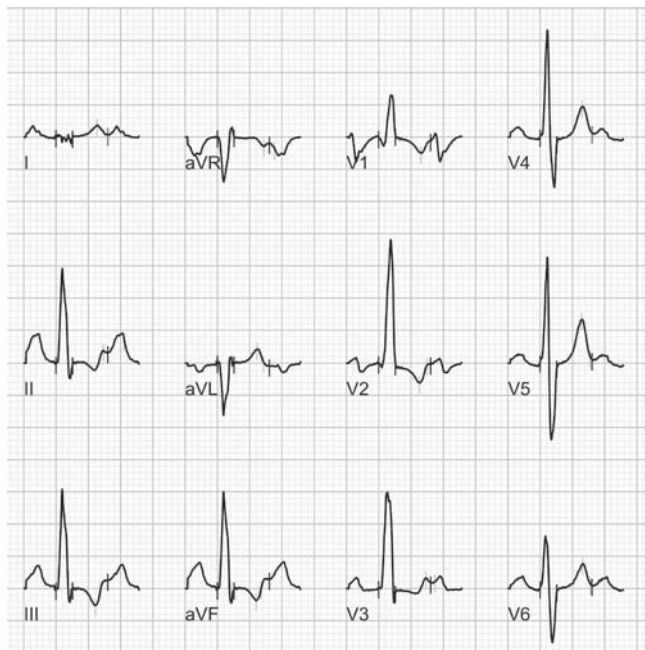

Figure 7

Typical ECG observed in right ventricular pressure load: there is a sinus tachycardia of approximately 115 bpm, a rightward oriented heart axis, a borderline first degree AV-block, an increased QRS duration with a right bundle branch block configuration, and inverted T-waves – a 'strain pattern', most prominent in the right ventricular leads (V1, V2) and the inferior wall leads (II, III, aVF).

≥ 0.1 mV or a duration of ≥ 40 ms in lead V1. Voltage criteria for right ventricular hypertrophy are based on an R wave > 5 mm with R:S > 1 in lead V1, overlying the right ventricle, and an R:S < 1 in lead V5, overlying the left ventricle [103, 125]. Repolarization disorders are often seen in right ventricular overload, most likely as a consequence of right ventricular hypertrophy, fibrosis and recurrent ischemia. A typical 'strain'-pattern may be observed in leads V1 and V2: the J-point is normal, but there is a down-sloping ST-T segment, discordant with the QRS complex (Figure 7).

A chest X-ray may indicate whether there is severe pulmonary disease, left heart disease (Kerley-B lines) or long-standing pulmonary hypertension (prominent proximal pulmonary arteries) [6, 51, 76]. Standard blood tests may clarify whether there is concomitant thyroid disease [126, 127], increased wall stress (elevated (NT-pro)BNP), or ischemia (elevated Troponin I or T) [128-130]. Every patient deserves adequate assessment of pulmonary function, including an arterial blood sample analysis, and spirometric analysis. In specific cases where alveolar hypoventilation is suspected, one should perform overnight oximetry. Similarly, when hypoxia is observed, alveolar diffusion capacity should be measured, corrected for alveolar volume [51, 52]. Exercise capacity is an important marker of disease burden, and can distinguish pulmonary impairment from cardiac impairment [131]. Although not as thorough as for instance bicycle ergometry, the 6-minute walk test is an adequate reflection of exercise capacity, oxygen consumption, and daily functioning [25, 33, 35, 56, 72, 76, 131-135]. This test is especially useful in advanced right ventricular failure when more vigorous exercise tests, such as bicycle ergometry, are no longer feasible [132].

Right heart imaging is not as easy as left heart imaging due to the directly retrosternal position, and functional assessment is only reliable in experienced hands. In contrast to the globular-shaped left ventricle, the normal right ventricle is not easily reflected by a common mathematical three-dimensional figure [136]. This becomes evident when the heart is imaged in its orthogonal planes: at best it can be stated that after birth, under physiological conditions, the right ventricle is crescent-shaped, half wrapped around the left ventricle (Figure 8). This is easily understood considering the higher systolic and diastolic left ventricular filling pressures, rendering the left ventricle globular-shaped in a physiological situation.

The use of Simpson's rule has allowed radiologists to accurately calculate right ventricular volumes in diastole and systole, as well as ejection fraction [136]. Cardiac MRI has helped greatly to understand the contraction pattern of the right ventricle, and is nowadays considered the gold standard for measurement of volume and ejection fraction [32, 75, 104, 137-139]. Nevertheless, echocardiography - which revolutionized cardiology by producing straightforward moving images of the heart - is easier to perform, less expensive, more

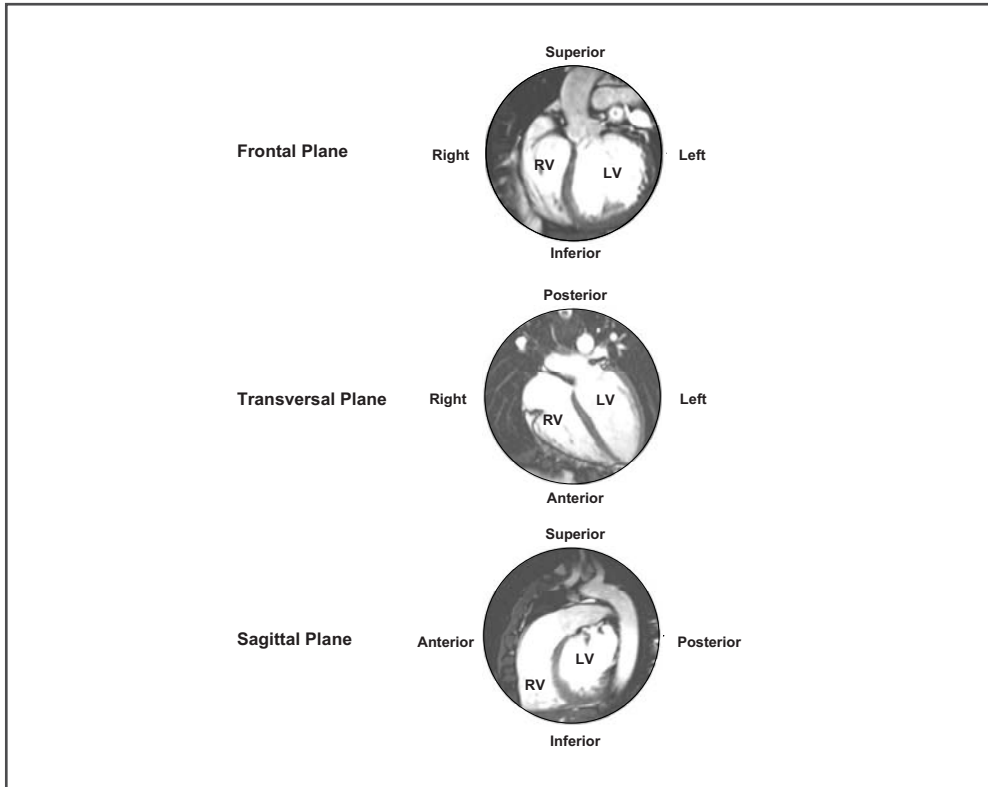


Figure 8

Cardiac magnetic resonance imaging of the normal heart in orthogonal slices.

Top: depiction of the left and right ventricle in the frontal plane. There is clear bulging of the septum towards the right ventricular cavity, which seems smaller in this section.

Middle: depiction of the left and right ventricle in the transversal plane. It is clear that the right ventricle is thin-walled with a trabeculated aspect.

Bottom: depiction of the left and right ventricle in the sagittal plane. The right ventricle lies retrosternally on the diaphragm, within the pericardial sac. Although the left ventricle has a consistent globular-shape, the right ventricle may at best be appreciated as crescent-shaped.

readily available, and allows a fairly reliable estimation of right atrial, right ventricular, and pulmonary pressures, the latter by application of the simplified Bernoulli equation [24, 60, 97, 100, 140, 141]. Although echocardiography is beyond the scope of this thesis, it should be considered an essential part of evaluation of patients with suspected right heart disease [51, 52, 76]. In patients with suspected pulmonary embolism the use of a computed tomography (CT) angiogram may help diagnose both large and small vessel thrombosis [62, 142]. So far, CT imaging is not yet of much help for assessment of right ventricular function, although a

rough idea of right-to-left ventricular volume ratios is also rendered by CT imaging.

In general, right ventricular overload is often diagnosed with considerable delay, except for in patients with congenital heart disease, who are generally recognized before or shortly after birth [51, 76]. Due to successful research there is an increasing awareness for the entity of right ventricular overload in the setting of pulmonary arterial hypertension. However, good screening methods are lacking [143]. Since right ventricular overload is generally already moderate-to-severe when patients become symptomatic, there is a theoretical benefit of case-finding and/or screening. Whether indeed earlier treatment initiation secures a better long-term outcome is unknown. The current concept of pulmonary arterial hypertension, however, is that of a progressive disease that should best be treated earlier, rather than later [144].

The significance of right ventricular overload

A chain is as strong as its weakest link. An otherwise perfectly healthy person with a good left atrium and ventricle may therefore be highly symptomatic when faced with right ventricular overload. Of course, right ventricular pressure overload is ultimately more limiting than right ventricular volume overload, since the Fontan circulation proves that with normal pulmonary vascular resistance a reasonable cardiac output is feasible [13, 25, 55]. Nevertheless, right ventricular overload is generally associated with poor exercise capacity, arrhythmias, and poor survival. The reason why pulmonary arterial hypertension is defined as a mean pulmonary artery pressure of >25 mmHg, is that this is approximately double of what is normally found in healthy subjects [60]. At less than systemic pulmonary artery pressures still, e.g. 78/36 mmHg (mean 50 mmHg), the right ventricle would therefore have to produce approximately four times the normal work [60, 84]. Despite the misleading right ventricular hypertrophy and impressive stroke work, the right ventricle likely passes a point of compensated adaptation early on in the process of overload. This view is supported by the reports regarding the poor right ventricular remodeling after pulmonary valve replacement in adult tetralogy of Fallot patients with severely dilated right ventricles [30, 31, 36]. Similarly, the right ventricle appears to be physiologically limited in its hypertrophy [84, 145], most likely due to maximum myocardial oxygen delivery. This then leads to an increase in heart rate once stroke work - and hence stroke volume - can no longer be increased [75]. A decrease in stroke volume and a compensatory increase in heart rate should therefore be regarded as relatively late symptoms of compromised cardiac output [113].

Early detection of right ventricular overload therefore remains a clinical challenge [146]. A challenge we best face with non-invasive diagnostic modalities.

Aim and outline of the thesis

The main aim of this thesis was to improve non-invasive diagnosis and follow-up of right ventricular function in the setting of right ventricular volume and/or pressure overload. The thesis focused on right ventricular volume overload in the setting of adult Fallot patients who underwent pulmonary valve replacement, and on right ventricular pressure overload in the setting of pulmonary arterial hypertension.

Part I focuses on right ventricular volume overload in adults with Fallot's tetralogy after correction in early childhood. The innate pulmonary valve abnormality precludes long-term surgical correction, and many adult Fallot patients will require repeated pulmonary valve replacement. In *Chapter II* we attempt to elucidate which patient characteristics were associated with a more prompt recovery time after surgical replacement, describing a small, yet well-documented cohort of adult Fallot patients who underwent elective pulmonary valve replacement. In *Chapter III* we analyze what may be expected from pulmonary valve replacement with respect to right ventricular reverse remodeling: i.e. what post-operative results may be expected based on the degree of pulmonary regurgitation and right ventricular function. In *Chapter IV* we determine what effect pulmonary valve replacement has on cardiac repolarization characteristics in adult Fallot patients, since many adult Fallot patients have a high arrhythmia propensity as a consequence of long-standing right ventricular volume overload.

Part II concentrates on right ventricular pressure overload due to pulmonary arterial hypertension. In *Chapter V*, using an animal experimental setup, we document the evolutionary changes in right ventricular morphology and function during the development of pulmonary arterial hypertension. We compare electrocardiography, echocardiography, heart catheterization and right ventricular histology to monitor this chain of events. Documentation of evolutionary electrocardiographic changes due to right ventricular pressure overload helps to understand especially the early right ventricular changes in developing pulmonary arterial hypertension. In *Chapter VI* we subsequently study the additional value of three dimensional vectorcardiography for diagnosis of increased right ventricular pressure load, compared to conventional 12-lead ECG diagnosis. In *Chapter VII* we report on a particular patient whose ECG recordings changed markedly after developing idiopathic pulmonary arterial hypertension, and briefly review the available literature on this subject. In *Chapter VIII*, based on the hemodynamic abnormalities associated with electrocardiographically detectable

abnormalities, we define electrocardiographic cut-off points for determination of treatment response in pulmonary arterial hypertension patients. In *Chapter IX* we determine that resting heart rate, reflecting hemodynamics and neurohumoral activation, is a very important marker of prognosis in pulmonary arterial hypertension. Finally, in *Chapter X* we discuss the individual chapters, the conclusions we may draw from this research, and we reflect on future research and what this should address with respect to right ventricular failure.

References

1. Farb A, Burke AP and Virmani R. Anatomy and pathology of the right ventricle (including acquired tricuspid and pulmonic valve disease). *Cardiol Clin* 1992;10:1-21.
2. Liao YL, Emidy LA, Dyer A, Hewitt JS, Shekelle RB, Paul O, Prineas R and Stamler J. Characteristics and prognosis of incomplete right bundle branch block: an epidemiologic study. *J Am Coll Cardiol* 1986;7:492-499.
3. Rabkin SW, Mathewson FA and Tate RB. The natural history of right bundle branch block and frontal plane QRS axis in apparently healthy men. *Chest* 1981;80:191-196.
4. Fleg JL, Das DN and Lakatta EG. Right bundle branch block: long-term prognosis in apparently healthy men. *J Am Coll Cardiol* 1983;1:887-892.
5. Ho SY and Nihoyannopoulos P. Anatomy, echocardiography, and normal right ventricular dimensions. *Heart* 2006;92 Suppl 1:i2-13.
6. Chin KM, Kim NH and Rubin LJ. The right ventricle in pulmonary hypertension. *Coron Artery Dis* 2005;16:13-18.
7. Dell'Italia LJ. The right ventricle: anatomy, physiology, and clinical importance. *Curr Probl Cardiol* 1991;16:653-720.
8. Pettersen E, Helle-Valle T, Edvardsen T, Lindberg H, Smith HJ, Smevik B, Smiseth OA and Andersen K. Contraction pattern of the systemic right ventricle shift from longitudinal to circumferential shortening and absent global ventricular torsion. *J Am Coll Cardiol* 2007;49:2450-2456.
9. Duncker DJ and Bache RJ. Regulation of coronary blood flow during exercise. *Physiol Rev* 2008;88:1009-1086.
10. Zong P, Tune JD and Downey HF. Mechanisms of oxygen demand/supply balance in the right ventricle. *Exp Biol Med (Maywood)* 2005;230:507-519.
11. Westerhof N, Boer C, Lamberts RR and Sipkema P. Cross-talk between cardiac muscle and coronary vasculature. *Physiol Rev* 2006;86:1263-1308.
12. Bashore TM. Adult congenital heart disease: right ventricular outflow tract lesions. *Circulation* 2007;115:1933-1947.
13. Sommer RJ, Hijazi ZM and Rhodes JF. Pathophysiology of congenital heart disease in the adult: part III: Complex congenital heart disease. *Circulation* 2008;117:1340-1350.

14. Hopkins WE and Waggoner AD. Severe pulmonary hypertension without right ventricular failure: the unique hearts of patients with Eisenmenger syndrome. *Am J Cardiol* 2002;89:34-38.
 15. Shrivastava S. Timing of surgery/catheter intervention in common congenital cardiac defects. *Indian J Pediatr* 2000;67:S2-S6.
 16. Agnoletti G, Boudjemline Y, Bonnet D, Sidi D and Vouhe P. Surgical reconstruction of occluded pulmonary arteries in patients with congenital heart disease: effects on pulmonary artery growth. *Circulation* 2004;109:2314-2318.
 17. Sivakumar K, Krishnan P, Pieris R and Francis E. Hybrid approach to surgical correction of tetralogy of Fallot in all patients with functioning Blalock Taussig shunts. *Catheter Cardiovasc Interv* 2007;70:256-264.
 18. Brock RC. The surgery of pulmonary stenosis. *Br Med J* 1949;2:399-406.
 19. Campbell M, Deuchar DC and Brock R. Results of pulmonary valvotomy and infundibular resection in 100 cases of Fallot's tetralogy. *Br Med J* 1954;2:111-122.
 20. Giannopoulos NM, Chatzis AC, Bobos DP, Kirvassilis GV, Tsoutsinos A and Sarris GE. Tetralogy of Fallot: influence of right ventricular outflow tract reconstruction on late outcome. *Int J Cardiol* 2004;97 Suppl 1:87-90.
 21. Hoohenkerk GJ, Schoof PH, Bruggemans EF, Rijlaarsdam M and Hazekamp MG. 28 years' experience with transatrial-transpulmonary repair of atrioventricular septal defect with tetralogy of Fallot. *Ann Thorac Surg* 2008;85:1686-1689.
 22. Billig DM. Current considerations in the surgical management of tetralogy of Fallot. *Chest* 1973;64:79-83.
 23. Oosterhof T, Tulevski II, Vliegen HW, Spijkerboer AM and Mulder BJ. Effects of volume and/or pressure overload secondary to congenital heart disease (tetralogy of fallot or pulmonary stenosis) on right ventricular function using cardiovascular magnetic resonance and B-type natriuretic peptide levels. *Am J Cardiol* 2006;97:1051-1055.
 24. Gatzoulis MA, Clark AL, Cullen S, Newman CG and Redington AN. Right ventricular diastolic function 15 to 35 years after repair of tetralogy of Fallot. Restrictive physiology predicts superior exercise performance. *Circulation* 1995;91:1775-1781.
 25. Diller GP, Dimopoulos K, Okonko D, Li W, Babu-Narayan SV, Broberg CS, Johansson B, Bouzas B, Mullen MJ, Poole-Wilson PA, Francis DP and Gatzoulis MA. Exercise intolerance in adult congenital heart disease: comparative severity, correlates, and prognostic implication. *Circulation* 2005;112:828-835.
-

26. Gatzoulis MA, Till JA, Somerville J and Redington AN. Mechanoelectrical interaction in tetralogy of Fallot. QRS prolongation relates to right ventricular size and predicts malignant ventricular arrhythmias and sudden death. *Circulation* 1995;92:231-237.
 27. Abd El Rahman MY, Abdul-Khaliq H, Vogel M, Alexi-Meskishvili V, Gutberlet M and Lange PE. Relation between right ventricular enlargement, QRS duration, and right ventricular function in patients with tetralogy of Fallot and pulmonary regurgitation after surgical repair. *Heart* 2000;84:416-420.
 28. Gatzoulis MA, Balaji S, Webber SA, Siu SC, Hokanson JS, Poile C, Rosenthal M, Nakazawa M, Moller JH, Gillette PC, Webb GD and Redington AN. Risk factors for arrhythmia and sudden cardiac death late after repair of tetralogy of Fallot: a multicentre study. *Lancet* 2000;356:975-981.
 29. Hazekamp MG, Kurvers MM, Schoof PH, Vliegen HW, Mulder BM, Roest AA, Ottenkamp J and Dion RA. Pulmonary valve insertion late after repair of Fallot's tetralogy. *Eur J Cardiothorac Surg* 2001;19:667-670.
 30. Therrien J, Provost Y, Merchant N, Williams W, Colman J and Webb G. Optimal timing for pulmonary valve replacement in adults after tetralogy of Fallot repair. *Am J Cardiol* 2005;95:779-782.
 31. Therrien J, Siu SC, McLaughlin PR, Liu PP, Williams WG and Webb GD. Pulmonary valve replacement in adults late after repair of tetralogy of fallot: are we operating too late? *J Am Coll Cardiol* 2000;36:1670-1675.
 32. Vliegen HW, van Straten A, de Roos A, Roest AA, Schoof PH, Zwinderman AH, Ottenkamp J, van der Wall EE and Hazekamp MG. Magnetic resonance imaging to assess the hemodynamic effects of pulmonary valve replacement in adults late after repair of tetralogy of fallot. *Circulation* 2002;106:1703-1707.
 33. Fredriksen PM, Therrien J, Veldtman G, Ali WM, Liu P, Thaulow E and Webb G. Aerobic capacity in adults with tetralogy of Fallot. *Cardiol Young* 2002;12:554-559.
 34. Roest AA, Helbing WA, Kunz P, van den Aardweg JG, Lamb HJ, Vliegen HW, van der Wall EE and de Roos A. Exercise MR imaging in the assessment of pulmonary regurgitation and biventricular function in patients after tetralogy of fallot repair. *Radiology* 2002;223:204-211.
 35. Diller GP, Dimopoulos K, Okonko D, Uebing A, Broberg CS, Babu-Narayan S, Bayne S, Poole-Wilson PA, Sutton R, Francis DP and Gatzoulis MA. Heart rate response during exercise predicts survival in adults with congenital heart disease. *J Am Coll Cardiol* 2006;48:1250-1256.
 36. Henkens IR, van Straten A, Schalij MJ, Hazekamp MG, de Roos A, van der Wall EE and Vliegen HW. Predicting outcome of pulmonary valve replacement in adult tetralogy of Fallot patients. *Ann Thorac Surg* 2007;83:907-911.
-

37. Oosterhof T, van Straten A, Vliegen HW, Meijboom FJ, van Dijk AP, Spijkerboer AM, Bouma BJ, Zwinderman AH, Hazekamp MG, de Roos A and Mulder BJ. Preoperative thresholds for pulmonary valve replacement in patients with corrected tetralogy of Fallot using cardiovascular magnetic resonance. *Circulation* 2007;116:545-551.
 38. Waterbolk TW, Hoendermis ES, den Hamer IJ and Ebels T. Pulmonary valve replacement with a mechanical prosthesis. Promising results of 28 procedures in patients with congenital heart disease. *Eur J Cardiothorac Surg* 2006;30:28-32.
 39. Frigiola A, Tsang V, Nordmeyer J, Lurz P, van Doorn C, Taylor AM, Bonhoeffer P and de Leval M. Current approaches to pulmonary regurgitation. *Eur J Cardiothorac Surg* 2008;34:576-581.
 40. Oosterhof T, Meijboom FJ, Vliegen HW, Hazekamp MG, Zwinderman AH, Bouma BJ, van Dijk AP and Mulder BJ. Long-term follow-up of homograft function after pulmonary valve replacement in patients with tetralogy of Fallot. *Eur Heart J* 2006;27:1478-1484.
 41. Quintessenza JA, Jacobs JP, Chai PJ, Morell VO, Giroud JM and Boucek RJ. Late replacement of the pulmonary valve: when and what type of valve? *Cardiol Young* 2005;15 Suppl 1:58-63.
 42. Karamlou T, McCrindle BW and Williams WG. Surgery insight: late complications following repair of tetralogy of Fallot and related surgical strategies for management. *Nat Clin Pract Cardiovasc Med* 2006;3:611-622.
 43. Erez E, Tam VK, Dublin NA and Stakes J. Repeat right ventricular outflow tract reconstruction using the Medtronic Freestyle porcine aortic root. *J Heart Valve Dis* 2006;15:92-96.
 44. Meyns B, Jashari R, Gewillig M, Mertens L, Komarek A, Lesaffre E, Budts W and Daenen W. Factors influencing the survival of cryopreserved homografts. The second homograft performs as well as the first. *Eur J Cardiothorac Surg* 2005;28:211-216.
 45. Ghez O, Tsang VT, Frigiola A, Coats L, Taylor A, van DC, Bonhoeffer P and de LM. Right ventricular outflow tract reconstruction for pulmonary regurgitation after repair of tetralogy of Fallot. Preliminary results. *Eur J Cardiothorac Surg* 2007;31:654-658.
 46. Khambadkone S and Bonhoeffer P. Percutaneous implantation of pulmonary valves. *Expert Rev Cardiovasc Ther* 2003;1:541-548.
 47. Khambadkone S, Coats L, Taylor A, Boudjemline Y, Derrick G, Tsang V, Cooper J, Muthurangu V, Hegde SR, Razavi RS, Pellerin D, Deanfield J and Bonhoeffer P. Percutaneous pulmonary valve implantation in humans: results in 59 consecutive patients. *Circulation* 2005;112:1189-1197.
-

48. Lurz P, Coats L, Khambadkone S, Nordmeyer J, Boudjemline Y, Schievano S, Muthurangu V, Lee TY, Parenzan G, Derrick G, Cullen S, Walker F, Tsang V, Deanfield J, Taylor AM and Bonhoeffer P. Percutaneous pulmonary valve implantation: impact of evolving technology and learning curve on clinical outcome. *Circulation* 2008;117:1964-1972.
 49. Schievano S, Coats L, Migliavacca F, Norman W, Frigiola A, Deanfield J, Bonhoeffer P and Taylor AM. Variations in right ventricular outflow tract morphology following repair of congenital heart disease: implications for percutaneous pulmonary valve implantation. *J Cardiovasc Magn Reson* 2007;9:687-695.
 50. Schievano S, Migliavacca F, Coats L, Khambadkone S, Carminati M, Wilson N, Deanfield JE, Bonhoeffer P and Taylor AM. Percutaneous pulmonary valve implantation based on rapid prototyping of right ventricular outflow tract and pulmonary trunk from MR data. *Radiology* 2007;242:490-497.
 51. Galie N, Torbicki A, Barst R, Darteville P, Haworth S, Higenbottam T, Olschewski H, Peacock A, Pietra G, Rubin LJ, Simonneau G, Priori SG, Garcia MA, Blanc JJ, Budaj A, Cowie M, Dean V, Deckers J, Burgos EF, Lekakis J, Lindahl B, Mazzotta G, McGregor K, Morais J, Oto A, Smiseth OA, Barbera JA, Gibbs S, Hoeper M, Humbert M, Naeije R and Pepke-Zaba J. Guidelines on diagnosis and treatment of pulmonary arterial hypertension. The Task Force on Diagnosis and Treatment of Pulmonary Arterial Hypertension of the European Society of Cardiology. *Eur Heart J* 2004;25:2243-2278.
 52. Simonneau G, Galie N, Rubin LJ, Langleben D, Seeger W, Domenighetti G, Gibbs S, Lebrec D, Speich R, Beghetti M, Rich S and Fishman A. Clinical classification of pulmonary hypertension. *J Am Coll Cardiol* 2004;43:5S-12S.
 53. Schulze-Neick I and Beghetti M. Classifying pulmonary hypertension in the setting of the congenitally malformed heart--cleaning up a dog's dinner. *Cardiol Young* 2008;18:22-25.
 54. Galie N, Manes A, Palazzini M, Negro L, Marinelli A, Gambetti S, Mariucci E, Denti A, Branzi A and Picchio FM. Management of pulmonary arterial hypertension associated with congenital systemic-to-pulmonary shunts and Eisenmenger's syndrome. *Drugs* 2008;68:1049-1066.
 55. Diller GP and Gatzoulis MA. Pulmonary vascular disease in adults with congenital heart disease. *Circulation* 2007;115:1039-1050.
 56. Dimopoulos K, Diller GP, Piepoli MF and Gatzoulis MA. Exercise intolerance in adults with congenital heart disease. *Cardiol Clin* 2006;24:641-60, vii.
 57. Sommer RJ, Hijazi ZM and Rhodes JF, Jr. Pathophysiology of congenital heart disease in the adult: part I: Shunt lesions. *Circulation* 2008;117:1090-1099.
-

58. Viswanathan S and Kumar RK. Assessment of operability of congenital cardiac shunts with increased pulmonary vascular resistance. *Catheter Cardiovasc Interv* 2008;71:665-670.
 59. Ussia GP, Mule M, Caruso E, Aiello R and Tamburino C. Combined endothelin receptor antagonist and transcatheter interventional therapy of patent ductus arteriosus with severe pulmonary artery hypertension. *Int J Cardiol* 2007;116:427-429.
 60. Chemla D, Castelain V, Herve P, Lecarpentier Y and Brimiouille S. Haemodynamic evaluation of pulmonary hypertension. *Eur Respir J* 2002;20:1314-1331.
 61. Diller GP, Dimopoulos K, Broberg CS, Kaya MG, Naghotra US, Uebing A, Harries C, Goktekin O, Gibbs JS and Gatzoulis MA. Presentation, survival prospects, and predictors of death in Eisenmenger syndrome: a combined retrospective and case-control study. *Eur Heart J* 2006;27:1737-1742.
 62. Silversides CK, Granton JT, Konen E, Hart MA, Webb GD and Therrien J. Pulmonary thrombosis in adults with Eisenmenger syndrome. *J Am Coll Cardiol* 2003;42:1982-1987.
 63. Goerler H, Simon A, Gohrbandt B, Hagl C, Oppelt P, Weidemann J, Haverich A and Strueber M. Heart-lung and lung transplantation in grown-up congenital heart disease: long-term single centre experience. *Eur J Cardiothorac Surg* 2007;32:926-931.
 64. Choong CK, Sweet SC, Guthrie TJ, Mendeloff EN, Haddad FJ, Schuler P, De La MM and Huddleston CB. Repair of congenital heart lesions combined with lung transplantation for the treatment of severe pulmonary hypertension: a 13-year experience. *J Thorac Cardiovasc Surg* 2005;129:661-669.
 65. Hosseinpour AR, Cullen S and Tsang VT. Transplantation for adults with congenital heart disease. *Eur J Cardiothorac Surg* 2006;30:508-514.
 66. Michelakis ED, Rebeyka I, Wu X, Nsair A, Thebaud B, Hashimoto K, Dyck JR, Haromy A, Harry G, Barr A and Archer SL. O₂ sensing in the human ductus arteriosus: regulation of voltage-gated K⁺ channels in smooth muscle cells by a mitochondrial redox sensor. *Circ Res* 2002;91:478-486.
 67. Therrien J, Connelly MS and Webb GD. Patent Ductus Arteriosus. *Curr Treat Options Cardiovasc Med* 1999;1:341-346.
 68. Penalzoza D and Arias-Stella J. The heart and pulmonary circulation at high altitudes: healthy highlanders and chronic mountain sickness. *Circulation* 2007;115:1132-1146.
 69. Jones DP, Damiano R, Cox JL and Wolfe WG. The effect of altitude-induced hypoxia on regional myocardial blood flow. *J Thorac Cardiovasc Surg* 1981;82:216-220.
-

70. Murray PA, Baig H, Fishbein MC and Vatner SF. Effects of experimental right ventricular hypertrophy on myocardial blood flow in conscious dogs. *J Clin Invest* 1979;64:421-427.
 71. van Wolferen SA, Marcus JT, Westerhof N, Spreeuwenberg MD, Marques KM, Bronzwaer JG, Henkens IR, Gan CT, Boonstra A, Postmus PE and Vonk-Noordegraaf A. Right coronary artery flow impairment in patients with pulmonary hypertension. *Eur Heart J* 2008;29:120-127.
 72. Diller GP, Okonko DO, Uebing A, Dimopoulos K, Bayne S, Sutton R, Francis DP and Gatzoulis MA. Impaired heart rate response to exercise in adult patients with a systemic right ventricle or univentricular circulation: Prevalence, relation to exercise, and potential therapeutic implications. *Int J Cardiol* 2008;
 73. Henkens IR, Mouchaers KT, Vliegen HW, van der Laarse WJ, Swenne CA, Maan AC, Draisma HH, Schalij I, van der Wall EE, Schalij MJ and Vonk-Noordegraaf A. Early changes in rat hearts with developing pulmonary arterial hypertension can be detected with three-dimensional electrocardiography. *Am J Physiol Heart Circ Physiol* 2007;293:H1300-H1307.
 74. Castelain V, Chemla D, Humbert M, Sitbon O, Simonneau G, Lecarpentier Y and Herve P. Pulmonary artery pressure-flow relations after prostacyclin in primary pulmonary hypertension. *Am J Respir Crit Care Med* 2002;165:338-340.
 75. Holverda S, Gan CT, Marcus JT, Postmus PE, Boonstra A and Vonk-Noordegraaf A. Impaired stroke volume response to exercise in pulmonary arterial hypertension. *J Am Coll Cardiol* 2006;47:1732-1733.
 76. Barst RJ, McGoon M, Torbicki A, Sitbon O, Krowka MJ, Olschewski H and Gaine S. Diagnosis and differential assessment of pulmonary arterial hypertension. *J Am Coll Cardiol* 2004;43:40S-47S.
 77. Velez-Roa S, Ciarka A, Najem B, Vachieri JL, Naeije R and Van de Borne P. Increased sympathetic nerve activity in pulmonary artery hypertension. *Circulation* 2004;110:1308-1312.
 78. Gomez A, Bialostozky D, Zajarias A, Santos E, Palomar A, Martinez ML and Sandoval J. Right ventricular ischemia in patients with primary pulmonary hypertension. *J Am Coll Cardiol* 2001;38:1137-1142.
 79. Badesch DB, Tapson VF, McGoon MD, Brundage BH, Rubin LJ, Wigley FM, Rich S, Barst RJ, Barrett PS, Kral KM, Jobsis MM, Loyd JE, Murali S, Frost A, Girgis R, Bourge RC, Ralph DD, Elliott CG, Hill NS, Langleben D, Schilz RJ, McLaughlin VV, Robbins IM, Groves BM, Shapiro S and Medsger TA, Jr. Continuous intravenous epoprostenol for pulmonary hypertension due to the scleroderma spectrum of disease. A randomized, controlled trial. *Ann Intern Med* 2000;132:425-434.
 80. McLaughlin VV. 'Raising the bar' for the treatment of pulmonary arterial hypertension. *Eur Heart J* 2006;27:510-511.
-

81. McLaughlin VV, Shillington A and Rich S. Survival in primary pulmonary hypertension: the impact of epoprostenol therapy. *Circulation* 2002;106:1477-1482.
 82. Galie N, Ghofrani HA, Torbicki A, Barst RJ, Rubin LJ, Badesch D, Fleming T, Parpia T, Burgess G, Branzi A, Grimminger F, Kurzyna M and Simonneau G. Sildenafil citrate therapy for pulmonary arterial hypertension. *N Engl J Med* 2005;353:2148-2157.
 83. Galie N, Beghetti M, Gatzoulis MA, Granton J, Berger RM, Lauer A, Chiossi E and Landzberg M. Bosentan therapy in patients with Eisenmenger syndrome: a multicenter, double-blind, randomized, placebo-controlled study. *Circulation* 2006;114:48-54.
 84. Lankhaar JW, Westerhof N, Faes TJ, Gan CT, Marques KM, Boonstra A, van den Berg FG, Postmus PE and Vonk-Noordegraaf A. Pulmonary vascular resistance and compliance stay inversely related during treatment of pulmonary hypertension. *Eur Heart J* 2008;
 85. Dimopoulos K, Okonko DO, Diller GP, Broberg CS, Salukhe TV, Babu-Narayan SV, Li W, Uebing A, Bayne S, Wensel R, Piepoli MF, Poole-Wilson PA, Francis DP and Gatzoulis MA. Abnormal ventilatory response to exercise in adults with congenital heart disease relates to cyanosis and predicts survival. *Circulation* 2006;113:2796-2802.
 86. Mancini DM, Katz SD, Lang CC, LaManca J, Hudaihed A and Androne AS. Effect of erythropoietin on exercise capacity in patients with moderate to severe chronic heart failure. *Circulation* 2003;107:294-299.
 87. Smith KJ, Bleyer AJ, Little WC and Sane DC. The cardiovascular effects of erythropoietin. *Cardiovasc Res* 2003;59:538-548.
 88. van der MP, Voors AA, Lipsic E, van Gilst WH and van Veldhuisen DJ. Erythropoietin in cardiovascular diseases. *Eur Heart J* 2004;25:285-291.
 89. van der MP, Lipsic E, Henning RH, Boddeus K, van d, V, Voors AA, van Veldhuisen DJ, van Gilst WH and Schoemaker RG. Erythropoietin induces neovascularization and improves cardiac function in rats with heart failure after myocardial infarction. *J Am Coll Cardiol* 2005;46:125-133.
 90. Bullard AJ, Govewalla P and Yellon DM. Erythropoietin protects the myocardium against reperfusion injury in vitro and in vivo. *Basic Res Cardiol* 2005;100:397-403.
 91. Weissmann N, Manz D, Buchspies D, Keller S, Mehling T, Voswinckel R, Quanz K, Ghofrani HA, Schermuly RT, Fink L, Seeger W, Gassmann M and Grimminger F. Congenital erythropoietin over-expression causes "anti-pulmonary hypertensive" structural and functional changes in mice, both in normoxia and hypoxia. *Thromb Haemost* 2005;94:630-638.
-

92. Klepetko W, Mayer E, Sandoval J, Trulock EP, Vachieri JL, Darteville P, Pepke-Zaba J, Jamieson SW, Lang I and Corris P. Interventional and surgical modalities of treatment for pulmonary arterial hypertension. *J Am Coll Cardiol* 2004;43:73S-80S.
 93. Sandoval J, Gaspar J, Pulido T, Bautista E, Martinez-Guerra ML, Zeballos M, Palomar A and Gomez A. Graded balloon dilation atrial septostomy in severe primary pulmonary hypertension. A therapeutic alternative for patients nonresponsive to vasodilator treatment. *J Am Coll Cardiol* 1998;32:297-304.
 94. Chang SM, Lin CC, Hsiao SH, Lee CY, Yang SH, Lin SK and Huang WC. Pulmonary hypertension and left heart function: insights from tissue Doppler imaging and myocardial performance index. *Echocardiography* 2007;24:366-373.
 95. Wensel R, Opitz CF, Anker SD, Winkler J, Hoffken G, Kleber FX, Sharma R, Hummel M, Hetzer R and Ewert R. Assessment of survival in patients with primary pulmonary hypertension: importance of cardiopulmonary exercise testing. *Circulation* 2002;106:319-324.
 96. Kawut SM, Taichman DB, Ahya VN, Kaplan S, Archer-Chicko CL, Kimmel SE and Palevsky H. Hemodynamics and survival in patients with pulmonary arterial hypertension related to systemic sclerosis. *Chest* 2003;123:344-350.
 97. McGoon M, Gutterman D, Steen V, Barst R, McCrory DC, Fortin TA and Loyd JE. Screening, early detection, and diagnosis of pulmonary arterial hypertension: ACCP evidence-based clinical practice guidelines. *Chest* 2004;126:14S-34S.
 98. Perloff JK. Auscultatory and phonocardiographic manifestations of pulmonary hypertension. *Prog Cardiovasc Dis* 1967;9:303-340.
 99. Perloff JK and Harvey WP. Mechanisms of fixed splitting of the second heart sound. *Circulation* 1958;18:998-1009.
 100. Silversides CK, Veldtman GR, Crossin J, Merchant N, Webb GD, McCrindle BW, Siu SC and Therrien J. Pressure half-time predicts hemodynamically significant pulmonary regurgitation in adult patients with repaired tetralogy of fallot. *J Am Soc Echocardiogr* 2003;16:1057-1062.
 101. Dhingra R, Ho NB, Benjamin EJ, Wang TJ, Larson MG, D'Agostino RB, Sr., Levy D and Vasan RS. Cross-sectional relations of electrocardiographic QRS duration to left ventricular dimensions: the Framingham Heart Study. *J Am Coll Cardiol* 2005;45:685-689.
 102. Karliner JS, Sarnquist FF, Graber DJ, Peters RM, Jr. and West JB. The electrocardiogram at extreme altitude: experience on Mt. Everest. *Am Heart J* 1985;109:505-513.
 103. Lehtonen J, Sutinen S, Ikaheimo M and Paakko P. Electrocardiographic criteria for the diagnosis of right ventricular hypertrophy verified at autopsy. *Chest* 1988;93:839-842.
-

104. Book WM, Parks WJ, Hopkins KL and Hurst JW. Electrocardiographic predictors of right ventricular volume measured by magnetic resonance imaging late after total repair of tetralogy of Fallot. *Clin Cardiol* 1999;22:740-746.
 105. Ahearn GS, Tapson VF, Rebeiz A and Greenfield JC, Jr. Electrocardiography to define clinical status in primary pulmonary hypertension and pulmonary arterial hypertension secondary to collagen vascular disease. *Chest* 2002;122:524-527.
 106. Kashani A and Barold SS. Significance of QRS complex duration in patients with heart failure. *J Am Coll Cardiol* 2005;46:2183-2192.
 107. Henkens IR, Scherptong RW, van Kralingen KW, Said SA and Vliegen HW. Pulmonary hypertension: the role of the electrocardiogram. *Neth Heart J* 2008;16:250-254.
 108. Luciani GB, Viscardi F, Pilati M, Crepaz R, Faggian G and Mazzucco A. Age at repair affects the very long-term outcome of sinus venosus defect. *Ann Thorac Surg* 2008;86:153-159.
 109. Neffke JG, Tulevski II, van der Wall EE, Wilde AA, van Veldhuisen DJ, Dodge-Khatami A and Mulder BJ. ECG determinants in adult patients with chronic right ventricular pressure overload caused by congenital heart disease: relation with plasma neurohormones and MRI parameters. *Heart* 2002;88:266-270.
 110. Tongers J, Schwerdtfeger B, Klein G, Kempf T, Schaefer A, Knapp JM, Niehaus M, Korte T and Hoepfer MM. Incidence and clinical relevance of supraventricular tachyarrhythmias in pulmonary hypertension. *Am Heart J* 2007;153:127-132.
 111. Zeppenfeld K, Schalij MJ, Bartelings MM, Tedrow UB, Koplan BA, Soejima K and Stevenson WG. Catheter ablation of ventricular tachycardia after repair of congenital heart disease: electroanatomic identification of the critical right ventricular isthmus. *Circulation* 2007;116:2241-2252.
 112. Gatzoulis MA, Till JA and Redington AN. Depolarization-repolarization inhomogeneity after repair of tetralogy of Fallot. The substrate for malignant ventricular tachycardia? *Circulation* 1997;95:401-404.
 113. Fox K, Borer JS, Camm AJ, Danchin N, Ferrari R, Lopez Sendon JL, Steg PG, Tardif JC, Tavazzi L and Tendera M. Resting heart rate in cardiovascular disease. *J Am Coll Cardiol* 2007;50:823-830.
 114. Horner SM, Murphy CF, Coen B, Dick DJ, Harrison FG, Vespalcova Z and Lab MJ. Contribution to heart rate variability by mechanoelectric feedback. Stretch of the sinoatrial node reduces heart rate variability. *Circulation* 1996;94:1762-1767.
 115. Gheorghiade M, Colucci WS and Swedberg K. Beta-blockers in chronic heart failure. *Circulation* 2003;107:1570-1575.
-

116. Colucci WS, Ribeiro JP, Rocco MB, Quigg RJ, Creager MA, Marsh JD, Gauthier DF and Hartley LH. Impaired chronotropic response to exercise in patients with congestive heart failure. Role of postsynaptic beta-adrenergic desensitization. *Circulation* 1989;80:314-323.
 117. Colucci WS. In vivo studies of myocardial beta-adrenergic receptor pharmacology in patients with congestive heart failure. *Circulation* 1990;82:I44-I51.
 118. Colucci WS, Kolias TJ, Adams KF, Armstrong WF, Ghali JK, Gottlieb SS, Greenberg B, Klibaner MI, Kukin ML and Sugg JE. Metoprolol reverses left ventricular remodeling in patients with asymptomatic systolic dysfunction: the REversal of VEntricular Remodeling with Toprol-XL (REVERT) trial. *Circulation* 2007;116:49-56.
 119. Olshansky B, Sabbah HN, Hauptman PJ and Colucci WS. Parasympathetic nervous system and heart failure: pathophysiology and potential implications for therapy. *Circulation* 2008;118:863-871.
 120. Daliento L, Folino AF, Menti L, Zanco P, Baratella MC and Dalla VS. Adrenergic nervous activity in patients after surgical correction of tetralogy of Fallot. *J Am Coll Cardiol* 2001;38:2043-2047.
 121. Draisma HH, Schalij MJ, van der Wall EE and Swenne CA. Elucidation of the spatial ventricular gradient and its link with dispersion of repolarization. *Heart Rhythm* 2006;3:1092-1099.
 122. Scherptong RW, Henkens IR, Man SC, Le Cessie S, Vliegen HW, Draisma HH, Maan AC, Schalij MJ and Swenne CA. Normal limits of the spatial QRS-T angle and ventricular gradient in 12-lead electrocardiograms of young adults: dependence on sex and heart rate. *J Electrocardiol* 2008;
 123. Babu-Narayan SV, Kilner PJ, Li W, Moon JC, Goktekin O, Davlouros PA, Khan M, Ho SY, Pennell DJ and Gatzoulis MA. Ventricular fibrosis suggested by cardiovascular magnetic resonance in adults with repaired tetralogy of fallot and its relationship to adverse markers of clinical outcome. *Circulation* 2006;113:405-413.
 124. McCann GP, Gan CT, Beek AM, Niessen HW, Vonk Noordegraaf A and van Rossum AC. Extent of MRI delayed enhancement of myocardial mass is related to right ventricular dysfunction in pulmonary artery hypertension. *AJR Am J Roentgenol* 2007;188:349-355.
 125. Butler PM, Leggett SI, Howe CM, Freye CJ, Hindman NB and Wagner GS. Identification of electrocardiographic criteria for diagnosis of right ventricular hypertrophy due to mitral stenosis. *Am J Cardiol* 1986;57:639-643.
 126. Chu JW, Kao PN, Faul JL and Doyle RL. High prevalence of autoimmune thyroid disease in pulmonary arterial hypertension. *Chest* 2002;122:1668-1673.
 127. Lozano HF and Sharma CN. Reversible pulmonary hypertension, tricuspid regurgitation and right-sided heart failure associated with hyperthyroidism: case report and review of the literature. *Cardiol Rev* 2004;12:299-305.
-

128. Blyth KG, Groenning BA, Mark PB, Martin TN, Foster JE, Steedman T, Morton JJ, Dargie HJ and Peacock AJ. NT-proBNP can be used to detect right ventricular systolic dysfunction in pulmonary hypertension. *Eur Respir J* 2007;29:737-744.
 129. Gan CT, McCann GP, Marcus JT, van Wolferen SA, Twisk JW, Boonstra A, Postmus PE and Vonk-Noordegraaf A. NT-proBNP reflects right ventricular structure and function in pulmonary hypertension. *Eur Respir J* 2006;28:1190-1194.
 130. Torbicki A, Kurzyna M, Kuca P, Fijalkowska A, Sikora J, Florczyk M, Pruszczyk P, Burakowski J and Wawrzynska L. Detectable serum cardiac troponin T as a marker of poor prognosis among patients with chronic precapillary pulmonary hypertension. *Circulation* 2003;108:844-848.
 131. Sun XG, Hansen JE, Oudiz RJ and Wasserman K. Exercise pathophysiology in patients with primary pulmonary hypertension. *Circulation* 2001;104:429-435.
 132. ATS statement: guidelines for the six-minute walk test. *Am J Respir Crit Care Med* 2002;166:111-117.
 133. Miyamoto S, Nagaya N, Satoh T, Kyotani S, Sakamaki F, Fujita M, Nakanishi N and Miyatake K. Clinical correlates and prognostic significance of six-minute walk test in patients with primary pulmonary hypertension. Comparison with cardiopulmonary exercise testing. *Am J Respir Crit Care Med* 2000;161:487-492.
 134. Paciocco G, Martinez FJ, Bossone E, Pielsticker E, Gillespie B and Rubenfire M. Oxygen desaturation on the six-minute walk test and mortality in untreated primary pulmonary hypertension. *Eur Respir J* 2001;17:647-652.
 135. Provencher S, Chemla D, Herve P, Sitbon O, Humbert M and Simonneau G. Heart rate responses during the 6-minute walk test in pulmonary arterial hypertension. *Eur Respir J* 2006;27:114-120.
 136. Jauhiainen T, Jarvinen VM, Hekali PE, Poutanen VP, Penttila A and Kupari M. MR gradient echo volumetric analysis of human cardiac casts: focus on the right ventricle. *J Comput Assist Tomogr* 1998;22:899-903.
 137. Babu-Narayan SV, Gatzoulis MA and Kilner PJ. Non-invasive imaging in adult congenital heart disease using cardiovascular magnetic resonance. *J Cardiovasc Med (Hagerstown)* 2007;8:23-29.
 138. Oosterhof T, Mulder BJ, Vliegen HW and de Roos A. Cardiovascular magnetic resonance in the follow-up of patients with corrected tetralogy of Fallot: a review. *Am Heart J* 2006;151:265-272.
 139. Vonk-Noordegraaf A, van Wolferen SA, Marcus JT, Boonstra A, Postmus PE, Peeters JW and Peacock AJ. Noninvasive assessment and monitoring of the pulmonary circulation. *Eur Respir J* 2005;25:758-766.
-

140. Raymond RJ, Hinderliter AL, Willis PW, Ralph D, Caldwell EJ, Williams W, Ettinger NA, Hill NS, Summer WR, de BB, Schwartz T, Koch G, Clayton LM, Jobsis MM, Crow JW and Long W. Echocardiographic predictors of adverse outcomes in primary pulmonary hypertension. *J Am Coll Cardiol* 2002;39:1214-1219.
141. Yeo TC, Dujardin KS, Tei C, Mahoney DW, McGoon MD and Seward JB. Value of a Doppler-derived index combining systolic and diastolic time intervals in predicting outcome in primary pulmonary hypertension. *Am J Cardiol* 1998;81:1157-1161.
142. Hoeper MM, Mayer E, Simonneau G and Rubin LJ. Chronic thromboembolic pulmonary hypertension. *Circulation* 2006;113:2011-2020.
143. Sitbon O, Lascoux-Combe C, Delfraissy JF, Yeni PG, Raffi F, De ZD, Gressin V, Clerson P, Sereni D and Simonneau G. Prevalence of HIV-related pulmonary arterial hypertension in the current antiretroviral therapy era. *Am J Respir Crit Care Med* 2008;177:108-113.
144. Hoeper MM, Markevych I, Spiekerkoetter E, Welte T and Niedermeyer J. Goal-oriented treatment and combination therapy for pulmonary arterial hypertension. *Eur Respir J* 2005;26:858-863.
145. Henkens IR, Gan CT, van Wolferen SA, Hew M, Boonstra A, Twisk JW, Kamp O, van der Wall EE, Schalij MJ, Vonk Noordegraaf A and Vliegen HW. Electrocardiographic monitoring of treatment response in pulmonary arterial hypertension patients. *Chest* 2008;
146. Provencher S, Jais X, Yaici A, Sitbon O, Humbert M and Simonneau G. Clinical challenges in pulmonary hypertension: Roger S. Mitchell lecture. *Chest* 2005;128:622S-628S

