



Universiteit
Leiden
The Netherlands

Iris and iridociliary melanoma : concepts in diagnosis and management

Razzaq, L.

Citation

Razzaq, L. (2011, October 11). *Iris and iridociliary melanoma : concepts in diagnosis and management*. Retrieved from <https://hdl.handle.net/1887/17921>

Version: Corrected Publisher's Version

License: [Licence agreement concerning inclusion of doctoral thesis in the Institutional Repository of the University of Leiden](#)

Downloaded from: <https://hdl.handle.net/1887/17921>

Note: To cite this publication please use the final published version (if applicable).



Chapter **9**

**Corneal endothelial cell density after Ruthenium
plaque radiation therapy for iris melanoma patients**

Lubna Razzaq¹, Marina Marinkovic¹, Martine J. Jager¹, Jaco C. Bleeker¹,
Gregorius P.M. Luyten¹, Rob J.W. de Keizer^{1,2}

¹ Department of Ophthalmology, Leiden University Medical Center (LUMC), Leiden,
the Netherlands.

² Department of Ophthalmology, Antwerp University Hospital, Antwerp, Belgium.

Submitted for publication

Abstract

Purpose: To determine the effect of Ruthenium (Ru-106) plaque radiation, for iris and iridociliary melanoma, on corneal endothelium by measuring endothelial cell density (ECD).

Methods: Between December 1st, 2009 and February 28th, 2011, ECD was determined in both eyes of 63 patients with iris melanocytic tumors. Patients were divided into four groups: patients with: iris naevus (Group 1, n = 11); iris melanoma that had not yet undergone treatment (Group 2, n = 19); iris melanoma after Ruthenium brachytherapy (Group 3, n = 15); and iris melanoma after Ruthenium brachytherapy and phacoemulsification (Group 4, n = 18). A paired t-test was performed to obtain the difference of the mean values of ECD between the two eyes. A p-value of < 0.05 was considered significant. _

Results: The mean ECD was 2924 in iris naevus, 2751 in iris melanoma, 2647 in iris melanoma after Ruthenium, and 1613 mm² in iris melanoma after Ruthenium and phaco. The only significant difference occurred between the eye after Ruthenium with phaco and its contralateral eye (p-value: <0.001). However, no significant difference was found between the two eyes in any of the other three groups (p-value > 0.05).

Conclusion: Corneal endothelial cell density (ECD) is not affected by the presence of an iris tumor such as a naevus or a melanoma and treatment by plaque brachytherapy but it is significantly decreased after phacoemulsification for secondary cataract following brachytherapy.

Introduction

Iris melanomas are the most common primary malignancy of the iris. Their incidence varies from 49-72% of all iris tumors, and they account for 3-10% of all uveal melanomas [1-3]. Traditionally treatment modalities for iris melanoma include iridectomy, iridocyclectomy and enucleation [4,5]. Because of the high incidence of complications and visual morbidity from these surgical procedures, plaque brachytherapy and proton beam radiotherapy have also been introduced for the treatment of iris melanoma. The radioactive plaques that are being used are Iodine-125, Palladium-103 and Ruthenium-106 [6-11]. For treatment of iris melanoma a radioactive plaque is placed directly over the cornea. This direct irradiation to the cornea may damage the cornea and can lead to corneal problems. Potential complications of corneal irradiation, using radioactive plaques or proton beam therapy, are corneal erosions, corneal epitheliopathy, delayed corneal healing and corneal necrosis [6-8,10]. Following a case of corneal endothelial decompensation, we decided to analyze the effect of radiation on corneal endothelial cells *in vivo*.

The corneal endothelium is a single cell layer, which forms the innermost part of the cornea, and seems not to regenerate. The primary function of this cell layer is to maintain the relatively dehydrated state of the corneal stroma and therefore the clarity of the cornea [12,13]. Corneal endothelial cell density (ECD) can be used to evaluate the status of the cornea [14]. A significant decrease in ECD leads to corneal oedema; as a result, the cornea becomes hazy, leading to loss of vision. Corneal endothelial cell density slowly declines with age, but usually remains high enough to maintain lifelong corneal clarity [15,16]. Corneal endothelial cell damage is known to be caused by intraocular surgery, including phacoemulsification, as well as by contact lens wear, refractive surgery, trauma and hereditary endothelial dystrophies [17-20]. Cataract is the most common reported complication encountered after radiotherapy for iris melanoma; patients treated with plaque brachytherapy are more likely to undergo phacoemulsification than the normal population.

The present study was performed to evaluate the effect of ruthenium plaque radiation on the corneal endothelium by determining the ECD.

Materials and Methods

A study was carried out from December 1st, 2009 to February 28th, 2011, involving 63 patients with iris melanocytic tumors. Inclusion criteria for ECD examination in these patients were eyes with iris naevi or iris melanoma. Excluded were the

patients with previous history of corneal and/or ocular surgery, contact lens wear, trauma, and any corneal/ocular disease. All the patients were informed about the procedure and their consent was obtained in accordance with the Helsinki Declaration.

Patients were divided into four groups, i.e. Group 1: iris naevus, Group 2: untreated iris melanoma, Group 3: iris melanoma after Ruthenium brachytherapy (iris melanoma + Ru) and Group 4: iris melanoma after Ruthenium brachytherapy and phacoemulsification in the tumor eye (iris melanoma + Ru + phaco).

The Ruthenium applicator type was noted for all the patients in the third and fourth group and the surface area of cornea covered by the Ruthenium plaque was calculated for each patient. The radiation dose received by the corneal endothelium during Ru plaque brachytherapy was also calculated, taking the distance of endothelium from the surface of cornea as being 0.8mm. The presence of anterior chamber extension and corneal touch of melanoma were also recorded. The time interval between the application of Ruthenium plaque and measurement of ECD was calculated as well as the time interval between the Ru plaque application and phacoemulsification and between phacoemulsification and ECD measurement. The correlation between these variables and ECD was examined using Spearman's correlation coefficient.

The ECD was recorded by using the SP2000 non-contact specular microscope (Topcon, Tokyo, Japan). Photographs of the cornea were taken using the automatic-mode. All complete cells on the image were used to estimate the cell density. The estimated ECD was the mean of three consecutive measurements, and it was expressed as the number of cells per mm².

ECD was measured in both eyes; the normal eye was taken as control. We used paired t-tests to test for differences between the melanoma/naevus and fellow control eyes. A P-value of < 0.05 was considered significant.

Results

A total of 63 patients was included in this study and divided into four groups as mentioned above: (Group 1) iris naevus, (Group 2) untreated iris melanoma, (Group 3) iris melanoma after Ruthenium brachytherapy (iris melanoma + Ru) and (Group 4) iris melanoma after Ruthenium brachytherapy and phacoemulsification (iris melanoma + Ru + phaco) (Table 1). The location of iris melanoma in group 3 and 4 is given in Figures 1 A & B. Ru plaque CIA was used in 13/15 patients in group 3 and a CCA in two patients. In group 4, 16/18 patients had CIA while the remaining two had CCA. The mean corneal surface area covered by the Ruthenium plaque in Group 3 was 48mm² (range: 30 – 70) and in Group 4

Table 1 Baseline characteristics for patients in all four groups

	Iris naevus n = 11 (%)	Iris melanoma n = 19 (%)	Iris melanoma + Ru n = 15 (%)	Iris melanoma + Ru + Phaco n = 18 (%)
Age (years)	54.1 (range: 37-74)	65.6 (range: 43-87)	54.3 (range: 24-80)	58.9 (range: 21-75)
Gender				
Male	3 (27)	7 (36)	9 (60)	9 (50)
Female	8 (73)	12 (64)	6 (40)	9 (50)
Eye				
OD	6 (55)	12 (64)	10 (67)	10 (56)
OS	5 (45)	7 (36)	5 (33)	8 (44)
Anterior chamber extension present	3 (27)	10 (53)	11 (74)	10 (56)
Corneal touch present	0 (0)	2 (10)	3 (20)	2 (11)

it was 53mm² (range: 30 – 70). The mean radiation dose at the endothelium in Group 3 was 320 Gy (range: 234 – 497) and in Group 4 it was 390 Gy (range: 241 – 675). The difference in radiation dose between Group 3 and 4 is -70 Gy (p-value: 0.042). The mean time interval between the application of Ruthenium plaque for iris melanoma and estimation of ECD was 13 months in Group 3 (range: 3 – 56) and 69 months in Group 4 (range: 12 – 120 months), while the time interval between phacoemulsification in the melanoma treated eye and ECD estimation was 33 months in Group 4 (range: 1 – 73). There was no significant correlation found between ECD and age, surface area covered with Ru plaque, radiation dose at the endothelium and time interval after the Ru plaque placement in either group 3 or group 4 (Table 2a&b).

The ECD values obtained in different groups are given in Table 3. No significant differences were found between the contralateral eye and the eye containing the iris naevus (p=0.807; 95% CI:-177 – 141), the iris melanoma (p=0.198; 95% CI:-170.1 – 37.8) and the iris melanoma after Ruthenium (p=0.061; 95%CI: - 533 – 13). However, a significant difference was found between the contralateral eye and the eye with an iris melanoma after both Ruthenium and phaco (p=<0.001; 95%CI: -1574.5 – -1104.1) (Figure 2). All the patients in this last group underwent uneventful phacoemulsification surgery without any intra-operative and

Figure 1 **A:** Location of iris melanoma in patients with iris melanoma + Ru (Group 3) (n = 15) **B:** Location of iris melanoma in patients with iris melanoma + Ru + phaco (Group 4) (n = 18)

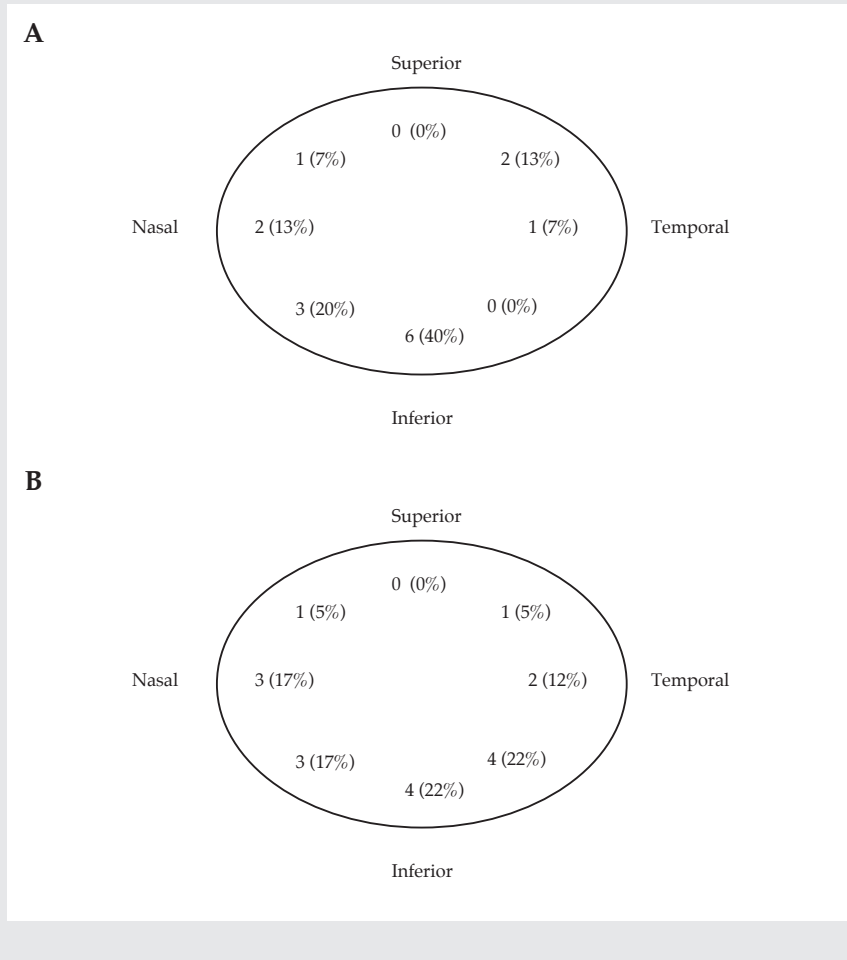


Table 2a ECD Correlation with different variables in iris melanoma + Ru group (Group 3)

Variable	Spearman correlation (r)	p value (2-tailed)
Age	-0.278	> 0.05
Surface area covered by Ru plaque	0.040	> 0.05
Endothelium radiation dose	-0.028	> 0.05
Time interval between Ru and ECD	0.076	> 0.05

Table 2b ECD correlation with different variables in iris melanoma + Ru + phaco group (Group 4)

Variable	Spearman correlation (r)	p value (2-tailed)
Age	0.095	> 0.05
Surface area covered by Ru plaque	0.359	> 0.05
Endothelium radiation dose	-0.253	> 0.05
Time interval between Ru and ECD	-0.074	> 0.05
Time interval between phaco and ECD	-0.109	> 0.05

post-operative complications. One patient developed CME (cystoid macular edema) a few months after phacoemulsification, which resolved after treatment with acetazolamide. Another patient in this group with a low ECD developed corneal oedema, while none of the others had any visible corneal problems. The differences between the two eyes in all four groups are presented in Figure 3.

Table 3 Measured ECD in both the eyes of different groups

Corneal endothelial cell density (ECD)	Iris naevus n = 11 Cells/mm ²	Iris melanoma n = 19 Cells/mm ²	Iris melanoma + Ru n = 15 Cells/mm ²	Iris melanoma + Ru + Phaco n = 18 Cells/mm ²
Mean \pm SD				
Affected eye	2924 \pm 589	2751 \pm 371	2647 \pm 717	1613 \pm 548
Control eye	2942 \pm 547	2817 \pm 425	2907 \pm 608	2952 \pm 394
Minimum				
Affected eye	1877	2194	1323	636
Control eye	1605	2034	1713	2183
Maximum				
Affected eye	3607	3502	2834	2669
Control eye	3580	3611	4208	2952
P- value	0.807	0.198	0.061	< 0.001

As the last group of iris melanoma + Ru + phaco showed significant differences in the mean values of ECD between the two eyes, we wondered whether this difference was caused by age or by the phacoemulsification. The expected ECD was calculated for all the patients in that group according to the age and phaco-related loss and the data were compared with the actual ECD. We calculated the ECD according to the age of each individual patient by taking the normal ECD (3000 – 3500 cells/mm² in a young adult); after age 18, ECD decreases by 0.6% per year, reaching 2500 cells/mm² at the age of 80 [15,21,22]. The difference between the estimated and expected ECD according to age was significant ($p < 0.001$; 95% CI: - 1832 – -1185). Similarly, the ECD was estimated according to the time interval after phaco, taking a loss of 2.5% per year after cataract surgery or a mean loss of 36% for 10 years [23]. The difference between expected and measured ECD was significant ($p < 0.001$; 95% CI: -1362 – -885) (Figure 4).

Figure 2 An example of endothelial cell count (ECD) measured in both eyes of a patient from group 4. (melanoma + Ru + phaco). ECD in untreated eye (RE) is 3024 cells/mm² and treated eye (LE) is 724 cells/mm²

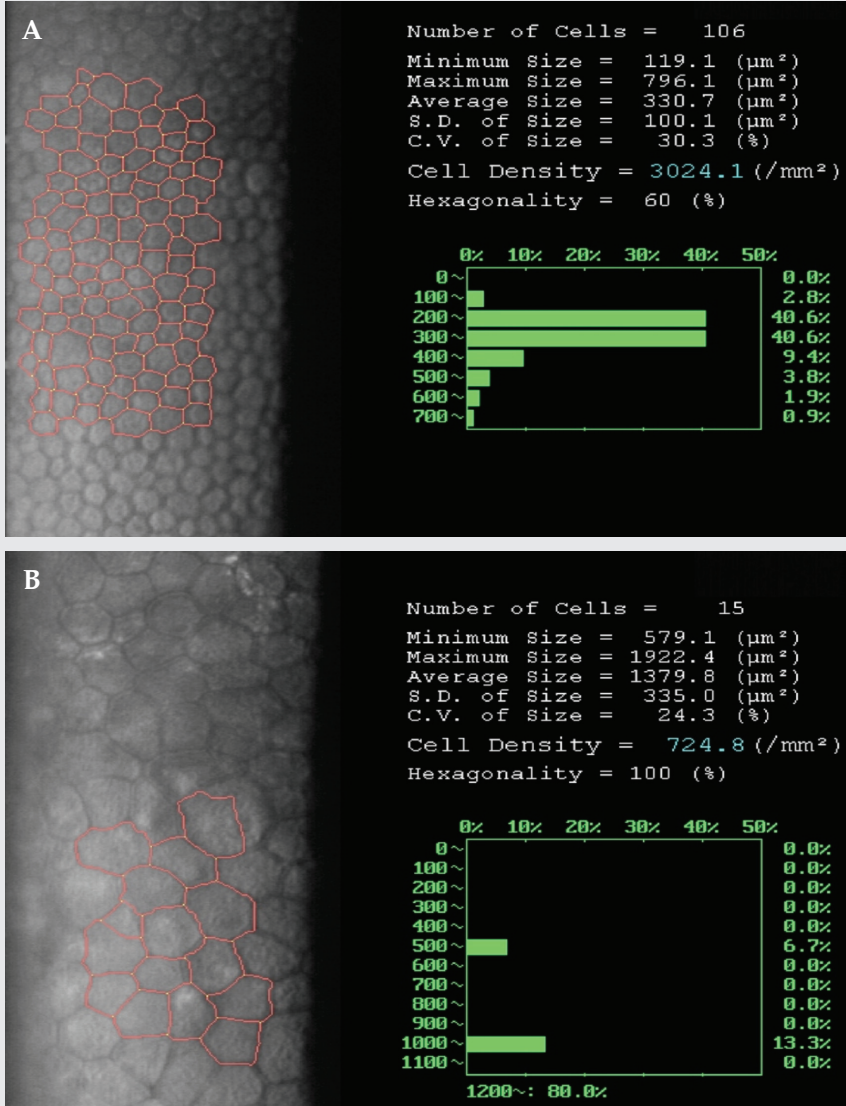


Figure 3 ECD in all four groups showing the difference between the tumor eye and contra lateral eye with p-value and 95% CI

- A. Group 1: $p=0.807$; 95% CI: -177 – 141.
- B. Group 2: $p=0.198$; 95% CI: -170.1 – 37.8.
- C. Group 3: $p=0.061$; 95% CI: -533 – 13.
- D. Group 4: $p< 0.001$; 95% CI: -1574.5 – -1104.1

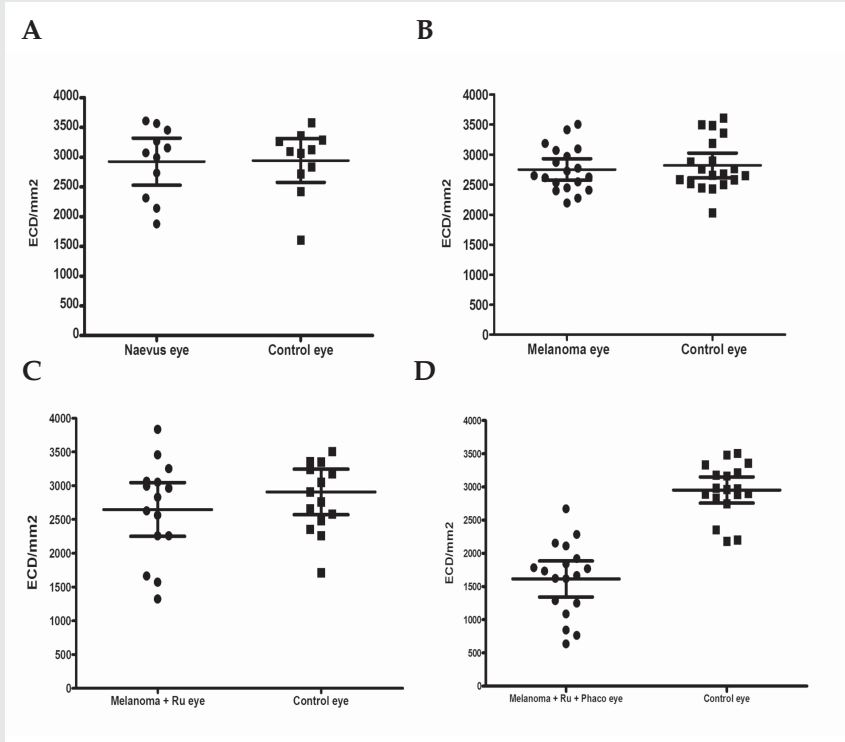
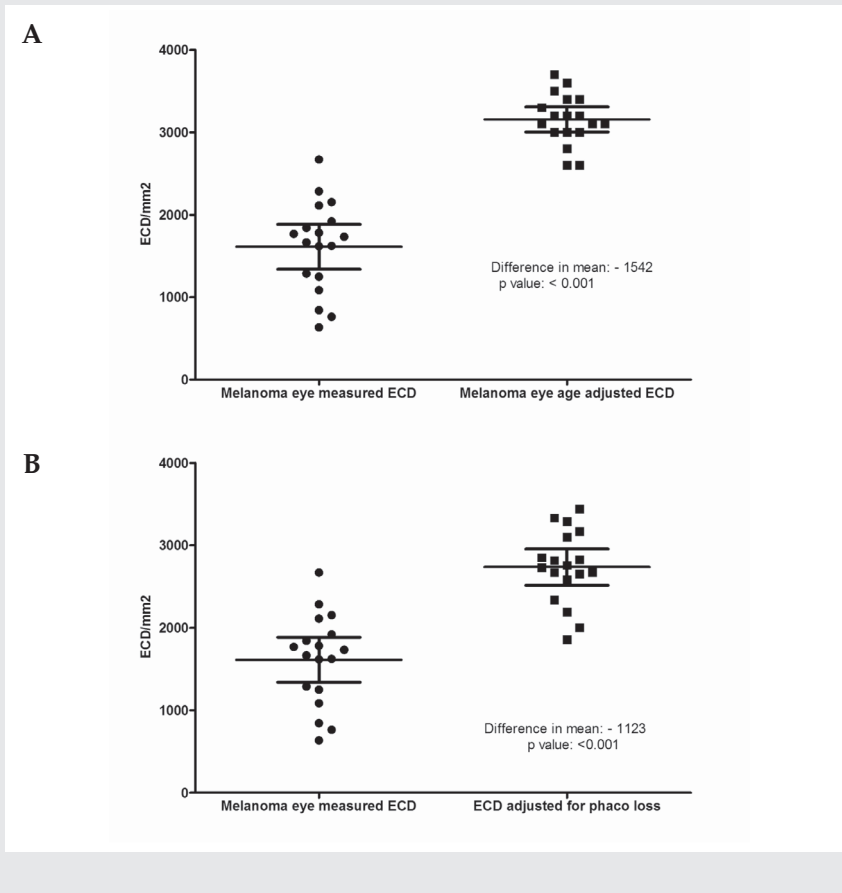


Figure 4 Difference in actual ECD and estimated ECD according to age (A) and phaco loss (B), showing 95% CI and p-values, for patients in iris melanoma + Ru + phaco group (n=18).



Discussion

During the last two decades, iris melanoma management has been changed to conservative treatment with radiotherapy in the form of plaque brachytherapy using Iodine, Palladium, Ruthenium and Proton beam radiotherapy. All the studies using these modes of treatment have reported good results for both tumor control as well as corneal integrity. The main complication of all of these treatment modalities is the development of radiation-related cataract, which is

treated by phacoemulsification [7-9,11]. Therefore, these patients need phacoemulsification more frequently than the normal population. We have used Ruthenium plaque for iris melanoma since 1997 and the results showed good tumor control with few side effects. The only corneal complication was corneal erosion on the first post-operative day in 25% of the patients, which healed with topical treatment [10].

However, one young patient with iris melanoma in our series treated with Ru in 2002 underwent an uneventful phacoemulsification for secondary cataract four years later, and developed local peripheral corneal oedema because of endothelial decompensation in 2009 (i.e. seven years after plaque treatment and three years after phacoemulsification). The ECD in this patient showed a very low count in the affected eye and a normal count in the fellow eye, which excluded the possibility of hereditary corneal dystrophy, which is usually bilateral. The cause of this low ECD was not known and suggested mechanisms are: 1) the melanoma itself, 2) Ruthenium plaque therapy and/or 3) phacoemulsification-related loss of endothelium. Our literature search did not show any study determining the effect of radiation therapy for iris melanoma on ECD although there are many studies which established the loss of ECD with aging and phacoemulsification [15,18,22-25]. To understand the significance of each mechanism in relation to low ECD, we performed a study to determine ECD in iris tumor patients and divided our patients into four groups as described earlier.

We did not observe any differences between the contralateral eye and the tumor eye in the first three groups of our study i.e. iris naevus (p value: 0.807), iris melanoma (p value: 0.198), and iris melanoma treated with Ruthenium (p-value: 0.061), but a significant difference was found in the last group of iris melanoma treated with Ruthenium and phacoemulsification (p value: < 0.001). In order to determine whether the low numbers were due to aging or phacoemulsification, ECD was calculated for both age and phaco-related loss and the differences were compared with the actual ECD. The difference between these estimates and the actual ECD was significant (p value: <0.001), with a greater than expected loss in actual ECD. We also estimated the correlation between ECD and different variables like surface area of cornea covered with plaque, radiation dose received by endothelium, time interval between Ruthenium and ECD and between phaco and ECD, but no significant correlation was found with any of these variables.

We do not know the exact mechanism of decreased ECD in patients after phaco, who were treated with Ruthenium plaque for iris melanoma, but the postulated mechanism can be that Ruthenium plaque radiation damages the endothelium (first hit); however, this does not yet lead to a decrease in ECD as the cells will not be lost until they try to divide. Phacoemulsification further damages the endothelium (second hit) and endothelium cells try to divide to repair the

damage and are lost, leading to a decreased ECD. Further experimental research is needed to know the exact etiology.

Another mechanism may be that the Ruthenium plaque was placed on one of the anterior ciliary artery and caused ischemia of the anterior segment including endothelial decompensation but we did not find any cells in anterior chamber/vitreous, acute uveitis, or hypotony, which are signs of ischemia. In group 4, most of the iris melanomas were located inferiorly (61%) but this is comparable to the number of iris melanomas located inferiorly in group 3 (60%).

As far as we know this is the first report determining the ECD after Ruthenium plaque brachytherapy for iris melanoma. The limitation of our study is the relatively small number of patients in each group and the absence of ECD counts before plaque treatment in most of the treated patients; we therefore took the other eye as an internal control, because the mean difference between normal fellow eyes is known to be only 0.7% [26].

This study enables the ophthalmologist to know that patients who have been treated with plaque brachytherapy are at high risk of developing endothelial decompensation after cataract surgery so all possible precautions should be taken to decrease the endothelium damage such as using closed shell techniques, and placing the surgery in experienced hands. Also the patients should be informed about the late complication of development of endothelium decompensation after cataract surgery and the need of long and regular follow-up.

We conclude that corneal endothelial cell density is not affected by the presence of an iris tumor such as naevus and melanoma and its treatment by Ruthenium plaque brachytherapy but it is significantly decreased by phacoemulsification for secondary cataract.

Acknowledgements

We are thankful to Dr. C. Creutzberg and Dr. M. Ketelaars for calculating the radiation dose at the endothelium for this study.

References

1. Ashton N. Primary tumors of the iris. *Br.J.Ophthalmol.* 1964;48:650-68.
2. Heath P. Tumors of the iris: Classification and clinical follow-up. *Trans.Am.Ophthalmol.Soc.* 1964;62:51-85.
3. Duke JR, Dunn SN. Primary tumors of the irs. *AMA.Arch.Ophthalmol.* 1958;59:204-14.
4. Arentsen JJ, Green WR. Melanoma of the iris: report of 72 cases treated surgically. *Ophthalmic Surg.* 1975;6:23-37.
5. Naumann GO, Rummelt V. Block excision of tumors of the anterior uvea. Report on 68 consecutive patients. *Ophthalmology* 1996;103:2017-27.
6. Shields CL, Shields JA, De PP, Singh AD, Hernandez C, Brady LW. Treatment of non-resectable malignant iris tumours with custom designed plaque radiotherapy. *Br.J.Ophthalmol.* 1995;79:306-12.
7. Shields CL, Naseripour M, Shields JA, Freire J, Cater J. Custom-designed plaque radiotherapy for nonresectable iris melanoma in 38 patients: tumor control and ocular complications. *Am.J.Ophthalmol.* 2003;135:648-56.
8. Damato B, Kacperek A, Chopra M, Sheen MA, Campbell IR, Errington RD. Proton beam radiotherapy of iris melanoma. *Int.J.Radiat.Oncol.Biol.Phys.* 2005;63:109-15.
9. Finger PT. Plaque radiation therapy for malignant melanoma of the iris and ciliary body. *Am.J.Ophthalmol.* 2001;132:328-35.
10. Razaq L, Keunen JE, Schaliij-Delfos NE, Creutzberg CL, Ketelaars M, de Keizer RJ. Ruthenium plaque radiation therapy for iris and iridociliary melanomas. *Acta Ophthalmol.* 2010.
11. Fernandes BF, Krema H, Fulda E, Pavlin CJ, Payne DG, McGowan HD et al. Management of iris melanomas with 125Iodine plaque radiotherapy. *Am.J.Ophthalmol.* 2010;149:70-6.
12. Maurice DM. The permeability to sodium ions of the living rabbit's cornea. *J.Physiol* 1951;112:367-91.
13. Harris JE, Nordquist LT. The hydration of the cornea. I. The transport of water from the cornea. *Am.J.Ophthalmol.* 1955;40:100-10.
14. Modis L, Jr., Langenbucher A, Seitz B. Corneal endothelial cell density and pachymetry measured by contact and noncontact specular microscopy. *J.Cataract Refract.Surg.* 2002;28:1763-9.
15. Moller-Pedersen T. A comparative study of human corneal keratocyte and endothelial cell density during aging. *Cornea* 1997;16:333-8.
16. Sanchis-Gimeno JA, Lleo-Perez A, Alonso L, Rahhal MS, Martinez SF. Corneal endothelial cell density decreases with age in emmetropic eyes. *Histol.Histopathol.* 2005;20:423-7.
17. Ravalico G, Tognetto D, Palomba MA, Lovisato A, Baccara F. Corneal endothelial function after extracapsular cataract extraction and phacoemulsification. *J.Cataract Refract.Surg.* 1997;23:1000-5.
18. Walkow T, Anders N, Klebe S. Endothelial cell loss after phacoemulsification: relation to preoperative and intraoperative parameters. *J.Cataract Refract.Surg.* 2000;26:727-32.
19. Carlson KH, Bourne WM. Endothelial morphologic features and function after long-term extended wear of contact lenses. *Arch.Ophthalmol.* 1988;106:1677-9.
20. Carlson KH, Bourne WM, Brubaker RF. Effect of long-term contact lens wear on corneal endothelial cell morphology and function. *Invest Ophthalmol.Vis.Sci.* 1988;29:185-93.
21. Bourne WM, McLaren JW. Clinical responses of the corneal endothelium. *Exp.Eye Res.* 2004;78:561-72.
22. Yee RW, Matsuda M, Schultz RO, Edelhauser HF. Changes in the normal corneal endothelial cellular pattern as a function of age. *Curr.Eye Res.* 1985;4:671-8.
23. Bourne WM, Nelson LR, Hodge DO. Continued endothelial cell loss ten years after lens implantation. *Ophthalmology* 1994;101:1014-22.
24. Roszkowska AM, Colosi P, D'Angelo P, Ferreri G. Age-related modifications of the corneal endothelium in adults. *Int.Ophthalmol.* 2004;25:163-6.
25. Lundberg B, Jonsson M, Behndig A. Postoperative corneal swelling correlates strongly to corneal endothelial cell loss after phacoemulsification cataract surgery. *Am.J.Ophthalmol.* 2005;139:1035-41.
26. van Dooren BTH. The corneal endothelium reflected. Ref Type: Thesis/Dissertation. 2007.

