



Universiteit
Leiden
The Netherlands

Iris and iridociliary melanoma : concepts in diagnosis and management

Razzaq, L.

Citation

Razzaq, L. (2011, October 11). *Iris and iridociliary melanoma : concepts in diagnosis and management*. Retrieved from <https://hdl.handle.net/1887/17921>

Version: Corrected Publisher's Version

License: [Licence agreement concerning inclusion of doctoral thesis in the Institutional Repository of the University of Leiden](#)

Downloaded from: <https://hdl.handle.net/1887/17921>

Note: To cite this publication please use the final published version (if applicable).



Chapter **6**

**Iris melanoma in a child treated with
iridectomy and a phakic iris repair implant lens:
A case report of 8 years follow-up**

Rob J.W. de Keizer¹, Lubna Razzaq¹, Ad M. Verbeek², Marie J. Tassignon³

¹Department of Ophthalmology, Leiden University Medical Center, Leiden, the Netherlands.

²Department of Ophthalmology, Nijmegen University Medical Center, Nijmegen, the Netherlands.

³Department of Ophthalmology, Antwerp University Hospital, Antwerp, Belgium.

The incidence of iris melanoma is 8% of all the uveal melanomas [1]. In children and adolescents iris melanoma accounts for 0.6% to 1.6% of all the uveal melanomas [2]. Iris naevi, cystic lesions, inflammatory processes and neoplasms can simulate iris melanoma [3].

We report a 12 years old boy referred to the Department of Ophthalmology, Antwerp and then to Leiden because of a melanocytic lesion on the right iris without complaints. The visual acuity was 20/20 in both the eyes. Slit lamp examination showed a pigmented iris lesion in the inferior quadrant of the right eye with diameter of 6.8mm. The pupil showed a visible deformation, abnormal vasculature was present with ectropion uveae (Figure 1a). Gonioscopy revealed a flat pigmented lesion extending in the open anterior chamber angle. There was no cataract and optic disc was normal. Fluorescence angiography of right eye showed only abnormal vessels. The left eye was normal. Intraocular pressure (IOP) was 33 mmHg in the right eye and 17 mmHg in the left eye. High IOP was believed to be steroid induced as patient was already being treated with steroid drops to rule out xanthogranuloma. The topical treatment was ended and IOP returned to normal afterwards. Ultrasound biomicroscopy (UBM) demonstrated an iris tumour 1 mm thick, with secondary cysts but without extension to the ciliary body. These findings were in the favor of iris melanoma (Figure 1b). The most probable diagnosis put forward on clinical findings and UBM was an iris melanoma. The follow-up examinations showed progression of the lesion and it was decided to extirpate the tumour.

Local excision was performed by one of the authors (MJT) in April 2001 consisting of a sectorial iridectomy and implantation of a customized designed phakic iris repair implant to reduce postoperative photophobia (Figure 2a). Main consideration was to implant the iris-clip lens over the natural crystalline lens, clipped in the remaining iris tissue. Postoperative visual acuity was 20/20 without correction and it remained unchanged during the last 8 years of follow-up. Histology showed iris melanoma spindle cell type A. Patient and family is completely satisfied with the cosmetic and functional results of the treatment (Figure 2b).

Figure 1 (A) Iris melanoma located in the right eye of our patient (B) UBM image showing iris tumor having secondary cysts, with no extension to anterior chamber angle or ciliary body

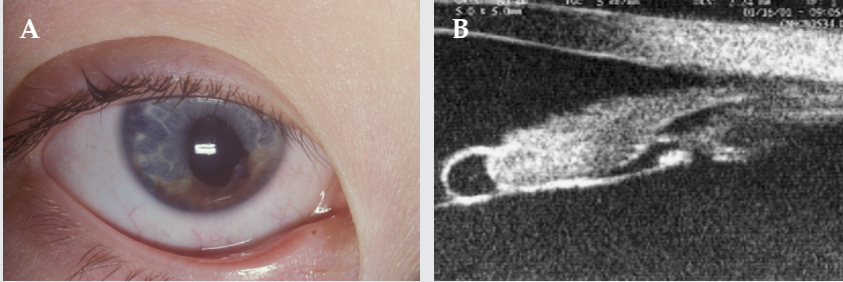
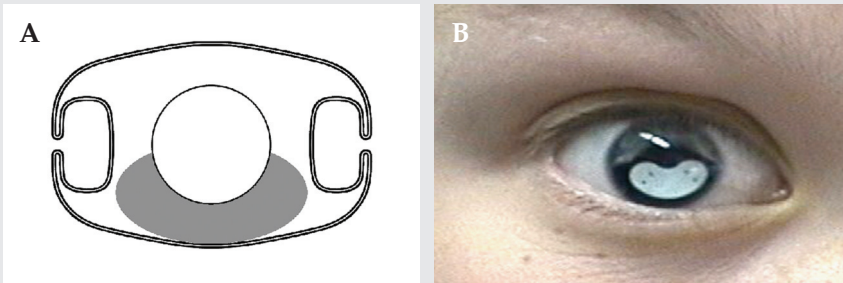


Figure 2 (A) Customized Ophtec phakic iris repair implant (B) Post-operative result showing the iris repair implant in place



Discussion

The diagnosis of an iris melanoma is difficult in children. Differentiation with iris naevus, iris cyst, iris metastasis, xanthogranuloma, Lisch nodule and Cogan-Reese syndrome should be done. The diagnostic approach was based on our clinical experience and the Harbour classification [4]. In our patient, 3 points of Harbour classification were positive.

Treatment options for iris melanoma are: local excision (iridectomy), enucleation and plaque or proton beam radiotherapy [5]. Complications of iridectomy

are photophobia, cataract, corneal edema, astigmatism, hypotony, retinal detachment and hemorrhage. Also the spherical aberrations in phakic eyes have shown rising values with increasing pupillary diameter and can be a problem after iridectomy due to the increase pupillary size [6]. Our therapeutical approach was based on the fact that because our patient was quite young and radiation complications in children are not uncommon [7,8]. So we preferred local excision and designed a phakic iris lens in collaboration with Ophtec® to cover the excised area. Important fact is that the iris implant was intended to be positioned over the patient's natural lens. We have now 8 years of follow-up of our patient with vision of 20/20 in both the eyes and no complication. .

Conclusion

Management of an iris melanoma in selected cases, where radiation is undesirable, can consist of iridectomy with special phakic iris-clip lens to achieve a good functional and cosmetic result provided the lesion is limited to the iris. Long term follow-up is necessary to detect recurrence of melanoma and any post operative complications.

References

1. Shields JA. Melanocytic tumors of the iris In: Eugenia A.K, eds. *Diagnosis and Management of Intraocular Tumours*. USA: Mosby; 1983;83.
2. Shields CL, Shields JA, Milite J, et al. Uveal melanoma in teenagers and children: a report of 40 cases. *Ophthalmology* 1991;98:1662-66.
3. Spalton DJ, Hitchings RA, Hunter PA. *Atlas of clinical ophthalmology*. London: Wolfe Publishing, Mosby-Yearbook, 1994: 9-11.
4. Harbour JW, Augsburger JJ, et al: Initial management and follow up of Melanocytic iris tumours: *Ophthalmology* 1995;102:1987-93.
5. Damato B, Kacperek A, Chopra M, et al. Proton beam radiotherapy of iris melanoma. *Int J Radiat Oncol Biol Phys*. 2005;63[1]: 109-15.
6. Kohnen T, Kasper T: At what pupillary size does an aspheric matter? *Cataract and refractive surgery* 2007;2[7]:49-51.
7. Messmer EP, Fritze H, Mohr C et al. Longterm treatment effects in patients with bilateral retinoblastoma:ocular and mid-facial findings. *Graefe's Arch Clin Exp Ophthalmol*. 1991;229:309-14
8. Snijders-Keilholz A, De Keizer RJ, Goslings BM et al. Probable risk of tumour induction after retro-orbital irradiation for Graves' ophthalmopathy. *Radiother Oncol* 1996;38[1]:69-71.

