Universiteit Leiden
The Netherlands

Health and demography in late 19th century Kimberley : a palaeopathological assessment

Merwe, A.E. van der

Citation

Merwe, A. E. van der. (2010, September 8). *Health and demography in late 19th century Kimberley : a palaeopathological assessment*. Barge's Anthropologica, Leiden. Retrieved from https://hdl.handle.net/1887/15931

Version:	Corrected Publisher's Version
License:	Licence agreement concerning inclusion of doctoral thesis in the Institutional Repository of the University of Leiden
Downloaded from:	https://hdl.handle.net/1887/15931

Note: To cite this publication please use the final published version (if applicable).

Health and Demography in Late 19th Century Kimberley

A Palaeopathological Assessment

Alie Emily van der Merwe

Colophon

Health and Demography in Late 19th Century Kimberley

A Palaeopathological Assessment

Alie Emily van der Merwe

Thesis Leiden University Medical Centre

Cover illustration:

'Big Hole' Kimberley Mine. Photograph by M. Loots

Histology section of archaeological bone

© 2010 A.E. van der Merwe, Leiden, the Netherlands. All rights reserved. No part of this book may be reproduced or transmitted, in any form or by any means, without the written permissions of the author.

Published by Barge's Anthropologica, Leiden

Barge's Anthropologica Serie Nr. 14

Printed by Ipskamp Drukkers

ISBN: 978-90-78943-02-0

Health and Demography in Late 19th Century Kimberley

A Palaeopathological Assessment

Proefschrift

Ter verkrijging van
de graad van Doctor aan de Universiteit Leiden,
op gezag van Rector magnificus Prof.Mr. P.F. van der Heijden,
volgens besluit van het College voor Promoties
te verdedigen op woensdag 8 september 2010
klokke 16:15 uur

door

Alie Emily van der Merwe
geboren te Vanderbijlpark, Zuid Afrika
in 1982

Promotiecommissie

Promotores

Prof. Dr. G.J.R. Maat
Prof. Dr. M. Steyn — University of Pretoria, South Africa

Overige Leden

Prof. Dr. M. van Kolfschoten — University of Leiden

Prof. Dr. P.C.W. Hogendoorn — Leiden University Medical Centre

Dr. Tj.D. Bruintjes — Gelre Ziekenhuizen, Apeldoorn

The work presented in this thesis was performed at the Department of Anatomy, University of Pretoria, South Africa and the Department of Anatomy and Embryology of the Leiden University Medical Centre as granted by SARHA (South African Resource and Heritage Agency) in excavation permit 80/03/04/004/51. The project was funded by the South African National Research Foundation and NAVKOM.

Financial support by the Stichting Nederlands Museum voor Anthropologie en Praehistorie and the Nederlandse Stichting voor Antropobiologie for the publication of this thesis is gratefully acknowledged.

Aan mijn moeder, zus en Johan Schutte

Contents

Chapter 1
Introduction **1**
In part accepted for publication in the South African Archaeological Bulletin

1.1 The study of palaeopathology 3
1.2 Kimberley – Historical setting 6
1.3 The purpose of the study 9

Chapter 2
Materials and Methods **13**
In part accepted for publication in the South African Archaeological Bulletin

2.1 Excavation of skeletal material 15
2.2 Accession numbers 16
2.3 Methods 19
2.3.1 Methods for sex determination 19
2.3.2 Methods for Age determination 23
2.3.3 Methods for the estimation of antemortem stature 26

Chapter 3
Results **33**
In part accepted for publication in the South African Archaeological Bulletin

3.1 Archaeological findings 35
3.2 Demography 37
3.3 Palaeopathology 38

Chapter 4
Trauma and Amputations in 19th Century Miners from Kimberley, South Africa **43**
International Journal of Osteoarchaeology (2010), 20(3):291-306

Chapter 5
Adult Scurvy in Skeletal Remains of Late 19th Century Mineworkers from Kimberley South Africa **67**
International Journal of Osteoarchaeology (2010), 20(3):307-316

Chapter 6
Ossified Haematomas and Infectious Bone Changes on the Anterior Tibia: Histomorphological Features as an Aid for Accurate Diagnosis **85**
International Journal of Osteoarchaeology (2010), 20(2):227 - 239

Chapter 7
Dental Health of 19th Century Mineworkers from Kimberley, South Africa **109**
International Journal of Osteoarchaeology DOI: 10.1002/oa.1143

Chapter 8
The High Prevalence of Supernumerary Teeth in skeletal Remains from a 19th Century Mining Community from Kimberley, South Africa **135**
South African Dental Journal (2009), 64(4):162 - 166

Chapter 9
The Origins of Late 19th Century Migrant Diamond Miners Uncovered in Kimberley, South Africa **149**
Accepted for publication in the South African Archaeological Bulletin

Chapter 10
General Discussion **175**
In part accepted for publication in the South African Archaeological Bulletin

Appendices

A.1 Individual catalogue 189
A.2 List of grave goods 245
A.3 Commingled remains catalogue 249
A.4 Discriptive craniometry data 267

Summary **271**

Nederlandse Samenvatting **277**

Curriculum Vitae **283**

Acknowledgements **289**

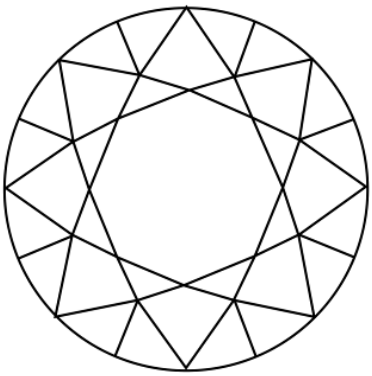

CHAPTER 1

Introduction

Modified from article accepted for publication as:

The history and health of a nineteenth-century migrant mine-worker population from Kimberley, South Africa

A.E. Van der Merwe, D. Morris, M. Steyn, G.J.R. Maat

South African Archaeological Bulletin



Kimberley town, 1882
(McGregor Museum Kimberley Photography nr.7623)

De Beers Mine compound, 1896
(McGregor Museum Kimberley Photography nr.829)

1.1 The study of palaeopathology

The distribution and frequency of disease and trauma in a population is rarely a function of chance. It is often directly related to the populations' genetic composition and the environment, pathogens, stress and activities they are exposed to on a daily basis (Wells, 1964). The medical literature is littered with terms such as painter's colic, tennis elbow and chauffeur's fracture as a constant reminder of this important principle (Graham *et al.*, 1981; Helm & Tonkin, 1992; Faro & Wolf, 2007). Through the study of pathology present in human skeletal remains, palaeopathologists attempt to reconstruct the fragile balance between living creatures, disease micro-organisms and environmental stresses throughout history (Angel, 1981; Ortner, 2003).

As can be expected, the primary use of human skeletal material to reconstruct health and disease in the past is filled with inherent difficulties. In most cases, no soft tissue evidence will be available for examination and, depending on the archaeological context, skeletons are often fragmented, incomplete or damaged. This is of great importance when interpreting the prevalence of pathological conditions in a study population as some diseases only affect certain parts of the skeleton. For example, rheumatoid arthritis mainly affects the hands and feet and the pathognomonic lesion of tuberculosis, Pott's disease, is found on the vertebrae (Ortner, 2003). Therefore, the study of extremely fragmented, damaged or incomplete skeletal material may result in an underestimation of disease frequencies.

A second difficulty researchers are often faced with is the ambiguity of lesions and associated diagnostic complications (Wells, 1964; Dastugue, 1978). Bone can only react to pathology in a limited number of ways: via the deposition of new bone, the resorption of bone or a combination of the two (Dastugue, 1978; Mann & Murphy, 1990). As a consequence, some diseases result in morphologically similar bone lesions. It is often possible to differentiate between diseases resulting in comparable bone reactions by assessing the skeletal distribution of the lesions and taking into consideration the demographic groups in which the diseases are most likely to manifest. Techniques to support the macroscopic evaluation of lesions, such as X-ray investigations or histological analyses, may also aid in the diagnostic process. However, differentiating between potential pathological conditions is not always possible. Therefore, thorough description and differential diagnosis of lesions are of great importance, not only to prevent

misdiagnosis of pathological lesions, but also to permit other researchers to interpret the lesions observed (Ortner, 2003). It has even been suggested by some authors that specific disease diagnoses should be avoided. A suggestion was made that the pathological lesions observed should be classified according to broader, more inclusive categories to minimize the misdiagnosis of disease (Milner *et al.,* 1996)

The question then arises - is the prevalence of pathological conditions observed in a skeletal sample representative of the health of the once living population from which the sample came? It is generally accepted that a direct association exists between the prevalence of specific pathological lesions observed in a skeletal sample and the pathogen load or frequency of the causative diseases in the once living population from which the sample came. Hence, it has been suggested that an increase in the frequency of a specific skeletal lesion can be interpreted as an increase in the risk of being affected by the disease most likely to have produced the lesion (Wood *et al.*, 1992; Van der Merwe, 2007). However, Wood and co-workers (1992) suggested that the samples being used to reconstruct past population health are biased since they are only representative of those individuals that died. Thus, no matter how large the skeletal sample, it will never be representative of the once living population. As a result of the inherited selectiveness of skeletal sample populations, the observed prevalence of diseases will most likely be an overestimation of the true frequency of the pathological conditions present in the once living population (Wood *et al.*, 1992).

Furthermore, Wood *et al.* (1992) suggested that an increase in the presence of pathological lesions (e.g. enamel hypoplasia or infectious lesions) does not necessarily suggest poor general health in a population. It must be kept in mind that skeletal evidence of disease only develops as a result of chronic disease or trauma. Thus, individuals presenting with no skeletal lesions may either have died as a result of a disease that does not cause skeletal changes or else their immune system was strong enough to eliminate the disease before its associated skeletal lesions could develop. It is also possible that the seemingly 'healthy' individual could not withstand the initial onslaught of the pathogen and died before any skeletal lesions could develop. Determining which of these scenarios is applicable to those skeletons free of pathological lesions is usually impossible.

On the contrary, a population sample comprised of individuals presenting with extensive evidence of pathological bone alterations as a result of chronic disease was most likely in good health. The immune systems of those affected were strong enough to prevent

death but not strong enough to completely eradicate the disease (Wood *et al.*, 1992; Larsen, 1997; Ortner, 2003).

Taking the selectiveness of a skeletal sample population and the paradox related to the interpretation of pathological lesions into consideration, it becomes clear that the prevalence of pathological conditions observed in a skeletal sample may not be representative of the health of the once living population from which the sample came when viewed in isolation (Wood *et al.*, 1992). Goodman (1993) suggested that to overcome the majority of these 'inherited' difficulties, skeletal lesions indicative of disease should not be interpreted in isolation. It is essential that archaeological and historical findings describing the subsistence, demography and environmental and cultural contexts of the sample should be taken into consideration at all times (Goodman, 1993; Larsen, 1997).

In conclusion, it can be said that although there are difficulties and limitations in the study of palaeopathology and the reconstruction of health in the past, a significant contribution can still be made to our understanding of human history and modern disease, when results are interpreted with caution (Bosch, 2000; Ortner 2003).

In this study an attempt will be made to describe and discuss the pathological lesions observed in a skeletal sample population salvaged after accidental disturbance, taking the available historical documents and archaeological findings into consideration. The historical setting of the site from which the remains were salvaged, as well as an account of the city and time period in which these individuals laboured will be briefly discussed, followed by a detailed description of the purpose of the study.

In the second chapter, general details of all methods used to analyze the skeletal remains will be given. Results concerning the archaeological findings of interest for this thesis, a description of the demographic composition of the sample, as well as a summary of all skeletal pathological lesions observed will be presented in the third chapter. Chapters four and five are detailed reports and discussions of lesions suggestive of trauma and metabolic disorders, respectively, observed in the study sample. The chapters on skeletal pathology will then be concluded by a description of the formation and remodelling of ossified haematomas when viewed microscopically.

Chapters seven and eight deal with the dental health of the salvaged skeletal sample, with the first summarizing the prevalence of carious lesions, antemortem tooth loss, periapical granulomata and cysts and bony evidence of periodontal disease, and the second

reporting on supernumerary teeth and the possible demographic detail this finding added to the study.

Lastly, a description of the ancestry of the salvaged remains and a discussion taking all the evidence presented in the dissertation into consideration can be found in the final two chapters.

1.2 Kimberley – Historical setting

Several tales exist describing how diamonds were first discovered on Colesberg Kopje in South Africa. The most plausible story states that in 1871, a prospector, Fleet Rawstone, had a cook, Damon (Esau Damoense), who had a habit of drinking too much and misbehaving. Consequently, Damon was sent away from their digging party with only a few cooking utensils and food, and was instructed to go do some digging on the hill as punishment. He returned a few nights later with two or three diamonds, which he claimed he discovered on Colesberg Kopje (Colesberg Hill). That same night, all the men in the camp rushed to the hilltop and started marking their claims in the dark (Roberts, 1976).

The discovery of diamonds on Colesberg Kopje gave rise to the town of Kimberley in what is today the Northern Cape Province of South Africa. The first diggings on the 'Diamond Fields', in 1870, were along the banks of the nearby Vaal River and at a few 'dry diggings' dotted around the region of Kimberley. New finds would spark a rush as diggers scrambled to stake out claims, one of the most famous being the 'New Rush' when Colesberg Kopje – now Kimberley Mine – was discovered. In time it was realised that the gems being recovered in the vicinity of and at Colesberg Kopje were located in diamondiferous kimberlite pipes, which could be mined to great depths. Open-cast mining resulted in the famous 'Big Hole' and other similarly deep excavations, but shafts were soon being sunk to retrieve kimberlite even deeper. Kimberley became the hub of industrialisation in South Africa, transforming the country's agrarian economy into one increasingly dependant on its mineral wealth. The demand for 'black' labour in the mines drew workers on an unprecedented scale from throughout the subcontinent.

By the end of the 19th century, the 2000 or so men who at first had mined on Colesberg Kopje had burgeoned into a population of 41 000, numbering 14 500 Europeans and 26 500 'black' persons (Stoney, 1900a). The efforts of many individual prospectors and claim-

holders had been swallowed up as companies amalgamated, with De Beers Consolidated Mines Ltd establishing a monopoly by the end of the 1880s.

Apart from the 'Native Locations', several closed labour compounds for housing 'Black' mine workers were established in the Kimberley district in the mid-1880s (Leary, 1891; Roberts, 1976; Worger, 1987). The compounds were developed to improve security and limit the theft of diamonds, while enhancing production by controlling the movements of workers. Although intended to provide adequate shelter and nutrition, the living conditions in the compounds were in fact poor (Leary, 1891; Barnes, 1895; Jochelson, 2001).

Disease and death was an everyday occurrence from the outset on the Diamond Fields. Thousands of people were digging in extremely dry surroundings, without proper housing, natural water sources and proper arrangements for waste disposal. Doctors Otto, Dyer and Matthews were the first to arrive at the fields in 1871 (Booth, 1929; Kretsmar, 1974). Kimberley's first hospitals attracted trained doctors who were assisted by the women and nurses of the Community of St. Michael and All Angels, headed by Sister Henrietta Stockdale (Booth, 1929; Kretsmar, 1974; Swanepoel, 2003). In 1882, the amalgamation of the Diggers Central Hospital and the Carnarvon Hospital gave rise to the Kimberley Hospital (Booth 1929), which at the time was the largest regular hospital in the Cape and the best training school for nurses in the country (Kretsmar, 1974). By the late 1890s, Kimberley Hospital had a 'Native surgical ward' and a special ward for 'black' women and children. Together with the compound hospitals, it was responsible for the migrant workers and paupers who fell ill (Cape of Good Hope Votes and Proceedings of Parliament, 1898; 1899; 1900). Hospital records indicate that between 1897 and 1899, 7 853 patients were admitted to Kimberley Hospital, of whom 5 368 were 'black'. Of those who were treated, 1 144 died (*ibid.*).

During this period the most frequently treated disease was 'zymotic disease', which resulted in 34.8% of admissions and 48.1% of deaths. 'Zymotic disease' was a term given to describe any contagious disease. A total of 977 patients were admitted for dietetic diseases, which probably included scurvy, and 52 (5.3%) died as a result thereof. Constitutional diseases, which most likely referring to inherited disorders, diseases of the respiratory system and diseases of bones and joints were also observed. Injury and violence (as it was termed in historical documents) brought 893 patients to the hospital in the aforementioned three years, of whom 40 died. Although it is unclear precisely how the

different diseases were categorized, it seems that the main causes of death in the last three years of the 19th century were tuberculosis, pneumonia, scurvy, syphilis, diarrhoea, mining accidents and interpersonal violence (Cape of Good Hope Votes and Proceedings of Parliament, 1898; 1899; 1900; Stoney, 1900b).

Paupers who died in the Kimberley or other surrounding compound hospitals were buried in the Gladstone cemetery. Use of this cemetery began informally prior to its official proclamation in March 1883, by which time half the ground were being used for

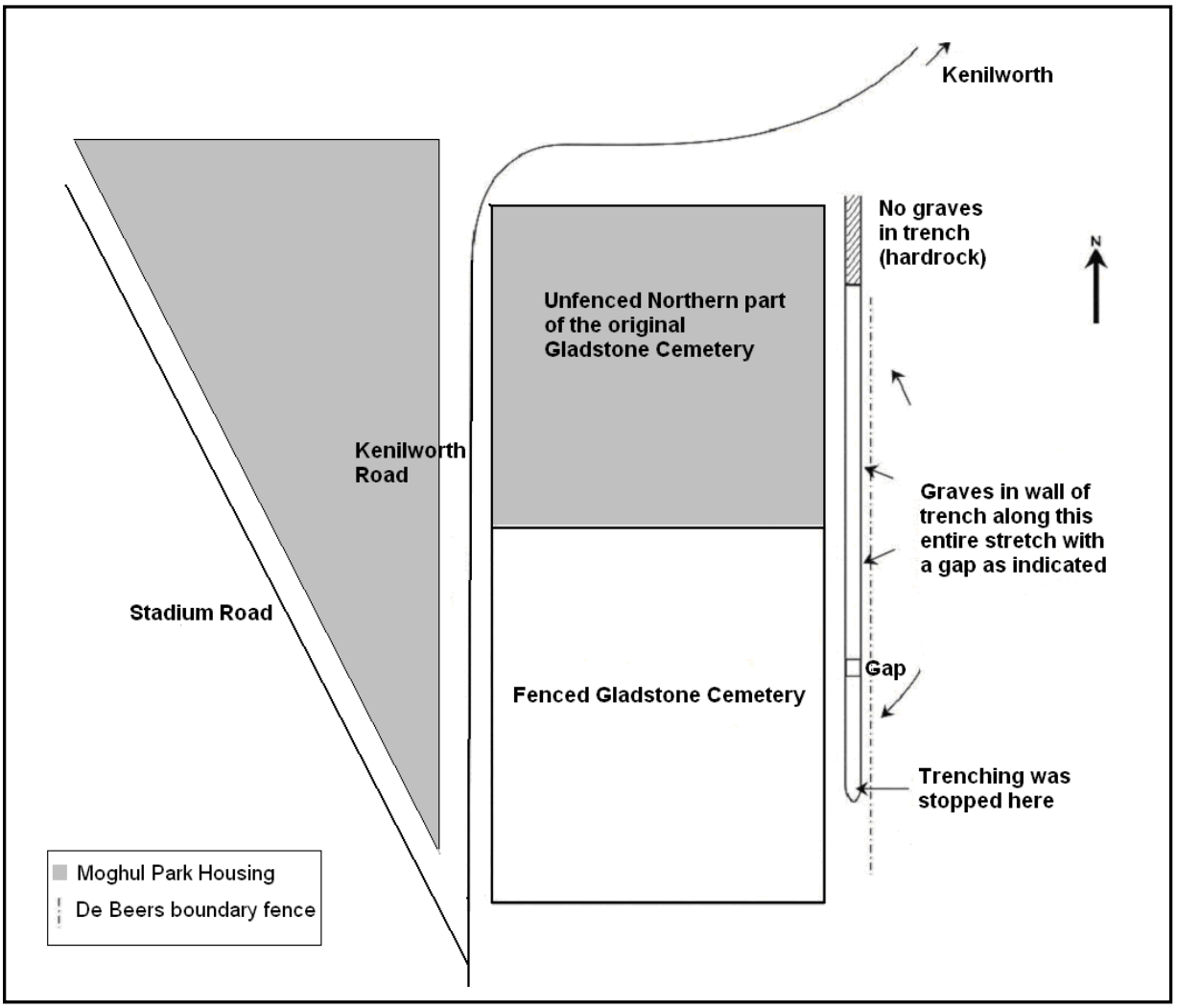

Figure 1.1 Map indicating the fenced as well as the northern build-over sections of the Gladstone cemetery and the trench which uncovered the human remains assessed in this study (modified from van der Merwe *et al.* 2009b). The trench was 180m long.

'native' internments – by then numbering approximately 1500 graves (Manager of Vooruitzigt Estate, 1883, cited in Swanepoel 2003). Some of the early registers were lost in a fire but one surviving register indicated that nearly 5 000 'black' burials took place

between 24 June 1887 and 28 November 1892, while another 611 'black' burials were recorded for the period between February and June 1900. These were mainly paupers' burials. At least some of these individuals were buried without coffins for lack of funds and were transferred to the grave wrapped only in blankets or coverlets (Swanepoel 2003).

In 1897, the cemetery was enlarged along its eastern border with an extra strip of land donated by De Beers. The cemetery was closed in mid-1900, and opened again in April 1902 for 'European' interments only. Decades later the visible cemetery was fenced, with those areas containing unmarked graves going unnoticed and falling outside of the new boundary. Municipal records confirm that in 1883 the cemetery measured some 7.2 ha; that it was enlarged by the addition of a strip of land in 1897; but the extent of the demarcated cemetery in 1998 was only some 3.6 ha. The original cemetery was nearly double its present size, and it has since been partly built-over at its northern end (Morris, 2003).

It was exactly in the strip of land given by the De Beers Company, right up against the mining area fence, but outside of the presently demarcated cemetery, where trenching by the Sol Plaatje municipality, in 2003, accidentally intersected 145 unmarked graves (see Figure 1.1). Acting on information received, staff of the McGregor Museum in Kimberley intervened to halt the trenching, and alerted the South African Heritage Resources Agency (SAHRA). As there had been no prior impact assessment, archaeologists of the McGregor Museum and community helpers spent the next several months investigating the damaged graves.

1.3 The purpose of the study

This study is a direct outflow of unpublished preliminary results obtained from a M.Sc study conducted by the author at the University of Pretoria, South Africa. The purpose of the Ph.D study was to re-evaluate and extend the abovementioned results in depth and diversity in order to unravel and interpret the archaeological context, demographic composition, health status and possible ancestry of the skeletal remains recovered, as one unit. It was anticipated that the results would shed more light on the previously disadvantaged and unknown individuals who laboured in the mines and the influence this important period of economic and social growth had on them.

A general description of the skeletal remains was done with regards to the age, sex and stature of each individual (details on each of the individuals assessed can be seen in

Appendix 1). Particular attention was given to pathological lesions observed on the bones, with special reference to those indicative of infectious disease, scurvy, trauma and enthesopathy (indicators of possible regular participation in strenuous physical activities). The dental health of the sample was also assessed and all dental pathology, as well as indications of normal variation, was recorded.

The prevalence of all pathological conditions observed in the Gladstone population was compared to other skeletal studies from South Africa as well as other countries. Diseases observed in this study were also interpreted in relation to archival documents describing the health of mine labourers in 19th century Kimberley, as well as hospital records reporting the prevalence of certain pathological conditions during this period. Although numerous historical documents are available describing Kimberley in the late 19th century, very little is known about the lowest class of mine labourers during this time period. Therefore, this study will give valuable insight into a relatively unknown group of people.

It has been suggested that skeletal lesions caused by specific pathological conditions can be accurately diagnosed on the bases of their histological characteristics (Schultz, 2003; Von Hunnius *et al.*, 2006). A high prevalence of pathological conditions, especially diseases such as treponematosis and scurvy causing lesions on the anterior tibiae, were present in this sample. Since lesions on the anterior tibiae are often ambiguous on a macroscopic level, a decision was made to employ microscopic investigation in order to firstly, test the methods available in cases where a reliable diagnosis could be made on a macroscopic level and secondly to evaluate as to whether histological investigations can improve the accuracy of diagnosis of these lesions.

Lastly an attempt was made to determine the ancestry of the individuals salvaged from the trench using craniometric methods. These results were compared with historical documents describing the various groups represented in the mine during the late 19th century.

References

Angel, J.L. 1981. History and development of paleopathology. *American Journal of Physical Anthropology* 56:509–515.

Barnes, G.W. 1895. Divisions of Kimberley. In: *Blue Book of Native affairs G8*.

Booth, J.R. 1929. *The Care of the Sick, Yesterday and Today.* Kimberley: The Diamond Fields Advertiser Limited.

Bosch, X. 2000. Look to the bones for clues to human disease. *The Lancet* 355:1248.

Cape of Good Hope Votes and Proceedings of Parliament. 1899. *Hospitals and Asylums Report for 1898.* Appendix I.

Cape of Good Hope Votes and Proceedings of Parliament. 1900. *Hospitals and Asylums Report for 1899.* Appendix I.

Cape of Good Hope Votes and Proceedings of Parliament. 1901. *Hospitals and Asylums Report for 1900.* Appendix I.

Dastugue, J. 1980. Possibilities, limits and prospects in paleopathology of the human skeleton. *Journal of Human Evolution* 9:3-8.

Faro, F. and Wolf, J.M. 2007. Lateral epicondylitis: review and current concepts. *The Journal of Hand Surgery* 32:1271-1279.

Goodman, A.H. 1993. On the interpretation of health from skeletal remains. *Current Anthropology* 34:281-288.

Graham, J.A.G., Maxton, D.G. and Twort, C.H.C. 1981. Painter's palsy: a difficult case of lead poisoning. *The Lancet* 318:1159-1160.

Helm, R.H. and Tonkin, M.A. 1992. The chauffeur's fracture: simple or complex? *The Journal of Hand Surgery*17:156-159.

Jochelson, K. 2001. *The Colour of Diseases, Syphilis and Racism in South Africa 1880 - 1950*. New York: Palgrave.

Kretsmar, N. 1974. An introduction to the history of medicine in the Diamond fields of Kimberley, South Africa. *Medical History* 18:155–162.

Larsen, C.S. 1997. *Bioarchaeology. Interpreting behavior from the human skeleton.* United Kingdom: Cambridge University Press.

Leary, J.G. 1891. Divisions of Kimberley. *Blue Book on Native Affairs G4*.

Mann, R.W. and Murphy, S.P. 1990. *Regional Atlas of Bone Disease, A Guide to Pathologic and Normal Variation in the Human Skeleton.* Springfield: Charles C Thomas.

Miller, E., Ragsdale, B. and Ortner, D.J. 1996 Accuracy in dry bone diagnosis: a comment on palaeopathological methodology. *International Journal of Osteoarchaeology* 6:221-229.

Morris, D. 2003. Salvage and investigation of graves disturbed by the Sol Plaatje Municipality outside Gladstone Cemetery, Kimberley. Unpublished Second Interim Report.

Ortner, D.J. 2003 *Identification of Pathological Conditions in Human Skeletal Remains*, 2nd ed. Amsterdam: Academic Press.

Roberts, B. 1976. *Kimberley Tubulent City.* Capetown: Pioneer Press.

Roberts, C. and Manchester, K. 1995. *The Archaeology of Disease*, 2nd ed. Stroud: Alan Sutton Publishing.

Schultz, M. 2003. Light microscopic analysis in skeletal paleopathology. In: *Identification of pathological conditions in human skeletal remains*, 2nd edn. Ortner D.J. (ed.) Amsterdam: Academic Press.

Steckel, R.H., Rose, J.C., Larsen, C.S. and Walker, P.L. 2002. Skeletal health in the Western Hemisphere from 4000B.C. to the present. *Evolutionary Anthropology* 11:142-155.

Stoney, W.W. 1900a. *Report of the Medical Officer of Health, Kimberley, for the Years 1898.*

Stoney, W.W. 1900b. *Annual Report of the Medical Officer of Health for the Years, 1899.*

Swanepoel, S. 2003. *Gladstone Cemetery, 1880s to 1900s.* Archival report.

Van der Merwe, A.E. 2007. *Human skeletal remains from Kimberley: An assessment of health in a 19th century mining community*, MSc. thesis, University of Pretoria.

Von Hunnius, T.E., Roberts, C.A., Boylston, A. and Saunders, S.R. 2006. Histological identification of syphilis in pre-columbian England. *American Journal of Physical Anthropology* 129: 559-566.

Wells, C. 1964. The significance of palaeopathology. In: *Bones, Bodies and Disease. Evidence of Disease and Abnormality in Early Man.* London: Thames and Hudson, pp. 17-22.

Wood, J.W., Milner, G.R., Harpending, H.C. and Weiss, K.M. 1992. The osteological paradox. *Current Anthropology* 33:343-370.

Worger, W.H. 1987. *South Africa's City of Diamonds: Mine Workers and Monopoly Capitalism in Kimberley, 1867-1895*. Craighall: AD. Donker.

CHAPTER 2

Materials and Methods

Modified from article accepted for publication as:

The history and health of a nineteenth-century migrant mine-worker population from Kimberley, South Africa

A.E. Van der Merwe, D. Morris, M. Steyn, G.J.R. Maat

South African Archaeological Bulletin



Diamond washing machinery, 1886
(McGregor Museum Kimberley Photography nr.7617)

Jones Street, Kimberley, 1895
(McGregor Museum Kimberley Photography nr.954_002)

2.1 Excavation of the skeletal material

A permit for excavation of a sample of the damaged graves was granted to the McGregor Museum in Kimberley by the South African Heritage Resources Agency (SAHRA) (permit 80/03/04/004/51). Since the proposed storm-water drain was diverted away from its original route (continued trenching was likely to have doubled the impact), it was not necessary to exhume all of the 145 graves exposed by the trench: 15 were chosen for detailed investigation, including all instances where skeletons had been left exposed by the trenching and with a view to assessing variation along the length of the disturbance. Once the salvage was completed, the trench and excavated graves were re-filled with sand. The permit also provided for temporary storage of the human and artefact remains excavated from the site at the Museum. As was required by SAHRA, regular public meetings and press briefings were held in order to inform the community and public at large of the progress being made with the study.

Information on the disturbance and the preliminary findings were disseminated broadly via various media to the citizens of Kimberley and beyond. Responses by people claiming knowledge of the cemetery were sporadic and essentially irrelevant. Not in a single instance was any direct link with the graves in question asserted (Morris *et al.,* 2004).

Local community members claimed that the graves were those of 'Skotse soldate' – Scottish soldiers – until indications to the contrary were pointed out (i.e. the absence of coffins and the occurrence of glass beads, iron and copper bangles, and copper ear-rings associated with male skeletons). This underscored the crucial role of archaeology in substantiating the identity of the buried individuals, and disproved the presumption that communities would be reliable informants in all instances. An understanding emerged, however, that these graves could represent part of the collective experience of Kimberley's underclass in the late 19th century, and a growing sense of responsibility amongst community members was palpable. Their involvement was an integral part of every stage of the ensuing investigation, with several public meetings being held to report on findings and proposals and to seek guidance or approval for successive interventions.

During the archaeological investigations, two sites were involved: firstly, the 180m-long trench itself, where the burials were disturbed, and secondly, a diamond washing plant halfway between the cemetery and Kenilworth village, where material dug out of the trench had been dumped in heaps before being bull-dozed to fill hollows or for processing in the

diamond screening operation. Exhumation of selected graves in the trench began in May 2003. It was clear that trenching had seriously damaged and displaced remains from the upper part of at least seven graves.

The dump-site was divided into ten sectors and screened accordingly (see Figure 2.1), resulting in the salvage of a large number of bones. Work there was called off in June 2003, when it was considered that most of the retrievable human remains had been recovered. Following excavation, all skeletal material and artefacts recovered were taken to the McGregor Museum for temporary storage in anticipation of further analysis. Traditional healers were given an opportunity to perform a cleansing ritual on the human remains at the museum.

All skeletal remains excavated from the trench were analyzed. In most cases the skeletons were complete and preservation was excellent. The remains recovered from the dumpsite near Kenilworth were analyzed separately using techniques specific to commingled remains as outlined by Ubelaker (2002), Byrd and Adams (2003) and L'Abbé (2005). Although some bones were damaged by the excavation machinery, the majority were well preserved and intact. All skeletal elements were counted taking left and right sides into account. Pair matching and articulation were done where possible and the minimum number of individuals represented by the remains recovered from the dump site was determined. Since these single skeletal elements may, in fact, not represent new individuals, but merely parts of incomplete skeletons excavated from the trench, they were not taken into account in the demographic and palaeopathological analyses of this study.

2.2 Accession numbers

Each grave was assigned a number and position in relation to a gap, which was probably a roadway between the graves: for example N8 (North 8), S2 (South 2), SE6 (South-East 6), etc. (see Figure 2.2). The accession numbers for the skeletons consisted of the grave designation followed by a number that corresponded to the quantity of skeletons removed from the grave, for example S2.2 would indicate the second skeleton in grave S2.

The dump was divided into eight sections (A – H), as can be seen in Figure 2.1, and skeletal elements were numbered according to the section from which they were excavated.

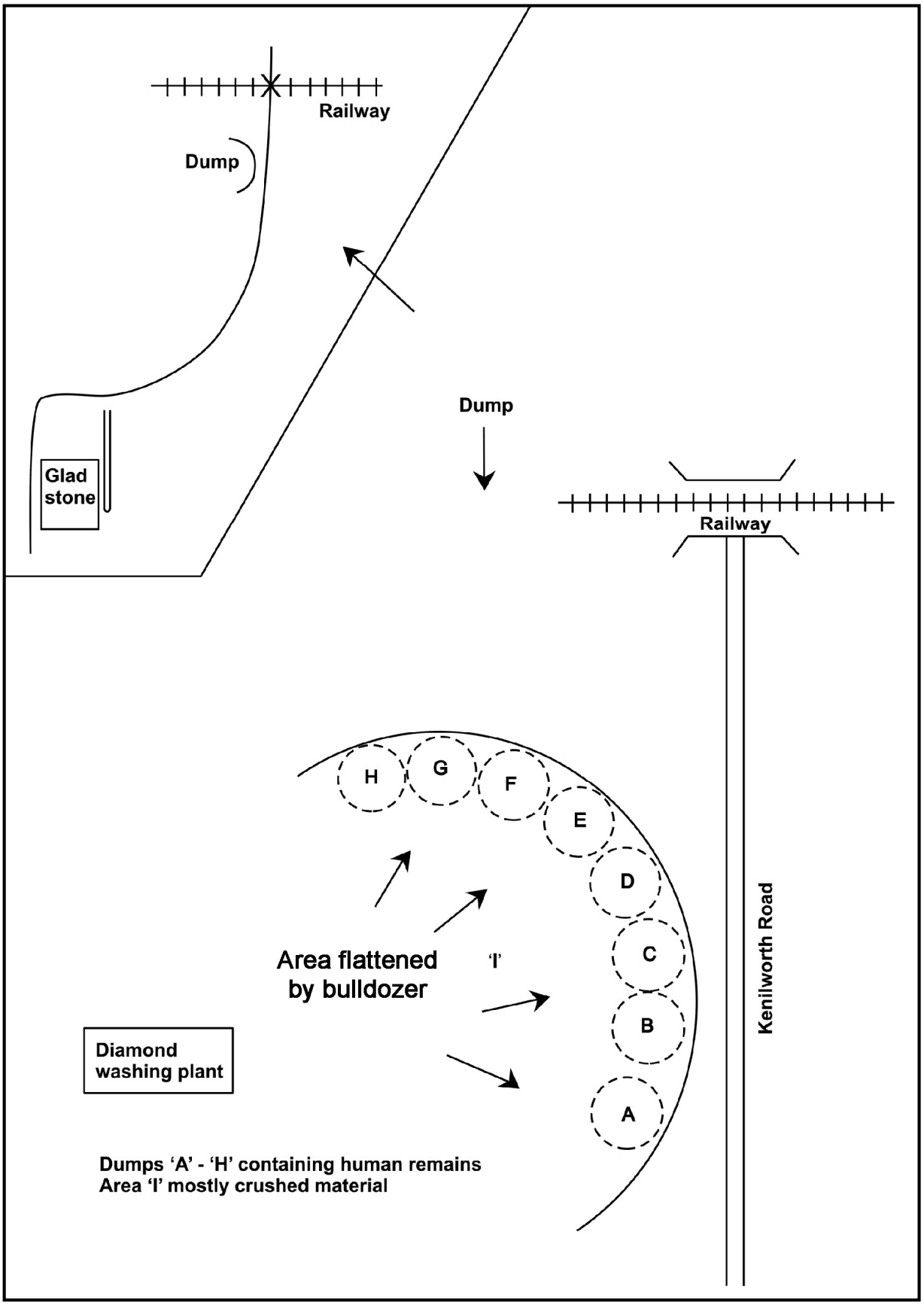

Figure 2.1 Map indicating the location of the dump site (top left corner) as well as the different areas of excavation A-H.

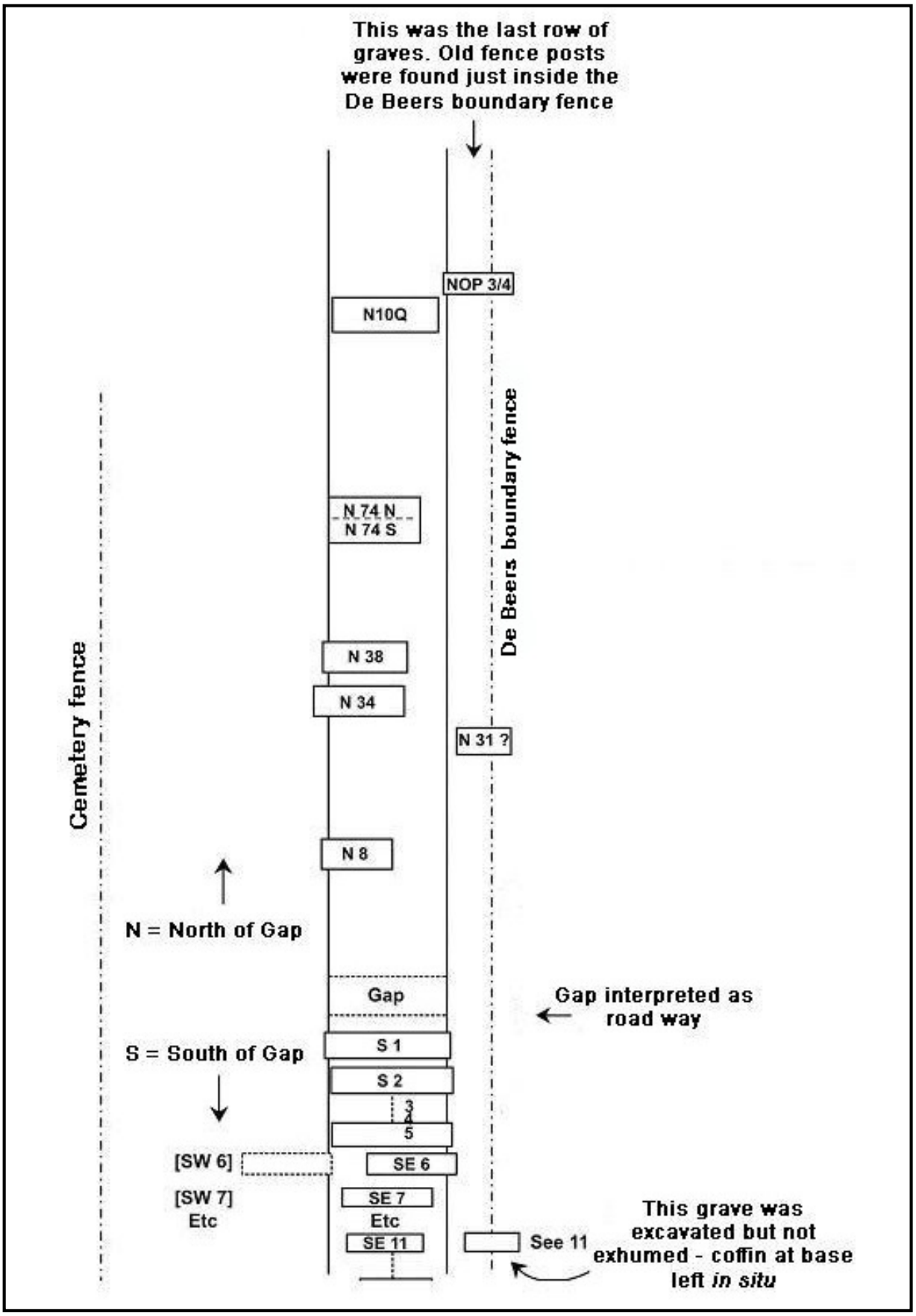

Figure 2.2 Map indicating the location of the graves in relation to the gap.

2.3 Methods*

2.3.1 Methods for sex determination

A combination of non-metric morphological skeletal characteristics, as well as several metric standards and discriminant functions derived from modern South African populations, was used to determine sex from adult skeletal remains in this study. The accuracy of sex determination of unknown skeletal material is highly dependant on the relative completeness as well as the preservation of the skeletal remains. Therefore, this multi-disciplinary approach increased the accuracy of sex determination in cases where non-metric traits could not be assessed or landmarks, from which measurements had to be taken, were damaged or missing.

It is also important to note that metric and non-metric differences between males and females are spread across a continuum, with a large amount of overlap between the sexes and only extreme cases showing exclusive male or female features (both morphologically and metrically). Thus, it is advisable to use more than one technique in order to obtain the most reliable results (Meindl *et al.*, 1985; Loth & İşcan, 2000b).

Sex determination: Morphological techniques

Non-metric morphological techniques used to determine the sex of an individual consist of the visual assessment of the morphology of a certain bony feature, which differs between sexes in shape or size. The degree of sexual dimorphism between the sexes dictates the accuracy of these features as a means of sex determination. These morphological features are more than often very effective since they are developmental in nature. For example, the expansion of the subpubic angle is a pelvic feature that develops during adolescence to accommodate childbirth (Loth & İşcan, 2000b). The only difficulty with these methods is that experience is needed in order to judge what is relatively large or small, or narrow or wide, for the specific population group being studied (Meindl *et al.*, 1985; Loth & İşcan, 2000b).

The most diagnostic elements for sex determination by non-metric means are the skull and pelvis (Berrizbeitia, 1989; Loth & İşcan, 2000b). Cranial features such as a prominent supraorbital torus, sloping forehead (when viewed laterally), prominent external occipital

* Modified from A.E. van der Merwe (2007)

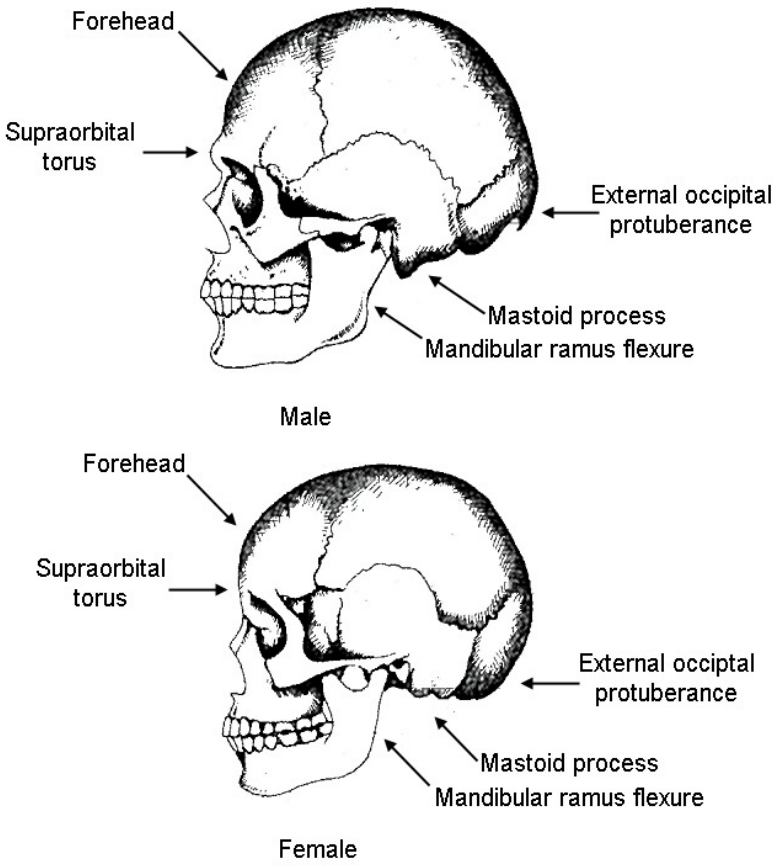

Figure 2.3 Morphological sex differences as can be observed in the skull (modified from Steyn *et al*., 2004).

protuberance, large mastoid processes and rounded orbital margins, suggest possible masculine development (see Figure 2.3). Feminine development is indicated by a small supraorbital torus and straight forehead, a less prominent external occipital protuberance, small mastoid processes and sharp orbital margins (De Villiers, 1968; Krogman & İşcan, 1986; Loth & İşcan, 2000b). Several characteristics of the mandible, such as the size and shape of the mandibular condyles, the shape of the chin (squared or angular), degree of gonial eversion, as well as mandibular ramus flexure, can also aid in sex determination (De Villiers, 1968; Krogman & İşcan, 1986; Kemkes-Grottenthaler *et al.*, 2002).

Some of these methods are more accurate than others and these differences are often population specific. For example, Loth and Henneberg (1996) found that mandibular ramus flexure at the level of the occlusal plane is a good indicator of sex in the South African population, with an average accuracy of 94%. On the other hand Kemkes-Grottenhaler *et al.* (2002) indicated a mere 59% overall accuracy in sex determination when mandibular ramus flexure was applied to a German forensic and archaeological sample for the purpose of sex determination. This study also indicated that the accuracy of mandibular non-metric morphological features (degree of mandibular ramus flexure and gonial eversion) is greatly influenced by antemortem tooth loss (Kemkes-Grottenthaler *et al.*, 2002). Nevertheless, mandibular ramus flexure, gonial eversion, as well as the shape and size of the mandibular condyles were assessed in situations where only the mandible was available or in conjunction with other methods and features.

In the pelvis (see Figure 2.4), non-metric features, such as a wide subpubic angle, wide sciatic notches, a round pelvic inlet, a broad and flat sacrum, elongated pubic bones, and a pre-auricular sulcus suggest possible feminine development (Day, 1975; Flander, 1978; St Hoyme & İşcan, 1989; Patriquin *et al.*, 2003). Masculine developmental characteristics include a narrow subpubic angle and sciatic notches, a heart-shaped pelvic inlet, a narrow and curved sacrum, as well as triangular pubic bones (Loth & İşcan, 2000b; Patriquin *et al.*, 2003). A study by Partiquin *et al.* (2003) indicated that the assessment of the shape of the greater sciatic notches, as well as the pubic bones, yielded the most dependable results in the black South African population.

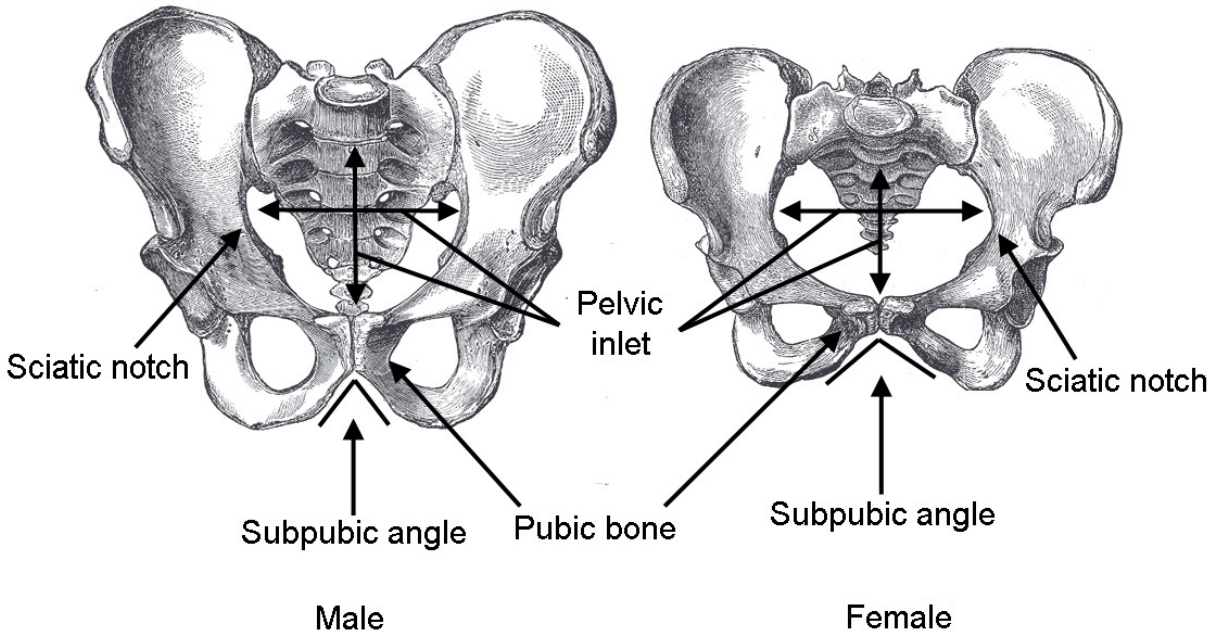

Figure 2.4 Morphological sex differences as can be observed in the pelvis.

Sex determination: osteometric techniques

Although sex differences in morphological features are clearly visible on the skull and pelvis, they are not easily visualized in other parts of the human skeleton, such as the long bones. Accordingly, metric investigation of long bones is needed to determine differences in dimensions between male and female individuals. The metric technique of sex determination is based on the fact that within various population groups, males tend to be more robust than females (Meindl *et al.*, 1985; St Hoyme & İşcan, 1989; Loth & İşcan, 2000b). Unfortunately, the drawbacks of these methods are that the formulae are population specific and the metric overlap between the sexes can be as high as 85% (Steyn

& İşcan, 1997; Loth & İşcan, 2000b; Franklin *et al.*, 2005). Additionally, all landmarks needed to make the necessary measurements should be intact.

A number of metric techniques are available for the South African Black population. Standards for sex determination of Black South Africans from single long bone measurements are available for the humerus, femur and tibia (Berrizbeitia, 1989; Loth & İşcan, 2000b; Asala *et a.l*, 2004). Of these measurements, the maximum diameter of the femoral and humeral heads prove to be the most accurate (91%) (Asala, 2001). Other dimensions such as humeral epicondylar breadth, femoral midshaft circumference, femoral distal breadth, proximal tibial breadth and tibial circumference at the nutrient foramen, are between 85.3% and 88.6% accurate (Kieser *et al.*, 1992; Loth & İşcan, 2000b). Franklin *et al.* (2005) recently developed cranial multivariate discriminant functions for the Black South African population that are 75-80% accurate, with bizygomatic breadth, cranial length, and cranial height as the most sexually dimorphic.

Taking the geographical location of Kimberley into consideration, it can be expected that some of the skeletal remains within this population may belong to individuals of KhoeSan ancestry. As osteometric techniques are population specific, sex determination based on standards for South African Negroids may not prove very useful for these individuals (De Villiers, 1968; Morris, 1984; Meindl *et al.*, 1985; Patriquin *et al.*, 2003).

Sex determination: juvenile skeletal remains

Sex differences in the skeleton are hard to visualize and often ambiguous before puberty, making sex determination in young individuals extremely difficult (Krogman & İşcan, 1986; St Hoyme & İşcan, 1989; Loth & İşcan, 2000b; Schutkowski, 1993; Loth & Henneberg, 2001). Nevertheless, some features such as the shape of the mandible, depth of the greater sciatic notch and the curvature of the iliac crest can be successful in the determination of sex for individuals up to five years of age (Schutkowski, 1993; Loth & İşcan, 2000b; Loth & Henneberg, 2001). Since techniques developed for sex determination in juvenile skeletal remains tend to be unreliable, no attempts were made to determine sex from immature skeletons in this study.

2.3.2 Methods for age determination

The human lifespan can be divided into four distinct phases, i.e. infancy (0-3 years), childhood (4 to approximately 12 years), adolescence (13 to approximately 16 years) and adulthood (Scheuer & Black, 2004). Various techniques for age determination exist for each of these groups and they will be discussed accordingly.

Age determination: infants and childhood

Prenatal and infant age can often be metrically determined from the diaphyseal lengths of bones such as the clavicles, humeri, ulnae, radii and femora. These methods are relatively accurate, and can provide an age estimate to within a month of the infant's true age at death (Ubelaker, 1987; Kosa, 1989; Loth & İşcan, 2000a; Scheuer & Black, 2000).

Dental development and eruption is the most reliable method for estimating the age of children (Massler *et al.*, 1941; Ubelaker, 1987; Ubelaker, 1989; Johnston & Zimmer, 1989; Loth & İşcan, 2000a; Scheuer & Black, 2000; Foti *et al.*, 2003). Teeth are consistent in the sequence and rate of eruption and are therefore a very reliable indicator of age (Loth & İşcan, 2000a; Foti *et al.*, 2003). Deciduous lower central incisors start erupting between six and seven months of age, and a full set of deciduous teeth is visible around three years of age (Ubelaker, 1987; Ubelaker, 1989; Scheuer & Black, 2000). A chart developed by Ubelaker (1987) was used to estimate age at death in cases where deciduous tooth eruption had commenced. Ubelaker's (1987) eruption chart is of great value, especially when estimating the age of individuals between five months in utero and four years, since it can estimate age with relative accuracy, based on dental development and eruption of deciduous teeth. After four years of age, the age estimations based on the dental eruption of permanent teeth gets wider and it is therefore suggested that this method is used in association with other aging methods in the older age groups.

Other aging methods include fusion of the various bones of the skull and mandible. For example, union of the mandible at the mandibular symphysis occurs between six and nine months, while development of the tympanic ring and its eventual fusion with the temporal bone, closure of the fontanelles, and fusion of the metopic suture all normally occur around two to three years of age (Weaver, 1979; Becker, 1986; Johnston & Zimmer, 1989; Scheuer & Black, 2000). Development of the vertebral column is also a valuable indicator of age. Fusion of the two segments of the neural arch normally occurs during the

first year of life and fusion of the vertebral arch to the vertebral body (neurocental fusion) usually takes place between the ages of two and three years (Scheuer & Black, 2000).

The diaphyseal lengths of long bones were used as an indicator of juvenile age in conjunction with estimates given by tooth eruption charts and stages of bone epiphyseal fusion (Scheuer & Black, 2000). No x-rays were used in the study of dental eruption; all investigations were done through macroscopic visual assessment only. Methods, such as the assessment of fontanelle closure, could not be used due to the young age of the individuals in this study and the fragmentary condition of the remains.

Age determination: adolescence

Two methods were used for the estimation of age at death for adolescents: the eruption of permanent teeth and epiphyseal closure (Scheuer & Black, 2000; Foti *et al.*, 2003). Although the majority of permanent teeth erupt before the age of 11 years, canine and second molar eruption, which occurs around 11 to 12 years of age, can aid in classifying a non-adult as an adolescent (Massler *et al.*, 1941; Hillson, 1998; Loth & İşcan, 2000a).

Epiphyseal union is the most important feature to investigate during age determination in adolescents. Bone formation from ossification centres proceeds in an organized manner, with a specific sequence and timing, to form diaphyses and epiphyses. During adolescence, the cartilage structure of the metaphyses is gradually ossified, eventually leading to fusion between the diaphysis and epiphysis. When considering the major long bones, epiphyseal union starts at the elbow (distal humerus and proximal radius and ulna) between 11 and 17 years of age. It then proceeds throughout the skeleton in an orderly fashion, with the medial clavicle being the last epiphysis to unite between the ages of 16 and 30 years (Krogman & İşcan, 1986; Ubelaker, 1989; Loth & İşcan, 2000a, Sheuer & Black, 2000).

Union of other bones and epiphyses, such as the union of the primary elements of the os coxa (ilium, ischium and pubis), occurring between 11 and 17 years of age and fusion of the iliac crest and ischial tuberosity, between 17 and 23 years and 16 and 18 years of age respectively, can also be investigated. Fusion of epiphyseal ends of the metacarpals and phalanges occur between 14 and 16 years of age; the lesser trochanter of the femur between the ages of 16 and 17 years; the medial epicondyle of the humerus unite between 12 and 17 years of age; and the auricular surface of the sacrum between 12 and 14 years of age, to name but a few (Krogman & İşcan, 1986; Scheuer & Black, 2000).

Although the ossification of epiphyses proceeds in a predictable sequence, the rate at which it proceeds can be influenced by factors such as nutritional status, climate and sex (Scheuer & Black, 2000). Therefore, more than one method was utilized to estimate age at death wherever possible.

Age determination: adulthood

Once adulthood has been reached and growth and development had ceased, skeletal structures continue to be maintained and modified in a process referred to as bone remodeling. The rate of remodeling is highly variable, since it is greatly influenced by the environment, genetics and human behaviour (Loth & İşcan, 2000a). This variability makes the estimation of age from adult skeletal material extremely challenging. Therefore, it is suggested that more than one method of age determination should be employed whenever possible in order to increase accuracy.

Several relatively accurate methods are available to estimate the age of young adults, including epiphyseal fusion of the sternal end of the clavicle, ossification of the vertebral epiphyseal rings, as well as unity between the various parts of the scapula (Krogman & İşcan, 1986; Scheuer & Black, 2000). The epiphyses of the sternal ends of the clavicles fuse between 16 and 30 years of age (Krogman & İşcan, 1986; Scheuer & Black, 2000). In the vertebral column, vertebral epiphyseal rings unite with the vertebral body in individuals older than 18 years. The various parts of the scapula, including the acromion, vertebral margin and inferior angle, unite between the ages of 18 and 23 years (Krogman & İşcan, 1986).

Estimation of age from the sternal ends of the ribs is currently the most reliable, non-intrusive technique available for age estimation of older adult skeletal remains (Loth & İşcan, 1994; Oettlé & Steyn, 2000). The ribs of the remains excavated from the trench were very well preserved and therefore the investigation of sternal rib ends was the method of choice in this study (Loth & İşcan, 2000a). The sternal ends of the ribs are not affected by physical activity or environmental conditions and therefore remodeling in this region proceeds at a relatively constant rate as age increases, provided that no pathological conditions such as DISH are present in those being investigated (İşcan & Loth, 1986; Loth & İşcan, 1989; Oettlé & Steyn, 2000). This method was first developed by Loth and İşcan (1989) and includes assessment of pit depth, shape, rim and wall configuration of the sternal end of the 4th rib (İşcan & Loth, 1986; Loth & İşcan, 1989; Loth & İşcan, 1994;

Oettlé & Steyn, 2000). Oettlé and Steyn (2000) developed standards for determining age at death from sternal rib ends of the South African Negroid population. They obtained the same reliable result as was seen by Loth and İşcan (1989). Ribs depicting the different stages, as well as written descriptions of bone changes as described by Oettlé and Steyn (2000), were used in this study.

Other techniques employed to estimate the age of adults in this study included the assessment of changes present on the pubic symphysis, the closure of ectocranial sutures, and dental wear on the first, second and third molars (Lovejoy *et al.*, 1985; Brothwell, 1989; Masset, 1989; Brooks & Suchey, 1990; Loth & İşcan, 1994; Loth & İşcan, 2000a).

Other methods available for the estimation of age from adult skeletal material, such as bone histology and dental microscopy, were not used in this study due to limited funds, time restrictions and the intrusive nature of some of these methods.

2.3.3 Methods for the estimation of antemortem stature

The estimation of antemortem stature provides a factor of individualization for each skeleton investigated. The estimation of antemortem stature is based on the relationships between skeletal elements and total body length (Sjøvold, 2000). Thus, it can be assumed that the larger the skeletal elements are, the taller the individual.

For the purpose of this study, regression formulae and soft tissue correction factors for the estimation of antemortem stature for South African males and females, developed by Lundy and Feldesman (1987), were used. Long bones, which add to the body length (tibia, fibula, and femur), have been reported to yield more accurate estimations than those of the arm. Of single bone measurements, bicondylar length of the femur is the most reliable (Lundy & Feldesman, 1987; Wilson & Lundy, 1994). Accordingly, femoral measurements were used to estimate antemortem stature in this study.

2.3.4 Macroscopic evaluation of palaeopathology

All bones, regardless of their preservation, were visually assessed for any macroscopic indication of pathological bone alterations. Diagnoses were based on the bony characteristics of the defects as well as the distribution of the lesions across the skeleton. All lesions were compared to standard palaeopathological texts and photographs and illustrations found in the publications of Steinbock (1976), Roberts and Manchester (1995),

Mann and Murphy (1990), Larsen (1997), Aufderheide and Rodríguez-Martín (1998) and Ortner (2003).

Where possible, Chi-square tests were performed to determine if significant differences existed between the Gladstone sample and comparative populations in terms of pathological lesion prevalence and the prevalence of lesions between males and females.

Methods used to assess the dental health of individuals in the Gladstone skeletal sample as well as craniometric techniques employed to determine the possible ancestry of these unknown individuals will be discussed in Chapters seven and nine, respectively.

References

Asala, S.A. 2001. Sex determination from the head of the femur of South African whites and blacks. *Forensic Science International* 117:15-22.

Asala, S.A., Bidmos, M.A. and Dayal, M.R. 2004. Discriminant function sexing of fragmentary femur of South African blacks. *Forensic Science International* 145: 25-29.

Aufderheide, A.C. and Rodríguez-Martín, C. 1998. *The Cambridge Encyclopedia of Human Paleopathology*. Cambridge: Cambridge University Press.

Becker, M.J. 1986. Mandibular symphysis (medial suture) closure in modern *Homo sapiens*: preliminary evidence from archaeological populations. *American Journal of Physical Anthropology* 69:499-501.

Berrizbeitia, E.L. 1989. Sex determination with the head of the radius. *Journal of Forensic Sciences* 34:1206-1213.

Brooks, S. and Suchey, J.M. 1990. Skeletal age determination based on the os pubis: a comparison of the Acsadi-Nemeskeri and Suchey-Brooks methods. *Journal of Human Evolution* 5:227-238.

Brothwell, D. 1989. The relationship of tooth wear to ageing. In: *Age Markers in the Human Skeleton*. İşcan, M.Y. (ed). Springfield: Charles C Thomas, pp.303-318.

Byrd, J.E. and Adams, B.J. 2003. Osteometric sorting of commingled human remains., *Journal of Forensic Science* 48:717–723.

Day, M.H. 1975. Sexual differentiation in the innominate bone studied by multivariate analysis. *Annals of Human Biology* 2:143-151.

De Villiers, H. 1968. Sexual dimorphism of the skull of the South African Bantu-speaking Negro. *South African Journal of Science* 84:118-124.

Flander, L.B. 1978. Univariate and multivariate methods for sexing the sacrum. *American Journal of Physical Anthropology* 49:103-110.

Foti, B., Lalys, L., Adalian, P. and Guistiniani, J. 2003. New forensic approach to age determination in children based on tooth eruption. *Forensic Science International* 132:49-56.

Franklin, D., Freedman, L. and Milne, N. 2005. Sexual dimorphism and discriminant function sexing in indigenous South African crania. *Homo* 55: 213-228.

Hillson, S. 1998. *Dental Anthropology.* Cambridge: Cambridge University Press.

Johnston, F.E. and Zimmer, L.O. 1989. Assessment of growth and age in the immature skeleton. In: *Reconstruction of Life from the Skeleton.* İşcan MY (ed). New York: Alan R. Liss.

Kemkes-Grottenthaler, A., Lobig, F. and Stock, F. 2002. Mandibular ramus flexure and gonial eversion as morphological indicators of sex. *Homo* 53:97-111.

Kieser, J.A., Moggi-Cecchi, J. and Groeneveld, H.T. 1992. Sex allocation of skeletal material by analysis of the proximal tibia. *Forensic Science International* 56:29-36.

Kósa, F. 1989. Age estimation from the fetal skeleton. In: *Age Markers in the Human Skeleton.* İşcan MY (ed). Springfield: Charles C Thomas, pp.21-54.

Krogman, W.M. and İşcan, M.Y. 1986. *The Human Skeleton in Forensic Medicine*, 2 ed. Springfield, Illinois: Charles C Thomas.

L'Abbe, E.N. 2005. A case of commingled remains from rural South Africa. *Forensic Science International*, 151:201-206.

Larsen, C.S. 1997. *Bioarchaeology: Interpreting Behavior from the Human Skeleton.* Cambridge: Cambridge University Press.

Lovejoy, C.O., Meindl, R.S. and Mensforth, R.P. 1985. Multifactorial determination of skeletal age at death: a method and blind tests of its accuracy. *American Journal of Physical Anthropology* 68:1-14.

Loth, S.R. and Henneberg, M. 1996. Mandibular ramus flexure: a new morphologic indicator of sexual dimorphism in the human skeleton. *American Journal of Physical Anthropology* 99:473–485.

Loth, S.R. and İşcan, M.Y. 1994. Morphological indicators of skeletal aging: implications for paleodemography and paleogerontology. In: *Biological Anthropology and Aging: Perspectives on Human Variation over the Life Span.* Crews, D.E. and Garruto, R.M. (eds) New York: Oxford University Press, pp.395-421.

Loth, S.R. and İşcan, M.Y. 2000a. Morphological age estimation. In: *Encyclopedia of Forensic Sciences*. Siegel, J., Saukko, P. and Knupfer, G. (eds). London: Academic Press, pp.242-252.

Loth, S.R. and İşcan, M.Y. 2000b. Sex determination. In: *Encyclopedia of Forensic Sciences*. Siegel, J., Saukko, P. and Knupfer, G. (eds). London: Academic Press, pp.252-260.

Loth, S.R. and Henneberg, M. 2001. Sexually dimorphic mandibular morphology in the first few years of life. *American Journal of Physical Anthropology* 115:179-186.

Lundy, J.K. and Feldesman, M.R. 1987. Revised equations for estimating living stature from the long bones of the South African Negro. *South African Journal of Science* 83:54-55.

Mann, R.W. and Murphy, S.P. 1990. *Regional Atlas of Bone Disease: A Guide to Pathologic and Normal Variation in the Human Skeleton.* Springfield: Charles C Thomas.

Masset, C. 1989. Age estimation on the basis of cranial sutures. In: *Age Markers in the Human Skeleton.* İşcan, M.Y. (ed). Springfield: Charles C Thomas, pp.71-104.

Massler, M., Schour, I. and Poncher, H. 1941. Developmental pattern of the child as reflected in the calcification pattern of teeth. *American Journal of Diseases of Children* 62:33-67.

Meindl, R.S., Lovejoy, C.O., Mensforth, R.P. and Don Carlos, L. 1985. Accuracy and direction of error in the sexing of the skeleton: implications for paleodemography. *American Journal of Physical Anthropology* 68:79-85.

Morris, A.G. 1984. *An Osteological Analysis of the Protohistoric Populations of the Northern Cape and Western Orange Free State, South Africa.* Unpublished Ph.D. Thesis, University of the Witwatersrand.

Morris, D., van Ryneveld, K. and Voigt, E.A. 2004. Outside Gladstone Cemetery: first thoughts on unmarked late nineteenth century graves, Kimberley. In: Morris, D. and Beaumont, P. (eds) *Archaeology in the Northern Cape: Some Key Sites*. Kimberley: McGregor Museum.

Oettlé, C. and Steyn, M. 2000. Age estimation from sternal ends of ribs by phase analysis in South African blacks. *Journal of Forensic Sciences* 45:1071-1079.

Ortner, D.J. 2003. *Identification of Pathological Conditions in Human Skeletal Remains*, 2 ed. Amsterdam: Academic Press.

Patriquin, M.L., Loth, S.R. and Steyn, M. 2003. Sexual dimorphic pelvic morphology in South African whites and blacks. *Homo* 53:225-262.

Roberts, C. and Manchester, K. 1995. *The Archaeology of Disease*, 2 ed. Stroud: Alan Sutton Publishing.

St Hoyme, L.E. and İşcan, M.Y. 1989. Determination of sex and race: accuracy and assumptions. In: *Reconstruction of Life from the Skeleton*. İşcan, M.Y. and Kennedy, K.A.R. (eds). New York: Wiley-Liss, pp.53-94.

Scheuer, L. and Black, S. 2000. *Developmental Juvenile Osteology.* London: Academic Press.

Scheuer, L. and Black, S. 2004. *The Juvenile Skeleton.* Amsterdam: Elsevier Academic Press.

Schutkowski, H. 1993. Sex determination of infant and juvenile skeletons: I. morphognostic features. *American Journal of Physical Anthropology* 90:199-205.

Sjøvold, T. 2000. Stature estimation from the skeleton. In: *Encyclopedia of Forensic Sciences.* Siegal, J., Saukko, P. and Knupfer, G. (eds). London: Academic Press, pp.276-283.

Steinbock, R.T. 1976. *Paleopathological Diagnosis and Interpretation*. Springfield: Charles C. Thomas.

Steyn, M. and İşcan, M.Y. 1997. Sex determination from the femur and tibia in South African whites. *Forensic Science International* 90:111-119.

Steyn, M., L'Abbé, E.N. and Loots, M. 2004. *Forensic Anthropology.* Pretoria: Department of Telematic Learning and Education Innovation, University of Pretoria.

Ubelaker, D.H. 1987. Estimating age at death from immature human skeletons: an overview. *Journal of Forensic Sciences* 32:1254-1263.

Ubelaker, D.H. 1989. The estimation of age at death from immature human bone. In *Age Markers in the Human Skeleton.* İşcan, M.Y. (ed). Springfield: Charles C Thomas, pp.55-70.

Ubelaker, D.H. 2002. Approaches to the study of commingling in human skeletal biology. In: *Advances in Forensic Taphonomy: Method, Theory and Archaeological Perspectives.* Haglund, W.D. and Sorg, M.H. (eds). Florida: CRC Press, pp.355-378.

Van der Merwe, A.E. 2007. *Human Skeletal Remains from Kimberley: An Assessment of Health in a 19th Century Mining Community*. Unpublished MSc thesis. University of Pretoria.

Weaver, D.S. 1979. Application of the likelihood ratio test to age estimation using the infant and child temporal bone. *American Journal of Physical Anthropology* 50:263-270.

Wilson, M.L. and Lundy, J.K. 1994. Estimated living statures of dated Khoisan skeletons from the south-western coastal region of South Africa. *South African Archaeological Bulletin* 49: 2-8.

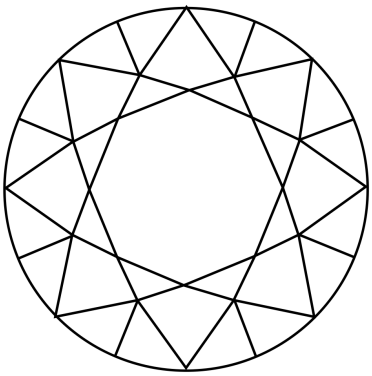

CHAPTER 3

Results

Modified from article accepted for publication as:

The history and health of a nineteenth-century migrant mine-worker population from Kimberley, South Africa

A.E. Van der Merwe, D. Morris, M. Steyn, G.J.R. Maat

South African Archaeological Bulletin

Bultfontein mine compound
(McGregor Museum Kimberley photography nr.599)



Kimberley mine compound, 1904
(McGregor Museum Kimberley photography nr.833)

3.1 Archaeological findings

In general there was a consistency in burial pattern, although some aspects varied from grave to grave. Two of the 15 graves investigated contained only one individual each, buried in coffins. One grave contained two individuals, and the remainder of the graves contained between five and 14 skeletons each. Within the graves, some individuals had been laid supine with some semblance of decorum. Occasionally skeletons were found side-by-side, and successive inhumations were separated by a layer of grave-fill. However, in other instances skeletons were found prone, on their sides, squeezed into corners, or packed one on top of another (see Figure 3.1). In one case an individual had been placed on his back with his legs flexed upwards against the end wall of the grave, making room for another body that was lodged against the other end of the pit. It was clear that several of the burial events within these graves had involved multiple simultaneous interments.

Figure 3.1 One of the 15 graves excavated from the trench. It is clear from this photo that little attention was given to burial practices, with three individuals being visible in this grave: the first on his right side, the second lying prone and the third supine against the grave wall to his right.

In almost all instances, bodies were aligned with their heads to the west, though one individual was found facing east. The variability in the number of skeletons per grave may be a reflection on the fluctuating, yet high, daily 'pauper' mortality rates in Kimberley at the time, and it appears that perhaps one grave per day was provided for these burials. In 1883, 'native interments' at Gladstone Cemetery averaged 4.5 per diem (Swanepoel, 2003).

It is difficult to conceive of any attendant burial rite, and in many cases it could hardly be said a 'laying to rest' had taken place. There appears to have been scant regard for the dignity of the dead and one would wonder to what extent any living relatives would have been informed of these deaths.

In striking contrast to the somewhat haphazard disposal of corpses within the graves was the formal regularity of the graves themselves: precisely dug in rows, orientated east-west to a depth of 2 meters, with the sides tapering slightly outwards towards the base. Earlier there was anxiety about certain Kimberley burials having been too close together and "of a depth totally inadequate" (Matthews & Shillito, 1879), but altogether more systematic cemetery management was clearly in place by the 1890s. Even so, these Gladstone graves were filled to within half a meter of the surface in some cases – hence the disturbance of remains when trenching eventually brought the unmarked graves to light. A final indignity was that as the earth and any slight mounds settled and subsided, aggravated by the flow of waste water from the adjacent mining property (Swanepoel, 2003), trash from the ash heap, including discarded broken bottles and flattened tins, was dumped as fill to form a stratigraphic veneer over the graves. Thus, it is not unexpected that this portion of the burial ground was excluded when the cemetery was later re-fenced.

A markedly small percentage of the interments that were investigated were in coffins (n = 3). It appears that the greater proportion of corpses brought to this part of the cemetery would have arrived wrapped only in hessian sacking (partially preserved in a few cases) or other fabric. There were limited indications of clothing in the graves, with buttons, parts of leather shoes (with metal eyelets) and belt buckles being found in only a few instances.

Grave goods were predominantly in the form of personal ornaments and were comprised of glass, copper and iron beads, twisted copper and iron bangles (worn on wrists, arms, ankles or as necklaces), and copper ear-rings. The only grave goods of an explicitly religious nature were a clutch of objects probably from a bag (traces of which had disintegrated) clearly representing *ditaola*, i.e. animal bones, shells and buttons, used for traditional African divining. All of these personal objects point to rural connections. A summary of all grave goods recovered during excavation can be seen in Appendix 2.

Evidence of medical intervention was encountered repeatedly during the archaeological phase of the investigation. This included bandaging on limbs and several instances of amputation. In one case part of an amputated limb (wrapped in dressings) was found inside a coffin belonging to another individual. There was also evidence of

postmortem procedures, such as craniotomies, known to have been carried out by pathologists in Kimberley from the 1880s. It seemed possible that the majority, if not all, of those individuals buried in this part of the cemetery had come from a hospital context.

3.2 Demography

Skeletal elements salvaged from the dump site about a kilometer away, to which the trench contents were taken, represented a minimum number of 26 individuals with a minimum number of 17 males, 5 females and 4 persons of unknown sex (see Table 3.1). It is important to consider that some of the remains excavated from the dumpsite may have belonged to individuals who were partly exhumed from the trench and were therefore already accounted for. Thus, although remains from the dump represent at least 26 individuals, it cannot be assumed that these bones increase the sample size of the skeletal population in general. The main focus of this study was the remains excavated from the trench and only these will be discussed further. Tables describing all the elements recovered from the dump as well as calculations made to determine the minimum number of individuals (MNI) represented by the remains can be seen in Appendix 3.

Table 3.1 Number of individuals excavated from the Gladstone cemetery and Dumpsite and their sex distribution.

Site	N	M	%	F	%	U	%
Dump site	26*	17*	65.3	5*	19.2	4*	15.3
Gladstone cemetery	107	86	80.3	15	14	6	5.7

*This number represents the minimum number of individuals represented by the skeletal elements recovered from the Dump site. N = number of individuals/skeletons in the population, M = Male, F = Female, U = unknown

The 15 graves that were exhumed yielded 107 *in situ* skeletons and included 86 males, 15 females and 6 individuals of unknown sex. Almost all individuals excavated from the trench were between 20 and 49 years of age (see Table 3.2), matching the high mortality rate reported in archival documents for people aged between 15 and 45 years in Kimberley at the time (Stoney, 1900a,b). One foetus, two infants and 13 juveniles aged between 11 and 19 years were the only non-adults observed in this study. Fifty-two individuals were between 20 and 34 years of age (n = 52). Twenty-five persons were estimated to have been

between 35 and 49 years of age at the time of death and only four individuals were estimated to have been older than 50 years. Due to the fragmentary condition of some of the remains investigated in this study, eight individuals could only be described as being adult and two were of indeterminate age.

Table 3.2 Summary of the age distribution of skeletons excavated from the trench at Gladstone

Age in years	n	%	Cum. %
Antenatal	1	0.9	0.9
0-10	2	1.9	2.8
11-19	13	12.1	14.9
20-34	52	48.6	63.5
35–49	25	23.4	86.9
≥50	4	3.7	90.6
Adult	8	7.5	98.1
Unknown	2	1.9	100.0
Total	107	100	

n = number of individuals,
Cum % = Cumulative %

3.3 Palaeopathology

A list of all the pathological conditions observed in this sample population can be seen in Table 3.3. Infectious diseases, including treponemal disease, tuberculosis and non-specific osteomyelitis, were observed in 11 individuals (10.3%). Lesions suggestive of treponematosis were observed in nine skeletons. This condition was mainly characterized by osteomyelitic changes and subperiosteal bone growth on the anterior tibia resulting in sabre-shin tibiae (77.8% of those affected) (see Figure 3.2). Osteomyelitic changes of the fibula (66.7% of cases) and humerus (in one case), as well as gummatous lesions on the cranial vault (55.6% of cases), were also frequently observed. Due to the small sample size of females in this study, no significant difference (χ^2 = 2.15, p-value > 0.1) could be found in the prevalence of treponemal infection between males and females.

Non-specific osteomyelitis was observed in only one individual with severe osteomyelitis of the right tibia and fibula (GLD SE11.2). A large cloaca was present on the medial aspect of the right tibia, with abundant reactive new bone growth on the affected tibia and fibula (see Figure 3.3). Evidence of new bone formation was present throughout the affected bones, causing a change in bone morphology as well as ankylosis of the proximal and distal ends of the joints. The infection also spread to the right foot and accordingly, severe infection and pathological new bone growth was seen on the right talus and calcaneus.

An individual with osteomyelitic changes to the lumbar vertebrae, left patella and right olecranon process was diagnosed with possible tuberculosis (GLD N8.3).

Table 3.3 Frequency of skeletal pathologies observed in the Gladstone sample.

Pathological condition	N	na	%
Infectious diseases			
Treponemal disease	107	9	8.4
Tuberculosis	107	1	0.9
Non-specific osteomyelitis	107	1	0.9
Metabolic and nutritional disorders			
Scurvy	107	16	15.0
Trauma			
Fractures	107	28	26.2
Myositis ossificans	107	9	8.4
Amputations	107	6	5.6
Spondylolysis	82	7	8.5
Longstanding subluxation	107	2	1.9
Degenerative disorders			
Schmörl's nodes	87	27	31.0
Degenerative joint changes	107	24	22.4
Degenerative disc disease	87	13	14.9
Non-specific indicators of pathology			
Cribra orbitalia	82	9	11.0

n = number of individuals assessed, na = number of individuals affected

Figure 3.2 Possible treponemal involvement of the tibia resulting in characteristic sabre-shin tibiae in a male between 35 and 50 years of age (GLD N74.7).

Figure 3.3 Osteomyelitis of the left tibia with cloaca formation, infectious involvement of the fibula causing widespread new bone formation, and proximal and distal ankylosis in an adult male (GLD SE11.2).

Healed scurvy was diagnosed in 16 individuals (15%): 13 males and three females. This diagnosis was based on the presence of mostly bilateral ossified subperiosteal haematomas on weight bearing bones and periodontal disease in the absence of poor dental health. Some of these individuals also displayed widespread subperiosteal bone apposition, most likely associated with slight healed/ossified subperiosteal bleeding. Although all of the abovementioned bone lesions may also be indicative of other diseases when viewed in isolation, the skeletal distribution of these lesions was interpreted as possible scurvy. This condition was well documented in hospital records and other historical documents as being problematic during the time period associated with the excavated remains. Further details, as well as histological findings associated with the ossified haematomas and scurvy observed in this sample, are discussed in Chapters five and six (Van der Merwe *et al.*, 2010a; Van der Merwe *et al.*, 2010c).

A large number of individuals also presented with traumatic lesions, which included myositis ossificans, amputations, spondylolysis, lesions indicative of longstanding subluxation and fractures (see Table 3.3). Of the aforementioned lesions, healed and perimortem fractures were the most common, with 28 individuals (26.2%) being affected. Cranial fractures (see Figure 3.4) encompassed 48.8% of all fractures observed. Of special interest is the occurrence of amputations in this sample population (n=6). These included evidence of healed amputations, amputations done shortly before death as well as separated amputated limbs (Van der Merwe *et al.*, 2010b). Trauma observed in this population will be discussed in more detail in Chapter four.

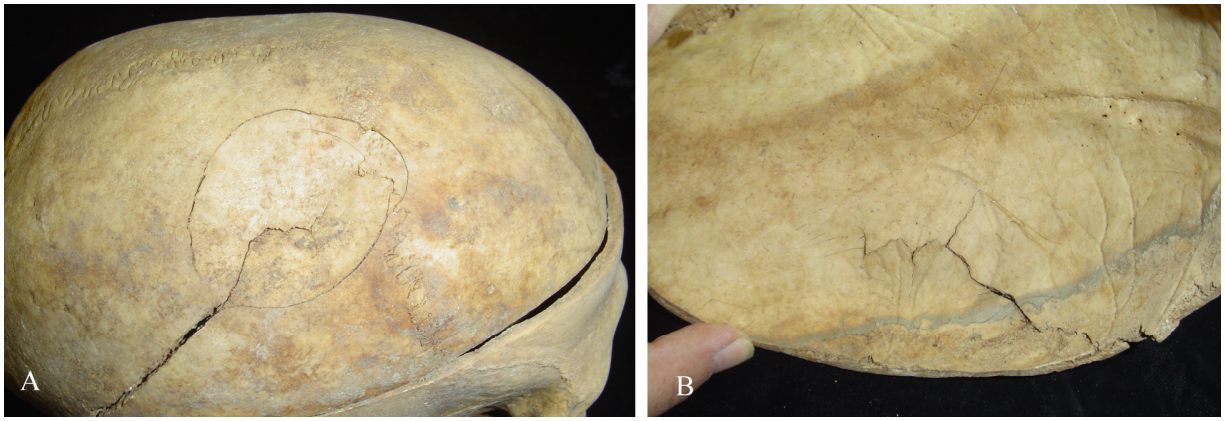

Figure 3.4 Perimortem blunt force trauma to the right parietal bone observed in a male 30 – 45 years of age at the time of death (GLD N74.6).

Although the majority of skeletons within this sample population were those of young individuals, several displayed skeletal lesions indicative of joint degeneration. Schmörl's nodes were observed in 27 individuals (31%). All those affected by the condition were younger than 45 years of age, with the majority being between 20 and 34 years old. When comparing the prevalence of these lesions to other South African skeletal samples such as the rural Venda and another contemporary sample of mine labourers from Koffiefontein it becomes evident that individuals in the Gladstone skeletal sample were significantly more affected by Schmörl's nodes (Venda (2.6%) (χ^2 = 33.81, p-value < 0.001), Koffiefontein skeletal sample (13.9%) (χ^2 = 3.8, p-value < 0.05)) (L'Abbé *et al*., 2003; L'Abbé, 2005b).

Osteoarthritic changes[1] were noted in 21 (24.4%) males and three (20%) females. These included acetabular (7.5% of 133 acetabulums), sacro-iliac (n=2, 2%), acromio-clavicular, (n= 8, 7.9%), and temporo-mandibular (n=1, 1%) joint changes. No significant difference (χ^2 = 0.13, p-value > 0.2) in the prevalence of arthritic changes was observed between males and females (most likely due to the poor sample distribution).

Vertebral osteophytosis as a result of degenerative disc disease (Maat *et al.*, 1995) was noted in 11 males and two females. There was no significant difference in the frequency between males and females (χ^2 = 0.003, p-value > 0.2). The prevalence of this condition (14.9%) was statistically comparable to results obtained from another contemporary mining population sample from Koffiefontein (22.2%) (χ^2= 0.95, p-value > 0.05) (L'Abbé *et al.,* 2003).

[1] The terms "osteoarthritic changes" or "arthritic observations" are used here to refer to the general degenerative changes observed in synovial joints, without specifying the disease responsible for the change.

Lastly, non-specific indicators of health, particularly cribra orbitalia, were observed in nine individuals (11%). This included two (15.3%) females and seven (10.1%) males. Orbits were affected bilaterally in most cases except in two individuals (GLD SE7.8 and GLD N34.4). In both these cases, only the left orbit was affected. No porotic hyperostosis was noted in any of the affected individuals.

References

Maat, G.J.R., Mastwijk, R.W. and Van der Velde, E.A. 1995. Skeletal distribution of degenerative changes in vertebral osteophytosis, vertebral osteoarthritis and DISH. *International Journal of Osteoarchaeology* 5:289-298.

Matthews, J.W. and Shillito, J. 1879. Report on the sanitary condition of Kimberley. *Supplement to the Independent*, Saturday 29 March 1879. insert between pp.2-3.

Stoney, W.W. 1900a. *Annual Report of the Medical Officer of Health, Kimberley, for the Year 1898*.

Stoney, W.W. 1900b. *Annual Report of the Medical Officer of Health for the Year 1899*.

Swanepoel, S. 2003. *Gladstone Cemetery, 1880s to 1900s.* Archival report housed in McGregor Museum Kimberley, South Africa.

Van der Merwe, A.E., İşcan, M.Y., and L'Abbé, E.N. 2006. The pattern of vertebral osteophyte development in a South African population. *International Journal of Osteoarchaeology* 16:459-464.

Van der Merwe, A.E., Maat, G.J.R. and Steyn M. 2010a. Histomorphological observations of pathological lesions on the anterior tibiae of individuals from a 19th century mining community in Kimberley, South Africa. *International Journal of Osteoarchaeology* 20(2):227-239.

Van der Merwe, A.E., Steyn, M. and L'Abbé E.N. 2010b. Trauma and amputations in 19th century miners from Kimberley, South Africa. *International Journal of Osteoarchaeology* 20(3):291-306.

Van der Merwe. A.E., Steyn, M. and Maat, G.J.R. 2010c. Adult scurvy in skeletal remains from late 19th century mineworkers from Kimberley, South Africa. *International Journal of Osteoarchaeology* 20(3):307-316.

CHAPTER 4

Trauma and Amputations in 19th Century Miners from Kimberley, South Africa

Modified from article published as:

Trauma and amputations in 19th century miners from Kimberley, South Africa

A.E. Van der Merwe, M. Steyn, E.N. L'Abbé

International Journal of Osteoarchaeology (2010)

20(3):291-306



De Beers Mine disaster, 12 July 1888
(McGregor Museum Kimberley photography nr.2459)



Kimberley mine aerial gear, 1890s
(McGregor Museum Kimberley photography nr.5030)

Abstract

Trauma is the result of violent, accidental or therapeutic events that cause physical or psychological injury. The frequencies and types of trauma within a population can give important information regarding lifestyle as well as the quantity and quality of medical care available to them. The purpose of this study was to assess the prevalence of trauma in the Gladstone sample population with regards to the presence of interpersonal violence, a hazardous working environment, strenuous working requirements and the availability of medical care.

The individuals studied here were diamond miners from Kimberley, dating to the late 19th century. A total of 107 well-preserved skeletons were excavated from unmarked graves after accidental discovery. This sample included 86 males, 15 females and 6 individuals of unknown sex. The majority of individuals (72%) were between 20 and 49 years of age. The remains were most likely those of migrant mine workers of low socioeconomic status who had passed away in local hospitals. All bones were visually assessed for macroscopic indications of traumatic bone alterations and compared to standard palaeopathological texts and photographs.

A total of 26.2% (n=28) of the individuals in the sample presented with well-healed, healing or perimortem fractures. Fractures to the skull encompassed 48.8% (n=20) of all fractures observed. A total of six (5.6%) amputations were noted. Spondylolysis was observed in 8.5% (n=7) of individuals within the sample and longstanding subluxation was noted in two persons. The high prevalence of cranial fractures within this population is suggestive of high levels of interpersonal violence, while long bone fractures, spondylolysis and evidence of longstanding subluxations are most likely testament to the strenuous work requirements and the high-risk environment to which these individuals were exposed on a daily basis. When considering the presence of well-reduced fractures and healed amputations, it seems that adequate medical care was available to at least some members of this community.

4.1 Introduction

Diamonds were first discovered on Colesberg Kopje (today known as the 'big hole') in Kimberley, South Africa in 1871. By August of that year, approximately 800 claims had been cut out of Colesberg Kopje and between 2000 and 3000 men were working there (Roberts, 1976). Colesberg Kopje was soon to become Kimberley, the first town in South Africa to be completely dependant on its mineral wealth, the first to experience a strike and the first town to have its streets lit by electricity (Roberts, 1976).

During the late 19th century, historical documents indicate that 'native' individuals flooded to Kimberley from surrounding areas and neighbouring countries in search of work in the mines (Stoney, 1900). A census held in 1898 established there were approximately 14 500 Europeans and 26 500 black labourers living and working in Kimberley (Stoney, 1900). The number of black labourers in Kimberley was extremely changeable and dependant on the demand for labour in the mines (Stoney, 1900; McNish, 1970; Jochelson, 2001). Black labourers ''from almost every tribe south of the Zambezi'' (Roberts, 1976:15) were brought to Kimberley to work and when their contracts expired, returned to their 'kraals' (Leary, 1891; McNish, 1970; Roberts, 1976:294).

Mining was a labour-intensive task, fresh fruit and vegetables were scarce, comfortable accommodation was restricted and medical care limited. All of these factors contributed to the high prevalence of disease and injury described in archival documents reporting conditions treated at the Kimberley Hospital (Cape of Good Hope Votes and Proceedings of Parliament (CGHVPP), 1899; Stoney, 1900; Roberts, 1976; Van der Merwe, 2007).

Labourers received medical attention from the Kimberley and Compound Hospitals. In the case of death, the patient was wrapped in blankets and received a pauper's burial, without a coffin, in the Gladstone or other surrounding cemeteries (Swanepoel, 2003).

The Gladstone cemetery was officially opened on 24 March 1883, and half of the ground was devoted to African burials. Nearly 5000 African individuals were buried at the Gladstone cemetery between 24 June 1887 and 28 November 1892. Unfortunately, no registers were available for the period between 1892 and 1900. However, some documents indicate that a total of 611 pauper burials took place between February and June 1900 (Swanepoel, 2003).

In 1897, Gladstone cemetery was enlarged with an extra strip of land, given by the De Beers mining company, on the eastern side of the cemetery (see Figure 4.1). The cemetery

was closed in mid-1900 and opened again in April 1902 for European internments only. In 2003, the Sol Plaatjie municipality uncovered several unmarked graves in the abovementioned eastern area with these remains becoming the focus of this research in which the traumatic injuries of diamond mine workers were assessed.

Trauma is the result of intentional or accidental encounters with animals, humans and cultural hazards found in and around the home and working place, or therapeutic procedures that cause injury to a person (Merbs, 1989; Lovell, 1997; Walker, 2001; Neri & Lancellotti, 2004). The assessment of the prevalence of trauma in an archaeological population is difficult to interpret, since the investigation of dry bone poses several limitations. Determining trauma frequency rates is often hindered by poor preservation and fragmentation of skeletal remains and perimortem trauma often mimics post-depositional damage and consequently passes undetected. This is also the case in well-remodelled fractures (Grauer & Roberts, 1996).

Notwithstanding the difficulties, the assessment of trauma within a population can still yield considerable information. The prevalence and location of traumatic lesions are influenced by intrinsic factors such as age and sex, as well as extrinsic factors relating to culture (Lovell, 1997; Glencross & Stuart-Macadam, 2000; Ortner, 2003). Different environmental conditions and cultural practices expose individuals to specific traumatic hazards. Therefore, the study of the prevalence of trauma within a population can aid in reconstructing the occupational and environmental stresses the sample was exposed to, as well as various aspects of cultural behaviour

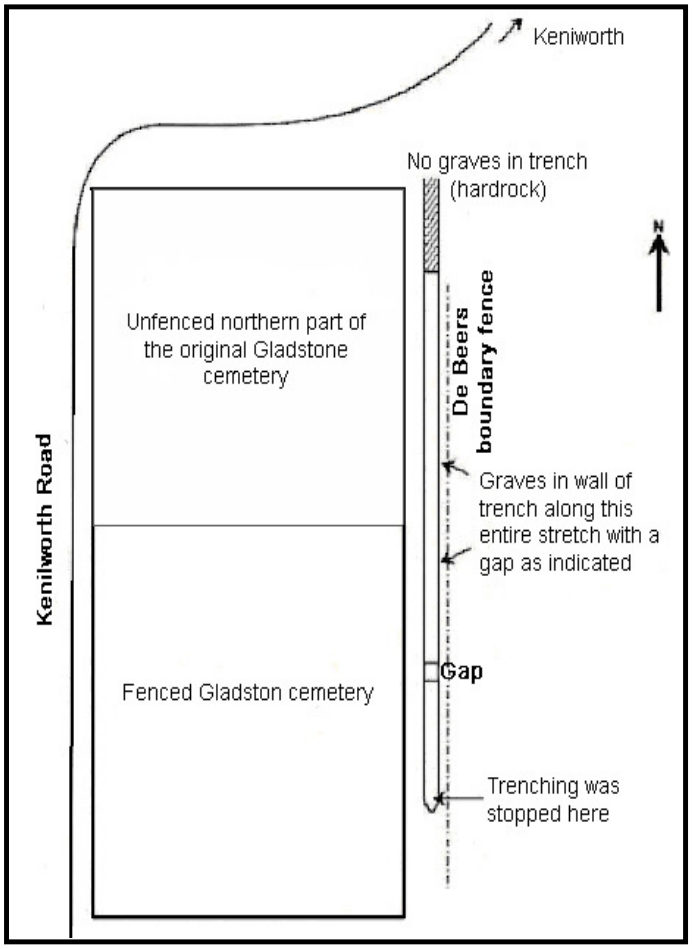

Figure 4.1 Map indicating the current fenced Gladstone cemetery, the location of the trench that uncovered the graves and the De Beers boundary fence. (Trench length ca. 180m)

(Steinbock, 1976; Jurmain & Bellifemine, 1997; Kilgore *et al*., 1997; Lovell, 1997; Ortner, 2003). By determining whether the fracture is healed, unhealed, reduced or infected, conclusions can be made regarding the availability of medical care and the accommodation of injured individuals within the community (Steinbock, 1976; Kilgore *et al*., 1997; Neri & Lancellotti, 2004).

The purpose of this study was to assess the prevalence of trauma in the skeletal population exhumed from the Gladstone cemetery. The prevalence, nature and location of fractures, amputations and longstanding subluxations will be interpreted and discussed with regard to the availability of medical care at the close of the 19th century, levels of interpersonal violence and exposure to a hazardous working environment (i.e. mining).

4.2 Materials and Methods

In April 2003, numerous unmarked graves were disturbed outside the fenced Gladstone cemetery. The McGregor Museum in Kimberley was given permission by the South African Heritage Resources Agency (SAHRA) to exhume and investigate the human remains.

The remains are believed to be those of migrant mine workers who died in surrounding hospitals in Kimberley between 1897 and 1900 (Van der Merwe, 2007). These individuals were most likely of low socio-economic status, malnourished and exposed to a high pathogen load (Van der Merwe, 2007). The low socioeconomic status of these individuals was clearly illustrated by their burial positions, with the majority of persons being laid to rest without coffins in graves containing more than one individual.

Standard anthropometric techniques such as morphological changes of the sternal ends of the ribs, changes to the pubic symphysis, cranial suture closure, as well as cranial and pelvic morphology and discriminant functions were used to determine the age and sex of all individuals exhumed from the trench (e.g. De Villiers, 1968; Krogman & Íşcan, 1986; Hillson, 1998; Oettlé & Steyn, 2000; Asala, 2001; Franklin *et al*., 2005).

A total of 86 males, 15 females and 6 individuals of unknown sex were excavated from the trench. The majority of these individuals (72%) were between 20 and 49 years of age, while the rest were comprised of one premature baby, two infants (both younger than one year of age), 13 juveniles (11–19 years) and four individuals older than 50 years of age. Due to the fragmentary condition of some of the remains, eight individuals could only be

described as adult and two were of unknown age. With the exception of these 10 skeletons, all others were remarkably well preserved and complete.

All bones were visually assessed for macroscopic indications of traumatic bone alterations and diagnoses were made based on the bony characteristics of the defects. All lesions were compared to standard palaeopathological texts and photographs as can be found in Steinbock (1976), Mann and Murphy (1990), Roberts and Manchester (1995), Larsen (1997), Aufderheide and Rodríguez-Martín (1998) and Ortner (2003). X-rays were not part of the routine investigation due to time and financial constraints.

Special attention was also given to distinguish between perimortem trauma and damage caused to the remains by the trenching machinery. Perimortem fractures were identified by the absence of signs of healing. Fracture lines associated with these fractures are generally sharp and coupled with radiating lines (hairline fractures) at the site of trauma. The fractured ends are also just as discoloured and weathered as the adjacent bone, and therefore it could be determined whether unhealed fractures were the result of damage by the trenching machinery or perimortem trauma (Steinbock 1976; Mann & Murphy, 1990; Roberts & Manchester, 1995; Ortner, 2003).

The prevalence of skeletal lesions indicative of trauma was determined in relation to the number of individuals within the sample population, as well as the number of bony elements investigated. These frequencies were compared to other studies conducted in South Africa and northern Chile (Eisenstein, 1978; Standen & Arriaza, 2000). Chi-squared tests were carried out in order to compare the prevalence of traumatic lesions between these comparative groups and the Gladstone sample. Where possible, chi-squared tests were also performed in order to test for significant differences in the frequency of lesions between males and females.

4.3 Results

4.3.1 Fractures

A total of 26.2% (n=28) of the individuals excavated from the trench (see Table 4.1) presented with well-healed, healing or perimortem fractures. Twenty-four of these were male and four female. No significant difference could be found in the frequency of fractures between the sexes (χ^2=0.006, p-value > 0.2).

Table 4.1 Number of individuals with fractures in the Gladstone skeletal sample.

Sex	n	nf	%
Males	86	24	27,9
Females	15	4	26,7
Total	107	28	26.2

n = number of individuals examined
nf = number of individuals who presented with one or more fractures

A total of 36 fractured bones were observed (see Table 4.2). These included 15 fractured crania, five fractured femora, four fractured ribs, two fractured fibulae, radii, ulnae and claviculae as well as one fractured tibia, os coxa, humerus and vertebra. It is clear that the majority of fractures occurred on the skulls, with 17.9% of crania presenting with (a) lesion(s).

Single fractures were noted in 19 individuals, while six people had two fractures, two had three fractures each, and one male had a total of four fractures. A summary of this information can be seen in Table 4.3.

Eight perimortem fractures were observed in five skeletons. Several well-healed and remodeled fractures were also noted. These included a parry fracture (see Figure 4.2), also known as a defense fracture as it is usually the consequence of a blow to the ulna when lifting the arm in a defense position (Mann & Murphy, 1990; Smith, 1996). A radial fracture (see Figure 4.3) and a Pott's fracture, which is a fracture of the distal fibula resulting from twisting of the ankle, (see Figure 4.4) were also noted. A sprinter's fracture was recorded in a male between 15 and 18 years of age (see Figure 4.5). This is an avulsion fracture of the anterior inferior iliac spine caused by sudden strain on the rectus femoris muscle (Merbs, 1989).

Table 4.2 Number of skeletal elements fractured in the Gladstone skeletal sample.

Sex	S	Fe	Ti	Fi	Oc	Ra	Ul	Hu	Cl	Ri	Vb	Total
n	84	181	173	166	161	164	164	169	159	**	**	
Males	12	4	1	2	1	2	2	1	1	4	1	31
Females	3	1	0	0	0	0	0	0	1	0	0	5
Total	15	5	1	2	1	2	2	1	2	4	1	36
%	17,9	2,8	0,6	1,2	0,6	1,2	1,2	0,6	1,3	**	**	

n = Number of skeletal elements investigated
** = Due to the fragmentary condition of ribs and vertebrae, the total number of elements could not determined.
S = skull; Fe = femur; Ti = tibia; Fi = fibula; Oc = os coxa; Ra = radius; Ul = ulna; Hu = humerus; Cl = clavicle; Ri = rib; Vb = vertebra.

Figure 4.2 A well-healed parry/defense fracture (arrow) of the right ulna observed in a 30–40 year old male (GLD N74.4).

Figure 4.3 A well-healed radial fracture (arrow) of the left radius observed in a 30–40 year old male (GLD N38.3).

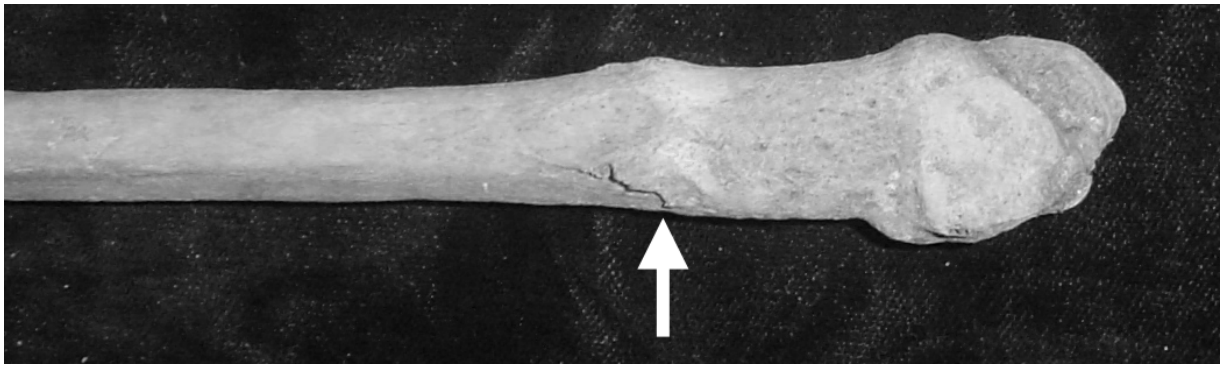

Figure 4.4 A well-healed Pott's fracture (arrow) of the right fibula observed in a 30–35 year old male (GLD N38.3).

Table 4.3 Prevalence of fractures observed in females from the Gladstone sample.

Number	Sex	Age (years)	Fr*	S	Fe	Ti	Fi	Oc	Ra	Ul	Hu	Cl	Ri	Vb
GLD SE11.6	F	30-37	1		1									
GLD N74.1	F	40-50	1	1										
GLD S2.4	F	33-43	2	1								1		
GLD SE7.5	F	30-43	1	1										
Total number of fractures in females			5	3	1							1		

Fr*=The number of fractures observed per individual. S = Skull; Fe = femur; Ti = tibia; Fi = fibula; Oc= Os coxa; Ra = radius; Ul = Ulna; Hu = humerus; Cl = clavicle; Ri = rib; Vb = vertebra.

Table 4.3 (cont.) Prevalence of fractures observed in males from the Gladstone sample.

Number	Sex	Age (years)	Fr*	S	Fe	Ti	Fi	Oc	Ra	Ul	Hu	Cl	Ri	Vb
GLD N31.E.1	M	30-40	3	3										
GLD N74.2	M	18-21	1	1										
GLD N74.5	M	40-55	1								1			
GLD N100.2	M	28-38	1									1		
GLD S1.2	M	25-35	1	1										
GLD N100.1	M	40-55	1	1										
GLD N34.3	M	30-35	2	2										
GLD N34.5	M	15-18	1					1						
GLD N34.6	M	22-28	1	1										
GLD N34.9	M	22-30	1	1										
GLD N34.12	M	22-30	1	1										
GLD N38.1	M	23-30	1										1	
GLD N38.2	M	25-29	4	1	1	1	1							
GLD N38.3	M	30-40	2				1		1					
GLD N74.6	M	30-45	3	2									1	
GLD N74.4	M	30-40	1							1				
GLD N8.2	M	25-30	1											1
GLD N8.10	M	20-25	1	1										
GLD S2.3	M	20-25	2		1				1					
GLD S2.9	M	35-45	2		1								1	
GLD S3.2	M	30-40	1										1	
GLD S3.5	M	25-30	1		1									
GLD S5.1	M	28-34	2	2										
GLD SE7.9	M	35-45	1							1				
Total number of fractures in males			36	17	4	1	2	1	2	2	1	1	4	1
Total number of fractures in sample			41	20	5	1	2	1	2	2	1	2	4	1

M = male; Fr*=The number of fractures observed per individual; S = Skull; Fe = femur; Ti = tibia; Fi = fibula; Oc = Os coxa; Ra = radius; Ul = Ulna; Hu = humerus; Cl = clavicle; Ri = rib; Vb = vertebra.

Figure 4.5 A healed sprinter's fracture of the anterior inferior iliac spine observed in a 15–18 year old male (GLD N34.5).

Fractures of the skull comprised 48.8% (n=20) of observed traumatic injuries and were by far the most frequent in the sample. These included six healed fractures of the nasal bone, one of the orbital margin, four fractures of the zygomatic bone, four depressed fractures of the frontal bone (see Figures 4.6 and 4.7) and five of the parietal bone. These lesions were all of relatively similar size and shape, with preference in location towards the left side of the skull. They are suggestive of blunt force trauma.

The limbs were the second-most affected body part, primarily with femoral fractures (n=5, 3%). Only one (1%) tibial and two (1%) fibular fractures were observed. The upper limbs were less affected than the lower limbs with the humerus (n=1, 1%), radius (n=2, 1%) and ulna (n=2, 1%) demonstrating five fractures in total (1% of investigated bones). No significant difference was observed between fractured bones of the upper or lower limbs (χ^2=0.502, p-value > 0.2). Furthermore, four rib fractures, two fractured clavicles and one vertebral fracture were also observed.

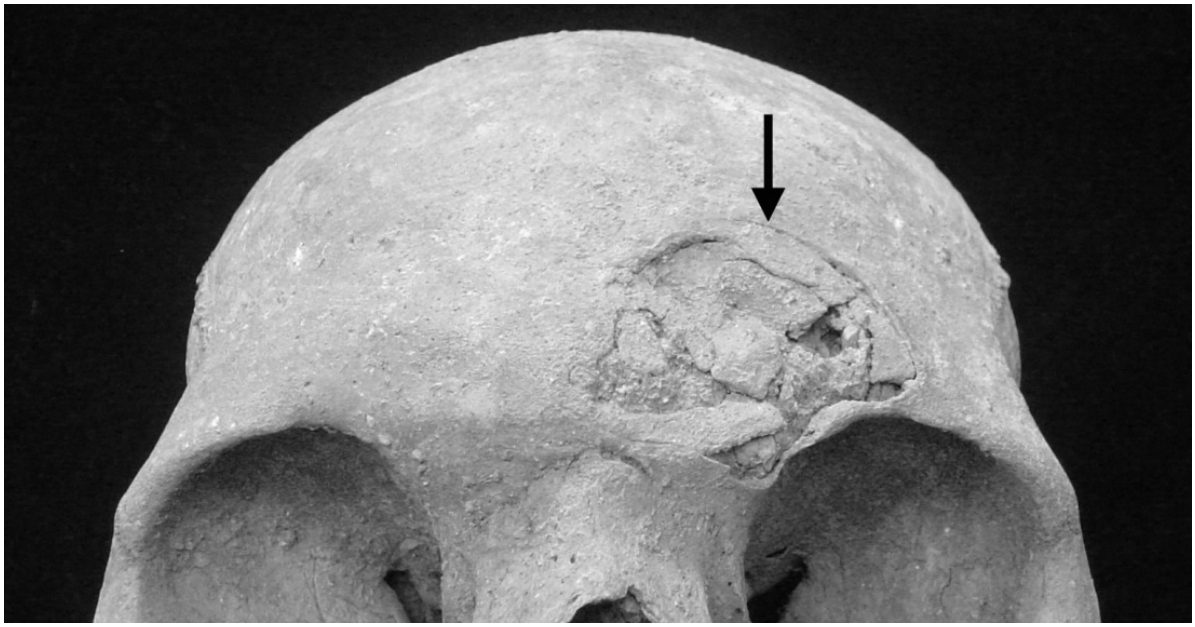

Figure 4.6 A partially healed fracture in the frontal bone in a 25–29 year old male (GLD N38.2).

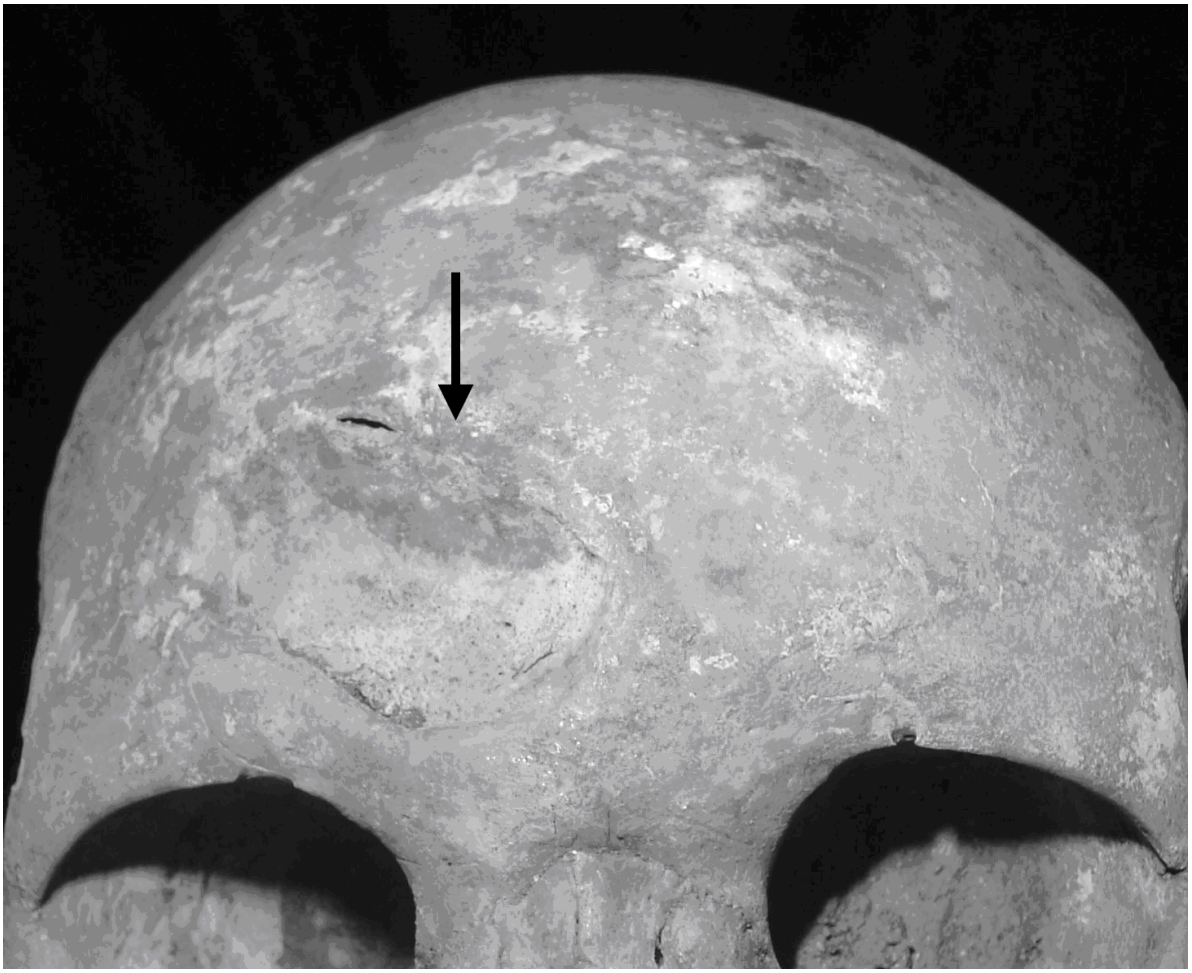

Figure 4.7 Healed depressed fracture of the frontal bone noted in a 30–40 year old male (GLD N31.E.1).

4.3.2 Spondylolysis and subluxation

Spondylolysis, a fracture of the vertebral arch resulting in bilateral separation of the pars interarticularis, was observed in 8.5% (n=7) of the sample (see Table 4.4). There was no significant difference in the prevalence of this lesion between the sexes (χ^2=0.001, pvalue > 0.2). All of the lesions showed bilateral separation of the neural arch (see Figure 4.8) and occurred on vertebrae L4 (n=3) or L5 (n=4). Spondylolysis associated with spondylolisthesis, the anterior sliding of the vertebral body as a result of the spondylolysis, was seen in one individual (GLD NOP 3/4.1). These injuries are often associated with strenuous physical labour and therefore can be expected to be present in these diamond mining labourers.

Another injury indicative of heavy, repetitive labour with little medical intervention would be the longstanding subluxation of joints, which was noted in two individuals (see Table 4.4). The first was in the right sternoclavicular joint of individual GLD S2.6,

Figure 4.8 Bilateral spondylolysis of L5 in a 35–50 year old male (GLD N 74.7).

resulting in remodelling and the formation of an articulation facet on the inferior surface of the sternal end of the clavicle. The second was found in a 40–55 year old male (GLD N74.5), with a fracture of the left humerus as the most likely cause. The non-reduced fracture caused shortening of the humeral shaft as well as medial rotation of the distal end of the humerus. In order to attain some functionality of the arm, subluxation of the shoulder joint occurred (see Figure 4.9). The subluxation caused a false articulation facet to develop between the acromion and the posterior surface of the humeral head. This most probably led to an unstable shoulder joint, with the humerus in a position of hyperextension and lateral rotation.

Table4.4 Prevalence of spondylolysis and subluxation in the Gladstone population.

Number	Sex	Age (years)	Spondylolysis	Spondylolisthesis	Subluxation
GLD N31.E.1	M	30-40	1		
GLD N74.3	M	17-22	1		
GLD N74.8	M	16-20	1		
GLD N74.5	M	40-55	1		1
GLD N34.8	F	20-23	1		
GLD N74.7	M	35-50	1		
GLD NOP 3/4.1	M	25-35	1	1	
GLD S2.6	M	35-45			1
Total			7	1	2
n			82	82	107
%			8.5	1.2	1.8

n - total number of individuals investigated, M – male, F – female.

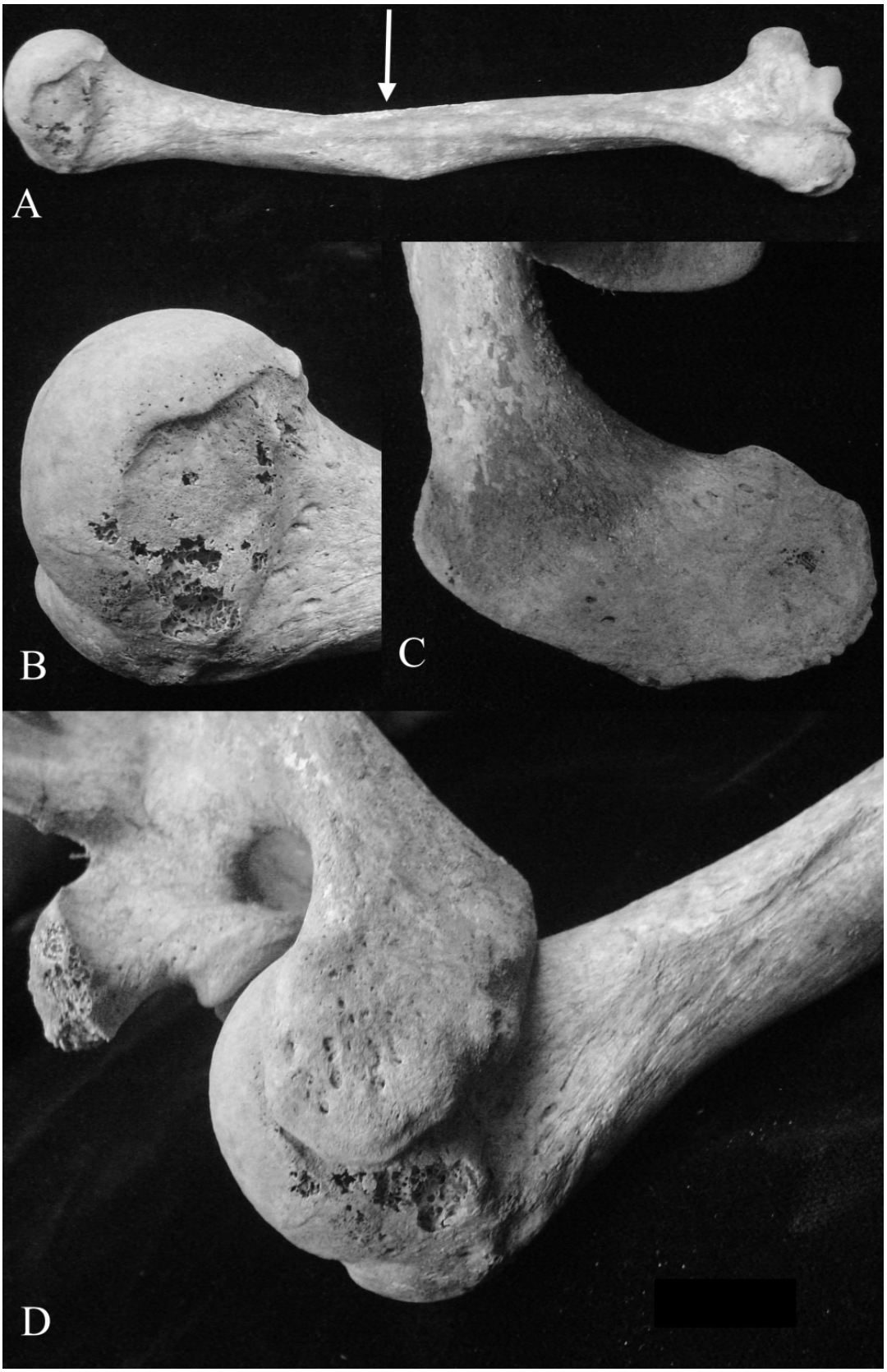

Figure4.9 Longstanding dislocation of the gleno-humeral joint caused the formation of an articulation surface between the humeral head and the inferior surface of the acromion process of the scapula in this 40–55 year old male (GLD N74.5). (a) The fracture of the humerus caused medial rotation of the distal end of the bone. The articulation surface between (b) the humeral head and (c) inferior acromion (d) can also be seen.

4.3.3 Amputations

While the dislocation of joints may not have received immediate care, evidence of medical intervention was noted in this sample with six individuals exhibiting healed or unhealed amputations. This included one amputation of the femur, two of the tibia and fibula, one of the foot at the ankle, one of the humerus and one of the proximal radius and ulna (see Table 4.5).

A 30–35 year old male (GLD N38.2) presented with an amputation of the right femur, approximately 106mm distal from the proximal end (see Figure 4.10). This person did not survive the procedure, as the amputated limb was buried with the individual and the amputation showed no macroscopic indication of healing. The reason for the amputation had most likely been a compound fracture of the distal femur (as observed during analyses of the remains) that had become severely infected, as was indicated by the reactive new bone growth present around the fractured end.

Examples of well-healed amputations included an amputation of the left tibia, fibula and foot (GLD N34.3) just distal to the proximal end of the left tibia and fibula (see Figure 4.11), as well as an amputation of the left foot (GLD S2.6). These amputations developed into the very characteristic peg shaped distal bone end associated with healed amputations, accompanied by closure of the medullary cavity (Mann & Murphy, 1990). Ankylosis of the distal ends of the left tibia and fibula occurred following amputation of the foot.

Table 4.5 Prevalence and location of amputations.

Number	Sex	Age(years)	Fem	Tib& Fib	Foot	Hum	Ul& Ra	T	%
GLD N34.3	M	30-35		1					
GLD N38.2	M	25-29	1						
GLD N8.1amp	M	Adult		1					
GLD S2.6	M	35-45			1				
GLD S2.7b	U	U				1			
GLD S2.7c	U	U					1		
Total n = 107			1	2	1	1	1	6	5.6

M – male, U – unknown, Fem – Femur, Tib – Tibia, Fib – Fibula, Hum – Humerus, Ul – Ulna, Ra – Radius, T – Total

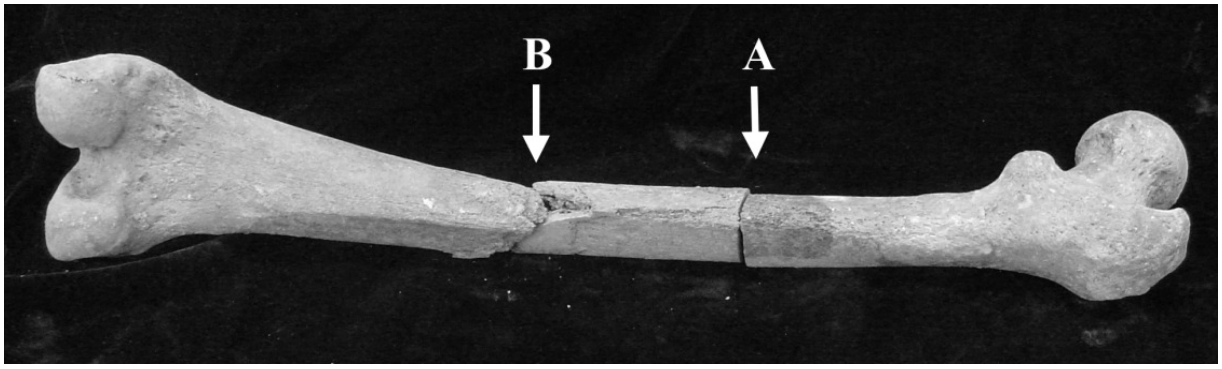

Figure 4.10 Right femur of a 25–29 year old male, amputated (A) following a compound fracture and (B) infection (GLD N38.2).

Figure 4.11 Well-healed amputation of the left tibia and fibula of a 30–35 year old male (GLD N34.3).

Apart from the abovementioned individuals who showed signs of amputations, three separate amputated limbs were also excavated. These amputations were of great interest, since some yielded information regarding the reason for the procedure.

The first amputated limb was composed of a left tibia, fibula and foot amputated just distal to the knee (GLD N1.8 (b)). The limb was found in a coffin with the complete skeleton of a 15–19 year old female. The cause for this amputation was severe infection of the lower leg, which had most likely commenced at the foot. Serious signs of infection with extensive remodeling and new bone formation on the left talus and calcaneus were observed along with signs of infectious new bone deposition on the tibia and fibula. A radius and ulna, amputated just distal to the elbow (GLD S2.7c), was also recorded. Signs of infectious new bone formation were present on the proximal half of the bones. The last amputated element was a humerus (GLD S2.7b). This fragment of bone was amputated at both the distal and proximal ends, as can be seen in Figure 4.12.

The initial distal amputation had most likely become infected shortly after the procedure was done and accordingly, the amputation was extended proximally.

Figure 4.12 Humeral shaft with evidence for amputation on the proximal and distal ends. Signs of infection (arrow) can be seen on the distal end of the bone (GLD S2.7a).

4.4 Discussion

4.4.1 Evidence of interpersonal violence and strenuous activity among 19th century migrant labourers in Kimberley

As this sample population was comprised of individuals who most likely died at the surrounding hospitals in Kimberley, a high prevalence of skeletal pathology can be expected. Accordingly, the frequency of disease in this sample should be interpreted with caution, since it is not representative of the rest of the 'healthy' individuals from which the sample population was taken. Conversely, the assessment of healed trauma, such as the healed fractures observed in this study, can give a more accurate view into the lives of the people from which the sample came, since these lesions were not the reason for hospitalisation.

The frequency and variation in fracture type within a population can yield important information regarding lifestyle, interaction with the environment and the nature of medical attention that was available at the time (Steinbock, 1976; Kilgore *et al*., 1997). Parry fractures of the ulna, blunt trauma to the skull and evidence of cut marks by a sharp object are all indicative of interpersonal violence (Smith, 1996; Jurmain & Bellifemine, 1997; Kilgore *et al*., 1997; Lovell, 1997; Jurmain, 2001; Ortner, 2003; Judd, 2004). Femoral,

tibial and humeral fractures, on the other hand, are usually related to accidents such as falls (Kilgore *et al*., 1997).

The high prevalence of cranial fractures within this population (24%) (20 fractures observed in 84 skulls) is suggestive of interpersonal violence, as was also suggested in a sample from Chile where 24.6% (n=17) of individuals presented with cranial fractures (Standen & Arriaza, 2000). Most of the fractures observed on the cranial vaults were circular in shape, relatively similar in size and seemed to have been caused by a weapon such as a knobkerrie, although this cannot be stated with any certainty. A knobkerrie is a traditional South African club or stick shaped weapon with one rounded end. All cranial fractures were due to blunt-force trauma and several other weapons or even rocks can produce the same results (Jurmain & Bellifemine, 1997). Thus, although the lesions observed in this study had a preference toward the left side of the skull, suggesting possible right handed assault from the front, it should also be considered that the high prevalence of cranial fractures may be partly related to mining accidents such as rock falls, which were also recorded in archival documents. Therefore, these fractures cannot be exclusively attributed to interpersonal violence.

The prevalence of lesions suggesting interpersonal violence did however concur with the historical accounts of violence amongst the black labourers in Kimberley. The notion of violence as a symbol of masculinity and group affiliation was very strong in this population, leading to fights between various groups. These fights were a means by which leaders were selected and justice was served. An Anglican clergymen reported that ‘‘tribal fights and murders occurred every weekend’’ (Harries, 1994:58). According to records, weapons such as knobkerries, fighting sticks and pick handles were used (Harries, 1994).

Levels of interpersonal violence have been shown to increase when periods of environmental deterioration, sudden population growth and an increase in competition for resources are present within a population (e.g. Torres-Rouff & Costa Junqueira, 2006). The discovery of diamonds in Kimberley was a catalyst for the creation of these conditions. Numerous individuals went to Kimberley to seek their fortune, or employment, causing a dramatic growth in population numbers (Roberts, 1976; Harries, 1994). When considering that the study sample was most likely migrant labourers from various parts of the country, aggressive behaviour may also have been spurred by cultural differences (Harries, 1994). Furthermore, the increase in population numbers would inevitably have caused competition for resources, especially among the labourers of lower socioeconomic status. The high

prevalence of scurvy reported in archival documents for this population supports a state of limited fresh nutritional resources (Van der Merwe, 2007). Few women were present in Kimberley, as suggested by the few female skeletons excavated as well as the archival records. This fact may have increased the level of social conflict and competition. Other factors such as regular over-indulgence of liquor, labour disputes and skirmishes over the theft and illegal selling of diamonds may also have led to various violent confrontations between labourers and their employers or overseers (Turrell, 1987; Harries, 1994).

According to Lovell (1997), high fracture risks are associated with occupations generally restricted to men, such as agriculture, mining and forestry, while domestic activities in developing countries (such as carrying water and firewood) also pose a high risk of fractures to females. Mining accidents occurred frequently in Kimberley and included individuals falling down mine shafts, getting killed in rock falls, drowning in mud rushes and being run over with wagons, carts or trams, to name but a few (CGHVPP, 1901; Knight, 1978; Turrell, 1987; Harries, 1994). The prevalence of long bone fractures, spondylolysis, longstanding subluxations as well as some of the cranial fractures within the Gladstone population may therefore be a reflection of the high-risk environment to which these individuals were subjected to.

Separation of the neural arch or spondylolysis is a condition mostly recognised by the bilateral fracture of the pars articularis of vertebrae L4 or L5 (Merbs, 1989; Arriaza, 1997). Lane (1893) noted that spondylolysis is associated with strenuous physical activity and occurs frequently in individuals participating in heavy labour.

An investigation into the prevalence of this condition among 372 black South African skeletons from the Raymond Dart collection was conducted by Eisenstein (1978), who found that 3% of the sample population presented with spondylolysis (Eisenstein, 1978). Unfortunately, the exact number of individuals presenting with the condition, as observed by Eisenstein (1978), was not stated in the literature, making statistical comparison difficult. The observed prevalence of the condition in the Gladstone sample (8.5%) does, however, seem higher than what would be expected in the average South African black population.

Spondylolysis is caused by repetitive increased compression of the posterior elements of the vertebrae due to hyperextension of the back or increased shearing forces due to repeated flexion. During hyperextension of the back, the joints of adjacent vertebrae become locked together, causing an increase in stress exerted on the bone (Arriaza, 1997).

The reason for the high prevalence of spondylolysis in this population is clear: activities associated with mining will include a higher-than-average prevalence of hyperflexion and hyperextension of the back, which will inevitably increase the likelihood of spondylolysis in individuals who are genetically susceptible (Lovell, 1997; Earl, 2002). Therefore, the relatively high prevalence of spondylolysis within this sample is suggestive of participation in the continuous strenuous physical activities most likely associated with mining.

Thus, it can be concluded that the skeletal evidence concurs with the historical documents and that individuals within this sample were exposed to high levels of interpersonal violence, a hazardous working environment, as well as strenuous labour requirements.

4.4.2 Medical care in Kimberley at the close of the 19th century

The clear evidence of saw marks perpendicular to the long axis of the bone observed on the amputated limbs supports the assertions made in historical documents that the Gladstone cemetery was used as a burial ground by Kimberley and other surrounding hospitals. Several archival documentations of amputations are available from the Kimberley Hospital (CGHVPP, 1885). According to these records, up to 35 amputations were done annually, which amounted to approximately 50% of all operations performed in Kimberley Hospital (CGHVPP, 1885). The operations were most likely done under general anaesthesia. Anaesthesia with ether was first performed in Grahamstown (South Africa) in June 1847, and by the 1850s chloroform was being used (Laidler & Gelfand, 1971).

Unfortunately, no documentation suggesting the possible reasons for these amputations was available. However, two therapeutic reasons for the amputation of a limb can be suggested. First is amputation after injury, resulting from such severe crushing of the limb that it had no chance of healing. When considering the types of mine accidents mentioned earlier, crushing and compound fractures such as these may have been frequently encountered in Kimberley. The second reason for amputation is severe infection of a part of a limb. Evidence of infectious lesions found on amputated limbs (such as GLD N38.2, GLD N8.1b, GLD S2.7b and GLD S2.7c) suggests that some amputations were indeed the result of severe infections. This is plausible in light of the fact that antibiotics were not yet available for the treatment of infectious conditions (Quetel, 1990). Thus, the amputation of the infected body part was the only way to prevent spreading of the infection.

The presence of some well-healed and remodeled fractures within this population also indicates that medical care, although sometimes limited, was available to treat fractures. This has been confirmed historically, since hospital records refer to the treatment of injuries, which most likely would have included fractures (CGHVPP, 1899; 1901).

In summary, the high prevalence of cranial fractures within this population is suggestive of high levels of interpersonal violence (Jurmain & Bellifemine, 1997; Standen & Arriaza, 2000). Cultural differences among migrant workers, competition for resources, few females, regular overindulgence in alcohol and labour issues most likely all contributed to the occurrence of violent events within and among labourers and their employers (Harries, 1994; Turrell, 1987).

The prevalence of fractures of long bones and possibly some of the cranial fractures, as well as the presence of spondylolysis and longstanding subluxations, are indicative of the strenuous work and high-risk environment these individuals were exposed to. Medical treatment was available to these individuals, bearing in mind the presence of well-reduced fractures and evidence of amputation for medical purposes.

This study has provided a valuable glimpse into the working environment, social situation and medical facilities in Kimberley at the close of the 19th century. More than 14 million carats of diamonds was extracted from a hole measuring approximately 1200m wide and 800m deep, which used to be Colesberg Kopje. This research offers recognition to those unnamed labourers who unknowingly played a crucial role, not only in the history, but also in the economic growth of South Africa.

References

Arriaza, B.T. 1997. Spondylolysis in prehistoric human remains from Guam and its possible etiology. *American Journal of Physical Anthropology* 104:393–397.

Asala, S.A. 2001. Sex determination from the head of the femur of South African whites and blacks. *Forensic Science International* 117:15–22.

Auferheide, A.C. and Rodríguez-Martín, C. 1998. *The Cambridge Encyclopedia of Human Paleopathology*. Cambridge: Cambridge University Press.

Cape of Good Hope Votes and Proceedings of Parliament. 1885. *Hospitals and Asylums Report for the years 1884 G10* Appendix I.

Cape of Good Hope Votes and Proceedings of Parliament. 1899. *Hospitals and Asylums Report for 1898* Appendix I.

Cape of Good Hope Votes and Proceedings of Parliament. 1901. *Hospitals and Asylums Report for 1900* Appendix I.

De Villiers, H. 1968. Sexual dimorphism of the skull of the South African Bantu-speaking Negro. *South African Journal of Science* 84:118–124.

Earl, J.E. 2002. Mechanical aetiology, recognition, and treatment of spondylolithesis. *Physical Therapy in Sport* 3:79–87.

Eisenstein, S.M. 1978. Spondylolysis: a skeletal investigation of two population groups. *Journal of Bone and Joint Surgery* 60B:488–494.

Franklin, D., Freedman, L. and Milne, N. 2005. Sexual dimorphism and discriminant function sexing in indigenous South African crania. *Homo* 55:213–228.

Glencross, B. and Stuart-Macadam, P. 2000. Childhood trauma in the archaeological record. *International Journal of Osteoarchaeology* 10:198–209.

Grauer, A.L. and Roberts, C.A. 1996. Paleoepidemiology, healing, and possible treatment of trauma in the medieval cemetery population of St. Helen-on-the-walls, York, England. *American Journal of Physical Anthropology* 100:531–544.

Harries, P. 1994. *Work, culture and identity*: *Migrant laborers in Mozambique and South Africa, c 1860–1910.* Johannesburg: Witwatersrand University Press.

Hillson, S. 1998. *Dental Anthropology*. Cambridge: Cambridge University Press.

Jochelson, K. 2001. *The Colour of Diseases, Syphilis and Racism in South Africa 1880–1950*. New York: Palgrave.

Judd, M. 2004. Trauma in the city of Kerma: ancient versus modern injury patterns. *International Journal of Osteoarchaeology* 14:34–51.

Jurmain, R. 2001. Palaeoepidemiological patterns of trauma in a prehistoric population from Central California. *American Journal of Physical Anthropology* 115:13–23.

Jurmain, R. and Bellifemine, V.I. 1997. Patterns of cranial trauma in a prehistoric population from Central California. *International Journal of Osteoarchaeology* 7:43–50.

Kilgore, L., Jurmain, R. and Van Gerven, D. 1997. Palaeoepidemiological patterns of trauma in a medieval Nubian skeletal population. *International Journal of Osteoarchaeology* 7:103–114.

Knight, B.H. 1978. Injuries sustained in mining and quarrying. In: *The Pathology of Violent Injury*. Mason, J.K. (ed.). London: Edward and Arnold, pp.137 – 150..

Krogman, W.M. and Íşcan, M.Y. 1986. *The Human Skeleton in Forensic Medicine*, 2nd ed. Springfield: Charles C Thomas.

Laidler, P.W. and Gelfand, M. 1971. *South Africa: its medical history 1652–1898*. Cape Town: Struik.

Lane, A. 1893. Case of spondylolythesis associated with progressive paraplegia: laminectomy. *The Lancet* 1:991–992.

Larsen, C.S. 1997. *Bioarchaeology. Interpreting Behavior from the Human Skeleton*. Cambridge: Cambridge University Press.

Leary, J.G. 1891. Division of Kimberley. In *Blue Book on Native Affairs G4*. Cape of Good Hope. Ministerial Department of Native Affairs. Cape Town: WA Richards & Sons.

Lovell, N.C. 1997. Trauma analysis in paleopathology. *Yearbook of Physical Anthropology* 40:139–170.

Mann, R.W. and Murphy, S.P. 1990. *Regional Atlas of Bone Disease, A. Guide to Pathologic and Normal Variation in the Human Skeleton*. Springfield: Charles C Thomas.

McNish, J.T. 1970. *The Glittering Road*. Cape Town: Struik.

Merbs, C.F. 1989. Trauma. In: *Reconstruction of Life from the Human Skeleton*. Íşcan, M.Y. and Kennedy, K.A.R. (eds). New York: Alan R. Liss,, pp. 161-190.

Neri, R. and Lancellotti, L. 2004. Fractures of the lower limbs and their secondary skeletal adaptations: a 20th century example of pre-modern healing. *International Journal of Osteoarchaeology* 14:60–66.

Oettlé, C. and Steyn, M. 2000. Age estimation from sternal ends of ribs by phase analysis in South African blacks. *Journal of Forensic Sciences* 45:1071– 1079.

Ortner, D.J. 2003. *Identification of Pathological Conditions in Human Skeletal Remains*, 2 ed. Amsterdam: Academic Press.

Quetel, C. 1990. *History of Syphilis*. Maryland: Johns Hopkins University Press.

Roberts, B. 1976. *Kimberley Turbulent* City. Cape Town: Pioneer Press.

Roberts, C. and Manchester, K. 1995. *The Archaeology of Disease*, 2 ed. Stroud: Alan Sutton Publishing.

Smith, M.O. 1996. 'Parry' fractures and female-directed interpersonal violence: implications from the later archaic period of west Tennessee. *International Journal of Osteoarchaeology* 6:84–91.

Standen, V.G. and Arriaza, B.T. 2000. Trauma in the preceramic coastal population of Northern Chile: violence or occupational hazards? *American Journal of Physical Anthropology* 112:239–249.

Steinbock, R.T. 1976. *Paleopathological Diagnosis and Interpretation.* Springfield: Charles C. Thomas.

Stoney, W.W. 1900. Report of the Medical Officer of Health, Kimberley, for the year 1898. Unpublished report held in Kimberley Africana Library, Kimberley.

Swanepoel, S. 2003. Gladstone Cemetery, 1880s to 1900s. Unpublished archival report, McGregor Museum, Kimberley.

Torres-Rouff, C. and Costa Junqueira, M.A. 2006. Interpersonal violence in prehistoric San Pedro de Atacama, Chile: Behavioral implications of environmental stress. *American Journal of Physical Anthropology* 130:60–70.

Turrell, R.V. 1987. *Capital and Labour on the Kimberley Diamond Fields, 1871–1890.* Cambridge: Cambridge University Press.

Van der Merwe, A.E. 2007. Human Skeletal Remains from Kimberley: An Assessment of Health in a 19th Century Mining Community. Unpublished M.Sc. Thesis, University of Pretoria.

Walker, P.L. 2001. A bioarchaeological perspective on the history of violence. *Annual Review of Anthropology* 30:573–596.

CHAPTER 5

Adult Scurvy in Skeletal Remains of Late 19th Century Mineworkers from Kimberley, South Africa

Modified from article published as:

Adult scurvy in skeletal remains from late 19th century mineworkers from Kimberley, South Africa

A.E. Van der Merwe, M. Steyn, G.J.R. Maat

International Journal of Osteoarchaeology (2010)

20(3):307-316

Inside Wesselton Mine compound
(McGregor Museum Kimberley Photography nr.564)



Central Company Compound, Kimberley
(McGregor Museum Kimberley Photography nr.9426)

Abstract

Throughout history, scurvy has been a well-known disease that develops due to restrictions on fresh fruit and vegetable resources. The condition results from an extended limited intake of vitamin C. Although skeletal lesions associated with infantile scurvy have been well described by many authors, very little literature is available on adult scurvy and the resulting skeletal lesions. The purpose of this study was to investigate the skeletal remains of a 19th century mining population from Kimberley, South Africa, for any skeletal lesions that may be indicative of adult scurvy. Scurvy was well documented as being extremely prevalent in this population. The skeletal remains of 107 individuals, presumed to have died around 1898, were studied. The majority of these individuals were males between 20 and 49 years of age. It is likely that most individuals were migrant diamond mine workers. All bones were visually assessed for macroscopic indications of pathological bone alterations associated with healed scurvy. Bone samples were also taken from ambiguous lesions in order to perform histological investigations. Lesions indicative of possible healed adult scurvy were observed in 16 individuals. These lesions included bilateral ossified haematomas, widespread subperiosteal bone reactions and periodontal disease. Histological investigation confirmed the presence of ossified haematomas on the anterior tibiae of some individuals. Hospital records and historical documents describing the prevalence of scurvy in the local hospitals and the daily diet of the black mine workers supported these findings.

5.1 Introduction

Scurvy has been recognised as a serious disease in history, resulting in many deaths due to limited fresh vegetables and fruit during periods of poverty, war, famine or long journeys (Steinbock, 1976; Reuler *et al.*, 1985; Pangan & Robinson, 2001; Maat, 2002; De Luna *et al.*, 2003; Ortner, 2003; Fain, 2005). The condition results from an extended limited intake of vitamin C, also known as ascorbic acid. Ascorbic acid is responsible for the hydroxylation of lysine and proline in the body and is therefore an essential element during the synthesis of polypeptide precursors for the formation of collagen fibrils. A deficiency in vitamin C causes collagen abnormalities (Steinbock, 1976; Stuart-Macadam, 1989; Ortner & Ericksen, 1997; Pangan & Robinson, 2001; Ortner, 2003; Fain, 2005; Brickley & Ives, 2006). Accordingly, clinical abnormalities include abnormal dentine production, weakening of the blood vessel walls and a tendency to develop haemorrhage, oedema, purpura, tooth loss, bone changes and keratin abnormalities (Pangan & Robinson, 2001; De Luna *et al.*, 2003; Ortner, 2003; Fain, 2005).

Vitamin C cannot be produced in the human body and therefore, the regular intake of this vitamin is essential (Stuart-Macadam, 1989; Fain, 2005; Brickley & Ives, 2006). At least 10mg of vitamin C should be consumed every day in order to prevent deficiency (Reuler *et al.*, 1985; Pangan & Robinson, 2001; Fain, 2005). The best natural sources of vitamin C are citrus fruits and uncooked green vegetables. Large amounts of potatoes and meat, such as liver and kidney, can also provide sufficient levels of ascorbic acid (Steinbock, 1976; Roberts & Manchester, 1995; De Luna *et al.*, 2003; Fain, 2005; Brickley & Ives, 2006).

Pathological changes associated with scurvy have been well described in the clinical literature. Apart from gingival hypertrophy and bleeding, petechiae (pinpoint bleeding of the skin) and follicular hyperkeratosis, haematoma formation and subperiosteal swellings in the lower extremities have been reported (Petit, 1741; Hamilton & Dyke, 1918; Hirschmann & Raugi, 1999; Fain, 2005). Haematoma formation on the tibiae in particular was noted by Aschoff and Koch (1919), who examined and dissected 23 soldiers who suffered from scurvy. Although skeletal lesions associated with infantile scurvy have been well described by many authors such as Stuart-Macadam (1989), Ortner and Ericksen

(1997) and Brickley and Ives (2006), very little literature is available on adult scurvy and the resulting skeletal lesions (Van der Merwe, 2007).

A study conducted by Maat (1984) provided some insight into the development, and specifically the distribution, of lesions in adult scurvy. In this study the remains of 50 Dutch whalers were investigated (Maat, 1984; Maat & Uytterschaut, 1987; Maat, 2004). Historical records indicated that scurvy had been a major problem among the men who participated in the whaling expeditions and lesions suggestive of scurvy were found in 39 of the 50 individuals (Maat, 1984). These lesions included signs of subperiosteal haematomas, haemarthroses and periodontal bleeding (Maat, 1984; Maat, 2004). It was found that subperiosteal haematomas often affected the diaphyses of the tibiae and fibulae and that these lesions were usually bilateral (Maat, 1984). However, in cases where haematomas were observed on the upper extremities, lesions were frequently unilateral. It should be mentioned that the individuals investigated in this study were extremely well preserved and diagnosis was made mainly on the basis of visible soft tissue remnants of haemorrhage.

However, this study, gave important insights into the distribution of lesions that can be associated with adult scurvy. Unfortunately, only one individual in this sample presented with bony lesions associated with healed vitamin C deficiency. This is understandable when considering that the whalers died in a scorbutic state and skeletal lesions associated with scurvy would only develop once normal vitamin C levels had been restored (Murray & Kodicek, 1949).

The purpose of this study was to investigate the skeletal remains of a 19th century mining population from Kimberley, South Africa, for lesions indicative of scurvy. Scurvy was well documented in historical records describing the study population. The condition was extremely prevalent and resulted in numerous deaths among the migrant labourers working in Kimberley (Medical Officer of Health, 1900).

5.2 Materials and Methods

In April 2003, the Sol Plaatjie Municipality (Kimberley) unknowingly disturbed several unmarked graves outside the fenced Gladstone Cemetery while digging a proposed storm-water trench. The McGregor Museum in Kimberley became involved through the

South African Heritage Resources Agency (SAHRA), and was requested to exhume and investigate the graves. After the excavation, all skeletal material and artefacts, were taken to the McGregor museum, tagged, and kept for further analysis.

It is likely that most individuals within this population were migrant workers, as was suggested by historical reports. Native individuals in search of work flooded into Kimberley during the late 19th Century after diamonds had been discovered in the area (Leary, 1891; Stoney, 1900; McNish, 1970; Roberts, 1976; Jochelson, 2001). Men left their families at home (whether in another town or another country) and came to Kimberley in the hope of finding fortune or maybe merely an extra income to sustain their families (McNish, 1970). When they became ill these individuals were treated in the Kimberley and compound hospitals (Van der Merwe, 2007). Various diseases such as tuberculosis, treponematosis, scurvy and cases of violent injury, to name but a few, were described in historical documents from these hospitals. In the case of death, the patients received a pauper's burial, as no direct family could be contacted. It should be noted that Kimberley was a rapidly growing city with limited resources. It was the first city in South Africa to develop away from a natural water source, and this, in conjunction with the extremely dry climate, had severe consequences on the availability of fresh fruit and vegetables (Roberts, 1976).

Standard anthropometric techniques such as cranial morphology, the width of the pubic angle, morphological changes of the sternal ends of the ribs and discriminant functions were used to determine the age and sex of all individuals exhumed from the trench (e.g. De Villiers, 1968; Krogman & Íşcan, 1986; Hillson, 1998; Oettlé & Steyn, 2000; Asala, 2001; Franklin *et al.*, 2005). A total of 107 skeletons were excavated, including 86 males, 15 females and 6 individuals of unknown sex. The majority of individuals excavated from the trench were young and middle-aged adults, as can be seen in Table 5.1. One premature baby, two infants (both younger than one year of age) and 13 juveniles between 11 and 19 years were the only non-adults in the sample. The highest number of individuals was observed to be between 20 and 34 years of age (n = 52). Twenty-five individuals were estimated to have been 35–49 years of age and only four were determined to have been older than 50 years of age at the time of death. Due to the fragmentary condition of some of the remains, eight individuals could only be described as

being adult and two were of unknown age (see Table 5.1). The majority of the skeletons demonstrated excellent preservation.

All bones were visually assessed for any macroscopic indication of pathological alterations, especially those associated with scurvy. Attention was given to signs of ossified haematomas (characterised by localised, well-demarcated lesions of bone apposition) (see Figure 5.1), periodontal disease (see Figure 5.2) and general widespread

Table 5.1 Age and sex distribution of individuals excavated next to the fenced Gladstone cemetery.

	J	YA	MA	OA	A	U	Total	%
Age in years	0-19	20-34	35-49	>50	>20			
Male	10	46	21	2	7	0	86	80.4
Female	3	6	4	2	0	0	15	14.0
U	3	0	0	0	1	2	6	5.6
Total	16	52	25	4	8	2	107	
%	14.9	48.6	23.4	3.7	7.5	1.9		

J=Juveniles, YA=Young adult, MA=Middle adult, OA=Old adult, A=Adult, U=Unknown

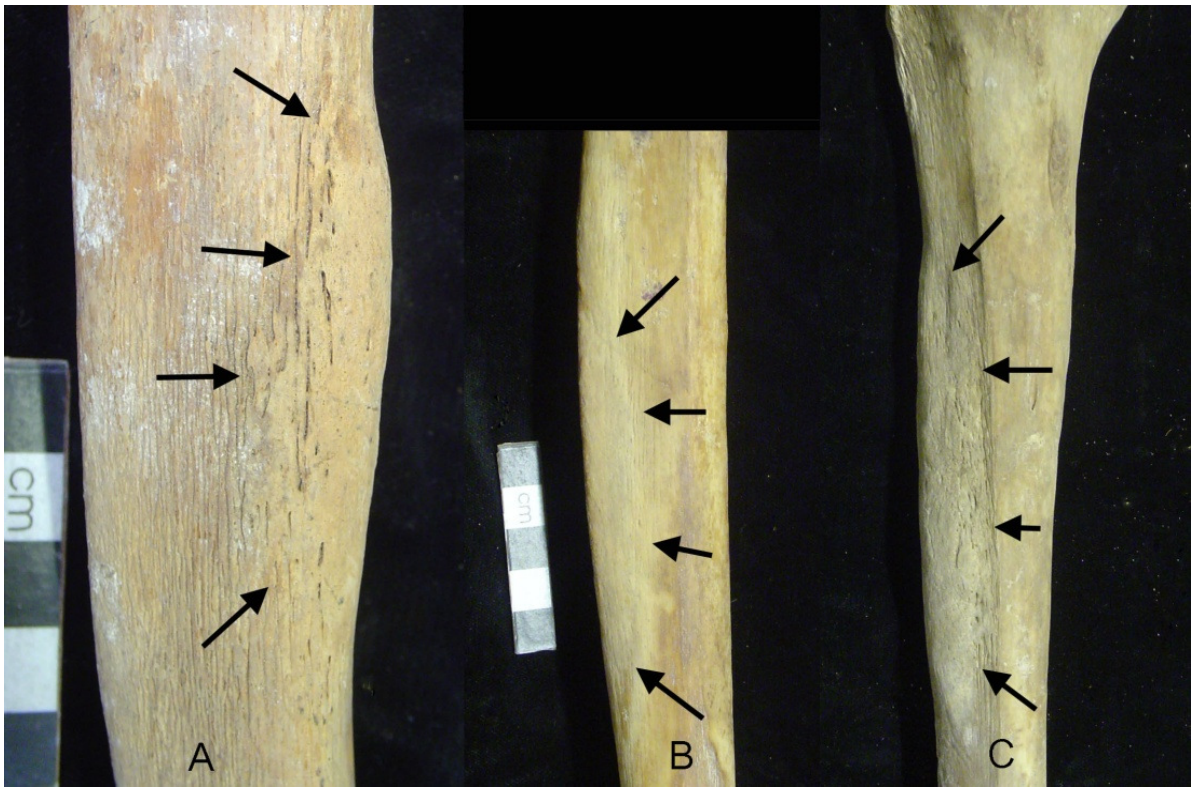

Figure 5.1 Clearly demarcated lesions of new bone apposition (as indicated by arrows) on anterior tibiae of three individuals as a possible result of scurvy (A: GLD SE7.5, B: GLD N38.5, C: GLD N74.9).

bilateral subperiosteal bone apposition (see Figure 5.3). Diagnoses of possible scurvy were made based on the bony characteristics of the defects as well as on the distribution of the lesions across the skeleton. All lesions were compared to standard palaeopathological texts and photographs as can be found in Steinbock (1976), Maat (1984; 2004), Roberts and Manchester (1995), Mann and Murphy (1990), Larsen (1997), Aufderheide and Rodríguez-Martín (1998) and Ortner (2003).

Because other diseases such as treponemal infections were also present in this sample population, bone samples were taken from ambiguous lesions in order to perform histological investigation to increase the accuracy of diagnoses (Van der Merwe *et al.*, 2010).

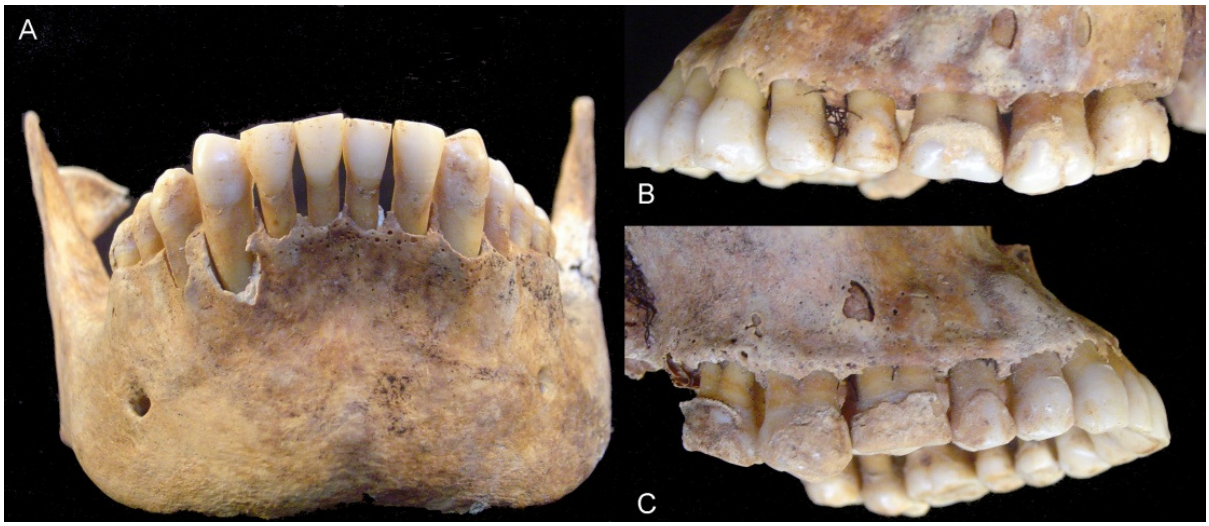

Figure 5.2 Widespread periodontal disease can be seen as observed in individual GLD S2.4, who was suggested to have suffered from scurvy. A) mandibular teeth, B) left maxilla, C) right maxilla.

5.3 Results

Possible scurvy was diagnosed in 16 individuals (14.9%), comprising 13 males (15.1%) and three females (20%) (see Table 5.2). There was no significant difference in the prevalence of scurvy between males and females ($\chi^2 = 0.22$, p-value > 0.2).

All individuals presenting with lesions were younger than 45 years of age, including one juvenile, seven young adults and eight middle aged adults. No significant differences were observed in the distribution of healed scurvy lesions between the various age groups. Scurvy was identified by the presence of mostly bilateral ossified haematomas on the tibiae (see Figure 5.1), widespead subperiosteal bone growth (most likely also associated with

slight subperiosteal bleeding) (see Figure 5.3) and periodontal disease. Although all the abovementioned pathological lesions can be indicative of other diseases when viewed separately, the combination of these lesions in one individual was interpreted as possible scurvy. A summary of the lesions observed in each individual can be seen in Table 5.2.

For example, individual GLD N31.E.1 presented with bilateral striations and patches of porous new bone formation on the anterior tibiae. Indications of periodontal disease were also observed on the maxilla and mandible. These lesions, in the absence of any signs of trauma and in conjunction with the historical records, suggested that scurvy may be a plausible explanation.

The same pattern of striated bone surfaces with widespread lesions of subperiosteal bone apposition in association with periodontal disease was noted in individuals GLD S2.1, GLD S2.9 and GLD N31.E.4. In individuals GLD S2.1 and GLD N31.E.4, subperiosteal lesions were only present on the left tibia.

Possible lesions suggestive of ossified haematomas were noted in 11 individuals (Table 5.2). The lesions were localised with clear borders, separating them from the original underlying bone (see Figures 5.1 and 5.4). All affected individuals had widespread periosteal lesions indicative of slight subperiosteal bleeding. Apart from the ossified haematomas and periosteal lesions on the tibiae, skeletons GLD SE7.6, GLD SE7.5 and GLD SE7.9 also presented with indications of periodontal disease.

Samples taken from lesions suggestive of ossified haematomas presented with an undisturbed original periosteal surface (distinctly visible on cross section) and appositional bone on top of the original periosteal surface (see Figure 5.5a). Histological investigations showed cortical bone unaffected by pathology with uninterrupted subperiosteal circumferential lamellae, indicating the level of the original periosteal surface and appostional bone (radiating outwards) on top of it (see Figure 5.5b) (Van der Merwe *et al.*, 2010). It was clear from these histological sections that the lesions were the result of ossified haematomas and not of an infective condition, since the original underlying periosteal surface of the cortical bone was not affected. In addition, no lytic changes or unstructured bone replacements, characteristic of infectious inflammation, were noted.

Table 5.2 Prevalence of skeletal lesions in individuals with possible scurvy in the Gladstone population

Case no	Sex	Age	Widespread subperiosteal bone deposition and striations	Ossified haematomas	Periodontal disease
GLDN31.E.1	M	MA	P (bilaterally on tibiae)	A	P
GLD N74.8	M	J	P (L tibia)	A	A
GLD N74.9	M	YA	P (bilaterally on tibiae)	P (ant. tibiae)	A
GLDN31.E.4	M	MA	P (ant. L femur & tibia)	A	P
GLD N34.13	M	YA	P (bilaterally on tibiae)	P (ant. R tibia)	A
GLD N38.5	M	YA	P (L tibia)	P (ant. L tibia)	A
GLD N8.5	M	YA	P (bilaterally on tibiae & R ulna)	P (ant. tibiae)	A
GLD N8.10	M	YA	P (bilaterally on femora, tibiae & fibulae)	P (ant. tibiae)	A
GLD S2.1	M	MA	P (L tibia)	A	P
GLD S2.9	M	MA	P (bilaterally on tibiae)	A	P
GLD SE7.3	M	YA	P (bilaterally on tibiae)	P (ant. tibiae)	A
GLD SE7.6	M	YA	P (bilaterally on tibiae, fibula & R femur)	P (ant. tibiae)	P
GLD SE7.9	M	MA	P(bilaterally on tibiae)	P (ant. tibiae)	P
GLD SE7.4	F	MA	P (bilaterally on tibiae)	P (R tibia & R femur)	A
GLD SE7.5	F	MA	P (bilaterally on tibiae)	P (ant. tibiae)	P
GLD S2.4	F	MA	P (bilaterally on tibiae)	P (ant. tibiae)	A
Total			16	11	7

M = male, F = female, J = Juvenile (0 – 19 years), YA=Young adult (20 – 34 years), MA = Middle adult (35 – 49 years), A = absent, P = present, ant. = anterior, R = right, L = left

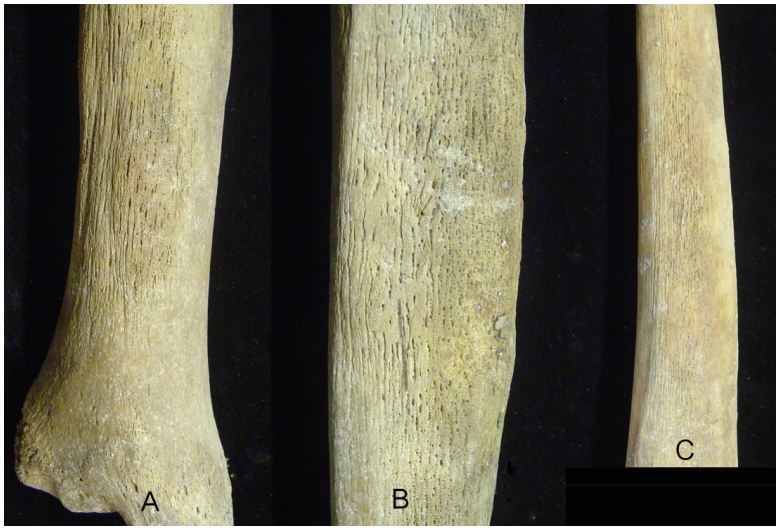

Figure 5.3 Striations and widespread subperiosteal bone deposition observed on tibiae of individuals possibly suffering from scurvy (A: GLD N8.10, B: GLD N8.10, C: GLD N8.5).

The ossified haematomas were bilateral in eight of the 11 cases presenting with these lesions (72.7%). Two individuals (20%) presented with lesions only on the right tibia and one individual (10%) had a haematoma affecting the left tibia only.

Figure 5.4 Ossified haematoma (a) with closer view of lesion as indicated by black arrow (b). White arrow indicates signs of subperiosteal bone apposition. Lesion most likely developed as result of healed scurvy in a male, 25-30 years of age (GLD SE7.6).

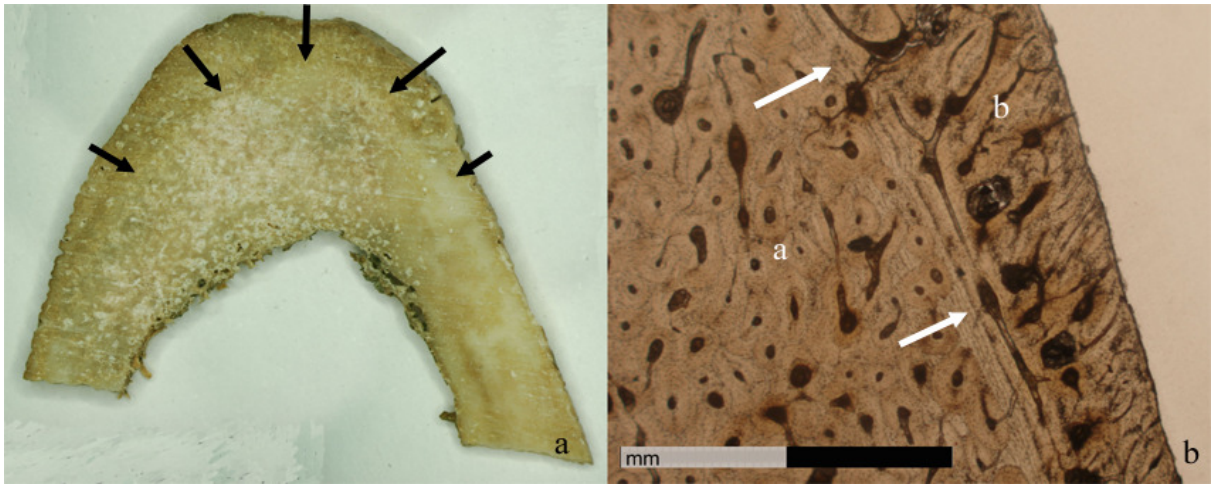

Figure 5.5 (a.) Cross section through an ossified haematoma most likely resulting from scurvy. The original periosteal surface (indicated by arrows) can be easily visualized. (b.) Histological features supporting that the observed lesions were ossified haematomas: unaffected original bone (a), original circumferential lamellae (arrows) and appositional bone (b) are clearly discernible.

5.4 Discussion

The documentation of adult scurvy is rarely seen in the description of the health status of archaeological populations. This is most likely due to the ambiguous lesions caused by this condition. Haematomas on the diaphyses of bone can also be caused by or easily mistaken for trauma, treponemal infection, non-specific osteomyelitis or an osteoblastoma, while joints with haemarthroses can be washed clean by rain and ground water movement.

It is widely known that persons suffering from vitamin C deficiency have a tendency to bleed due to defective collagen in bone and vascular walls (Barlow, 1883; Lind, 1953; Jaffe 1972). Any mechanical or physical strain on a defective blood vessel could result in haemorrhage. In a study conducted on the Johannesburg Bantu in 1962, Seftel *et al.* (1966) noted that individuals suffering from scurvy often presented with haemorrhagic swellings of the gums as well as bleeding into the muscle of the calf or posterior thigh. Steinbock (1976) and others (van Wersch, 1954; Maat, 2004) also state that pathological features are common along the adult diaphyses, rather than in the metaphyses as seen in infantile scurvy. It can also be expected that skeletal sites that receive regular minor trauma, such as the shin, will be more prone to the development of haematomas due to the increased susceptibility of the scorbutic individual to haemorrhage (Stuart-Macadam, 1989). Although very little literature is available on the presence of haematoma formation on the surface of the anterior tibia in adults due to scurvy (e.g. Aschoff & Koch, 1919; Van Wersch, 1954), it is proposed that the skeletal lesions of ossified haematomas observed in

the Gladstone remains most probably developed due to vitamin C deficiency. It is possible, however, that these lesions could have been exacerbated by trauma to the shins of these individuals.

The prevalence of scurvy within the Gladstone population (14.9%) correlates well with the documented prevalence of this disease among black individuals being treated at the Kimberley Hospital. In 1897, 311 patients (16.7% of all admissions) were being treated for scurvy. According to the report, this could have been prevented if ''employers [were] properly feeding their men'' (CGHVPP, 1899). It was also stated that due to the neglect by the employers, it became the hospital's responsibility to cure the malnourished 'Natives' employed in the mines. During the last six weeks of 1899, up to 292 patients (17.8% of all admissions) were being treated for scurvy, of which 52 died (Medical Officer of Health, 1900).

A high prevalence of scurvy can be expected in groups following a diet consisting mainly of maize meal and occasional coarse meat, which was the only food supplied by the employers and compounds. There were even times when no food was being supplied to compound workers and they were responsible for buying and preparing their own meals (Harries, 1994). Therefore, these diets were normally high in carbohydrates, low in animal proteins and low in fresh fruit and vegetables (Grusin & Samuel, 1957; Seftel *et al.*, 1966). When considering the lack of fresh fruit and vegetables, Kimberley's climate should be kept in mind. Nineteenth century Kimberley, as is still the case, was very hot and dry, plagued by fires and brutal dust storms (McNish, 1970; Roberts, 1976). Accordingly, naturally growing fruit and vegetables were scarce and agricultural enterprises difficult.

Another possible explanation for the high prevalence of scorbutic individuals found in this population can be the regular consumption of homemade traditional beer and alcohol (McNish, 1970). The regular consumption of beer stored in iron and/or tin cans may cause the consumer to develop siderosis which, through the oxidation of serum vitamin C, may lead to the development of scurvy (Seftel *et al.*, 1966). Historical documents indicate that alcoholic beverages were consumed in large quantities by the labourers in Kimberley (Harries, 1994). Sorghum beer was also prepared in large quantities and together with European liquors, became the ''cultural markers, binding black workers together'' (McNish, 1970; Harries, 1994:58). This habit of overindulging, which mainly occurred on weekends, resulted in a ''large absentee rate on Mondays, when as many as 50% of the men failed to report for work'' (Harries, 1994:58).

Healed scurvy was diagnosed in the Kimberley population sample based on the presence of periodontal disease, ossified haematomas (especially on the anterior tibiae) and widespread patches of subperiosteal bone deposition. It is important to consider that although gingivitis is one of the characteristic clinical symptoms of scurvy, it is very inconsistent (Fain, 2005). It has been suggested that hypertrophy and bleeding of the gingivae mostly occurs in patients with teeth, and that the inflammation is more severe in those with poor dental hygiene (Fain, 2005). Thus, although scurvy and the resulting gingivitis can be responsible for the bone changes indicative of periodontal disease observed in the investigated skeletal remains, it should also be considered that several other factors influence the development of periodontal disease, including the age of the individual, the presence of plaque micro-organisms, hereditary factors, the availability of dental care and the plaque-encouraging characteristics of the person's daily diet (Hillson, 1998). Thus, although the presence of periodontal disease in association with the widespread subperiosteal bone apposition and localised ossified haematomas support the possibility of scurvy, the absence of periodontal disease, or its presence without the associated skeletal lesions, is most likely not indicative of the condition.

The differential diagnosis for lesions observed on the anterior tibiae in this sample population includes trauma resulting in heamatoma formation and later ossification thereof, saber shin tibiae as a result of treponematosis, non-specific osteomyelitis and possible osteoblastomas. In order to exclude the possibility that these lesions may be the result of treponematosis, non-specific osteomyelitis or osteoblastomas, histological investigations were also carried out on the majority of the lesions (Van der Merwe *et al.*, 2010).

Histological investigations confirmed the presence of ossified haematomas and showed that the appositional bone did not develop due to infective bone changes. The appositional bone also did not have the dense woven bone trabecular structure as would be expected for an osteoblastoma (Vigorita, 1999; Ortner, 2003). All histological sections were characterised by a clearly visible original periosteal surface (distinctly visible on cross-section) and appositional bone on top of the original periosteal surface. The cortical bone was unaffected by pathology, with circumferential lamellae indicating the level of the original periosteal surface and appositional bone (radiating outwards) on top of the external circumferential lamellae (Van der Merwe *et al.,* 2010). Accordingly, it was confirmed by the histological sections that these lesions were indeed the result of ossified haematomas.

Trauma must be considered in the differential diagnosis for the ossified haematomas on the anterior tibiae. Considering that these individuals were most probably all working in the mines and many consumed large amounts of alcohol, accidents and skirmishes would have often occurred. It is also well known that ossified haematomas, as a result of scurvy, will only develop once the patient has recovered from the scorbutic state (Murray & Kodicek, 1949). Therefore, it can be argued that the individuals in the Kimberley sample population had to have sufficient amounts of vitamin C in their diet at certain times, otherwise ossification of the haematomas would not have occurred. Several episodes of vitamin C deficiency, probably alternated with treatment in the local hospitals or return of migrant labourers to a more variable diet when they returned home, as well as repeated minor or more major traumatic incidents to the anterior tibiae; all most likely contributed to the patterns of pathological changes seen in this population. The distribution of the lesions supports scurvy as a more likely cause of the haematomas when compared to trauma since lesions were most often symmetrical, affecting both the left and right anterior tibiae, whereas in the cases where the upper limbs were also affected it was usually only unilaterally. This distribution of lesions is very similar to the distribution of lesions described by Maat (2004) in the whalers and can most likely be associated with the strain on these bones due to weight bearing. It would be expected that haematomas as a result of trauma, whether accidental or violent, would be more widespread, much less symmetrical and there would be less similarities in the distribution of the lesions among those exhibiting them.

Therefore, it can be concluded that lesions suggestive of adult healed scurvy were observed in 16 individuals from the Gladstone skeletal sample. These lesions included ossified haematomas (often bilateral), widespread subperiosteal bone apposition and periodontal disease. Histological investigations confirmed the nature of the ossified haematomas in those that were sampled and investigated microscopically (Van der Merwe *et al.,* 2010). Hospital records and historical documents describing the prevalence of scurvy in the Kimberley and Compound Hospitals and the daily diet of the black mine workers supported these findings. Therefore, this study provides one of the few descriptions of skeletal lesions caused by scurvy in adult individuals. Histological analysis of possible ossified haematomas helped to confirm the diagnoses, and should be included in such an investigation whenever possible.

References

Asala, S.A. 2001. Sex determination from the head of the femur of South African whites and blacks. *Forensic Science International* 117: 5–22.

Aschoff, L. and Koch, W. 1919. Skorbut, eine pathologischanatomische studie. Gustav Fisher Verlag: Jena.

Aufderheide, A.C. and Rodríguez-Martín, C. 1998. *The Cambridge Encyclopedia of human paleopathology*. Cambridge: Cambridge University Press.

Barlow, T. 1883. On cases described as 'acute rickets' which are probably a combination of scurvy and rickets, the scurvy being essential, and the rickets a variable, element. *Medico-Chirurgical Transactions* 66:159–219.

Brickley, M. and Ives, R. 2006. Skeletal manifestations of infantile scurvy. *American Journal of Physical Anthropology* 120:163–172.

Cape of Good Hope Votes and Proceedings of Parliament. 1899. Hospitals and Asylums Report for 1898 Appendix I.

De Luna, R.H., Judson Colley, B., Smith, K., Divers, S.G., Rinehart, J. and Marques, M.B. 2003. Scurvy: an often forgotten cause of bleeding. *American Journal of Hematology* 73:85–8587.

De Villiers, H. 1968. Sexual dimorphism of the skull of the South African Bantu-speaking Negro. *South African Journal of Science* 84:118–124.

Fain, O. 2005. Musculoskeletal manifestations of scurvy. *Joint Bone Spine* 72:124–128.

Franklin, D., Freedman, L. and Milne, N. 2005. Sexual dimorphism and discriminant function sexing in indigenous South African crania. *Homo* 55: 213–228.

Grusin, H. and Samuel, E. 1957. A syndrome of osteoporosis in Africans and its relationship to scurvy. *Journal of Clinical Nutrition* 5:644–650.

Hamilton, W. and Dyke, M.B. 1918. Outbreak of scurvy in the South African native labour corps. *Lancet* Oct: 513–515.

Harries, P. 1994. *Work, Culture and Identity. Migrant Laborers in Mozambique and South Africa, c 1860–1910*. Johannesburg: Witwatersrand University Press.

Hillson, S. 1998. *Dental Anthropology*. Cambridge: Cambridge University Press.

Hirschmann, J.V. and Raugi, G.J. 1999. Adult scurvy. *Journal of the American Academy of Dermatology* 41:895–906.

Jaffe, H.L. 1972. *Metabolic, Degenerative and Inflammatory Diseases of Bones and Joints*. Philadelphia: Lea and Febiger.

Jochelson, K. 2001. *The Colour of Diseases, Syphilis and Racism in South Africa 1880–1950*. New York: Palgrave.

Krogman, W.M. and İşcan, M.Y. 1986. *The Human Skeleton in Forensic Medicine*, 2nd ed. Springfield: Charles C Thomas.

Larsen, C.S. 1997. *Bioarchaeology. Interpreting Behavior from the Human Skeleton*. Cambridge: Cambridge University Press.

Leary, J.G. 1891. Divisions of Kimberley. In: *Blue Book on Native Affairs G4*. Cape of Good Hope. Ministerial Department of Native Affairs. Cape Town: WA Richards & Sons.

Lind, J. 1953. *Lind's Treatise on Scurvy.* Stewart CP, Guthrie D (eds). Edinburgh: University Press.

Maat, G.J.R. 1984. Scurvy in Dutch whalers buried at Spitsbergen. In: *Proceedings of the Palaeopathology Association 4th European Meeting*, Haneveld GT, Perizonius WRK, Janssens PJ (eds). Paleopathology Association, Utrecht; pp. 140–148.

Maat, G.J.R. 2002. History and pathology of a disregarded disease. *Histopathology* 41: 460–462.

Maat, G.J.R. 2004. Scurvy in adults and youngsters: The Dutch experience. A review of the history and pathology of a disregarded disease. *International Journal of Osteoarchaeology* 14: 77–81.

Maat, G.J.R. and Uytterschaut, H.T. 1987. Microscopic observations on scurvy in Dutch whalers buried at Spitsbergen. In: *Proceedings of the Palaeopathology Association 5th European Meeting*. Capecchi V, Rabino Massa E (eds). Paleopathology Association, Sienna; pp. 211–218.

Mann, R.W. and Murphy, S.P. 1990. *Regional Atlas of Bone Disease: A guide to Pathologic and Normal Variation in the Human Skeleton*. Springfield: Charles C Thomas.

McNish, J.T. 1970. *The Glittering Road*. Cape Town: C. Struik.

Medical Officer of Health. 1900. *Medical Officer of Health reports for 1899 and 1900*. Unpublished report held in Kimberley Africana Library, Kimberley.

Murray, P.D.F. and Kodicek, E. 1949. Bones, muscles and vitamin C. III. Repair of the effect of total deprivation of Vitamin C at the proximal ends of the tibia and fibula in guinea-pigs. *Journal of Anatomy* 83:285–295.

Oettlé, C. and Steyn, M. 2000. Age estimation from sternal ends of ribs by phase analysis in South African blacks. *Journal of Forensic Sciences* 45:1071–1079.

Ortner, D.J. 2003. *Identification of Pathological Conditions in Human Skeletal Remains*, 2 ed. Amsterdam: Academic Press.

Ortner, D.J. and Ericksen, M.F. 1997. Bone changes in the human skull probably resulting from scurvy in infancy and childhood. *International Journal of Osteoarchaeology* 7:212–220.

Pangan, A.L. and Robinson, D. 2001. Hemarthrosis as initial presentation of scurvy. *Journal of Rheumatology* 23:1923–1925.

Petit, J.L. 1741. Traite des maladies os I, II. Paris.

Reuler JB, Broudy V, Cooney T. 1985. Adult scurvy. *Journal of the American Medical Association* 253:805–807.

Roberts, B. 1976. *Kimberley Tubulent City*. Cape Town: Pioneer Press

Roberts, C. and Manchester, K. 1995. The Archaeology of Disease, 2 ed. Stroud: Alan Sutton Publishing.

Seftel, H.C., Malkin, C., Schmaman, A., Abrahams, C., Lynch, S.R., Charlton, R.W. and Bothwell, T.H. 1966. Osteoporosis, scurvy and siderosis in Johannesburg Bantu. *British Medical Journal* 1:642–646.

Steinbock, R.T. 1976. *Paleopathological Diagnosis and Interpretation*. Springfield: Charles C. Thomas.

Stoney, W.W. 1900. *Report of the Medical Officer of Health, Kimberley, for the years 1898*. Unpublished report held in Kimberley Africana Library, Kimberley.

Stuart-Macadam, P. 1989. Nutritional deficiency diseases: a survey of scurvy, rickets and iron deficiency anemia. In: *Reconstruction of Life from the Skeleton.*, Íşcan, M.Y. and Kennedy, K.A.R. (eds). New York: Alan R. Liss.

Van der Merwe, A.E. 2007. *Human skeletal remains from Kimberley: an assessment of health in a 19th century mining community*. Unpublished MSc. thesis, University of Pretoria.

Van der Merwe, A.E., Maat, G.J.R. and Steyn, M. 2010. Ossified haematomas and infectious bone changes on the anterior tibia: histomorphological features as an aid for accurate diagnosis. *International Journal of Osteoarchaeology*. 20(2):227-239.

Van Wersch H.J. 1954. *Scurvy as a Skeletal Disease. A Comparative Study of Scurvy and Rickets, Clinically, Histologically, Histochemically, Biochemically and Roetgenologically.* Utrecht: Dekker & van de Vegt

Vigorita, V.J. 1999. *Orthopaedic Pathology*. Philadelphia: Lippincott Williams & Wilkins

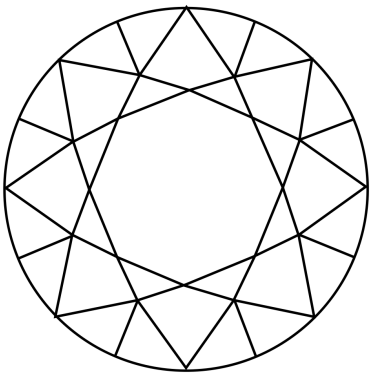

CHAPTER 6

Ossified Haematomas and Infectious Bone Changes on the Anterior Tibia: Histomorphological Features as an Aid for Accurate Diagnosis

Modified from article published as:

Ossified haematomas and infectious bone changes on the anterior tibia: histomorphological features as an aid for accurate diagnosis

A.E. Van der Merwe, G.J.R. Maat, M. Steyn

International Journal of Osteoarchaeology (2010)

20(2):227-239



Kimberley Town Hall, 1902
(McGregor Museum Kimberley Photography nr.5305)



Bultfontein Compound, 1900s
(McGregor Museum Kimberley Photography nr.5341)

Abstract

Examination of the histological structure of bone not only helps investigators to estimate age at death, but can also aid in the diagnosis of palaeopathological lesions. The purpose of this paper is to assess whether histological features, as described in the literature, can confirm the macroscopic diagnoses of ossified subperiosteal haematomas, associated with healed scurvy, and syphilitic bone changes observed on the anterior tibiae of individuals from a 19th century mining community from Kimberley, South Africa.

The frequent occurrence of these two diseases amongst the deceased was well established in related hospital and governmental documents. A section of bone was removed from lesions on the tibiae of 14 individuals. These bone changes were macroscopically diagnosed as being indicative of either treponematosis, ossified subperiosteal haematomas, or non-specific periostitis. Cross-sections were prepared for microscopic investigation, using a manual ground section technique.

Ossified haematomas were histologically identified in seven individuals. These sections were characterised by normal cortical bone, an intact original periosteal surface, and newly formed, radiating trabecular bone apposing it. Three phases of ossified subperiosteal haematoma formation and remodelling could be distinguished. Infectious bone changes, most likely associated with treponematosis, were observed in one individual. These were histologically characterised by lysis and numerous resorption holes/channels. No clear distinction could be made between the internal spongy, cortical or newly formed bone. Histological features described by some authors as characteristic of this condition could not be identified. In addition, three individuals presented with microscopic features indicative of both the aforementioned bone affections, and three did not show any pathological changes on microscopic level.

It was concluded that although specific pathological conditions can most likely not be diagnosed purely on the basis of histomorphological observations, broad distinctions could be made between lesions caused by the ossification of subperiosteal haematomas and bone changes due to infectious diseases.

6.1 Introduction

Examination of the histological structure of archaeological bone not only helps investigators to estimate the age at death of individuals, informs them whether the bone is human or not, and gives information regarding the preservation of the bone, but can also aid in the accurate diagnosis of pathology (Martin & Armelagos, 1979; Garland, 1993; Herrmann, 1993; Schultz, 2001; Maat, 2004). Reliable diagnosis of pathological bone lesions is the basis for the reconstruction of diseases in past populations. Macroscopic investigations, conventional X-rays and CT scans are techniques available to study pathological lesions present in bone, but false diagnoses are still common due to the absence of soft tissue evidence and similarities in the formation of bone lesions in different diseases (Ortner & Putschar, 1981; Mann & Murphy, 1990; Schultz, 2001). Therefore, it is important that different techniques, microscopic methods in particular, should be developed and refined in order to increase the accuracy with which the diagnosis of pathological lesions can be made.

For the purposes of this study, microscopic features of proliferative reactions on long bones will be reviewed briefly, in particular lesions on the tibiae caused by healed scurvy and treponemal infection. Numerous diseases can be responsible for bone formation on the surface of long bones, such as non-specific periostitis, non-specific osteomyelitis, treponemal disease, leprosy, healed scurvy and mechanical trauma, to name a few. Two lines of bone behaviour can be recognised during microscopic investigation of bone, namely proliferative (osteoblastic) or lytic (osteoclastic) patterns (Cotran *et al.*, 1999; Vigorita, 1999). The first is responsible for the deposition of new bone, and the latter causes the resorption of bone (Coetzee *et al.*, 2003; Junqueira & Carneiro, 2003; Ross & Pawlina, 2006).

According to Schultz (2001), three groups of bone changes due to newly formed bone can be described microscopically (i.e., proliferative patterns): haemorrhagic, inflammatory, and tumorous. Only the first two will be discussed further. Haemorrhagic changes, such as ossified subperiosteal haematomas, are characterised by newly-built spongy bone on the intact external surface of the original bone (Maat & Uytterschaut, 1987; Schultz, 2001, 2003; Maat, 2004). It has been shown that such changes may occur in cases of healed scurvy after a vitamin C-deficient period. Experimental histological investigation of diaphyseal bone in vitamin C deficient guinea pigs indicated that the ossified haematomas

consisted of narrow bony trabeculae radiating from the original bone surface to the periosteum (Murray & Kodicek, 1949). As was also noted by Schultz (2001), these radiating trabeculae often join together with bony bridges. At the site of the ossified haematoma the external circumferential lamellae of the original bone are still intact and the underlying compact bone substance seems unaffected. It was also shown in guinea pigs that once the vitamin C-deficient diet is corrected, the structure of the radiating trabeculae starts to change: spaces separating the trabeculae begin to narrow and the trabecular bone gradually gets remodelled into compact bone, while still retaining its former radiating architectural characteristics (Murray & Kodicek, 1949). Therefore, in the long term, the radiating structure of the previously formed trabeculae may still stay visible.

Inflammatory diseases due to infection, such as non-specific periostitis, non-specific osteomyelitis and treponematosis, can also cause bone apposition on the external surface of long bones. In these cases, however, the border between the original bony cortex and the newly formed bone, namely the periosteal surface, breaks up and disappears (Vigorita, 1999; Maat, 2004).

According to Schultz and others, lesions caused by treponemal disease are also characterised by 'polsters' and 'grenzstreifen' when examined under polarised light (Schultz, 2001, 2003; Von Hunnius *et al.*, 2006). 'Polsters'can be identified as lamellar outgrowths at the periosteal level resembling pillows separated from each other by blood vessels. These structures seem regular, repetitive and positioned side-by-side. According to the same authors, 'polsters' may also be observed in bony lesions caused by leprosy, but then they are said to often be underdeveloped and flat. 'Grenzstreifen', also translated as 'border stripes', can be identified as a fine, narrow, band-like structure that marks the remaining original periosteal surface of the bone. On the external aspect of the 'grenzstreifen', newly formed bone will then be visible as a solid mass. Another important characteristic of infectious changes in bone, in particular treponemal disease, is said to be the osteoclastic changes of the endosteal bone and bony trabeculae. This process results in lysis, i.e. resorption holes/canals, corroded structures and vestiges of extensive remodeling visible throughout the thickness of the original cortical bone (Schultz, 2001, 2003; Von Hunnius *et al.*, 2006).

The purpose of this paper is to assess whether histological features, as described by Murray and Kodicek (1949), Maat and Uytterschaut (1987), Maat (2004), Schultz (2001, 2003) and Von Hunnius *et al.* (2006), correlate with the macroscopic diagnoses of ossified

haematomas (most probably resulting from healed scurvy) and syphilitic bone changes observed on the anterior tibiae of individuals from a 19th century mining community from Kimberley, South Africa. The frequent occurrence of these two diseases amongst the deceased was well-established in related hospital and other government sources (CGHVPP, 1899; Medical Officer of Health, 1900).

6.2 Materials and Methods

In April 2003, the Sol Plaatjie Municipality (Kimberley, South Africa) unknowingly disturbed several unmarked graves outside the fenced Gladstone cemetery, while digging a storm-water trench. The disturbed remains were most likely those of diamond miners who had died between 1897 and 1900 in the Kimberley and surrounding hospitals. They had been given paupers' burials. The McGregor Museum in Kimberley became involved through the South African Heritage Resources Agency (SAHRA), who requested them to investigate the graves. Consequently, all graves disturbed by the ground-moving machinery were exhumed. Preservation of the remains was found to be remarkably good in most cases.

Sex determination and estimation of age at death was done for each skeleton using standard anthroposcopic techniques such as the width of the subpubic angle, femoral head diameter, width of the sciatic notch, sternal ends of the ribs, the degree of cranial suture closure, tooth eruption and changes to the face of the pubic symphysis (e.g. De Villiers, 1968; Krogman & Íşcan, 1986; Hillson, 1998; Oettlé & Steyn, 2000; Asala, 2001; Franklin *et al.*, 2005). A total of 107 skeletons were exhumed from the trench which included 86 males, 15 females and 6 individuals of unknown sex. One premature baby, two infants (both younger than one year of age) and 13 juveniles between 11 and 19 years were the only non-adults present in the sample. The highest number of individuals was observed to be between 20 and 34 years of age (n=52). Twenty-five persons were estimated to have been 35 to 49 years old at the time of death. Only four individuals were found to have been older than 50 years. Due to the fragmentary condition of 10 skeletons, eight individuals could only be described as being adult, and the age of two other persons stayed undetermined (Van der Merwe & Steyn, 2006; Van der Merwe, 2007).

Diagnoses of pathological lesions on a macroscopic level were done using standard palaeopathological texts and pictures such as can be found in Steinbock (1976), Roberts

and Manchester (1995), Mann and Murphy (1990), Aufderheide and Rodríguez-Martín (1998) and Ortner (2003). Macroscopically, pathological lesions indicative of non-specific osteomyelitis, treponemal disease, tuberculosis, scurvy, amputations, fractures and some congenital abnormalities were found, amongst others (Van der Merwe & Steyn, 2006; Van der Merwe, 2007).

Indeed, historical documents supported the presence of many macroscopically observed pathological conditions within this population. For instance, it was reported that in 1897 a total of 311 individuals were admitted to Kimberley Hospital with manifest scurvy. Also, a high prevalence of diseases such as pneumonia, treponematosis, tuberculosis, as well as cases of trauma, were well documented in hospital reports and governmental documents (CGHVPPt, 1898; Stoney, 1900).

After anthropological investigations commenced, it became evident that it would be of great advantage to sample re-occurring pathological lesions on the anterior tibiae in order to increase the accuracy of diagnoses. Therefore, a 3–4mm transverse section of bone was removed from lesions on the anterior tibia of 14 individuals. Based on macroscopic investigations, these lesions had initially been diagnosed as ossified haematomas (see Figure 6.1), most likely associated with healed scurvy, in seven individuals (see Table 6.1). Two individuals had been diagnosed with treponemal disease (see Figure 6.2), three persons with lesions indicative of both treponemal disease and ossified haematomas, and two skeletons with lesions indicating possible non-specific periostitis (see Table 6.1).

Treponematosis was macroscopically diagnosed in individuals presenting with saber shin tibiae, gummatous osteomyelitis, diffuse periosteal and cortical bone thickening, and stellate scars on the cranial vault (Steinbock, 1976; Hackett, 1978; Reichs, 1989; Maat *et al.*, 1997; Ortner, 2003). Ossified haematomas, probably associated with healed scurvy, were macroscopically characterised by localised and well-demarcated lesions of bone apposition (Mann & Murphy, 1990; Maat, 2004). These lesions were usually symmetrical, and the majority of individuals presented with varying stages of bone reaction due to periodontal disease.

Sampling of the pathological lesions was done by making two parallel transverse cuts with a hacksaw, halfway through the bone shaft. These cuts were made perpendicular to the long axis of the bone. Care was taken not to damage the visible layer of bone growth on top of the original bone surface. By inserting a thin metal device into one of the cuts and bending it towards the second cut, the sample broke loose a the base of the two cuts

Figure 6.1 Ossified haematoma on the anterior tibia of a male, 28–34 years of age. (GLD SE7.3).

and could be removed. The section was bagged and labeled with the number of the individual, the anatomical location from where the sample was taken, as well as the initial macroscopic diagnosis of the pathology. Cross-sections were prepared for microscopic investigation, using a manual ground section technique described by Maat *et al.* (2000, 2001).

Each section was first inspected macroscopically. The form, distribution and nature of the new bone growth were documented. Next, each section was studied with both bright field and polarised light. Attention was given to the micro-architecture of the compact bone structure and external circumferential lamellae, as well as to the appositional bone in cases where it was present.

6.3 Results

Bone sections of 14 individuals were studied. Histological observations confirmed the presence of ossified haematomas in seven of these individuals (GLD N8.4, N8.5, N34.13, N38.5, S2.4, SE7.3, SE7.9), as can be seen in Table 6.1. These lesions were positioned on top of normal cortical bone, which itself was not affected by the pathological condition. During histological investigation it was found that the original periosteal surface, represented by the original external circumferential lamellae (see Figure 6.3), was intact in all of the abovementioned samples and could be followed throughout the section. In some

Figure 6.2 Humeri (A), ulnae (B), fibulae (C) and tibiae (D) of a male, 30–45 years of age (GLD N 74.7). The individual most likely suffered from treponematosis. Note the swollen appearance of the tibiae, distal fibulae, distal right humerus and distal left ulna.

cases it was interrupted in spots on the section, but still easy to visualise. The newly formed bone on the outside of the original periosteal surface was composed of radiating trabeculae (see Figure 6.4), as described by Murray and Kodicek (1949) in guinea pigs. These trabeculae were perpendicular to the periosteal surface of the bone.

Three phases of remodelling could be distinguished during the examination of the ossified subperiosteal haematomas. Recently ossified haematomas presented with very characteristic loosely arranged radiating trabeculae, as can be seen in individual GLD SE7.9 (see Figure 6.5). Here, the newly-formed bone seemed porous and many resorption



Figure 6.3 Histological structure of a bone lesion most likely caused by an ossified haematoma. Figure A shows the original cortical bone structure (a), original periosteal surface represented by original circumferential lamellae (c) and appositional bone (b) when viewed under normal bright light, and Figure B, when viewed with polarized light.

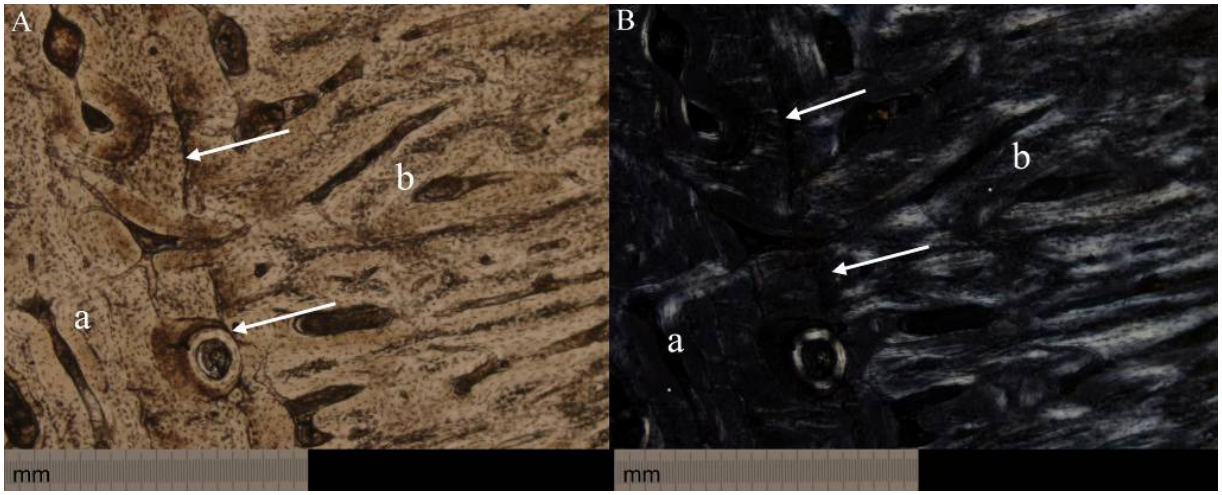

Figure 6.4 Radiating structure of appositional bone observed in an ossified haematoma. Original cortical bone (a), original periosteal surface (indicated by arrows) and appositional bone (b) can be seen here. Note the radiating structure of the appositional bone when viewed under bright light (Figure A). The structure becomes even more visible when viewed with polarized light (Figure B).

holes/canals were present. The second stage (for example in GLD SE7.3) is characterized by remodelling of the aforementioned trabeculae and filling-in of the openings between them (see Figure 6.6). Although in this case the various original trabeculae cannot be distinguished as separate anymore, the appositional bone still retains its radiating character. The last phase characterises very long-standing lesions, and can be seen in individuals GLD S1.3 and GLD N8.4. Although the appositional bone still retains its radiating structure (see Figure 6.7), bone remodeling into Haversian systems has commenced in the appositional bone, making the distinction between the ossified haematoma and the original compact

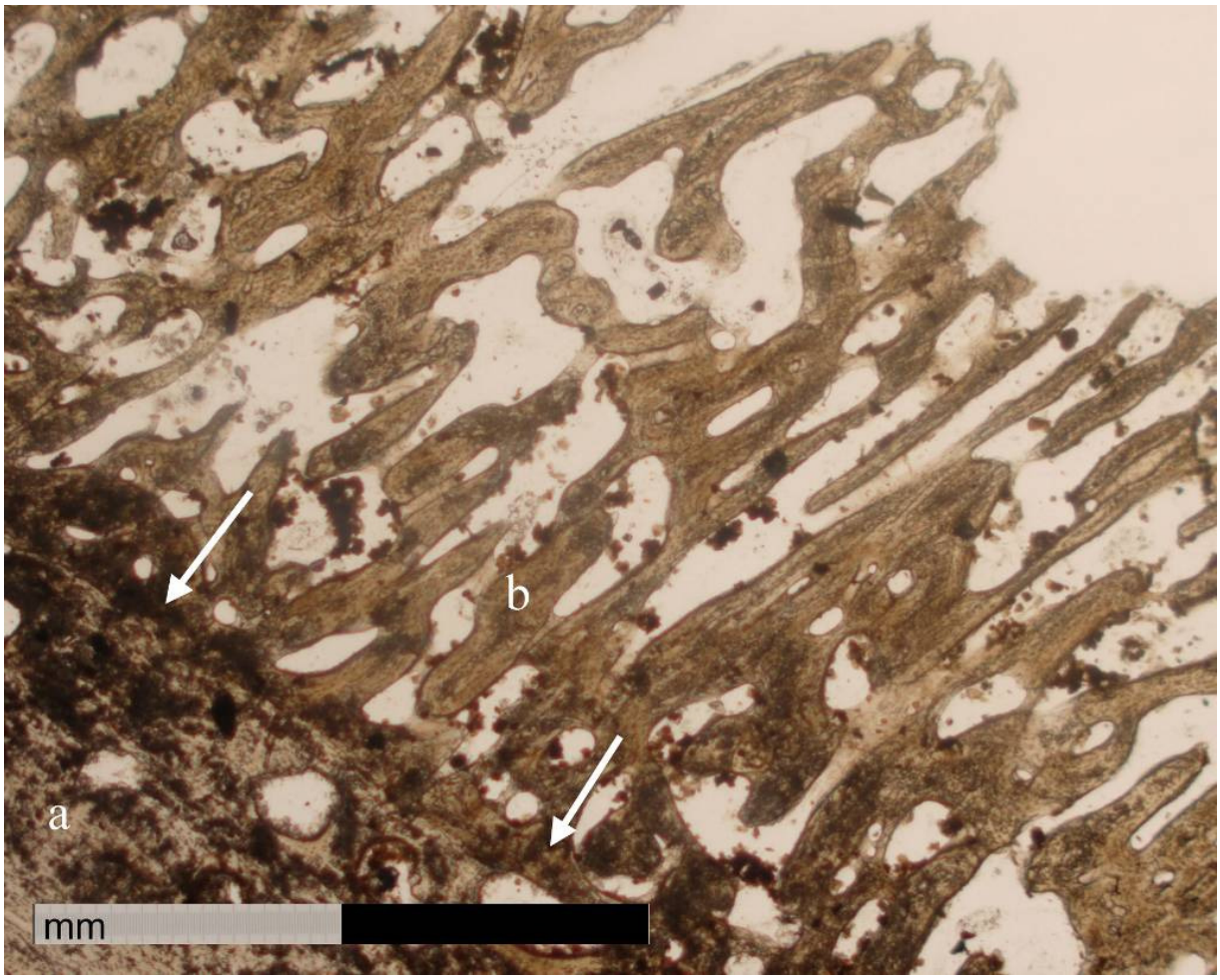

Figure 6.5 Phase I of the ossification of a subperiosteal haematoma. The unaffected original cortical bone (a), original periosteal surface (arrows) and very characteristic radiating trabeculae of the appositional bone (b) can be identified.

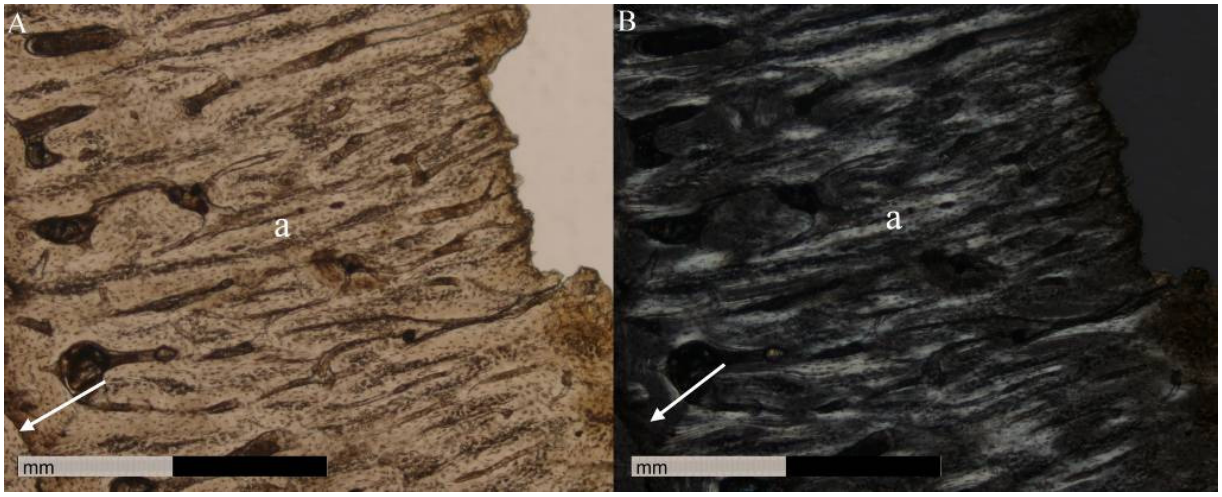

Figure 6.6 Phase II of remodelling of a subperiosteal haematoma. The original periosteal surface (arrows) and appositional bone (a) can be seen when viewed with bright (A) and polarized light (B). Note that although spaces between the original radiating trabeculae in appositional bone had been filled in, the new bone still retains a radiating structure.

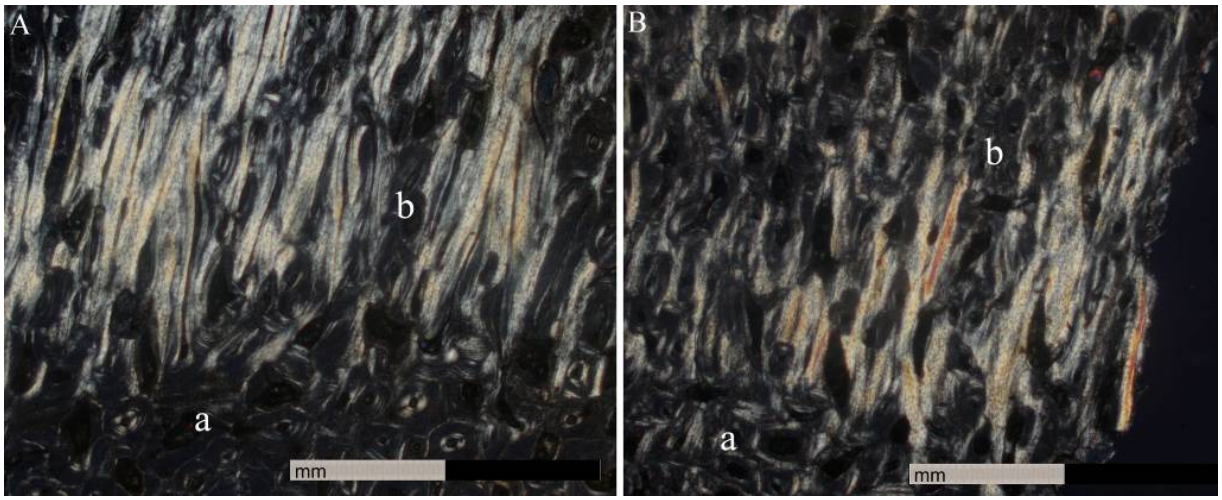

Figure 6.7 Phase III of remodelling of a subperiosteal haematoma. Long-standing ossified haematomas of GLD S1.3 (A) and GLD N8.4 (B) viewed with polarized light. Although the original cortical bone (a) and radiating structure of appositional bone (c) can still be clearly distinguished, the original periosteal surface had become vague and remodelling of appositional bone into Haversian bone, resembling cortical bone, had begun.

bone less clear. Histological features confirmed the presence of osteomyelitis in one case (see Table 1). It should be mentioned here that this term includes all infectious bone changes such as lesions caused by non-specific osteomyelitis, treponematosis, leprosy and tuberculosis. Clear and unmixed histological indications of infectious bone changes were observed in this case (GLD N74.7). The cortical bone seemed extremely thickened on cross-section (see Figure 6.8). On a histological level, intense remodeling with numerous resorption holes/canals was present (see Figure 6.9), giving the section a porous appearance and making distinction between the internal spongy bone and the cortical bone almost

impossible. No original circumferential lamellae, as were seen in the ossified haematomas, were present in this section. No separable bone apposition or radiating bone structures were visible. Histological features such as 'grenzstreifen' and 'polsters', described by Schultz (2001, 2003) as characteristic of treponematosis, could not be identified.

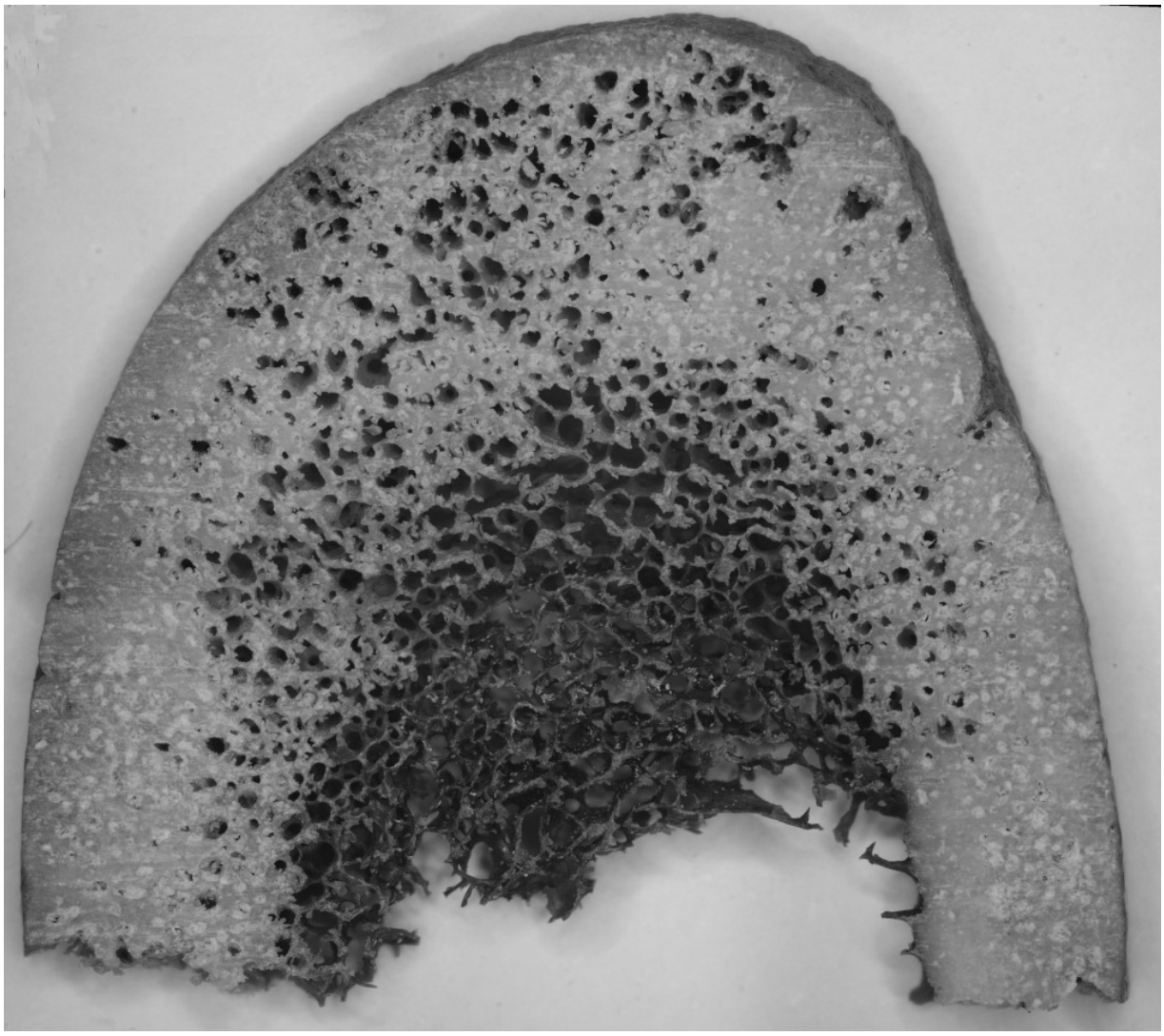

Figure 6.8 Cross section through the anterior tibia of GLDN74.7 affected by treponemal disease.

In three cases histological findings confirmed the macroscopic diagnoses but also helped to identify the presence of more than one pathological condition (NOP3/4.2, S1.3, SE7.7). Histological observations in these sections were indicative of both the aforementioned conditions (haemorrhagic bone apposition and inflammatory bone reactions) (see Table 6.1). In all of these sections, the bone was extremely thickened in cross-section, and histological investigation revealed different severities of resorption

Table 6.1 Differential diagnosis on macroscopic level and microscopic findings of pathological lesions.

Individual	Age (years)	Sex	Differential diagnoses on macroscopic level	Microscopic findings	Final diagnosis
GLD N8.4	J	M	Osteoid osteoma with nidus, cortical osteoblastoma, ossified hematoma	Demarcated and radiating bone apposition	Ossified hematoma most likely associated with scurvy
GLD N34.13	YA	M	Osteochondroma, ossified hematoma	Demarcated and radiating bone apposition	Ossified hematoma most likely associated with scurvy
GLD N38.5	YA	M	Cortical osteoblastoma, ossified hematoma, treponemal disease	Demarcated and radiating bone apposition	Ossified hematoma most likely associated with scurvy
GLD S2.4	MA	Fe	Ossified hematoma, treponemal disease	Demarcated and radiating bone apposition	Ossified hematoma most likely associated with scurvy
GLD SE7.3	YA	M	Ossified hematoma	Demarcated and radiating bone apposition	Ossified hematoma most likely associated with scurvy
GLD SE7.9	MA	M	Osteomyelitis, ossified hematoma	Demarcated and radiating bone apposition	Ossified hematoma most likely associated with scurvy

M=male, F=female, J=juvenile (11-19 years), YA=young adult (20-34 years), MA=middle adult (35-49 years)

Table 6.1 (cont.) Differential diagnosis on macroscopic level and microscopic findings of pathological lesions.

Individual	Age	Sex	Differential diagnoses on macroscopic level	Microscopic findings	Final diagnosis
GLD N74.7	MA	M	Treponematosis, Non-specific osteomyelitis	Osteomyelitic bone reaction	Treponematosis
GLD N8.5	YA	M	Healed periostitis, ossified hematoma	Demarcated and radiating bone apposition	Ossified hematoma most likely associated with scurvy
GLD NOP3/4.2	YA	M	Treponematosis	A combination of demarcated bone apposition and osteomyelitic bone reaction	Possible treponematosis and hemorrhagic bone apposition
GLD S1.3	YA	M	Osteoid osteoma with nidus, cortical osteoblastoma ossified hematoma, treponemal disease	Combination of demarcated bone apposition and osteomyelitic bone reaction	Possible treponematosis and hemorrhagic bone apposition
GLD SE7.7	YA	M	Osteo-periostitis, early ossified hematoma	Combination of demarcated bone apposition and osteomyelitic bone reaction	Possible treponematosis and hemorrhagic bone apposition
GLD N31.E.1	MA	M	Ossified hematoma	Normal	Normal
GLD S2.9	MA	M	Periostitis	Normal	Normal
GLD SE7.4	MA	M	Periostitis	Normal	Normal

M =male, F=female, YA=young adult (20-34 years), MA=middle adult (35-49 years)

holes/canals indicative of inflammatory bone changes. Apart from these lytic changes to the cortical bone, a still distinct, although interrupted, original periosteal surface, represented by the original circumferential lamellae, was present with radiating appositional bone on top of it.

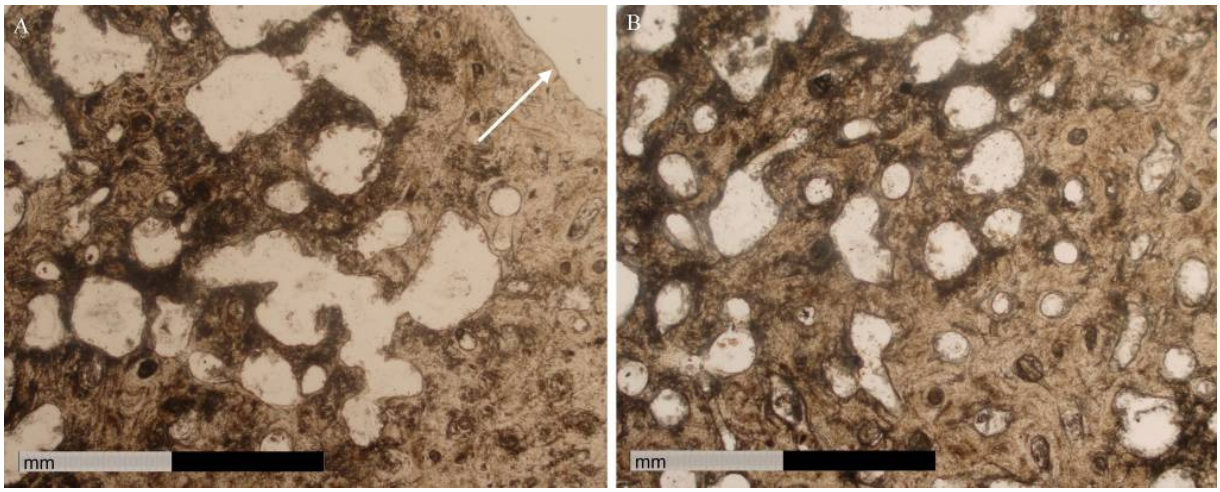

Figure 6.9 Destruction of cortical bone caused by an infectious condition. Periosteal surface indicated by an arrow in A.

Histological results proved macroscopic diagnoses wrong in three cases (GLD N31.E.1, S2.9, SE7.4). In all of these cases, externally striated bone surfaces and possible slight subperiosteal bone reactions were observed during macroscopic investigation. These lesions were thought to be indicative of either non-specific periostitis, early haemorrhagic bone changes, or periosteal remodeling as a result of the strenuous physical activity mine workers were exposed to on a daily basis. Histological investigation revealed that no pathological changes were present in or on the bone.

6.4 Discussion

Controversy exists regarding the accurate diagnosis of pathological conditions through microscopic evaluation of pathological lesions found in skeletal material (Murray & Kodicek, 1949; Blondiaux *et al.*, 1994; Schultz, 2003; Maat, 2004; Von Hunnius *et al.*, 2006). According to Schultz (2003), pathological conditions affecting bone can be distinguished from each other on the basis of their histomorphology on a microscopic level. Infectious diseases such as non-specific osteomyelitis, leprosy and treponemal disease are said to have identifiable characteristics on a microscopic level, making differentiation between these conditions more reliable (Schultz, 2001, 2003; Von Hunnius *et al.*, 2006).

Earlier studies, such as those by Martin and Armelagos (1979) and Putschar (1966), however, suggest that bone can only react in two non-specific ways. According to this argument, two types of cells are responsible for the morphological structure of bone on a microscopic level: osteoblasts and osteoclasts. The first is responsible for the formation of new bone, and the second for the resorption of bone. Remodelling of bone, be it due to a normal or pathological stimulus, is accordingly controlled by the relationship between the osteoblasts and the osteoclasts, one causing the deposition of bone and the other the resorption. Therefore, the basic development of specific histomorphological features for each disease seems impossible.

When considering the two diseases primarily investigated in this histological analysis, being ossified haematomas, probably due to scurvy and treponemal infection, it is clear that they are in two very different categories of bone changes. Individuals suffering from scurvy may develop subperiosteal haematomas on their weightbearing bones, especially on the tibiae and fibulae (Murray & Kodicek, 1949; Auferheide & Rodríguez-Martín, 1998; Maat, 2004). It should be mentioned here that although the ossified haematomas observed in this study can most likely be associated with scurvy, these lesions may also be trauma-related. The histologcal characteristics would however be similar, since the described histological features are indicative of ossified haematomas regardless of their cause. What is important to notice, though, is that the lesions developing due to the haemorrhagic reaction occur due to the ossification of the subperiosteal haematoma on top of the original bone surface. Therefore, it only involves the haematoma, and the underlying bone is not affected. This is exactly what can be seen on a microscopic level. The original cortical bone as well as the external circumferential lamellae are unaffected by the lesion.

Ossified haematoma formation induced by scurvy was well-described after convincing experiments in guinea pigs by Murray and Kodicek (1949), in a study on mid-diaphyseal thickenings of the tibia. Although this is an animal study, it is very valuable since it describes changes occurring during the ossification of a subperiosteal haematoma in the only other mammal incapable of producing its own vitamin C, like humans. According to this study, once the animals further recovered from the scorbutic state, the initial deposited appositional bone, which had a radiating trabecular structure, was remodeled into compact bone while still retaining its radiating characteristics. Thus, once normal levels of vitamin C were restored and retained, the density of the appositional bone increased.

Results obtained during the investigation of pathological lesions from the Kimberley population showed the same pattern of trabeculae formation. Remodeling of the appositional bone by filling in the openings between the trabeculae, as was observed in the guinea pigs, can be seen in humans too. Accordingly, three stages of ossified haematoma formation and remodeling are proposed.

In phase I, the bony, loosely-arranged trabeculae radiate from the original periosteal surface to the lifted periosteum. It should be kept in mind that this radiating structure will only be visible in cross-section, and that these trabeculae are actually more or less longitudinally arranged within the lesion. The original cortical bone as well as the external circumferential lamellae was still intact and unaffected by the pathological process. Looking at a cross-section with the naked eye, the appositional bone seemed extremely porous and clearly visible. It is proposed that this phase will be present during the early stages of ossification of a haematoma, and thus shortly after the restoration of normal levels of vitamin C in the diet.

Phase II could be recognised by the filling-in of the openings between the trabeculae. The original cortical bone, circumferential lamellae and appositional bone were still clearly distinguishable from each other. The appositional bone now had a more compact bone structure, when examined macroscopically on cross-section. In contrast to what was observed in phase I, longitudinal plates of bony lamellae now filled in the openings in the trabecular bone, resulting in the appositional bone having a regular though still radiating appearance on cross-section with no Haversian bone. This proposed phase characterizes the early stages of remodeling of an ossified haematoma after normal levels of vitamin C have been restored in the diet.

In phase III, extensive remodeling of the appositional bone could be observed. The relatively regular appositional bone structure observed in phase II had been replaced by a scattered formation of Haversian systems. The external circumferential lamellae, which represented the original periosteal surface in the previous two phases, became interrupted and were often no longer visible microscopically. Regardless of the extensive remodelling, the radiating structure of the appositional bone stayed visible on cross-section during microscopic investigations under polarised light. It is proposed that this phase is characteristic of long-standing ossified haematomas; the older the haematoma, the more extensive the remodeling of the appositional bone, as was also seen in the guinea pigs (Murray & Kodicek, 1949).

Schultz (2003) and Von Hunnius *et al.* (2006) identified certain histological structures termed 'grenzstreifen' and 'polsters', respectively, as "useful indicator[s] with which to diagnose chronic treponematoses by microscopy" (Schultz, 2003:92). These structures could not be identified in the sections taken from the tibia of an individual affected by treponemal disease, although they were visible in samples thought to be affected by both ossified haematomas and lesions indicative of treponematosis. Several reasons for the absence of these structures are proposed.

Firstly, the sections were slightly infested with a fungus, making the visualisation of the morphological structures difficult (see Figure 6.7). It also limited the use of polarised light, which would have made visualisation of the original circumferential lamellae easier and more reliable, should it be have been present. Another factor that should be considered is that the literature describing these histological features is unclear. Schultz (2003:91), for example, described 'grenzstreifen' as "a very fine line or narrow ribbon-like structure that is the original external surface of the bone shaft", yet the figure associated with this description in fact indicates the normal external circumferential lamellae of the cortex. Von Hunnius *et al.* (2006) on the other hand referred to 'grenzstreifen' as cement lines, although osteocyte lacunae are clearly visible within the 'grenzstreifen' in the figures exhibiting this feature.

Secondly, it is possible that these structures simply were not present in the specific part of the lesion from which the section was taken. In a study conducted by Von Hunnius *et al.* (2006) on the histological identification of syphilis, it was found that the structures described by Schultz (2003) are extremely variable in shape and distribution. Accordingly, positive diagnoses by using the presence of these features proved to be highly dependent on the part of the section investigated. Lastly, these structures may not be exclusively associated with treponematosis. As already mentioned by Schultz (2003), these characteristic structures are also visible in lesions caused by leprosy and haematogenous non-specific osteomyelitis. Features very suggestive of the described structures were also noted in the sections made from changes caused by ossified haematomas in this study.

Microscopic investigations of lesions that developed due to treponemal disease revealed that the sections were extremely porous, with huge resorption holes/canals scattered throughout the sample. No clear distinction could be made macroscopically or microscopically between the original internal trabeculae and the cortical bone due to the porous nature of the sections. Although the sections were clearly enlarged on cross-section,

no traces of the original periosteal surface or new appositional bone could be identified - only general osteoclastic resorption changes (lysis) were present.

According to Blondiaux *et al.* (1994), bone affected by leprosy presented with a large amount of osteoclastic lacunae, giving the bone a porous appearance, and little to no normal Haversian bone was observed. This picture is very similar to that seen in the macroscopically diagnosed treponemal lesions from Kimberley, and it is therefore proposed that infectious changes in bone are most likely very similar on a histological level regardless of the specific condition that caused the osteomyelitis. Therefore, although histological features could not confirm the apparent presence of treponematosis in this study, it was helpful in identifying general osteomyelitic changes clearly distinguishable from ossified subperiosteal haematomas. It was only in conjunction with macroscopic investigation and a clear description of the distribution pattern of the lesions across the skeleton that this osteomyelitis could be attributed to a specific infectious disease, treponematosis.

Four individuals in this study presented with a histological picture indicative of more than one pathological condition. These results emphasized the importance of differential diagnoses of lesions observed during macroscopic investigations.

It was interesting to note that, in three other cases, an incorrect diagnosis of the presence of disease was made by means of gross morphological analysis only. Striations and possible slight subperiosteal bone growth were observed on these bones. Histological sections indicated no pathological changes to the structure of the bone, suggesting that these tibiae were, in fact, normal. This has far-reaching implications for palaeopathological studies, since it may be possible that the pathological condition 'periostitis' particularly is over-diagnosed. This observation needs to be followed up in future studies.

6.5 Conclusion

Pathological lesions, diagnosed macroscopically as resulting from possible scurvy, treponematosis or non-specific periostitis, on the anterior tibiae of 19th century mine workers from Kimberley, were microscopically examined.

Ossified haematomas could be characterized by microscopically unaffected original cortical bone and apposed external radiating trabeculae with or without a horizontal interconnection on the outside surface. Three phases of ossified haematoma formation and

remodelling, as once described in guinea pigs, were proposed in humans, with each stage resulting in gradual bone remodeling from loosely arranged radiating trabecular bone to more compact Haversian bone, while still retaining a radiating bone structure.

Histological features such as the 'grenzstreifen' and 'polsters' described by Schultz (2003) could not be identified in the sections macroscopically diagnosed to be affected by treponemal infection. One possible explanation may be that these structures are not exclusively associated with treponematosis. It was proposed as very likely that the same histological picture will be observed in samples taken from lesions caused by non-specific osteomyelitis, treponematosis and leprosy, since the development of osteomyelitic changes has been described as characteristic in all of these diseases (e.g. Blondiaux *et al.*, 1994; Ortner, 2003).

Thus, it was concluded that although histological investigations could not aid in the diagnosis of specific infectious diseases, such as the syphilitic lesions observed in this study, it was valuable in distinguishing between infectious lesions and those formed by the ossification of subperiosteal haematomas.

References

Asala, S.A. 2001. Sex determination from the head of the femur of South African whites and blacks. *Forensic Science International* 117:15–22.

Aufderheide, A.C. and Rodríguez-Martín, C. 1998. *The Cambridge Encyclopedia of Human Paleopathology*. Cambridge: Cambridge University Press.

Blondiaux, J., Duvette, J., Eisenberg, L. and Vatteoni, S. 1994. Microradiographs of leprosy from an osteoarchaeological context. *International Journal of Osteoarchaeology* 4:13–20.

Cape of Good Hope Votes and Proceedings of Parliament. 1899. Hospitals and Asylums Report for 1898, Appendix I.

Coetzee, H.L., Loots, G.P. and Meiring, J.H. 2003. Bone. In: *Human Histology*. Pretoria: Van Schaik, pp. 91–110.

Cotran, R.S., Kumar, V. and Collins, T. 1999. *Robbins Pathological Basis of Disease*. Philadelphia: WB Saunders.

De Villiers, H. 1968. Sexual dimorphism of the skull of the South African Bantu-speaking Negro. *South African Journal of Science* 84:118–124.

Franklin, D., Freedman, L., andMilne N. 2005. Sexual dimorphism and discriminant function sexing in indigenous South African crania. *Homo* 55:213–228.

Garland, A.N. 1993. An introduction to histology of exhumed mineralized tissue. In: *Histology of Ancient Human Bone: Methods and Diagnosis.* Grupe, G. and Garland, A.N. (eds). Berlin: Springer-Verlag, pp.1-16.

Hackett, C.J. 1978. Treponematoses (yaws and treponarid) in exhumed Australian Aboriginal bones. *Records of the South Australian Museum* 27:387–405.

Herrmann, B. 1993. Light microscopy of excavated human bone. In *Histology of Ancient Human Bone: Methods and Diagnosis.* Grupe, G. and Garland, A.N. (eds). Berlin: Springer-Verlag, pp.79-94.

Hillson, S. 1998. *Dental Anthropology*. Cambridge: Cambridge University Press.

Junqueira, L.C. and Carneiro, J. 2003. Bone. In: *Basic Histology*, *Text and Atlas*. Lange Medical Books. New York: McGraw-Hill, pp. 141–160.

Krogman, W.M. and İşcan, M.Y. 1986. *The Human Skeleton in Forensic Medicine* (2nd ed). Springfield: Charles C. Thomas.

Maat, G.J.R. 2004. Scurvy in adults and youngsters: the Dutch experience. A review of the history and pathology of a disregarded disease. *International Journal of Osteoarchaeology* 14:77–81.

Maat, G.J.R. and Uytterschaut, H.T. 1987. Microscopic observations on scurvy in Dutch whalers buried at Spitsbergen. In: *Proceedings of the Palaeopathology Association 5th European Meeting.* Capecchi V, Rabino Massa E (eds). Paleopathology Association: Sienna; pp. 211–218.

Maat, G.J.R., Van den Eynde, G. and Mastwijk, R.W. 1997. De eerste Nassaus in Nederland: identificatie van en paleopathologische bevindingen bij de voorpuders van Willem Oranje, begraven in de Grote of Onze Lieve Vrouwe Kerk in Breda. *Nederlands Tijdschrift voor Geneeskunde*. 141:2501–2513.

Maat, G.J.R., Van den Bos, R.P.M. and Aarents, M.J. 2000. *Manual for the Preparation of Ground Sections for the Microscopy of Bone Tissue*. Leiden: Barge's Anthropologica.

Maat, G.J.R., Van den Bos, R.P.M. van Aarents, M.J. 2001. Manual preparation of ground sections for the microscopy of natural bone tissue: update and modification of Frost's rapid manual method. *International Journal of Osteoarchaeology* 11:377–374.

Mann, R.W. and Murphy, S.P. 1990. *Regional Atlas of Bone Disease: A Guide to Pathologic and Normal Variation in the Human Skeleton*. Springfield: Charles C. Thomas.

Martin, D.L. and Armelagos, G.J. 1979. Morphometrics of compact bone: an example from Sudanese Nubia. *American Journal of Physical Anthropology* 51:571– 578.

Medical Officer of Health. 1900. *Medical Officer of Health reports for 1899 and 1900*. Unpublished report held in Kimberley Africana Library, Kimberley.

Murray, P.D.F. and Kodicek, E. 1949. Bones, muscles and vitamin C. II Partial deficiencies of vitamin C and mid-diaphyseal thickenings of the tibia and fibula in guinea-pigs. *Journal of Anatomy* 3:205–223.

Oettlé, C. and Steyn, M. 2000. Age estimation from sternal ends of ribs by phase analysis in South African blacks. *Journal of Forensic Sciences* 45:1071–1079.

Ortner, D.J. 2003. *Identification of Pathological Conditions in Human Skeletal Remains* (2nd ed). Amsterdam: Academic Press.

Ortner, D.J. and Putschar, W.G.J.. 1981 *Identification of Pathological Conditions in Human Skeletal Remains*. Washington, DC: Smithsonian Institution Press.

Putschar, W.G.J. 1966. Problems in the paleopathology of bone. In: *Human Paleopathology* Jarcho S. (ed.). New Haven:Yale University Press, pp. 57–65.

Reichs, K.J. 1989. Treponematosis: a possible case from the late prehistoric of North Carolina. *American Journal of Physical Anthropology* 79:289–303.

Roberts, C. and Manchester, K. 1995. *The Archaeology of Disease* (2nd ed). Stroud: Alan Sutton Publishing.

Ross, M.H. and Pawlina, W. 2006. Bone. In: *Histology, A. Text and Atlas* (6th ed). Taylor, C., Scogna, K.H. and Ajello, J.P. (eds.). Baltimore: Lippincott Williams & Wilkins, pp. 202–237.

Schultz, M. 2001. Paleohistopathology of bone: a new approach to the study of ancient diseases. *Yearbook of Physical Anthropology* 44:106–147.

Schultz, M. 2003. Light microscopic analysis in skeletal paleopathology. In: *Identification of Pathological Conditions in Human Skeletal Remains* (2nd ed). Ortner, D.J. (ed.). Amsterdam: Academic Press.

Steinbock, R.T. 1976. *Paleopathological Diagnosis and Interpretation*. Springfield: Charles C. Thomas.

Stoney, W.W. 1900. *Report of the Medical Officer of Health, Kimberley, for the years 1898*. McGregor Museum, Kimberley, South Africa.

Van der Merwe, A.E. 2007. *Human Skeletal Remains from Kimberley: An Assessment of Health in a 19th Century Mining Community*. Unpublished MSc thesis. University of Pretoria.

Van der Merwe, A.E. and Steyn, M. 2006. Human skeletal remains from Kimberley, South Africa: an assessment of health in a 19th century mining community. In: *Proceedings of the 16th European Meeting of the Paleopathology Association*, Santorini.

Vigorita, V.J. 1999. *Orthopaedic Pathology*. Philadelphia: Lippincott Williams and Wilkins.

Von Hunnius, T.E., Roberts, C.A., Boylston, A. and Saunders, S.R. 2006. Histological identification of syphilis in Pre-columbian England. *American Journal of Physical Anthropology* 129:559–566.

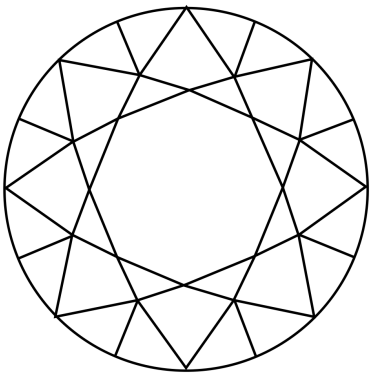

CHAPTER 7

Dental Health of 19th Century Migrant Mineworkers from Kimberley, South Africa

Modified from article published as:

Dental health of 19th century migrant mineworkers from Kimberley, South Africa

A.E. Van der Merwe, M. Steyn, G.J.R. Maat

International Journal of Osteoarchaeology (2010)

DOI: 10.1002/oa.1143

Migrant mine workers 1886
(McGregor Museum Kimberley Photography nr.7581)



Wesselton Mine compound, early 1900
(McGregor Museum Kimberley Photography nr.834)

Abstract

Dental health may deteriorate in populations exposed to economic growth as a result of easier access to refined carbohydrates and sugars. Such changes affected migrant labourers working in Kimberley, South Africa, during the late 19th century. A rescue excavation salvaged several skeletons from pauper's graves dating from this period, and the purpose of the study was to assess their dental health to determine whether it concurs with historical statements suggesting that the skeletal population sample consisted of migrant labourers with limited access to a healthy diet. According to historical sources, their diet mainly consisted of ground carbohydrates with occasional meat.

The permanent dentition of 79 males and 13 females (most between 20 and 49 years of age) were examined. Carious lesions were observed in 57% of males and 46.2% of females with an average of 2.7 and 3.8 carious teeth per mouth respectively. The anterior teeth were significantly less affected than the posterior teeth. Periodontal granulomata ('abscesses') were observed in 17.7% of males and 15.4% of females, and periodontal disease affected 40% of those investigated. Antemortem tooth loss (AMTL) was recorded in 29% (N=27) of the sample with an average of 3.5 teeth lost per mouth.

It was concluded that the prevalence of dental caries, periapical granulomata and periodontal disease as well as the pattern of AMTL observed, concurs with dietary descriptions for paupers in historical documents. The relatively low prevalence of carious lesions can be ascribed to the limited time migrant labourers spent in Kimberley and the labour restrictions they had to comply with during their stay in the compounds.

7.1 Introduction

Teeth are often recovered during archaeological excavations due to their hard and robust structure, thus becoming a valuable source of information during the investigation of skeletal material. Several characteristics can be investigated, such as the prevalence of carious lesions, antemortem tooth loss, dental wear, enamel hypoplasia and supernumerary teeth, all of which add to our understanding of the diet, oral hygiene, stress levels and habitual activities of past populations (Hillson, 1979; Roberts & Manchester, 1995; Hillson, 1998; Ortner, 2003).

Various studies have been conducted on the dental health of both living and skeletal population samples of black South Africans. As would be expected, these studies indicated that the prevalence of dental pathology changes as populations progressed from a traditional hunter-gather diet, to an agricultural diet, and then to a diet high in refined carbohydrates and sugars (Staz, 1938; Cleaton-Jones, 1979; Morris, 1992; Steyn *et al.*, 2002; L'Abbé *et al.*, 2003; L'Abbé *et al.*, 2005). Thus, it is clear that a decrease in dental health, specifically an increase in dental caries, is caused by changes in subsistence patterns often associated with economic growth and industrial advances. Such an economic change resulting in the rapid availability of sugars and machine ground carbohydrates (maize meal in particular) to originally rural African communities also occurred during the late 19th century in Kimberley, South Africa, with the discovery of diamonds.

The 1871 discovery of diamonds on Colesberg Kopje in South Africa, resulted in many people rushing to mark their claims. By 1899, population numbers had increased dramatically and it was estimated to include 16,300 Europeans and 28,200 black individuals (Stoney, 1900).

It is stated in historical documents that the majority of black mineworkers in Kimberley were migrant labourers. Males left their families in the rural areas, within and outside the borders of South Africa, and came to Kimberley for a limited period of time to work on the diamond mines. During their stay they were housed in closed labour compounds (Turrell, 1984; Roberts 1976; Worger 1987). The compounds were developed to improve security and limit the theft of diamonds, while increasing productivity by restricting and controlling the movements of labourers. Although the compounds were intended to provide adequate shelter and supply in the nutritional needs of all labourers, the living conditions in these camps were poor (Turrell, 1984; Jochelson, 2001). After their

labour contracts expired, workers returned to their rural families (McNish, 1970; Roberts, 1976).

Several complete skeletons were exhumed from damaged, unmarked graves alongside the fenced Gladstone cemetery in Kimberley, South Africa in 2003. Historical documents indicated that these graves dated to between 1897 and 1900. They were pauper's burials of individuals who had passed away in the Kimberley and surrounding hospitals (Swanepoel, 2003). Several skeletal lesions suggestive of scurvy, tuberculosis, treponemal diseases, violent trauma and congenital abnormalities were observed during the investigation of the remains (Van der Merwe *et al*, 2010a, b, c).

It can be assumed that food sources were initially very limited and low-cariogenic in nature when diamonds were first discovered in the district of Kimberley, since refined carbohydrates and sugars would have had to be brought all the way from large South African towns such as Durban and Cape Town. However, as the mining community grew economically, resources increased and Colesberg Kopje turned into a city. This probably resulted in much easier access to refined carbohydrates and sugars for the resident community, although this increased prosperity was probably slow to reach the migrant labourers. Therefore, the aim of this study was twofold: 1) to assess the prevalence of dental caries, antemortem tooth loss and enamel hypoplasia, as well as bony evidence of periodontal disease and periapical granulomata and -cysts in the skeletal population sample, and 2) to determine whether the dental health is consistent with what is known from historical documents. The majority of black individuals in Kimberley were migrant workers, housed in mining compounds, with restricted to no access to dietary products outside of their housing facilities. As briefly described in the historical documents, the diet of black labourers in Kimberley was comprised mainly of machine ground carbohydrates (mealie meal) and occasional meat (Harries, 1994). Therefore, they experienced limited exposure to dietary factors which may be associated with increased economic prosperity, such as an increase in the consumption of refined carbohydrates and sugars.

7.2 Materials and Methods

A total of 86 males, 15 females and 6 individuals of unknown sex were available for study. Standard anthropological techniques such as the assessment of changes to the sternal ends of the ribs, changes to the pubic symphyses, ectocranial suture closure, as well as

general cranial and pelvic morphology and discriminant functions were used to determine the age and sex of all individuals exhumed from the trench (e.g., De Villiers, 1968; Krogman & İşcan, 1986; Hillson, 1998; Oettlé & Steyn, 2000; Asala, 2001; Franklin *et al.*, 2005).

The permanent dentition of 79 males and 13 females were examined under good lighting for signs of dental caries, antemortem tooth loss and bony evidence of periapical - granulomata and -cysts, periodontal disease and enamel hypoplasia (EH). The 92 individuals examined were comprised of 12 (13%) sub-adults (11 – 19 years), 52 (57%) young adults (20 – 34 years), 25 (27%) middle aged adults (35 – 49 years), one (1%) old adult (50+ years) and two (2%) individuals who could only be described as being adult.

Due to the possibility of post-depositional damage to the teeth mimicking early stages of lesion development, a carious lesion was only recorded when a clear cavity was present. The location of carious lesions was recorded according to tooth type as well as to the surface of the tooth primarily affected by the lesion. Multiple lesions on one tooth were treated as a single occurrence.

Calculations described by Lukacs (1989) and Henneberg (1991) were used to analyze the dental caries data. The following was calculated:

a) individual caries frequency - the frequency of individuals presenting with carious lesions divided by the total number of individuals investigated;
b) caries intensity - the number of carious teeth observed divided by the total number of teeth investigated;
c) mean number of carious teeth per mouth - the total number of carious teeth observed divided by the total number of individuals presenting with teeth affected by dental caries; and
d) caries intensity per tooth type - the number of carious teeth present on a specific type of tooth divided by the total number of that specific tooth observed.

Percentages were calculated separately for each sex.

Unfortunately, the antemortem loss of teeth has a great influence on the accuracy of the intensity of dental caries within a population and can cause the underestimation thereof (Lukacs, 1995). Therefore, using a method described by Lukacs (1995), antemortem tooth loss was taken into account and a "corrected" intensity for dental caries within this population was also calculated.

Further statistical analyses included Chi-square tests to determine if there were significant differences in the prevalence of carious teeth between males and females, between various tooth types, between the observed caries intensity and corrected caries intensity, as well as to test for comparability with results obtained from other studies. Comparisons between population groups were done only for the data obtained for males in this study, as so few females were present in the Gladstone population sample and significant difference exists between the dental health of males and females in other studies, which would result in skewing of the data should it be pooled.

The prevalence of dental caries observed in the Gladstone sample was compared to studies by Oranje *et al*. (1935) and Staz (1938). Both investigated the difference in the prevalence of dental caries between living individuals following a traditional rural-, mine-based and urban diet. Although there are often difficulties in comparing results obtained from living to skeletal sample populations, these specific studies were well suited for several reasons. Firstly, they were comprised of samples of young male individuals contemporary to the Gladstone skeletal sample. The studies were also cross sectional and similar to this study, the prevalence of dental caries was, calculated by determining the caries frequency, caries intensity and the average number of carious teeth per mouth in those affected (the DMFT/S* index was not used). Other comparative samples included skeletal remains from Maroelabult, Koffiefontein and Venda, of which only results obtained for young adult males (19 – 40 years) were used for comparison (Steyn *et al.*, 2002; L'Abbé *et al.*, 2003; L'Abbé, 2005).

Antemortem tooth loss (AMTL) can be recognized by the resorption of the alveolar bone tissue, socket filling and mesial drift (Turner, 1979; Lukacs, 1989). It should be noted that teeth lost just before death will show no signs of alveolar resorption and therefore these may be interpreted to have been lost postmortem (Turner, 1979). Methods described by Lukacs (1989) and Henneberg (1991) to assess antemortem loss were used in this study. The following calculations were done:

a) individual AMTL frequency – the total number of individuals who lost one or more tooth antemortem divided by the total number of individuals investigated;

* Index recommended by the World Health Organization to express dental caries in clinical practice taking decayed (D), missing (M) and filled (F) teeth into consideration in relation to each specific tooth (T) or tooth surface (S) (Oral health surveys: basic methods. Geneva: World Health Organization, 1987)

b) AMTL intensity – the total number of teeth lost antemortem divided by the total number of teeth present in the sample before AMTL;

c) mean number of teeth lost antemortem per individual – the total number of teeth lost antemortem divided by the number of individuals affected by AMTL; and

d) prevalence of specific tooth types lost antemortem – the total number of a specific tooth type lost antemortem divided by the total number of the specific teeth present before AMTL.

The frequency of bony evidence of periapical granulomata and -cysts, chronic periapical abscesses and periodontal disease was also documented. Although these pathological conditions do not by themselves inform investigators about the specific questions under investigation, such as the diet of the population, they do add to the general picture of dental health of the sample being studied and therefore can often aid in explaining patterns observed in the prevalence of dental caries and AMTL observed in study populations.

A periapical granuloma could be recognized by the formation of a small bony cavity around the apex of the tooth root. Bony lesions resulting from granuloma formation are rather small - approximately 2-3 mm in diameter with allowance made for the portion of the cavity which is filled by the root tip. Similar lesions, but larger in size, result from periapical cysts. These develop through the replacement of granulation tissue by fluid, which is present in the periapical granuloma. When left untreated, the bony cavity where the cyst is located will slowly increase in size. Chronic periapical abscesses were recognized by evidence of infectious bony cavity formation connected to the exterior bone surface or a sinus by a small fistula (Dias & Tayles, 1997).

Bony evidence of periodontal disease was characterized by loss of the height of alveolar bone surrounding the teeth due to resorption of the alveolar processes. This is often accompanied by an inflammatory bone response resulting in a limbus along the alveolar edges (Hillson, 1998; Dias & Tayles, 1997; Ortner, 2003)

Dental enamel hypoplasia (EH) was recorded for each individual on all permanent teeth present. As enamel hypoplasia can manifest as horizontal lines, vertical grooves, pits and areas of missing enamel (King *et al*., 2002), the type of hypoplasia was also specified.

In cases where more than one defect was present on the tooth surface, it was still recorded as a single event. The frequency of enamel hypoplasia (EH) was calculated as the

proportions of individuals displaying the defect in relation to the total number of individuals examined. No attempt was made to calculate the intensity of EH per tooth type (the number of teeth affected by enamel hypoplasia from a specific tooth type divided by the total number of that specific tooth type examined), or to measure the distance between the hypoplastic lesions and the cemento-enamel junction, as this fell beyond the scope of this study (Hillson & Bond, 1997; Reid *et al.*, 2000).

7.3 Results

7.3.1 Dental caries

As can be seen in Table 7.1, 57% of males and 46.2% of females presented with one or more carious lesions. An average of 2.7 and 3.8 carious teeth per mouth was calculated for males and females respectively. It was concluded that an average dental caries intensity of 5.3% was present for males and 5.7% for females. No significant differences existed in the intensity of carious lesions between males and females ($\chi^2 = 0.085$, p –value > 0.5).

Using the method described by Lukacs (1995), a 'corrected caries intensity' was calculated for males and females to compensate for teeth lost antemortem due to dental caries. As a consequence, the caries intensity increased by 3% for males, totalling 8.3%, and 1% for females, totalling 6.6%. A significant difference existed between the observed dental caries intensity and the corrected caries rate for males ($\chi^2 = 16.203$, p–value < 0.001), but not for females ($\chi^2 = 0.322$, p-value > 0.5). Since none of the comparative studies available for South African populations used the caries correction factor, these results were not used in further comparative analyses.

The caries intensity was also calculated per tooth type. In general, carious lesions affected anterior teeth (incisors and canines) significantly less than posterior teeth (premolars and molars) ($\chi^2 = 57.295$, p -value < 0.01), as was expected. This is due to the difference in morphology of these teeth, with posterior teeth having fissures and crevices to which cariogenic substances can much easier adhere than on the smooth surfaces of the anterior teeth (Hillson, 1996).

The second molars were significantly more affected by carious lesions than any of the other teeth (χ^2 varies between 7.2 and 52.6, p -value < 0.01 for all), followed by the third molar, first molar and second premolar, although intensity differences between these teeth were not significant (see Table 7.2). The canine was the least affected tooth. No

significant difference in the distribution pattern of carious teeth was observed between males and females (see Table 7.2).

Table 7.1 Summary of prevalence of dental caries as observed in the Gladstone skeletal sample.

Variables	Caries frequency[1]			Lesions per mouth[2]			Caries intensity[3]		
	n	nia	%	nia	nta	c/m	nt	nta	%
Male	79	45	57.0	45	122	2.7	2291	122	5.3
Female	13	6	46.2	6	23	3.8	405	23	5.7
Total	92	51	55.4	51	145	2.8	2696	145	5.4

[1] total number of individuals affected by dental caries/total number of individuals present.
[2] total number of carious teeth/total number of individuals affected by dental caries.
[3]total number of carious teeth/total number of teeth present.
n=total number of individuals investigated, nia=total number of individuals affected with dental caries, nta=total number of teeth affected by dental caries, c/m=average number of carious lesions per mouth, nt= total number of teeth present.

Table 7.2 Caries intensity sorted by sex and tooth type. No significant differences observed between males and females.

Tooth	Male			Female			Total			
	n	na	%	n	na	%	n	na	%	χ^2
I1	275	2	0.7	51	2	3.9	326	4	1.2	3.622
I2	279	4	1.4	51	2	3.9	330	6	1.8	1.495
C	293	1	0.3	52	0	0.0	345	1	0.3	0.178
PM1	298	10	3.4	52	3	5.8	350	13	3.7	0.721
PM2	294	16	5.4	52	2	3.8	346	18	5.2	0.228
M1	280	19	6.8	52	6	11.5	332	25	7.5	1.423
M2	291	44	15.1	50	7	14.0	341	51	15.0	0.042
M3	281	26	9.3	45	1	2.2	326	27	8.3	2.523
Total	2291	122	5.3	405	23	5.7	2696	145	5.4	0.085

n=number of teeth investigated, na=number of teeth affected by carious lesions.
I=incisor, C=canine, PM=premolar, M=molar.

7.3.2 Periapical granulomata, -cysts and chronic periapical abscesses

Periapical granulomata and -cysts (see Fig. 7.1) were observed in 17.7% (N=14) of males and 15.4% (N=2) of females, with no significant difference existing between the

sexes (χ^2 = 0.042, p –value > 0.75). A total of 19 periapical granulomata, eight periapical cysts and two chronic periapical abscesses were observed in 16 individuals, with the majority presenting with two or more lesions. In general, posterior teeth (26 of the 29 cases) were significantly more affected than anterior teeth (χ^2 = 36.483, p –value < 0.001). The first molar was significantly more affected by granuloma formation than the incisors, canines and second premolars, with ten of the 29 lesions observed (χ^2 between 9.08 and 6.7, p -value < 0.05 for all), followed by the second molar and first premolar with five lesions each. Only one periapical granuloma was found associated with the canines and incisors and four third molars were affected.

Figure 7.1 Possible periapical cysts/abscesses affecting a) right mandibular second and third molars in female (33 – 43 years old) and b) left mandibular first molar in 25 – 30 year old male.

7.3.3 Bony evidence of periodontal disease

Bony evidence of periodontal disease was noted in 39.5% (N=30) of males and 53.8% (N=7) of females. No significant differences were observed in the prevalence between males and females (χ^2 = 0.94, p –value > 0.2). In previous research, it was found that 16 individuals possibly suffered from scurvy. Of these, seven showed signs of periodontal disease (43.8%) (Van der Merwe *et al.*, 2010c).

It should be kept in mind that scurvy, which was well documented in the sample population, often results in chronic gingivitis, which in turn will result in periodontal disease (Dias & Tayles, 1997; Hirschmann & Raugi, 1999; Pimentel, 2003). However, no significant difference existed in the prevalence of periodontal disease between individuals suffering from scurvy and those who did not. It should be noted that periodontal disease also develops due to neglected oral hygiene, which would have had a big influence on the prevalence of this condition in all individuals.

7.3.4 Antemortem tooth loss

Antemortem loss of one or more teeth (see Fig. 7.2) was observed in 30.4% and 23.1% of males and females respectively (see Table 7.3). This yielded an antemortem tooth loss (AMTL) intensity of 3.8% for males and 1.7% for females. Individuals who suffered from AMTL lost an average of 3.5 teeth per mouth. No significant difference existed in the prevalence of individuals affected by AMTL between males and females (χ^2 = 0.287, p -value > 0.5). However, a significant difference was present in the AMTL intensity between males and females, with males being significantly more affected (χ^2 = 6.974, p -value < 0.01).

As can be seen in Table 7.4, AMTL of the first molar (6.2% in total) was significantly more prevalent than the AMTL of any other tooth type (χ^2 values between 5.74 and 9.38, p -value < 0.02 for all when testing the frequency of AMTL of M1 against all other tooth types). However, in females, the second molar was most often affected by AMTL, whereas males showed most frequent loss of the first molar. Nevertheless, it should be kept in mind that only three females were affected by AMTL, making any conclusions regarding the

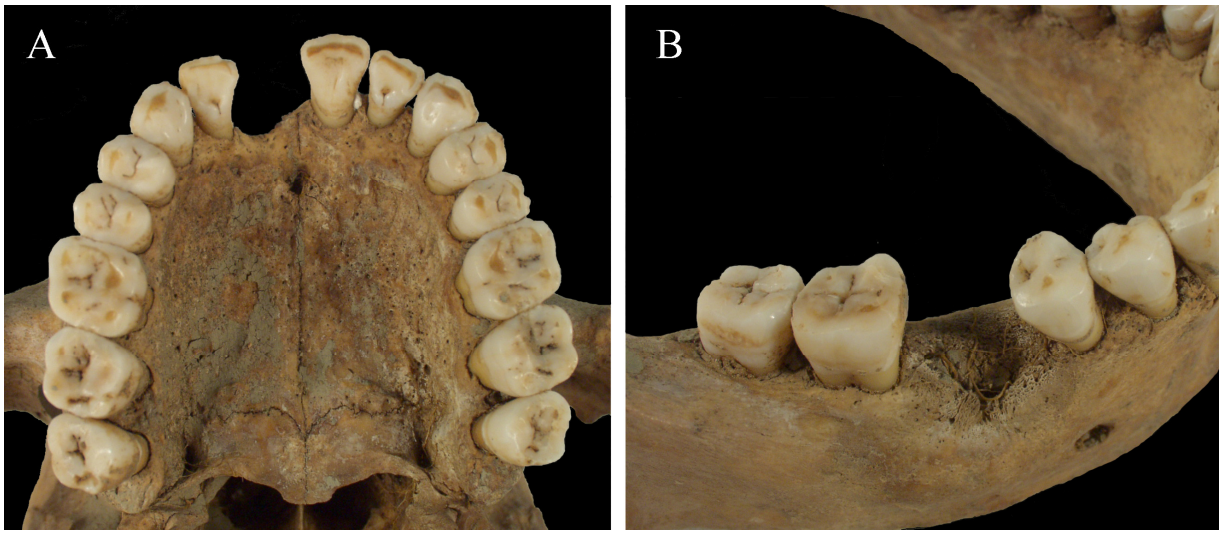

Figure 7.2 Antemortem tooth loss of right maxillary first incisor (a) with complete resorption of alveolar bone and b) antemortem tooth loss of right mandibular first molar shortly before death in a male, 30 – 40 years of age. Alveola only partially remodelled.

distribution of AMTL among females impossible. The rest of the molars and incisors followed the first molar, all being almost equally affected. Canines (1.7% in total) and premolars (1.4% and 2.5% respectively) were the least affected by AMTL.

Table 7.3 Summary of prevalence of antemortem tooth loss (AMTL).

	AMTL frequency[1]			AMTL per mouth[2]			AMTL intensity[3]		
Sex	n	nia	%	nia	nta	AMTL/m	nt	nta	%
Male	79	24	30.4	24	90	3.8	2381	90	3.8
Female	13	3	23.1	3	5	1.7	410	5	1.2
Total	92	27	29.3	27	95	3.5	2791	95	3.4

[1]total number of individuals with one or more teeth lost antemortem/total number of individuals present
[2] total number of teeth lost antemortem/total number of individuals present
[3] total number of teeth lost antemortem/total number of teeth present
n=number of individuals investigated, nia=total number of individuals with one or more teeth lost antemortem, nta=number of teeth lost antemortem, AMTL/m=average number of teeth lost antemortem per mouth, nt=number of teeth present before AMTL.

Table7.4 Antemortem tooth loss per tooth type.

	Male			Female			Total		
Tooth	n	na	%	n	na	%	n	na	%
I1	287	12	4.2	52	1	1.9	339	13	3.8
I2	290	11	3.8	52	1	1.9	342	12	3.5
C	299	6	2.0	52	0	0.0	351	6	1.7
PM1	303	5	1.7	52	0	0.0	355	5	1.4
PM2	303	9	3.0	52	0	0.0	355	9	2.5
M1	302	22	7.3	52	0	0.0	354	22	6.2
M2	304	13	4.3	52	2	3.8	356	15	4.2
M3	293	12	4.1	46	1	2.2	339	13	3.8
Total	2381	90	3.8	410	5	1.2	2791	95	3.4

n=total number of teeth present before AMTL, na=total number of teeth lost antemortem.
I=incisor, C=canine, PM=premolar, M=molar

7.3.5 *Enamel hypoplasia*

Enamel hypoplasia (EH) was noted in 15.2% (N = 14) of individuals (see Table 7.5). Of the 14 individuals with lesions, two showed evidence of pitting enamel hypoplasia (see Fig. 7.3a) while 12 exhibited cases of linear enamel hypoplasia (see Fig. 7.3b). No significant difference exists between the prevalence of this defect in males and females (χ^2 = 0.664, p-value > 0.25).

Table 7.5 Summary of the prevalence of enamel hypoplasia

Sex	n	na	%
Male	79	13	16.5
Female	13	1	7.7
Total	92	14	15.2

n=total number of individuals
na=total number of individuals affected by enamel hypoplasia.

Due to the skewed demographic composition of the skeletal sample and the fact that the population was historically documented to have been migrant workers who most likely did not develop EH in Kimberley, it was decided not to analyse the enamel hypoplasia results any further.

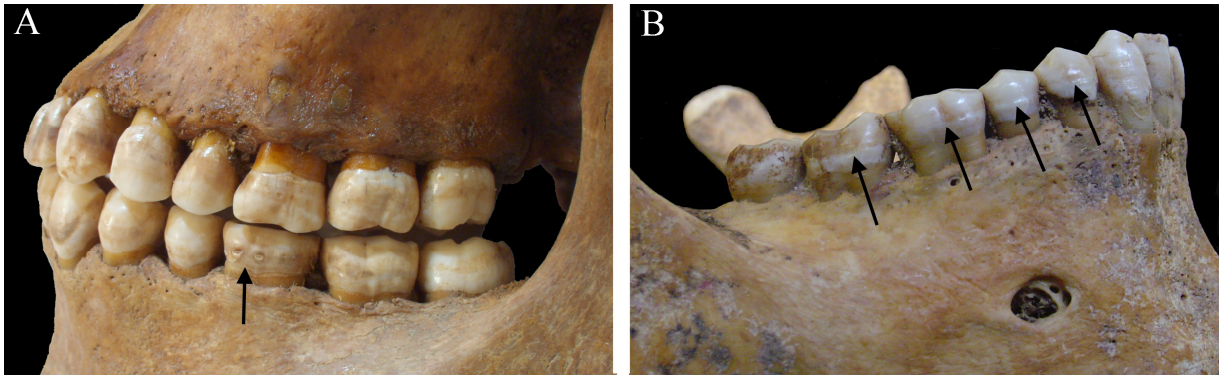

Figure 7.3 A) Teeth of a 22 – 28 year old male with pitted enamel hypoplasia, as indicated by arrow. B) Linear enamel hypoplasie (arrows) as seen in a 50 – 60 year old male.

7.4 Discussion

By 1898, diamond mining in Kimberley progressed from a single diamond found on a hill by an opportunistic private prospector, into a huge industry. Colesberg Kopje became Kimberley and the mine became the property of the De Beers Consolidated Mines (Kretschmer, 1998).

When mining activities commenced in Kimberley, all black labourers were given accommodation and food by their employers and were free to walk around town at will.

However, in 1885 a decision was made that the labourers should be confined to closed compounds for the duration of their contracts at the mine. Several reasons were put forward for this confinement, including prevention of unlawful diamond trading which would reduce the amount of diamonds stolen from the mine, limiting access to alcohol, ensuring workers would be fit for work each day, and the provision of an adequate food supply, which according to the authorities, was sure to instil health benefits (Roberts, 1976). Unfortunately, living conditions and diets in these camps did not live up to these expectations, with historical governmental and hospital documents indicating that death and disease were regular occurrences in the overcrowded compound sheds (Stoney, 1900; Jovhelson, 2001).

Historical documents indicated that the diets of mine workers housed in the compounds mainly consisted of maize meal and occasional coarse meat. There were also times when no food was supplied to workers and they were responsible for buying and preparing their own meals. However, these meals usually did not consist of much more than maize meal and sauce as the workers were not earning much and only certain foods could be purchased at the compound shop (Harries, 1994). Thus, the diets of these individuals are historically recorded to have been high in machine ground carbohydrates, low in animal proteins and low in fresh fruit and vegetables (Grusin & Samuel, 1957; Seftel *et al.*, 1966).

According to historical documents, migrant labourers came from all over South Africa and neighbouring countries to labour in the mines. Although differences in the diets between these traditional groups can be expected based on differing geographical locations and associated agricultural practices, all most likely followed a traditional agriculturalist diet, as most rural villages were located several days travel by foot from the nearest urban settlement from which supplies could be obtained (Oranje *et al.* 1935, Jovhelson, 2001). Such traditional diets were most likely high in self produced ground carbohydrates and vegetables, occasional meat and naturally occurring fruit, with limited access to varied amounts of machine ground carbohydrates and sugars, based on the socio-economic status of the rural group (Oranje *et al.* 1935).

As can be seen in Table 7.6, the Gladstone population had a much higher caries frequency (57%) when compared to a group who followed a traditional agricultural diet, such as the 'Primitive Xhosa' (36%), who consumed mainly whole cooked maize with no to occasional access to sugar ($\chi^2 = 12.6$, p-value < 0.05) .

Table 7.6 Prevalence of dental caries among various other South African young male skeletal populations.

	n	nia	nt	nta	Caries frequency %	Caries intensity %	Carious teeth/ mouth	Chi-square	Source
Gladstone	79	45	2291	122	57.0	5.3	2.7		this study
Agricultural-traditional									
Primitive Xhosa	465	167	-	385	35.9	-	2.3	12.6*	Oranje *et al*., 1935
Maroelabult	23	13	582	26	56.5	4.5	2.0	0.001	Steyn *et al*., 2002
Mine labourers									
Mine Xhosa	90	50	-	217	55.6	-	4.3	0.03	Oranje *et al*., 1935
Koffiefontein	24	21	1016	76	87.5	7.5	3.6	7.6*	L'Abbé *et al*., 2003
Agricultural-urban									
Urban Negro	331	298	9178	1312	90.0	14.3	4.4	134.8*	Staz,1938
Venda	-	-	305	35	-	11.5	-	17.92*	L'Abbé, 2005

* p-value < 0001, significant difference between previous study and results from Gladstone.
n=number of individuals investigated.
nia=total number of individuals with one or more tooth lost antemortem.
nt=number of teeth present before AMTL.
nta=number of teeth lost antemortem.

Table 7.7 Prevalence of dental caries as observed in groups following agricultural-traditional diet with varying amounts of sugar and refined carbohydrates.

	n	nia	nt	nta	Caries frequency %	Caries intensity %	Carious Teeth/ mouth	Chi-square	Source
Gladstone	79	45	2291	122	57,0	5,3	2,7		this study
Diet variation in primitive Xhosa									
No/occasional sugar	60	17	-	67	28	-	3,9	11.3*	Oranje *et al*., 1935
Regular sugar	61	42	-	129	69	-	3,1	1.5	Oranje *et al*., 1935
Unground maize	190	51	-	108	27	-	2,1	22.1*	Oranje *et al*., 1935
Machine ground maize	157	75	-	166	48	-	2,2	1.8	Oranje *et al*., 1935

* p-value < 0.05, significant difference between previous study and results from Gladstone.
n=number of individuals investigated.
nia=total number of individuals with one or more teeth lost antemortem.
nt=number of teeth present before AMTL.
nta=number of teeth lost antemortem.

In contrast, the caries intensity of the Gladstone skeletal population (5.3%) was significantly lower than that seen in populations with agricultural-urban diets such as the Venda (11.5%) and 'Urban Negro' (14.3%) (χ^2 = 17.9 and 134.8 respectively, p-value < 0.05 for both). These diets were most likely characterized by high quantities of refined carbohydrates and sugars, causing a dramatic increase in the number of individuals affected by dental decay.

The caries frequency, as was observed in the Gladstone skeletal sample, was statistically comparable to what was also recorded for the 'Mine Xhosa' (55.6%) (χ^2 = 0.03, p-value > 0.05), a contemporary living mining population of similar age distribution, as well as the caries frequency of the skeletal sample from Maroelabult (56.5%) (χ^2 = 0.001, p-value > 0.05). Interestingly, there were also no statistical difference in the caries frequencies between the Gladstone skeletal sample and the 'Primitive Xhosa', who followed a diet consisting mainly of ground maize (χ^2 = 1.8, p-value > 0.05) with regular consumption of sugar (χ^2 = 1.5, p-value > 0.05) (see Table 7.7).

It is of interest that the prevalence of dental caries is lower in the Gladstone sample when compared to the Koffiefontein population (87.5%), since both of these groups are late 19th century diamond mine workers. This difference may be due to the small sample size of the Koffiefontein skeletal sample, with only 36 skeletons being recovered and the teeth of only 24 individuals being available for investigation, or it could be that sugar and maize were more easily accessible to workers in the compounds where they were being housed.

The results and comparisons made for the prevalence of dental caries in the Gladstone sample suggest a diet similar to what has been described in the historical documents, and probably reflects a group of people who were experiencing changes in their eating patterns. The frequencies fit a diet high in ground carbohydrates with easier access to sugar than those following a strict agricultural-traditional diet such as the 'Primitive Xhosa', but definitely with more restricted access to sugar than those populations that were not limited to products available in the mining compounds, such as the Venda and the 'Urban Negro' (Oranje *et al*., 1935; Staz, 1938; L'Abbé, 2005).

As previously mentioned, the prevalence of dental caries also varies between groups following an agricultural-traditional diet with regards to their socioeconomic status and geographical location, as these two factor will influence whether refined carbohydrates and sugars were affordable and whether access to a larger town from which to obtain these products was available on a regular basis (Oranje *et al*., 1935). This is most likely the

reason why the prevalence of dental caries in the Gladstone sample was comparable to that observed in Maroelabult. Skeletal remains in the Maroelabult sample are believed to have been those of farm workers, most likely resulting in regular access to the products in question (Steyn *et al*., 2002). It should be kept in mind that there is still a significant difference between groups following agricultural-traditional and agricultural-urban diets and thus, although the prevalence of dental caries increases in the agricultural-traditional diet groups when their socioeconomic status changes, it does not reach the high levels observed in those groups residing in urban areas (Oranje *et al*., 1935; Staz, 1938). Accordingly, it can be suggested that, as was mentioned in historical documents, the majority of individuals investigated in the Gladstone study did not permanently reside in Kimberley. The migrant labourers were caught halfway between a traditional agricultural diet, which was followed in their rural homes, and the agricultural urban diet associated with the social and economic growth in Kimberley.

It can be suggested that the prevalence of carious lesions observed in this study was low for a carbohydrate rich diet as described in historical documents. This may be explained by the young age of most individuals within this sample, a traditional, less cariogenic diet when away from the mines, limited access to cariogenic food when working on the mines, or high fluoride levels in the drinking water (Sealy *et al*, 1992). Investigations showed that the fluoride concentrations of naturally occurring water in and around Kimberley are between 0.1 mg/l and 0.9 mg/l and within the optimal concentration levels to aid in the prevention of carious lesions (Silverstone *et al*., 1981). However, it should be considered that most individuals within this sample most likely did not originate from Kimberley and therefore may not have been exposed to optimal levels of fluoride in their drinking water during the period of tooth development. It has been suggested that, apart from the antibacterial function of fluoride in drinking water, the absorption of fluoride into the enamel of adult teeth may also aid in the prevention of dental caries. However, the absorption of fluoride into adult tooth enamel is dependant on the length of exposure, concentration levels, age of the individuals, as well as the different tooth surfaces under investigation (Tanaka *et al*., 1993; Li *et al.*, 1994; Hirose *et al*., 1996). It has accordingly been shown that the difference in absorbed enamel fluoride between groups exposed to water from a naturally fluoridated area and those from a non-fluoridated area is not significant and its influence in the prevention of dental caries is negligible (Li *et al.*, 1994).

The young age of the sample in conjunction with a low cariogenic diet is therefore a plausible explanation for the low caries rate, even though the sample population were working in an economically expanding environment with easier access to refined carbohydrates and sugars.

The first permanent molar is known to be the tooth most often affected by carious lesions in populations with a diet mainly consisting of refined carbohydrates and sugars (Henneberg, 1991). In general, it can be said that molars are the most affected, followed by premolars, incisors and canines (Hillson, 1998; Henneberg, 1991). The same distribution of carious lesions was observed in this study. Posterior teeth (molars and premolars) were significantly more affected by carious lesions than anterior teeth (incisors and canines). However, the highest prevalence of carious lesions was found on the second molar, and not on the first, as described by Henneberg (1991). This can most likely be explained by the pattern of antemortem tooth loss in the Gladstone skeletal sample, where the first molars were mostly affected, skewing the distribution of dental caries.

In order to compensate for antemortem tooth loss, a 'corrected caries intensity' was calculated. This method functions on the assumption that all teeth lost antemortem were due to the effects of either dental caries or dental wear (Lukacs, 1995). As was seen in the study done by Lukacs (1995) on the Harappa population, an increase in caries intensity was observed with the calculation of the 'corrected caries intensity'. The correction factor doubled the caries intensity in the Harappa sample (from 6.8% to 12.1%), but only a small increase in intensity was observed in this study (from 5.4% to 8.1%). The reason for only a slight increase can be associated with the relatively low intensity of teeth lost antemortem (3.4%). It is obvious that with a low intensity of antemortem tooth loss, the teeth present will be representative of the prevalence of carious lesions within the skeletal population sample.

Large carious lesions, severe periodontal disease, advanced dental attrition and trauma are usually responsible for antemortem tooth loss (Bonfigliolo *et al.*, 2003). In this population, in which very little attrition was observed, the antemortem loss of teeth can most probably be ascribed to carious activity.

Although a high prevalence of periodontal disease (in some cases probably as a result of scurvy) was observed within this sample, it could not be associated with the AMTL observed. The Gladstone skeletal sample presented with an average of only 3.5 teeth lost antemortem per individual affected by AMTL. It should be mentioned here that 63% of

those affected by AMTL lost only one or two teeth and that the average number of teeth lost antemortem was skewed by a single individual who was edentulous. By excluding this individual, the average number of teeth lost becomes even lower with an average of 2.5 teeth lost antemortem. Furthermore, the loss of consecutive teeth, which would be expected in cases where periodontal disease is responsible for the AMTL, was only observed in nine individuals (33%). Thus, although periodontal disease cannot be excluded as a possible cause of the AMTL observed in this population, the pattern of AMTL does suggest that tooth loss was, in the majority of cases, the result of dental caries.

A study by Lukacs (1992) showed that the antemortem loss due to dental caries mostly affects molars, with anterior teeth such as incisors and canines seldom being affected. An opposite pattern of tooth loss is observed in cases where teeth are willingly extracted for decorative or ritualistic purposes. When extractions are done for cosmetic purposes, the antemortem loss of anterior teeth is most often seen, since these teeth are the ones that are most visible (Morris, 1998). It has also been shown that carious lesions most often affect the first molar. This is probably because this is the first permanent molar to erupt and it is exposed to cariogenic factors longer than the other molars (Henneberg, 1991; Steyn, 1994). The frequent loss of the first molar seen in this study is possibly indicative of tooth extraction following dental caries (to alleviate pain) or natural avulsion due to severe carious activity. It is suggested that teeth were most likely not willingly extracted for decorative purposes, since the prevalence of AMTL of anterior teeth would then have been much higher (Morris, 1989).

Dental trauma cannot be excluded as a reason for AMTL within this population. It can be suggested, however, that it did not have a significant influence since anterior tooth loss was not commonly observed.

The high prevalence of bony evidence of periodontal disease and periapical-granulomata and -cysts also supports the hypothesis that this population had a diet consisting mainly of refined carbohydrates with access to sugar, as the prevalence of these conditions can be expected to increase as dental health (carious lesions) and dental hygiene decrease. Very little dental wear was observed in this population, and the majority of periapical-granulomata and -cysts formed as a result of periodontal disease and advanced stages of dental caries.

7.5 Conclusion

In conclusion, it can be said that the prevalence of dental caries observed in the Gladstone skeletal sample suggests a diet relatively high in machine ground carbohydrates, although most probably not highly refined carbohydrates, and concurs well with the historical accounts of a diet dominated by agricultural products such as maize meal. It probably also reflects the changing circumstances of the people in question, as they were caught somewhere in between their traditional eating habits and the more refined foods commonly associated with urban living. The young age of individuals within this population, the limited amount of time they spent in Kimberley as migrant labourers before returning to their traditional low cariogenic diets, as well as the restricted access labourers housed in the compounds had to products sold outside of the compound walls, all influenced the caries intensity observed in this sample population.

The antemortem loss of teeth observed in the Gladstone skeletal population is most likely the result of carious dental activity and periodontal disease associated with poor oral hygiene, although AMTL due to scurvy and dental trauma can not be excluded. No pattern suggesting dental mutilation was observed in this population.

The high prevalence of bony evidence of periapical granulomata, cysts and periodontal disease observed in this study supports the hypothesis of a carbohydrate rich diet and poor oral hygiene. Very little dental wear was observed, and the majority of periapical granulomata formed as a result of periodontal disease and advanced stages of dental caries.

References

Asala, S.A. 2001. Sex determination from the head of the femur of South African whites and blacks. *Forensic Science International* 117:15-22.

Bonfigliolo, B., Brasili, P. and Belcastro, M.G. 2003. Dento-alveolar lesions and nutritional habits of a Roman imperial age population (1st-4th c.AD): Quadrella (Molise, Italy). *Homo* 54:36-56.

Cleaton-Jones, P. 1979. Oral health of South African Black (Xhosa) mine recruits. *Oral Epidemiology* 7:288-291.

De Villiers, H. 1968. Sexual dimorphism of the skull of the South African Bantu-speaking Negro. *South African Journal of Science* 84:118-124.

Dias, G. and Tayles, N. 1997. 'Abscess cavity'- a misnomer. *International Journal of Osteoarchaeology* 7:548-554.

Franklin, D., Freedman, L. and Milne, N. 2005. Sexual dimorphism and discriminant function sexing in indigenous South African crania. *Homo* 55:213-228.

Grusin, H. and Samuel, E. 1957. A syndrome of osteoporosis in Africans and its relationship to scurvy. *Journal of Clinical Nutrition* 5:644-650.

Harries, P. 1994. *Work, Culture and Identity. Migrant Laborers in Mozambique and South Africa, 1860 - 1910.* Johannesburg: Witwatersrand University Press.

Henneberg, R.J. 1991. Dental caries. In: *Encyclopedia of Human Biology.* Dulbecco, R. (ed.). San Diego: Academic Press, pp.805.

Hillson, S.W. 1979. Diet and dental disease. *World Archaeology* 2:147-162.

Hillson, S.W 1998. *Dental Anthropology.* Cambridge: Cambridge University Press.

Hillson, S. and Bond, S. 1997. Relationship of enamel hypoplasia to the pattern of tooth crown growth: a discussion. *American Journal of Physical Anthropology* 104:89-103.

Hirschmann, J.V. and Raugi, G.J. 1999. Adult scurvy. *Journal of the American Academy of Dermatology* 41:895-909.

Hirose, M.N., Tange, T., Igarashi, S., Hirose, Y. and Nakagaki, H. 1996. In vivo fluoride profiles at different sites of buccal and lingual enamel surfaces obtained by enamel biopsy of human maxillary first permanent molars in young adults. *Archives of Oral Biology* 41:1187-1190.

Jochelson, K. 2001 *The Colour of Diseases, Syphilis and Racism in South Africa 1880 - 1950*. New York: Palgrave.

King, T., Hillson, S. and Humphrey, L.T. 2002. A detailed study of enamel hypoplasia in a post-medieval adolescent of known age and sex. *Archives of Oral Biology* 47:29-39.

Kretschmet, T. 1998. *De Beers and Beyond: The History of the International Diamond Cartel*. London: London Business School.

Krogman, W.M. and İşcan, M.Y. 1986. *The Human Skeleton in Forensic Medicine*, 2nd ed. Springfield: Charles C Thomas.

L'Abbé, E.N., Henderson, Z.L. and Loots, M. 2003. Uncovering the nineteenth-century typhoid epidemic at the Koffiefontein Mine, South Africa. *World Archaeology* 35:306-318.

L'Abbé, E.N. 2005. *A palaeodemographic, paleopathologic and macrophologic study of the 20th century Venda.* Ph.D. thesis, University of Pretoria.

Li, J., Nakagaki, H., Tsuboi, S., Kato, S., Huang, S., Mukai, M.. Robinson, C. and Strong, M. 1994. Fluoride profiles in different surfaces of permanent molar enamels from a naturally fluoridated and a non-fluoridated area. *Archives of Oral Biology* 39:727-731.

Lukacs, J.R. 1989. Dental paleopathology: methods for reconstructing dietary patterns. In: *Reconstruction of Life from the Skeleton*, 1st ed. İşcan, MY (ed.). New York: Alan R.Liss, pp. 261.

Lukacs, J.R. 1992. Dental paleopathology and agricultural intensification in South Asia: new evidence from the Bronze Age Harappa. *American Journal of Physical Anthropology* 87:133-150.

Lukacs, J.R. 1995. The 'caries correction factor': a new method of calibrating dental caries rates to compensate for antemortem loss of teeth. *International Journal of Osteoarchaeology* 5:151-156.

Maat, G.J.R. and Van der Velde, E.A. 1987. The caries-attrition competition. *International Journal of Anthropology* 2:281-292.

McNish, J.T. 1970. *The Glittering Road*. Cape Town: C. Struik.

Morris, A.G. 1989. Dental mutilation in historic and prehistoric South Africa. *Quaterly Bulletin of the South African Library* 43:132-134.

Morris, A.G. 1992. *The Skeletons of Contact. A Study of Protohistoric Burials from the Lower Orange River Valley, South Africa.* Johannesburg: Witwatersrand University Press.

Morris, A.G. 1998. Dental mutilation in Southern African history and prehistory with special reference to the "Cape Flats Smile". *Journal of the South African Dental Association* 53:179-183.

Oettlé, C. and Steyn, M. 2000. Age estimation from sternal ends of ribs by phase analysis in South African blacks. *Journal of Forensic Sciences* 45:1071-1079.

Oranje, P., Noriskin, J.N. and Osborn, T.W.B. 1935. The effect of diet upon dental caries in the South African Bantu. *The South African Journal of Medical Science* 1:57-62.

Ortner, D.J. 2003. *Identification of Pathological Conditions in Human Skeletal Remains*, 2nd ed. Amsterdam: Academic Press.

Pimental, L. 2003. Scurvy: historical reviews and current diagnostic approach. *American Journal of Emergency Medicine* 21:328-332.

Reid, D.J. and Dean, M.C. 2000. Brief communication: the timing of linear hypoplasias on human anterior teeth. *American Journal of Physical Anthropology* 113:135-139.

Roberts, B. 1976. *Kimberley Tubulent City.* Capetown: Pioneer Press.

Roberts, C. and Manchester, K. 1995. *The Archaeology of Disease*, 2nd ed. Stroud: Alan Sutton.

Sealy, J.C., Patrick, M.K., Morris, A.G. and Alder, D. 1992. Diet and dental caries among later stone age inhabitants of the Cape Province, South Africa. *American Journal of Physical Anthropology* 88:123-134.

Seftel, H.C., Malkin, C., Schmaman, A., Abrahams, C., Lynch, S.R., Charlton, R.W. and Bothwell, T.H. 1966. Osteoporosis, scurvy and siderosis in Johannesburg Bantu. *British Medical Journal* 1:642-646.

Staz, J. 1938. Dental caries in South Africa. *The South African Medical Journal* 3:1–63.

Steyn, M. 1994. *An Assessment of the Health Status and Physical Characteristics of the Prehistoric Population from Mapungubwe*. Ph.D. thesis, University of Witwatersrand.

Steyn, M., Nienaber, W.C., and Meiring, J.H. 2002. An assessment of the health status and physical characteristics of an early 20th century community at Maroelabult in the North West Province, South Africa. *Homo* 53:131-145.

Stoney, W.W. 1900. *Report of the Medical Officer of Health, Kimberley, for the Year 1898*. Unpublished report.

Swanepoel, S. 2003. *Gladstone Cemetery, 1880s to 1900s. Archival report*.

Tanaka, M., Moreno, E.C. and Margolis, H.C. 1993. Effect of fluoride incorporation into human dental enamel on its demineralization in vitro. *Archives of Oral Biology* 38:863-869.

Turner, C.G. 1979. Dental anthropological indications of agriculture among the Jomon people of Central Japan. *American Journal of Physical Anthropology* 51:619-636.

Turrell, R. 1984. Kimberley's Model Compounds. *The Journal of African History* 25:59-75.

Van der Merwe, A.E., Maat, G.J.R. and Steyn, M. 2010a. Histomorphological observations of pathological lesions on the anterior tibiae of individuals from a 19th century mining community in Kimberley, South Africa. *International Journal of Osteoarchaeology* DOI: 10.1002/oa.1026.

Van der Merwe, A.E. Steyn, M. and L'Abbé, E.N. 2010b. Trauma and amputations in 19th century miners from Kimberley, South Africa. *International Journal of Osteoarchaeology*. DOI: 10.1002/oa.1035.

Van der Merwe, A.E., Steyn, M. and Maat, G.J.R. 2010c Adult scurvy in skeletal remains from late 19th century mineworkers from Kimberley, South Africa. *International Journal of Osteoarchaeology* DOI: 10.1002/oa.1037.

Worger, W.H. 1987. *South Africa's City of Diamonds: Mine Workers and Monopoly Capitalism in Kimberley, 1867-1895*. Craighall: AD. Donker.

CHAPTER 8

The High Prevalence of Supernumerary Teeth in Skeletal Remains from a 19th Century Mining Community from Kimberley, South Africa

Modified from article published as:

A report on the high incidence of supernumerary teeth in skeletal remains from a 19th century mining community from Kimberley, South Africa

A.E. van der Merwe and M. Steyn

South African Dental Journal (2009)

64(4):162 – 166

Kimberley Market Square, 1895
(McGregor Museum Kimberley Photography nr.8681)

Gowie Brothers & Co., Kimberley, 1890s
(McGregor Museum Kimberley Photography nr.954_001)

Abstract

Supernumerary teeth can be described as the presence of more than 20 deciduous or 32 permanent teeth in one individual. This condition occurs in 0.1 - 3.7% of individuals within most populations. The purpose of this study was to examine the prevalence of hyperdontia in a 19th century mining community from Kimberley.

The Sol Plaatje municipality disturbed several unmarked graves outside the fenced Gladstone cemetery in Kimberley, South Africa. The remains belonged to mine workers and other individuals who died in the Kimberley and surrounding hospitals between 1897 and 1900. The well-preserved teeth of 76 adult males and 13 adult females were examined and counted.

Supernumerary teeth were documented in 6.7% (N = 6) of the study population. This is high considering the prevalence of this condition in other population groups. Two of the seven individuals affected by the condition presented with multiple non-syndromal supernumerary teeth.

The Gladstone sample population was primarily composed of migrant workers, and it is proposed that, although several factors may influence the development of supernumerary teeth, the possibility of a genetic relationship between some of these individuals should be considered to be responsible for the high prevalence of hyperdontia in this sample population.

8.1 Introduction

Supernumerary teeth, or hyperdontia, can be recognized by the presence of more than 20 deciduous, or 32 permanent teeth in one individual (Ortner, 2003; Ramsaram *et al.,* 2005; Montenegro *et al.*, 2006; Orhan *et al.,*2006, Proff *et al.,* 2006; Refoua & Arshad, 2006; Gündüz & Muğlali, 2007). Hyperdontia can develop either due to the retention of deciduous teeth or the development of extra deciduous and permanent teeth resulting from a derangement in the process of organogenesis (Łangowska-Adsmczyk & Karmańska, 2001; Ortner, 2003). The aetiology of these teeth is uncertain, but various causes for their presence such as atavism, dichotomy of the tooth germ, excessive growth of the dental lamina, heredity factors and general diseases have been suggested (Fastlicht, 1943; Brook, 1982; Mason *et al*., 2000).

The development of extra permanent teeth can be classified as "heterotopic" - teeth developing outside the alveolar region or "normotopic". The latter includes teeth that develop in the alveolar region and erupt in a relatively normal orientation (Ortner, 2003). Much variation in the morphology of supernumerary teeth has also been described (Fastlicht, 1943; Ashkenazi *et al*., 2007). These teeth may be normal in shape and size, normal in shape but reduced in size, of conical shape or, lastly, abnormal in shape as well as reduced in size (a denticle) (Fastlicht, 1943).

Single or multiple supernumerary teeth can be unilateral or bilateral (Ramsaram *et al*., 2005; Orhan AI *et al*., 2006; Refoua & Arshad, 2006) and it has been shown that the anterior maxilla and mandibular premolar regions are most commonly affected (Stafne, 1932; Luten, 1967; Mitchell, 1989; Shapira & Kutienic, 1989; Scheiner & Sampson, 1997; Rajab & Hamdan, 2002; Ramsaran *et al*., 2005). Multiple supernumerary teeth most often affect the mandibular premolar region (Stafne, 1932; Luten, 1967; Shapira & Kutienic, 1989; Yusof, 1990; Rajab & Hamdan, 2002; Ramsaran, 2005).

The purpose of this study was to examine and explain the prevalence of hyperdontia in a 19th century mining community from Kimberley, South Africa.

8.2 Materials and Methods

In April 2003, the Sol Plaatje municipality dug a trench for proposed water lines and disturbed a number of unmarked graves outside the fenced Gladstone cemetery in Kimberley, South Africa. A total of 107 well preserved skeletons was exhumed.

Historical records indicated that the remains were most likely those of black migrant workers who died in the Kimberley and compound hospitals between 1897 and 1900 (Stoney, 1900). The individuals were of low socioeconomic status, malnourished and exposed to a high pathogen load, as could be deducted from the high prevalence of infective and nutritional diseases described in hospital records (Stoney, 1900). Skeletal investigations concurred with these records, with several individuals presenting with lesions indicative of scurvy, treponematosis, tuberculosis, trauma and amputations (van der Merwe, 2007). After death these individuals received paupers' burials, without coffins, in graves mostly containing more than one individual.

Standard anthropometric techniques such as cranial morphology, the width of the pubic angle, morphological changes of the sternal ends of the ribs and discriminant functions were used to determine the age and sex of all individuals exhumed from the trench (De Villiers, 1968; Krogman & İşcan, 1986; Hillson, 1998; Oettlé & Steyn, 2000; Asala, 2001; Franklin *et al*., 2005). Based on these results, the sample consisted of 86 males, 15 females and 6 individuals of unknown sex. The majority of individuals exhumed were between 20 and 49 years of age at the time of death. Three children, 13 adolescents and four individuals older than 50 years were also found. Due to the fragmentary condition of some skeletons, 10 males and 2 females were excluded from the study. The teeth of 76 adult males and 13 adult females were examined and counted in order to determine whether any extra permanent teeth were present. The results were compared to various other studies.

8.3 Results

Supernumerary teeth were recorded in 6.7% (N = 6) of the individuals in this study population. This is high when considering that prevalences between 0.1 and 3.7% have been recorded for western population groups (Ramsaran *et al*., 2005; Montenegro *et al*., 2006, Güdnüz & Muğlali, 2007; Scheiner & Sampson, 1997; Yusof, 1990; Taylor, 1972; Altug-Atac & Erdem, 2007).

Although only one female and five males were affected by hyperdontia, no significant difference ($\chi^2 = 0.023$, p-value > 0.05) could be found in the prevalence of supernumerary teeth between the sexes.

Figure 8.1 Maxillary teeth of a female, 19-23 years (GLD N100.5). An extra premolar is present on right side of maxillary arch.

Three individuals (GLD N100.5, GLD N8.10 and GLD SE12.2) presented with parapremolars (see Table 8.1). Individual GLD N100.5 had a fully developed upper right parapremolar (see Figure 8.1), while GLD SE12.2 had a fully developed lower right parapremolar (see Figure 8.2). Although no crowns were present, roots suggesting rudimentary developed parapremolars/ denticles (see Figure 8.3) were visible next to the upper right second premolar of GLD N8.10.

Two individuals (GLD SE7.7 and GLD SE7.8) presented with rudimentary developed supernumerary molars (denticles). A single rudimentary developed distomolar/denticle was visible behind the upper right third molar in individual GLD SE7.8 (see Figure 8.4). GLD SE7.7 presented with three rudimentary extra molars/denticles (see Figure 8.5). These supernumerary teeth were very similar in morphology and location to that of GLD SE7.8 and GLD 8.10.

Possible multiple impacted teeth were observed in GLD SE11.5. Macroscopic investigation and X-rays revealed that these teeth, embedded in the mandibular body underneath the permanent right second incisor and canine, were most likely at least two premolars (see Figure 8.6).

Figure 8.2 Mandibular teeth of a 20-40 year old male (GLD SE12.2). Extra premolar present on the right.

Figure 8.3 Maxillary teeth of a possible male, 20-24 years old (GLD N8.10). Two rudimentary developed extra premolars present next to second upper right premolar.

Table 8.1 Summary of supernumerary teeth observed in the Gladstone skeletal sample.

Nr.	Age (years)	Sex	Location	Description of supernumerary tooth/teeth
GLD N100.5	19-23	F	Max.	Parapremolar
GLD N8.10	20-24	M	Max.	Rudimentary parapremolar*
GLD SE7.7	20-25	M	Max.	Three rudimentary developed distomolars and paramolars
GLD SE7.8	35-45	M	Max.	Rudimentary distomolar
GLD SE11.5	20-25	M	Mand.	Three impacted premolars
GLD SE12.2	20-40	M	Mand.	Parapremolar

M=male, F=female, Mand.=Mandibular, Max.=Maxillary

* Only roots present

Figure 8.4 Maxillary teeth of a male, 35-45 years (GLD SE7.8). Rudimentary developed extra molar present behind upper right third molar.

It is also possible that these teeth may in fact be a compound odontome. Should this case be excluded from the study due to this possibility, the prevalence of supernumerary teeth will still be 5.6% in the Gladstone population sample, and accordingly still higher than expected.

As shown in Table 8.1, supernumerary teeth most often occurred in the maxilla, although it was not significantly more affected than the mandible (χ^2 = 0.133, p-value > 0.2). Supernumary premolars were most commonly

Figure 8.5a Maxillary teeth of a possible male, 20-25 years of age (GLD SE7.7) showing two extra teeth on the left and a probable fourth molar on the right half of maxillary arch. 5b. Lateral view of the supernumerary teeth on the left.

observed, followed by supernumary molars. No extra incisors or canines were observed. All supernumerary teeth involved the permanent dentition and no extra teeth were observed as a result of retained deciduous teeth.

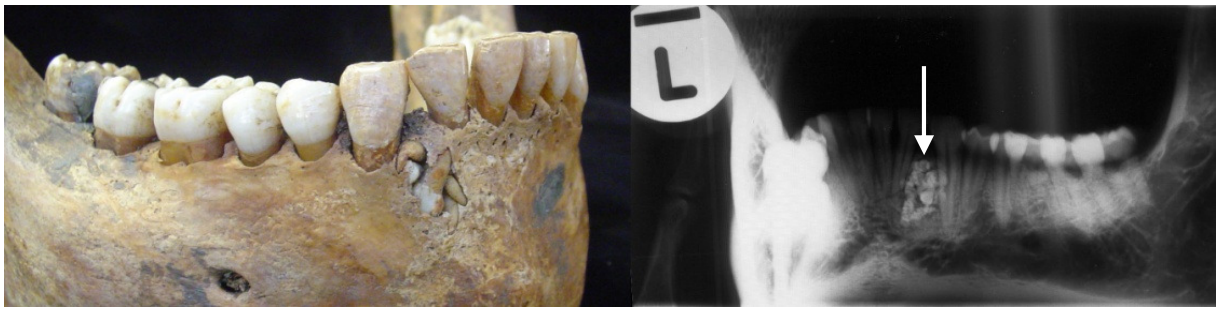

Figure 8.6 Impacted supernumerary teeth/possible odontome. Mandible of a male, 20-25 years (GLD SE11.5). Several extra teeth impacted underneath lateral incisor and canine on right side of mandible (indicated by arrow on x-ray).

8.4 Discussion

It has been reported that males are significantly more affected by supernumerary teeth than females (Scheiner & Sampson, 1997; Ramsara *et al*., 2005; Montenegro *et al*., 2006; Orhan *et al*., 2006; Proff *et al*., 2006; Refoua & Arshad, 2006). Although only one female and five males were affected by supernumerary tooth development in this population sample, no significant difference between the sexes could be detected. This can most likely be ascribed to the small sample size and poor sex distribution within this sample.

According to previous studies, supernumerary upper central incisors are the most common form of hyperdontia (Stafne, 1932; Luten, 1967; Shapira & Kutienic, 1989; Scheiner & Sampson, 1997; Rajab & Hamdan, 2002). It is interesting to note that none of the supernumerary teeth in the Gladstone population was in the anterior maxilla. All cases recorded in this study involved the premolar and molar regions, making these cases all the more unusual.

It has been shown that a single supernumerary tooth is found more often than two or multiple extra teeth (Orhan *et al*., 2006). In this study, two individuals (2.2%) had multiple supernumerary teeth (see Figure 8.2). This was remarkable, as it was reported that usually only 1% of the population presents with multiple extra teeth (Orhan *et al*., 2006). Individual GLD SE7.7 had three extra hypoplastic molars and individual GLD SE11.5 had several impacted teeth in the mandibular body (see Figure 8.6). It should be mentioned here that the feature observed in GLD SE11.5 may also be a compound odontome. An

odontome can be defined as a 'non-neoplastic, developmental anomaly or malformation that contains fully formed enamel and dentine' (Soames & Southern, 1988. pp.212). Although several clinical studies describing odontomes have been published, very few palaeopathological cases have been reported - one being a compound odontome from medieval Canterbury, Kent (Anderson & Andrews, 1993).

Unfortunately, the supernumerary teeth/odontome could not be removed from the mandible due to ethical constraints and no further x-ray examination could be done to allow better visualization of the feature. For the purpose of this study, this dental anomaly was counted as a supernumerary tooth. But, even with the exclusion of this case, the prevalence of supernumerary teeth within this population will still be higher than has been reported in any other study.

Results indicated that the number of individuals affected by supernumerary teeth in the Gladstone population was higher than what would be expected. Brown (1990) and Zhu *et al.* (1996) noted that there is a slightly higher prevalence of supernumerary teeth among sub-Saharan and Asian populations, ranging between 2.7% and 3.4% (Taylor, 1972; Brown, 1990; Montenegro *et al*., 2006). Although it can be expected that most, if not all individuals in this sample were sub-Saharan descendents, this does not seem like a plausible explanation for the higher prevalence.

Another reason for the high frequency of hyperdontia, especially in cases with multiple supernumerary teeth, can be the presence of syndromes. Besides the variation in tooth number amongst the 'normal' population, multiple supernumerary teeth generally occur as part of a pathological syndrome such as a cleft lip and palate, Gardner's syndrome, cleidocranialis dysplasia, Fabry-Anderson syndrome and Ehler-Danlos syndrome (Montenegro *et al*., 2006; Orhan *et al*., 2006; Proff *et al*., 2006; Refoua & Arshad, 2006; Gündüz & Muğlali, 2007).

It has been shown that multiple supernumerary teeth are rarely seen without being associated with systemic conditions or syndromes (Orhan *et al*., 2006; Gündüz & Muğlali, 2007). However, no skeletal lesions indicative of the conditions mentioned were observed in the Gladstone sample.

It should be kept in mind that since this sample population comes from the Kimberley and other surrounding hospitals, they will have a selection towards a higher prevalence of pathology and trauma. This is especially true when interpreting the prevalence of fractures, amputations and infectious diseases, since all of these conditions are reasons for

hospitalization. Since hyperdontia in itself would not lead to hospitalization, and no syndromes which could lead to hospitalization of patients who would be more prone to developing supernumerary teeth were detected, it can be assumed that the frequency of this condition in the sample is representative of the once living population the sample came from.

The Gladstone sample most likely came from a larger migrant working population, with the majority being young men. It was clearly stated in historical documents that men travelled to Kimberley in search of work, and that they would normally return to their home village once their contracts expired (Roberts, 1976). In cases where multiple supernumerary teeth do occur without relation to another disorder, it has been shown to have a strong familial occurrence (Brook, 1982; Fastlicht, 1943; Becker *et al*., 1982; Marya & Kumar, 1998; Łangowska-Adamczyk & Karmańska, 2001; Batra *et al*., 2005; Orhan *et al*., 2006; Refoua & Arshad, 2006). It is thus possible that the high prevalence of supernumerary teeth in this sample indicates that some of the individuals were genetically related. The morphological similarity of the supernumerary teeth, as was seen in individuals GLD N8.10, GLD SE7.7 and GLD SE7.8, supports possible genetic connections between the individuals in this sample. A possible genetic relationship between some of the individuals affected with hyperdontia in this sample may also explain the unusual distribution of these teeth, with all affecting the premolar and molar regions and no individuals presenting with the commonly observed upper anterior supernumerary teeth.

In summary, six individuals (6.7%) from a 19th century skeletal population were found to have had extra teeth. Most of these occurred in the form of extra premolars, but two with supernumerary molars were also found. Although it is possible that this is just a random occurrence, or that the syndromes responsible for these supernumerary teeth could not be detected from skeletal remains alone, the possibility of a genetic relationship between some of these individuals should be considered as likely.

References

Altug-Atac, A.T. and Erdem, D. 2007. Prevalence and distribution of dental anomalies in orthodontic patients. *American Journal of Orthodontics and Dentofacial Orthopedics* 131:510-514.

Anderson, T. and Andrews, J. 1993. A recently excavated odontome from medieval Canterbury, Kent. *International Journal of Osteoarchaeology* 3:99-104.

Asala, S.A. 2001. Sex determination from the head of the femur of South African whites and blacks. *Forensic Science International* 117:15-22.

Ashkenazi, M., Greenberg, B.P., Chodik, G. and Rakocz, M. 2007. Postoperative prognosis of unerupted teeth after removal of supernumerary teeth or odontomas. *American Journal of Orthodontics and Dentofacial Orthopedics* 131:614-619.

Batra, A., Duggal, R. and Parkash, H. 2005 Non-syndromic multiple supernumerary teeth transmitted as an autosomal dominant trait. *Journal of Oral Pathology and Medicine* 34:621-625.

Becker, A., Bimstein, E. and Shteyer, A. 1982. Interdisciplinary treatment of multiple unerupted supernumerary teeth: report of a case. *American Journal of Orthodontics* 81:417-422.

Brook, A.H. 1982. A unifying aetiological explanation for anomalies of human tooth number and size. *Archives of Oral Biology* 29:373-378.

Brown, A. 1990. Supplemental and congenitally absent premolar teeth. *British Dental Journal* 169:150.

De Villiers, H. 1968. Sexual dimorphism of the skull of the South African Bantu-speaking Negro. *South African Journal of Science* 84:118-124.

Fastlicht, S. 1943. Supernumerary teeth and malocclusion. *American Journal of Orthodontics and Oral Surgery* 29:623-637.

Franklin, D., Freedman, L. and Milne, N. 2005. Sexual dimorphism and discriminant function sexing in indigenous South African crania. *Homo* 55:213-228.

Gündüz, K. and Muğlali, M. 2007. Non-syndrome multiple supernumerary teeth: a case report. *Journal of Contemporary Dental Practice* 8:1-5.

Hillson, S. 1998. *Dental Anthropology.* Cambridge: Cambridge University Press.

Krogman, W.M. and İşcan, M.Y. 1986 *The Human Skeleton in Forensic Medicine*, 2nd ed. Springfield: Charles C Thomas.

Łangowska-Adamczyk, H. and Karmańska, B. 2001. Similar location of impacted and supernumerary teeth in monozygotic twins: a report of 2 cases. *American Journal of Orthodontics and Dentofacial Orthopedics* 119:67-70.

Luten, J.R. 1967. The prevalence of supernumerary teeth in primary and mixed dentitions. *ASDC Journal of Dentistry for Children* 34:346-353.

Marya, C.M. and Kumar, B.R. 1998. Familial occurrence of mesiodentes with unusual findings: case report. *Quintessence International* 106:366-367.

Mason, C., Azam, N., Holt, R.D. and Rule, D.C. 2000. A retrospective study of unerupted maxillary incisors associated with supernumerary teeth. *British Journal of Oral and Maxillofacial Surgery* 38:62-65.

Mitchell, H. 1989. Supernumerary teeth. *Dental Update* 16:65-69.

Montenegro, P.F., Castellón, E.V., Aytés, L.B. and Escoda, C.G. 2006. Retrospective study of 145 supernumerary teeth. *Medicina Oral, Patología Oral y Cirugía Bucal* 11:E339-E344.

Oettlé, C. and Steyn, M. 2000. Age estimation from sternal ends of ribs by phase analysis in South African blacks. *Journal of Forensic Sciences* 45:1071-1079.

Orhan, A.I., Özer, L. and Orhan, K. 2006. Familial occurrence of non-syndromal multiple supernumerary teeth. *Angle Orthodontist* 76:891-897.

Ortner, D.J. 2003. *Identification of Pathological Conditions in Human Skeletal Remains*, 2nd ed. Amsterdam: Academic Press.

Proff, P., Fanghanel, J., Allegrini, Jr., S., Bayerlein, T. and Gedrange, T. 2006. Problems of supernumerary teeth, hyperdontia or dentes supernumerarii. *Annals of Anatomy* 188:163-169.

Rajab, L.D. and Hamdan, M.A.M. 2002. Supernumerary teeth: review of the literature and a survey of 152 cases. *International Journal of Paediatric Dentistry* 12:244-254.

Ramsaran, A.S., Barclay, S., Scipio, E. and Ogunsalu, C. 2005. Non-syndromal multiple buried supernumerary teeth. *West Indian Medical Journal* 52:334 - 336.

Refoua, Y. and Arshad, M. 2006. An unusual case of bilateral maxillary and mandibular supernumerary teeth. *Journal of Dentistry* 3: 140-142.

Roberts, B. 1976. *Kimberley Turbulent City*. Cape Town: Pioneer Press.

Scheiner, M.A. and Sampson, W.J. 1997. Supernumerary teeth. A review of the literature and four case reports. *Australian Dental Journal* 42:160-165.

Shapira, Y. and Kutienic, M.M. 1989. Multiple supernumerary teeth: report of two cases. *American Journal of Dentistry* 2:28-30.

Soames, J.V. and Southern, J.C. 1988. *Oral Pathology* 206:212-213.

Stafne, E.C. 1932. Supernumerary teeth. *Dental Cosmos* 27:360-362.

Stoney, W.W. 1900. *Annual Report of the Medical Officer of Health, Kimberley, for the Year, 1899 and 1900.*

Taylor, G.S. 1972. Characteristic of supernumerary teeth in the primary and permanent dentition. *The Dental Practitioner and Dental Record* 22:203-208.

Van der Merwe, A.E. 2007. Human Skeletal Remains from Kimberley: An Assessment of Health in a 19th Century Mining Community. Unpublished MSc. Thesis, University of Pretoria.

Yusof, N.Z. 1990. Non-syndromal multiple supernumerary teeth: literature review. *Journal of the Canadian Dental Association* 56:147-149.

Zhu, J., Marcushamer, M., King, D. and Henry, R. 1996. Supernumerary and congenitally absent teeth: a literature review. *Journal of Clinical Pediatric Dentition* 20:87-95.

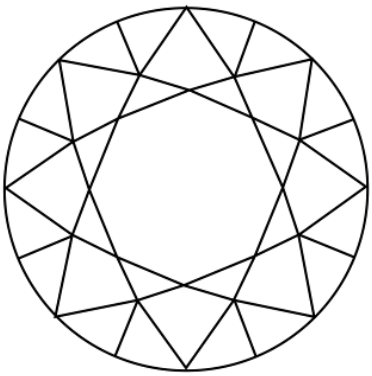

CHAPTER 9

The origins of late nineteenth-century migrant diamond miners uncovered in a salvage excavation in Kimberley, South Africa

Modified from article accepted for publication as:

The origins of late nineteenth-century migrant diamond miners uncovered in a salvage excavation in Kimberley, South Africa

A.E. Van der Merwe, I. Ribot, D. Morris, M. Steyn, G.J.R. Maat

South African Archaeological Bulletin



Individuals housed in the De Beers mine compound
(McGregor Museum Kimberley Photography nr.4606)

Cyclists with Kimberley mine shaft in background
(McGregor Museum Kimberley Photography nr.5918)

Abstract

The metric analysis of phenotypic variation observed in human skeletons is valuable for the determination of biological relatedness or ancestry, particularly when testing specific hypotheses concerning the possible ancestry of individuals from unmarked graves.

The purpose of this paper is to determine the possible ancestry of unknown individuals excavated from an area next to the fenced Gladstone Cemetery in Kimberley, South Africa, using cranio-morphometry. The skeletons are thought to be those of migrant diamond mine labourers who died between 1897 and 1900. Two historical statements will be tested: Firstly that black labourers came to work in Kimberley from various regions in Africa south of the equator and secondly that the local Khoe-San people did not participate in significant numbers as mine workers.

Standard craniometric measurements were taken from 59 well preserved male crania. These measurements were compared to craniometric data of eight modern and archaeological groups of males of known origin from Africa and Asia. Descriptive as well as univariate and multivariate statistical analyses were performed using SPSS. Eleven craniometric variables were selected for analysis.

Results obtained are in accord with the historical documents stating that the majority of labourers at the Kimberley mines were migrant workers and that the local communities (including Khoe-San) did not contribute much to the workforce. Many of the labourers came from elsewhere in southern Africa (e.g. Kwa-Zulu/Natal), but some may have originated from further afield. The heterogeneous nature of the sample reflects the varied origins of workers in Kimberley as well as some possible genetic admixture. This study reiterates the value of craniometric analyses as a tool to determine the probability of ancestry of unknown individuals when viewed in the light of contextual historical information.

9.1 Introduction

Phenotypic variation, as observed in human skeletons, and the metric analysis thereof can be a useful tool for the determination of biological relatedness or ancestry of unknown individuals, as they are highly correlated with the geographic origin as well as genetic characteristics of those being investigated (Relethford & Harpending, 2004; Roseman & Weaver, 2004; Pietrusewsky, 2008). Although morphological variation among population groups is continuous and does not reflect clear discontinuous groupings or 'races' in a strict sense, the craniometric investigation of unknown skeletons can still provide researchers with valuable information in terms of probabilities of the ancestry of individuals, when used in conjunction with available historical, archaeological or genetic information (Konigsberg *et al.,* 2009; Relethford, 2009). This method of investigation is particularly valuable when testing specific hypotheses that can help to trace back the possible origins of individuals from unmarked graves.

Two aspects should be kept in mind when investigating the possible biological affinities of unknown individuals based on their cranial morphology: firstly that the 'real' levels of population diversity present within a region for a specific period in time, although never precisely known, should be taken into consideration during interpretations, and secondly that 'real' levels of population diversity, as predicted by comparative data sets, are dependant on the sample size and nature of the comparative population samples. Despite these methodological difficulties inherent to morphometrical assessment as a tool for the determination of possible ancestry, studies of this kind on past and recent populations are possible (i.e. Franklin *et al.,* 2004; Morris & Ribot, 2006; Stynder, 2009). In fact, these studies prove to be especially valuable in the investigation of unknown population samples from the African continent since these population groups present with high levels of biological diversity and relatively large comparative data sets are available, especially in South Africa (i.e. Howells, 1996; Froment, 1992; Ribot, 2002-2004).

The purpose of this paper is to determine, as far as possible, the geographical origins of unknown individuals, whose graves were disturbed during the construction of a storm-water trench alongside the fenced Gladstone Cemetery in Kimberley, by assessing their cranio-morphometric dimensions. The skeletons are thought to be those of migrant diamond mine labourers who died between 1897 and 1900 (Van der Merwe, 2007, Van der Merwe *et. al*., in print).

The discovery of diamonds in the central interior of South Africa in the late 1860s sparked not only international interest, with thousands of hopeful diggers swarming to the diamond fields in pursuit of fortune, but also drew labour from African communities of the subcontinent and even beyond, as they moved to exploit the opportunities for material benefits. Describing *The Diamond Mines of South Africa*, De Beers Consolidated Mines general manager Gardner Williams recalled, "there [were] adventurers from the United States, Mexico, and South America; and white men from all the Colonies of South Africa [mingled] with…native Africans…[coming from] the Cape to the equator" (Williams, 1902:407).

Most of the labour in the Kimberley mines was provided by migrant black workers. Numbers fluctuated: in 1881 as many as 17 000 "African natives" were employed on the mines, this figure dropping back to some 11 000 in the late 1880s and to around 7000 to 8000 for the period represented by the Gladstone graves (Turrell, 1987:228). From the outset workers were bound by contract to work on the mines for fixed periods, usually for at least three months, after which they could return to their rural villages with their earnings. Labourers from more distant parts would often elect to remain for longer: from the 1880s some workers remained at the mines for up to 18 months or more (Turrell, 1987).

From the mid-1880s, black labourers were accommodated in closed compounds, where limited contact with the outside world was a measure for preventing illegal diamond trade as well as increasing company control over the workforce (Turrell, 1987; Worger, 1987). The compounds were intended to also provide labourers with food and accommodation, and workers' medical needs were additionally taken care of in compound hospitals, in association with the Kimberley Hospital (Williams, 1987) – although, in reality, the compounds were overcrowded, the diet inadequate, and medical care deficient (Turrell, 1987:162). In the unfortunate event of death – in a context of notoriously high mortality rates – the black labourers were buried as paupers, wrapped in blankets, often in unmarked graves which could contain often more than one individual, in specified parts of local cemeteries. One of these was the Gladstone Cemetery in Kimberley (Swanepoel, 2004).

This study will attempt to test two statements emerging from historical records concerning the origins of the migrant labourers in Kimberley at the close of the nineteenth century. Firstly, where the documentary evidence of the time suggests that the "native Africans" coming to the Kimberley mines originated in various regions of Africa south of the equator (Williams, 1902:407; Turrell, 1987; Worger, 1987), this study seeks to

determine the broad geographical origin (within or outside of South Africa) represented by the remains of migrant labourers excavated alongside Kimberley's Gladstone Cemetery. Secondly, it will assess to what extent local Khoe-San communities also laboured on the mines and were accommodated in the compounds. Contemporary records suggest that they did not, in fact, participate in appreciable numbers in mining activities but, like the nearby Tlhaping and Rolong Tswana, engaged rather in supplying Kimberley with fresh produce and firewood (Kallaway, 1981; Worger, 1987).

It can be expected that the discovery of diamonds will have had a huge impact on communities living in Kimberley's hinterland, including people of Khoe-San ancestry, and on other African groups who migrated from more distant regions in response to the opportunities in Kimberley for wage labour (Worger, 1987). So far, little research has focused on the perspectives offered by the study of skeletal remains on these questions and the role of indigenous miners in late nineteenth-century Kimberley. This study contributes to the understanding of some of the dynamics of population movements at the time and the involvement of labourers of local origin.

9.2 Materials and methods

A total of 107 exceptionally well preserved skeletons, currently curated at the McGregor Museum in Kimberley, were excavated after unmarked graves had been accidentally intercepted by a trench alongside the fenced Gladstone Cemetery (Morris *et al.*, 2004). They comprise 86 males, 15 females and 6 individuals of unknown sex. The large number of males in the sample reflects the fact that most of the individuals under study were probably migrant labourers on the mines (Van der Merwe, 2007; Van der Merwe *et al.*, in print).

Due to the unequal sex distribution of this sample population a decision was made to include only male individuals in this study. Standard craniometric measurements were taken from 59 males (Knussman & Barlett, 1988). Unfortunately 27 (31%) had to be excluded from the study because of poor preservation of the necessary cranial landmarks (De Villiers, 1968; Howells, 1996).

In order to assess the possible population affinity of the well-preserved male crania from the Gladstone sample, craniometric data of eight modern and archaeological male groups of known origin, mainly from Africa and one from Asia, were used for comparative

purposes (Figure 9.1). They correspond to specific regions within Africa (N = 279) and one outside the continent (N = 53). The largest sample comes from South Africa (N = 152), and is represented by at least three modern ethnic groups (Sotho/Tswana, Zulu and various Khoe-San) (Table 9.1). The Sotho/Tswana and Zulu data correspond to sub-groups of Bantu-speakers living in the north eastern interior and the central parts of South Africa (De Villiers, 1968; Howells, 1996). The Khoe-San data correspond to two different samples: a

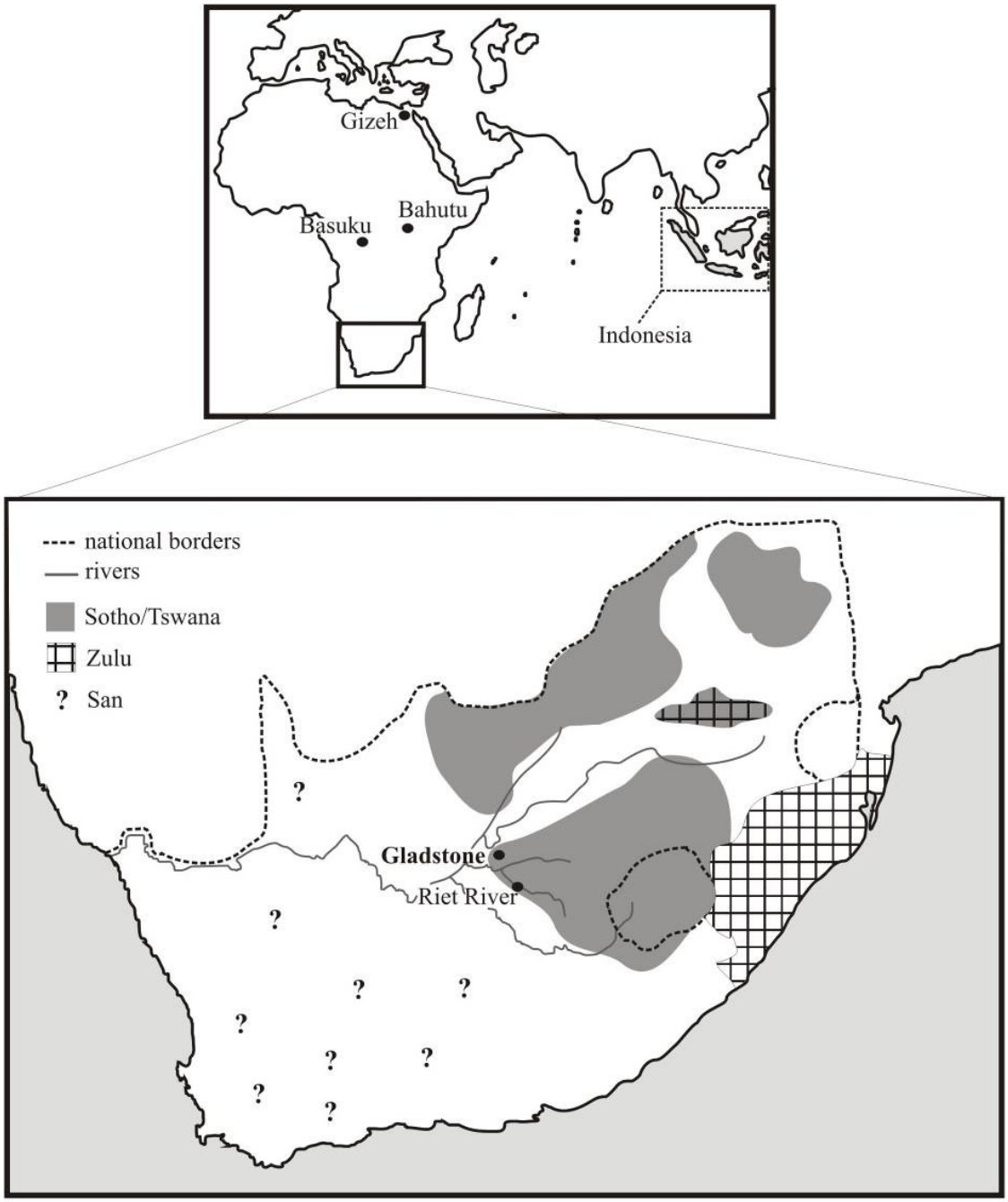

Figure 9.1 Geographical distribution of study sample: Gladstone cemetery (Kimberley, RSA) and worldwide comparative groups (after Giles *et al*., 1997 and Olson, 1996).

Table 9.1 List of comparative male cranial series studied.

Region	n	Geographic or 'ethnic' origin	Country	Date	Reference
Southern Africa	31	Sotho/Tswana	South Africa	20th c. AD	De Villiers 1968
	55	Zulu	South Africa	20th c. AD	Howells 1996
	48	various San	Various	19th- 20th c. AD	Howells 1996
	18	Riet River, Orange River Valley (Khoe-San)	South Africa	11-19th c. AD	Morris 1992
Central Africa	44	Basuku	Democratic Rep. Congo	20th c. AD	Ribot 2003; 2004
East Africa	26	Bahutu	Rwanda	20th c. AD	Ribot 2003; 2004
North Africa	57	Gizeh	Egypt	7th – 3rd c. BC	Howells 1996
Asia	53	various	Indonesia	19th – 20th c. AD	Von Bonin 1931

n=number of individuals investigated

group of various modern San individuals originating from locations not very precisely documented (Howells, 1996); and an archaeological (eleventh to nineteenth centuries AD) population from the Riet River site in the Northern Cape Province (Maggs, 1971; Morris, 1992). People of Khoe-San descent made up a significant component of the indigenous population of the area around Kimberley. Also in Kimberley's near hinterland were Tswana groups including Rolong and Tlhaping. The Sotho/Tswana comparative sample also represents groups from further away, and the Zulu a yet more distant group expected to be present amongst migrants working in the Kimberley mines originating from regions within South Africa (eastern and northern areas including the coast).

Two other regions of sub-Saharan Africa are represented by data originating from two modern Bantu-speaking groups (N = 70), the Basuku from Central Africa (central region of the Democratic Republic of the Congo) and the Bahutu from East Africa (Rwanda) (Ribot, 2003, 2004). These two population samples represent possible migrant labourers

originating from more distant regions of sub-Saharan Africa, outside of South Africa itself. Two other comparative groups, originating from North Africa and Asia (N = 110), have been added, as it is known that people working on the Kimberley mines originated from a wide range of countries and every continent (Williams, 1902). Although no large Indian sample was available for statistical analysis, late dynastic Egyptian and modern Indonesian data were selected here to detect something of the potentially far wider range of possible geographical origins (Von Bonin, 1931; Howells, 1996). According to Howells (1996), Indian populations are extremely diverse craniometrically showing affinities with both Egyptians and various South Eastern Asians.

Statistical analyses were performed using SPSS (version 11.5), and all graphs were generated with SYSTAT (version 10.0). In order to maximize the sample size of the eight comparative groups, 11 craniometrical variables were selected (Table 9.2): cranial length (g-op), cranial breadth (eu-eu), basion-bregma height (ba-b), cranial base length (b-n), basion-prosthion length (b-pr), upper facial height (n-pr), nasal height (n-ns), nasal breadth (al-al), orbital breadth (obb), orbital height (obh) and bizygomatic breadth (zy-zy).

The whole sample was evaluated for normality (i.e. through stem-and-leaf displays) and descriptive data are presented in Appendix 4. Results obtained from craniometric analyses of the Gladstone crania were compared to the various other populations described above with both univariate and multivariate statistics.

One-way analyses of variance (ANOVA) were performed to assess the differences between various groups by testing the equality of group means. *Post hoc* multiple comparison tests (Scheffe's or Tamhane's tests) were also done in order to localize group differences and similarities. When Levene's test (for homogeneity of variance) was significant, Tamhane's test was used instead of Scheffe's test.

Multiple discriminant function analyses were performed (with sample sizes more or less equal), including a stepwise method and Mahalanobis distances (D^2) as it serves as a basis for classifying unknown cases (such as those from Gladstone) into one of the defined groups (such as the eight comparative populations used in this study) (Pietrusewsky, 2008). The stepwise method was used to maximize group differentiation: variables were selected individually and evaluated in relation to all other variables to assess whether they meet the criteria of good discrimination between populations. A linear combination of independent variables was produced which corresponded to the best predictive model for population differences. Summarized classifications in percentages were obtained for each group as

well as for the unknown specimens. The largest posterior probabilities (based on discriminant scores) were used to provide an estimate regarding the likelihood of an unknown case belonging to a certain comparative group. In addition, the jackknifing method was used to cross-validate the final classification results (i.e. misclassified individuals were excluded to provide a less biased estimate of the misclassification rate). Finally, the degree of overlap and range of variation between the various groups was also assessed visually (i.e. plots of two functions with 95% confidence ellipse and centroid for each group).

In order to investigate the two statements made in historical documents regarding the population composition, two multivariate analyses were done: Analysis I included all data sets (groups within and outside of the African continent) in order to assess the possible multiple origins of individuals within the Gladstone sample population. Analysis II only included data from Africa (N = 322), in order to assess what proportion of the individuals in the Gladstone sample was of local Khoe-San origin.

Analysis I was conducted using only seven variables (instead of all 11 selected initially). Four measurements (nasal length, orbital breadth, orbital height and bizygomatic breadth) were excluded, as they showed only slight differences between comparative populations.

9.3 Results

Descriptive data resulting from the comparison of the Gladstone sample with the eight comparative data sets are presented in detail in Appendix 4. As was expected, the Gladstone sample appeared to be very diverse (presenting with relatively high standard deviations) for most of the variables, especially for g-op, ba-b and n-pr dimensions (S.D. > 6) (landmark abbreviations as given in the Material and Methods section 9.2, also see notes for Table 9.2). The results obtained from the one-way analyses of variance reflected high levels of group differentiation as the tests for the 11 craniometrical variables are all significant at the highest levels of probability (at least $P<0.01$) (Table 9.2). The post hoc multiple comparisons tests indicated that the sample from Gladstone Cemetery was very similar to South African Bantu-speaking groups (Sotho/Tswana, Zulu), and significantly different form the other six comparative groups (Khoe-San, Riet River, North Africa, Bahutu, Basuku and Asian).

Tables 9.3 to 9.5 show the results of the multiple discriminant analysis for Analysis I, which compared the Gladstone individuals with all African and other comparative groups, using seven variables (g-op, eu-eu, ba-b, b-n, b-pr, n-pr, al-al). Each function accounts for a percentage of the total variance with the first ones, having the highest 'eigenvalues', being the most important. The 'eigenvalues' (ratio of the between-groups to within-groups sums of squares) help to assess whether the obtained functions are effective in maximizing group differences. A good discriminant function is one that has much between-groups variability in comparison to within-groups variability, therefore high 'eigenvalues' are associated with good functions (below 0.1 the function has no efficiency). The first three functions obtained here were the best in the model as they accounted for most of the variance (90.2% in total)

Table 9.2 One-way analyses of variance for testing all group differences.

Variables[6]	N[1]	F[1]	Sig.[2]	L.[1]	Groups compared[4]	Significant differences between Gladstone and comparative groups[5]
g-op	384	28.79	**	NS	all	IND, BAS, KHS
eu-eu	384	22.92	**	NS	all	IND, NAFR, BAS
ba-b	384	25.78	**	NS	all	KHS, BAH, RRV, BAS
b-n	384	7.78	**	NS	all	KHS, BAS
b-pr	384	19.56	**	*	all	KHS, IND, NAFR, RRV
n-pr	384	26.34	**	*	all	KHS, BAS
n-ns	331	31.56	**	NS	all without IND	KHS, RRV, IND, BAS
al-al	383	17.74	**	*	all	NAFR, IND
obb	330	2.84	*	NS	all without IND	no differences
obh	331	9.96	**	NS	all without IND	KHS
zy-zy	322	12.92	**	NS	all without IND	KHS, BAS

[1]N=number of measurements investigated, F=F-ratio, L=Levene's test of homogeneity of variances
[2]Level of significance (NS = not significant; P<0.01*; P<0.001**).
[4]Groups with a minimal number of individuals (N≥15) have been selected for analysis and are coded as follows: **GLD** = Gladstone, **STW** = Sotho/Tswana, South Africa, **ZUL** = Zulu, South Africa, **KHS** = Khoe-San, Southern Africa, **RRV** = Riet River, South Africa, **BAS** = Basuku, Democratic Republic of Congo, **BAH** = Bahutu, Rwanda, **NAFR** = Gizeh, Egypt, **IND** = various Indonesia.
[5]Significant differences (P<0.001) between groups evaluated with post hoc multiple comparisons tests in descending order.
[6]**g–op** = cranial length or *glabella-opistocranion*, **eu-eu** = cranial breadth or *euryon-euryon*, **ba-b** = *basion-bregma* height, **b-n** = *basion-nasion* length, **b-pr** = *basion-prosthion* length, **n-pr** = *nasion-prosthion* distance, **n-ns** = nasal height *or naso-spinale*, **al-al** = nasal breadth or *alare-alare*, **obb** = orbital breadth, **obh** = orbital height, **zy-zy** = bizygomatic breadth or *zygion-zygion*.

Table 9.3 Multiple discriminant analysis I: eigenvalues and percentage of variance for seven first canonical discriminant functions used in analysis.

Function	Eigenvalue	% of variance	Cumulative %	Canonical correlation
1	1.625	44.8	44.8	0.787
2	0.923	25.5	70.3	0.693
3	0.723	19.9	90.2	0.648
4	0.213	5.9	96.1	0.419
5	0.128	3.5	99.6	0.336
6	0.013	0.4	100	0.112
7	0.001	0	100	0.034

Table 9.4 Multiple discriminant analysis I: standardized canonical discriminant functions

Variables[1]	Functions (as indicated in Table 9.3)						
	1	2	3	4	5	6	7
g-op	-0.970	-0.509	0.484	-0.153	0.002	0.533	0.241
eu-eu	0.593	-0.336	-0.407	0.295	0.409	0.163	0.564
ba-b	0.378	0.741	0.323	-0.838	-0.065	0.265	0.325
b-n	0.296	-0.819	-0.081	-0.084	0.668	-1.131	-0.736
b-pr	-0.111	0.820	0.208	0.434	-0.475	-0.207	0.982
n-pr	0.384	-0.086	0.593	0.526	-0.257	0.334	-0.522
al-al	-0.104	0.530	-0.164	0.217	0.767	0.284	-0.295

[1]**g–op** = cranial length, **eu-eu** = cranial breadth, **ba-b** = *basion-bregma* height, **b-n** = *basion-nasion* length, **b-pr** = *basion-prosthion* length, **n-pr** = *nasion-prosthion* distance, **al-al** = nasal breadth.

(Table 9.3). Their canonical correlations above 0.6 showed the high degree of association between the discriminant scores and the groups.

The higher standardized canonical discriminant function coefficients (above 0.6) are used to indicate the importance of the variables involved, whose different combinations result in different functions (Table 9.4). For example, cranial length (g-op) in Function 1, and both cranial base length (b-n) and basion-prosthion length (b-pr) in Function 2 corresponded to the key variables responsible for group differentiation.

Table 9.5 Multiple discriminant analysis I: classifications in counts (and %) for both unknown group (Gladstone) and known groups. Total correct classification after cross-validation = 59%.

Groups under study[1]	Predicted group membership								n
	STW	ZUL	KHS	RRV	BAS	BAH	NAFR	IND	
GLD	**6 (10.2)**	**32 (54.2)**	**3 (5.1)**	**0**	**8 (13.6)**	**2 (3.4)**	**6 (10.2)**	**2 (3.4)**	59
STW	**1 (3.2)**	2 (6.5)	1 (3.2)	3 (9.7)	4 (12.9)	16 (51.6)	4 (12.9)	0	31
ZUL	6 (10.9)	**1 (1.8)**	1 (1.8)	8 (14.5)	1 (1.8)	30 (54.5)	6 (10.9)	2 (3.6)	55
KHS	0	0	**31 (75.6)**	0	1 (2.4)	3 (7.3)	5 (12.2)	1 (2.4)	41
RRV	0	1 (5.6)	7 (38.9)	**2 (11.1)**	3 (16.7)	0	5 (27.8)	0	18
BAS	1 (2.3)	0	5 (11.4)	30 (68.2)	**0**	5 (11.4)	2 (4.5)	1 (2.3)	44
BAH	1 (3.8)	0	2 (7.7)	2 (7.7)	13 (50.0)	**5 (19.2)**	2 (7.7)	1 (3.8)	26
NAFR	2 (3.5)	0	1 (1.8)	0	2 (3.5)	4 (7.0)	**45 (78.9)**	3 (5.3)	57
IND	0	0	0	1 (1.9)	1 (1.9)	4 (7.7)	6 (11.5)	**40 (76.9)**	52

[1]Groups coded as follows: **GLD** = Gladstone, **STW** = Sotho/Tswana, South Africa, **ZUL** = Zulu, South Africa, **KHS** = Khoe-San, Southern Africa, **RRV** = Riet River, South Africa, **BAS** = Basuku, Democratic Republic of Congo, **BAH** = Bahutu, Rwanda, **NAFR** = Gizeh, Egypt, **IND** = various Indonesia. n = number of individuals investigated

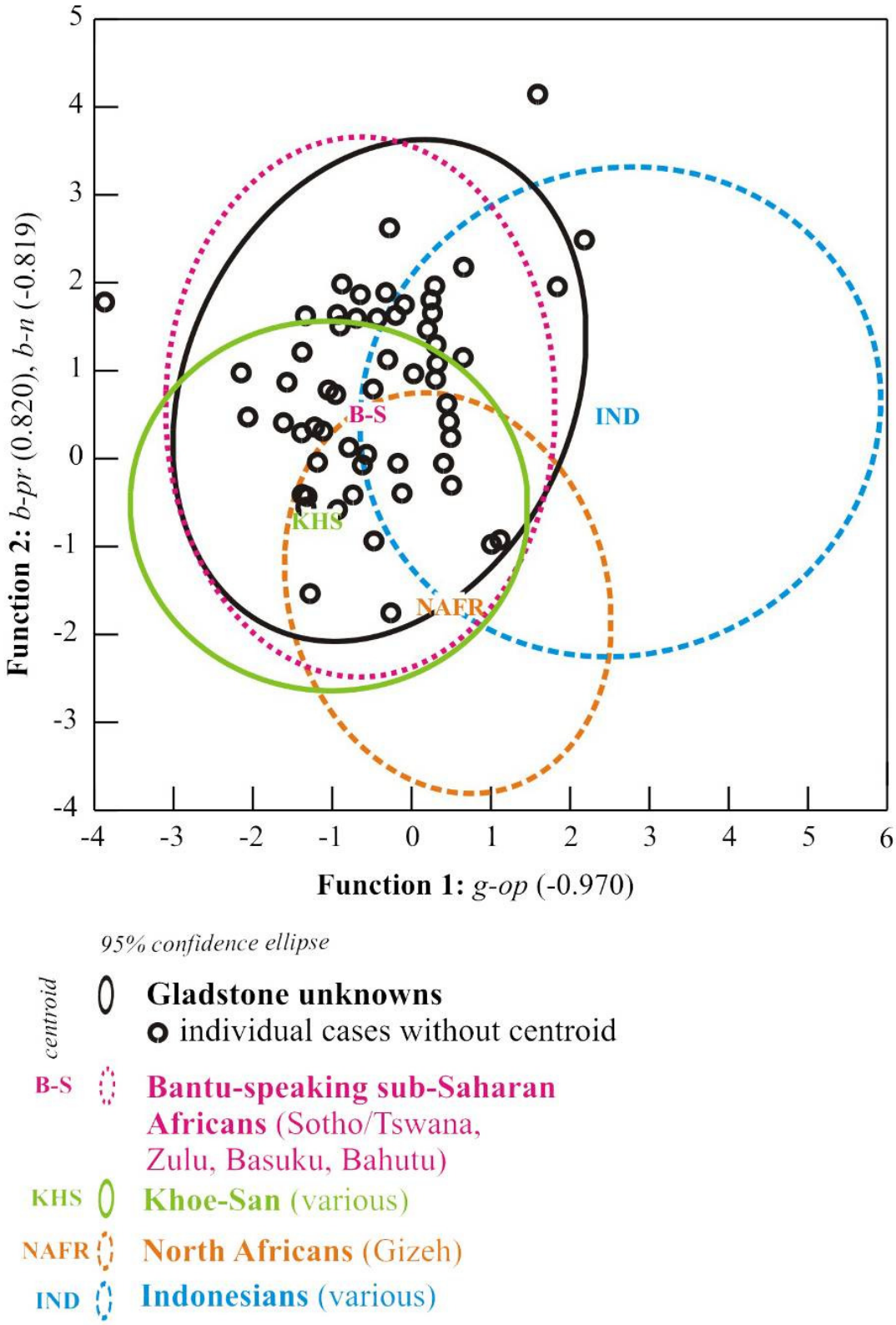

Figure 9.2 Discriminant scores plot for analysis I. Two functions account for 70.3% of total variance. 95% confidence ellipse with centroid shown for each group (for Gladstone, individual cases shown instead of centroid). Highest standardized discriminant function coefficients put into brackets for each function.

The classification results of the multiple discriminant Analysis I are summarized with the predicted membership for each individual in Table 9.5. In total, only 59% of the cases were correctly classified into their group of origin after cross-validation. This again indicated that there is a lot of morphological overlap between the groups as can also be seen by the scatter plot with the 95% confidence ellipses (Figure 9.2). As a high number of comparative groups were used, Africans in particular were pooled into two groups, of Bantu-speakers (Sotho/Tswana, Zulu, Basuku and Bahutu) and Khoe-San, for better visual assessment of the variation (although the multiple discriminant analysis considered the original groups separately).

Relative to the available comparative samples, the Gladstone individuals were classified as follows: mainly as Zulu (54%), and in decreasing order with the Basuku (13.6%), Sotho/Tswana (10.2%), North Africans (10.2%), Khoe-San (5.1%) and Bahutu (3.4%), but never with Riet River (Table 9.5). More than 80% of the Gladstone group fitted rather well into the Bantu-speaking groups (mainly Zulu and a few others), with a relatively more prognathic face. According to the highest posterior probabilities, three cases (GLD N74.8, GLD N38.7, GLD S2.6) were classified as Khoe-San as a result of a flatter face. Six individuals (GLD N31.E, GLD N38.8, GLD N74.1, GLD NOP3, GLD S2.1, GLD S3.2) were grouped with North Africans due to a flatter face and shorter vault, and two (GLD N34.7, GLD N34.1) with Indonesians as a result of a shorter cranial vault.

Tables 9.6 to 9.8 show the results of multiple discriminant analysis II, which compared Gladstone individuals with only the African groups, using all 11 variables. The first three

Table 9.6 Multiple discriminant analysis II: eigenvalues for discriminant functions.

Function	Eigenvalue	% of variance	Cumulative %	Canonical correlation
1	1.896	50.1	50.1	0.809
2	1.036	27.4	77.5	0.713
3	0.515	13.6	91.1	0.583
4	0.178	4.7	95.8	0.388
5	0.118	3.1	98.9	0.325
6	0.041	1.1	100.0	0.198

Table 9.7 Multiple discriminant analysis II: standardized canonical discriminant functions.

Variables[1]	Functions (as indicated in Table 9.6)					
	1	2	3	4	5	6
g-op	0.037	-0.034	0.334	0.633	-0.378	-0.900
eu-eu	0.382	-0.372	-0.006	0.064	0.145	0.682
ba-b	-0.050	0.791	-0.775	-0.108	-0.283	-0.110
b-n	0.642	-0.499	0.112	0.489	0.239	0.492
b-pr	-0.529	0.635	-0.030	-0.497	0.201	0.396
n-pr	-0.370	0.032	0.897	0.155	-1.152	0.477
n-ns	1.050	0.306	-0.683	-0.275	0.926	-0.179
al-al	-0.625	-0.040	-0.184	0.647	0.201	0.319
obh	-0.368	0.327	0.096	-0.179	0.271	-0.172
zy-zy	-0.125	0.033	0.637	-0.190	0.327	-0.490

[1]**g–op** = cranial length or *glabella-opistocranion*, **eu-eu** = cranial breadth or *euryon-euryon*, **ba-b** = *basion-bregma* height, **b-n** = *basion-nasion* length, **b-pr** = *basion-prosthion* length, **n-pr** = *nasion-prosthion* distance, **n-ns** = nasal height *or naso-spinale*, **al-al** = nasal breadth or *alare-alare*, **obh** = orbital height, **zy-zy** = bizygomatic breadth or *zygion-zygion*.

functions obtained accounted for most of the variance (91.1% in total) (Table 9.6).

Their canonical correlations (above 0.5) also reflected a relatively high degree of association between the discriminant scores and the groups. For the first two functions, the four variables that presented the highest standardized canonical discriminant function coefficients (above 0.6) were basion-nasion length (b-n) and nasal breadth (al-al) for Function 1, and basion-bregma height (ba-b) and basion-prosthion height (ba-pr) for Function 2 (Table 9.7).

Finally, the classification results of multiple discriminant analysis II are summarized in Table 9.8. In total, 63.4% of the cases were correctly classified into their group of origin after cross-validation. This indicated slightly less overlap between the groups in comparison to Analysis I (Figure 9.3). According to the highest posterior probabilities, the Gladstone unknown individuals were again mainly classified as belonging to Bantu-speaking groups (Sotho/Tswana, Zulu, Basuku and Bahutu) (85.9%), owing to a relatively high vault and prognathic face, with the majority again being classified as having greatest affinity with the Zulu comparative sample (52.6%). Slightly more individuals were classified as having a possible Khoe-San and Riet River ancestry (5.3%) owing to a lower

vault and flatter face, but less were classified as being of possible North African descent (8.8%) as characterized by a narrower nose.

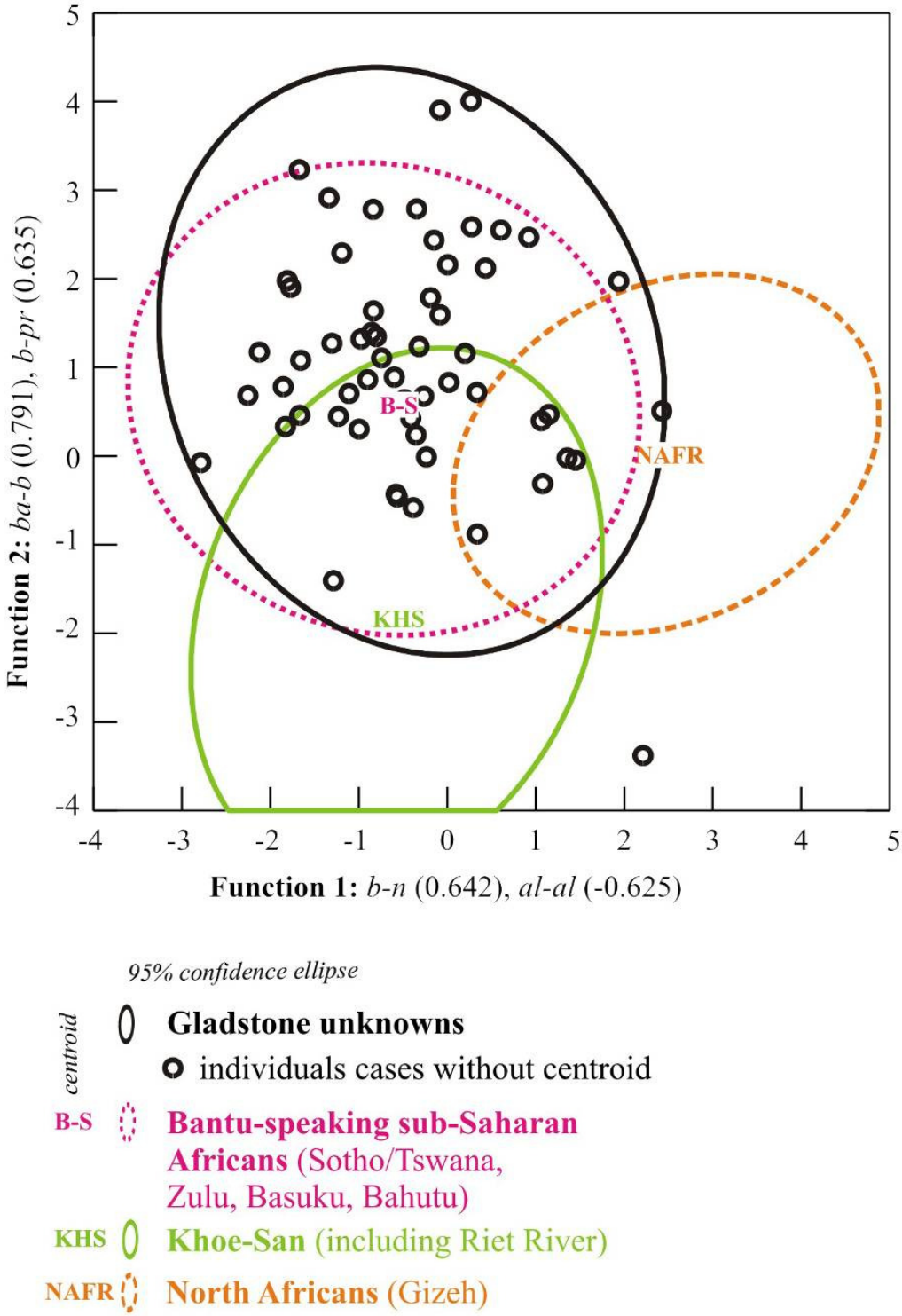

Figure 9.3 Discriminant scores plot for analysis II. Two functions account for 77.5% of total variance. 95% confidence ellipse with centroid shown for each group (for Gladstone, individual cases shown instead of centroid). Highest standardized discriminant function coefficients put into brackets for each function.

Table 9.8 Multiple discriminant analysis II: classifications in counts (and %) for both unknown group (Gladstone) and known groups. Total correct classification after cross-validation = 63.4%.

Groups under	Predicted group membership							
Study[1]	STW	ZUL	KHS	RRV	BAS	BAH	BAFR	n
GLD	11 (19.3)	30 (52.6)	1 (1.8)	2 (3.5)	6 (10.5)	2 (3.5)	5 (8.8)	57
STW	**7 (22.6)**	12 (38.7)	1 (3.2)	3 (9.7)	3 (9.7)	3 (9.7)	2 (6.5)	31
ZUL	8 (14.5)	**33 (60)**	1 (1.8)	0	8 (14.5)	1 (1.8)	4 (7.3)	55
KHS	3 (7.3)	1 (2.4)	**30 (73.2)**	3 (7.3)	2 (4.9)	2 (4.9)	0	41
RRV	2 (13.3)	0	6 (40.0)	**3 (20)**	2 (13.3)	1 (6.7)	1 (6.7)	15
BAS	1 (2.3)	8 (18.2)	4 (9.1)	1 (2.3)	**28 (63.6)**	1 (2.3)	1 (2.3)	44
BAH	1 (4.5)	1 (4.5)	2 (9.1)	0	2 (9.1)	**14 (63.6)**	2 (9.1)	22
NAFR	0	3 (5.3)	1 (1.8)	0	0	0	**53 (93.0)**	57

[1]Groups coded as follows: **GLD** = Gladstone, **STW** = Sotho/Tswana, South Africa, **ZUL** = Zulu, South Africa, **KHS** = Khoe-San, Southern Africa, **RRV** = Riet River, South Africa, **BAS** = Basuku, Democratic Republic of Congo, **BAH** = Bahutu, Rwanda, **NAFR** = Gizeh, Egypt. N = number of individuals investigated.

9.4 Discussion

The possible ancestry of the unknown individuals excavated from alongside the fenced Gladstone Cemetery, based on the craniometric results, should be discussed with caution, as morphological similarities, even in probabilistic terms, do not necessarily equate directly with biological affinity. In fact, morphological similarities should always be interpreted in relation to the present worldwide variation (clinal in nature with low inter-population differences) in association with historical records for the population under study. However, it is clear that considerable morphological variation is present within the Gladstone sample.

According to the general manager of De Beers, "nowhere else on the face of the earth … [could be found] an assemblage of workers of such varied types of race, nationality, and colouring as … [on] the South African Diamond Fields" (Williams, 1902: 407). Contemporary documentation indicates that "native Africans [came] from the Transvaal, Basutoland, and Bechuanaland, from districts far north of the Limpopo and the Zambesi, from the Cape Colony…, Delgoa Bay and countries along the coast of the Indian Ocean… from Damaraland and Namaqualand" to pursue opportunities for wage labour on the mines. The workers often travelled thousands of kilometres to the Diamond Fields, mainly on foot, and those coming from far off were often weak and emaciated by the time they arrived (Williams, 1902:413).

A government official, the 'Registrar of Natives', kept records of black labourers arriving at the mines (Smalberger, 1876; Williams, 1902), noting their identity as "Hottentots, Basutos, Soshaganas (Zulus from North of Delagoa), Mahawa (the Pedi or Secocoeni Basuto), Colonials, Kaffrarians, Mantatees, Batlapin, Swazis, Coolies, Baralongs, Griquas and Mozambique" (Turrel, 1987). While many of the labourers were not registered, the records hence incomplete, the documentation nevertheless clearly shows that the majority of black labourers were of Pedi, Tsonga (also known as the Shangaan), Sotho and Zulu origin. In contrast to what one might expect, African communities closest to the mines (including the Rolong, Tlhaping, Griqua and Koranna) contributed least of the workforce (Kallaway, 1981; Worger, 1987; Turrell, 1987).

The craniometrical results obtained in this study for both the worldwide (Analysis I) and African (Analysis II) comparisons, largely concur with historical information available for this population sample. Looking at the morphological variation in a broad perspective, the majority of individuals in this sample population was most probably of (Bantu-

speaking) sub-Saharan African descent (at least 80%), and especially of southern African origin correlating with the Zulu (at least 50%) and Sotho/Tswana (at least 10%) samples. As corroborated by the historical information cited above, the composition of the mine worker population represented by the Gladstone skeletons clearly reflects a particular southern African context with a high rate of inter-regional migration in the form of migrant labour. In fact, the observed morphologies do not resemble the geographically closest population (including Khoe-San) but rather the more distant Zulu sample. While there is a great degree of overlap between the Bantu-speaking sub-Saharan African groups, other possible origins, such as Central African (Basuku: at least 10%) or even to a lesser degree East African (Bahutu: at least 3%), cannot be excluded. Only a small percentage (1–5%) of individuals buried in the Gladstone cemetery were of possible Khoe-San descent.

In some cases possible ancestry could not be specified as the specimens in question presented with a combination of traits reflecting various possible population affinities (perhaps owing to gene flow between various regions). The fact that six Gladstone individuals fell within the range of variability of North Africans (GLD N31.E, GLD N38.8, GLD NOP3, GLD S2.1) and/or Indonesians (GLD N34.7, GLD N34.1) does not necessarily mean that individuals from those regions were present in the sample. It might suggest a wider range of possible origin and/or mixed ancestry in relation to more northern and eastern parts of the world (in addition to sub-Saharan Africa). For example, the morphological similarities observed between the Khoe-San and North African populations (often related to gracility) do not reflect a common origin (Morris & Ribot, 2006). It therefore remains difficult to systematically specify the origin of an individual on morphological grounds alone. However as suggested above, it can indicate some possible gene admixture within the Gladstone population, involving possibly a minimal number of Khoe-San individuals.

Although there are some obvious limitations regarding the assessment of ancestry through metric analysis of skeletal remains, owing to the inherent nature of human variation (which is highest within a ‘population’), this study has indicated that the interpretation of craniometric data can be of great value, particularly in the light of contextual data available for a historical ‘unknown’ group.

While the inter-group variation is highly overlapping on different geographical scales, all results are in accord with historical documentation describing the cosmopolitan nature of the workforce on the diamond mines of Kimberley. High wages were initially one of the

main reasons for individuals to travel up to thousands of kilometres from within Southern Africa to Kimberley to work on the mines (previously, many had exploited work opportunities in the Cape and Natal Colonies and the Free State). Attempts by the mining companies to lower the wages resulted in the almost immediate exodus of workers (Worger, 1987). Their earnings supported and began to transform rural economies in a variety of ways. Some migrant workers (such as the Tsonga) came to Kimberley mainly in order to earn cash for bride-wealth, some to buy farming equipment, for example ploughs and wagons, while others (especially the Pedi and South Sotho) worked in order to obtain a firearm, which was readily available in Kimberley during the early mining years, but forbidden to be sold to Africans from 1877 (Turrell, 1987; Worger, 1987). Much of this activity, at the start, was subject to chiefly control and other existing social obligations. Thus, for instance, young men returning from the mines would often owe a tribute or a tax from their earnings to the chief (Turrell, 1987). This relatively easy chiefly income came at a high price, however, since migrant labour in return also provided labourers with a window of opportunity to challenge chiefly control and to accumulate wealth independently (Turrell, 1987). Slowly but surely sterling began to displace cattle as payment for brides, leading to bride-prices being increased to above migrant labour wages, resulting in heightened social and political dissatisfaction within rural societies (Worger, 1987; Turrell, 1987).

The Gladstone burials relate to a later period, however, when rural autonomy had been considerably eroded throughout much of southern Africa. The loss of land and the imposition of hut taxes were amongst factors that compelled men from rural areas to seek wage labour. Those obtaining work on the mines were recruited for longer periods and at a lower wage (Worger, 1987; Pakenham, 1992).

Economic factors were the main reason why local populations around Kimberley, such as the Griqua, Kora and Tlhaping, did not generally participate in work on the mines, although small numbers did sell their labour in this way. Instead, they had the means, initially at least, to retain relative independence by selling firewood and fresh produce such as milk, meat and vegetables to the mines and the towns that grew up around them (Kallaway, 1981; Turrell, 1987; Worger, 1987). Here it should be mentioned that very little in the way of vegetables and other fresh produce reached the labouring classes on the mines, since scurvy was a major problem among them, with historical sources indicating

that labourers in the compounds were mostly fed with maize and occasional coarse meat (Cape of Good Hope Votes and Proceedings of Parliament, 1899; Harries, 1994).

With time, however, the depletion of resources (or denial of access to them) forced individuals from these groups increasingly to sell their labour, on farms, in towns or indeed on the mines, albeit in low numbers in proportion to migrant workers recruited from further away. The coming of the railway to Kimberley in 1885 brought in cheaper grain, coal and other products which undercut still further the local trade in fresh produce and firewood (Worker, 1987).

Thus, although the Kimberley mines brought new opportunities to the area it is obvious that, just as was observed in the communities providing migrant labour from further afield, it also resulted in social and political changes for the communities in the region around Kimberley itself. The Griqua and the local Khoe-San peoples benefited least of all from the discovery of diamonds in their proximity, and it appears that relatively few of them were taken up in the workforce.

In conclusion it can be said that the craniometric study on the 59 adult males excavated from alongside the Gladstone Cemetery has given substance to the historical records concerning migrant labourers coming to work in the Kimberley mines. They indicate that the greater proportion of labour at the Kimberley mine was provided by migrant workers from beyond Kimberley's immediate hinterland and that the local African communities (including Khoe-San) contributed much less to the labour force in the mines. Many of the labourers came from elsewhere in southern Africa (the relatively high correlation with the Zulu comparative sample suggests the north eastern side of South Africa as one region of origin), even as far afield as the east coast of Africa (possibly even as far as Asia). The relatively heterogeneous nature of the Gladstone sample (as seen in the high degree of morphological diversity) probably reflects the varied geographical origins of the workforce in Kimberley as well as some possible genetic admixture. Owing to the considerable overlap, as can be seen in Figures 9.2 and 9.3, however, it remains difficult to specify possible regions of origin more precisely. Nevertheless, this study reiterates the value of craniometric analyses as a tool to determine the probability of biological affinity of unknown individuals when viewed in the light of contextual historical information.

Further research combining both the morphometrical approach and ancient DNA analysis could expand on these results and provide more precise data on the ancestry of the people buried in these unmarked graves.

References

Cape of Good Hope Votes and Proceedings of Parliament. 1899. Hospitals and Asylums Report for 1898 Appendix I.

De Villiers, H. 1968. *The skull of the South African Negro*. Johannesburg: Witwatersrand University Press.

Franklin, D., Freedman, L. and Milne, N. 2004. Sexual dimorphism and discriminant function sexing in indigenous South African crania. *HOMO - Journal of Comparative Human Biology 55(3)*: 213-228

Froment, A. 1992. La différenciation morphologique de l'homme moderne: congruence entre forme du crâne et répartition géographique du peuplement. *Comptes Rendus de l'Académie des Sciences de Paris*, 315 (series III): 323-329.

Giles, B., Doyle, M., Johnston, M., Wood, I. and Harding, D. 1997. *Peoples of Southern Africa*. New York: The Diagram Group, Facts on file Inc. p.112.

Harries, P. 1994. Work, culture and identity. *Migrant laborers in Mozambique and South Africa, c 1860 - 1910*. Johannesburg: Witwatersrand University Press.

Howells, W.W. 1996. Howell's craniometric data on the internet. *American Journal of Physical Anthropology*, 101: 441-442.

Kallaway, P. 1981. Tribesman, trader, peasant and proletarian: the process of transition from a pre-Capitalist to a Capitalist mode of production in the immediate hinterland of the Kimberley Diamond Fields during the nineteenth century. In Bonner, P. (ed) *Working papers in Southern African studies*, Volume 2. Johannesburg: Ravan Press: 8-30.

Knussman, R. and Barlett, H.L. 1988. *Anthropologie*. Fischer: Stuttgart.

Konigsberg, L.W., Algee-Hewitt, B.F.B. and Steadman, D.W. 2009. Estimation and evidence in forensic anthropology: sex and race. *American Journal of Physical Anthropology* 139(1):77-90.

L'Abbé, E., Ribot, I. and Steyn, M. 2006. Tracing the origins of the Venda. *South African Archaeological Bulletin* 61(183): 19-25.

Maggs, T. 1971. Pastoral settlements on the Riet River. *South African Archaeological Bulletin* 26: 37-63.

Morris, A.G. 1992. *The Skeletons of Contact*. Johannesburg: Witwatersrand University Press.

Morris, A.G. and Ribot, I. 2006. Morphometric cranial identity of prehistoric Malawians in the light of sub-Saharan African diversity. *American Journal of Physical Anthropology*, 130: 10-25.

Morris, D., van Ryneveld, K. and Voigt, E.A. 2004. Outside Gladstone Cemetery: first thoughts on unmarked late nineteenth century graves, Kimberley. In Morris, D. and Beaumont, P. (eds) *Archaeology in the Northern Cape: some key sites*. Kimberley: McGregor Museum.

Olson, J.S. 1996. *The Peoples of Africa. An Ethnohistorical Dictionary*. London: Greenwood Press. p.681.

Pakenham, T. 1992. Rhodes, Raiders and Rebels. *The Scramble for Africa*. London: Abacus. p. 497–498.

Pietrusewsky, M. 2008. Metric analysis of skeletal remains: methods and applications. In Katzenber, A.M. and Saunders, S.R. (eds), *Biological anthropology of the human skeleton*. New York: John Wiley & Sons Inc. p.487-532.

Relethford, J.H. 2009. Race and global patterns of phenotypic variation. *American Journal of Physical Anthropology* 139(1): 16-22.

Relethford, J.H. and Harpending, H.C. 1994. Craniometric variation, genetic theory, and modern human origins. *American Journal of Physical Anthropology*, 95: 249-270.

Ribot, I. 2002. *Craniomandibular variation in sub-Saharan Africa: sexual dimorphism, geography, ecology and history*. PhD dissertation. Cambridge: University of Cambridge.

Ribot, I. 2003. Craniometrical analysis of Central and East Africans in relation to history. A case study based on unique collections of known ethnic affiliation. *Anthropologica et Praehistorica*, 114: 25-50.

Ribot, I. 2004. Differentiation of modern sub-Saharan African populations: craniometric interpretations in relation to geography and history. *Bulletins et Mémoires de la Société d'Anthropologie de Paris*, 16(3-4): 143-165.

Roseman, C.C. and Weaver, T.D. 2004. Multivariate apportionment of global human craniometric diversity. *American Journal of Physical Anthropology*, 125: 257-263.

Smalberger, J.M. 1976. The Role of the Diamond-Mining Industry in the Development of the Pass-Law System in South Africa . *The International Journal of African Historical Studies*, 9(3): 419-434.

Stynder, D.D. 2009. Craniometric evidence for South African Later Stone Age herders and hunter–gatherers being a single biological population. *Journal of Archaeological Science* 36(3): 798-806.

Swanepoel, S. 2003. *Gladstone Cemetery, 1880s to 1900s*. Archival report.

Turrell, R.V.1987. African labour in the early days In: *Capital and Labour in the Kimberley Diamond Fields 1871 – 1890*. Cambridge University Press. London, p.19 – 27.

Van der Merwe, A.E. 2007. *Human skeletal remains from Kimberley: An assessment of health in a 19th century mining community*, MSc. thesis, University of Pretoria.

Van der Merwe, A.E., Morris, D., Steyn, M. and Maat, G.J.R. In Print. The history and health of a nineteenth-century migrant mine-worker population from Kimberley, South Africa. *South African Archaeological Bulletin.*

Von Bonin, G.1931. A contribution to the craniology of the Easter Islanders. *Biometrika* 23 (3/4): 249-270.

Worger, W.H. 1987. *South Africa's City of Diamonds. Mine Workers and Monopoly Capitalism in Kimberley, 1867 – 1895*. Yale University Press, London.

Williams, G.F. 1987. The workers in the mines In: *The Diamond Mines of South Africa, Some Account of their Rise and Development.* The Macmillan Company, London.

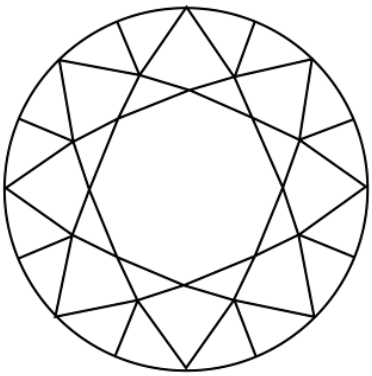

CHAPTER 10

General Discussion

Modified from article accepted for publication as:

The history and health of a nineteenth-century migrant mine-worker population from Kimberley, South Africa

A.E. Van der Merwe, D. Morris, M. Steyn, G.J.R. Maat

South African Archaeological Bulletin

Bultfontein mine compound hospital, 1900s
(McGregor Museum Kimberley Photography nr.5354)

Bultfontein Mine Compound, 1900s
(McGregor Museum Kimberley Photography nr.5357)

This study has brought together the results of archaeological, archival, palaeopathological and craniometric analyses to detail the history, health and possible ancestry of the unknown individuals whose remains were salvaged and investigated following accidental disturbance of unmarked graves next to the fenced Gladstone cemetery. The burial patterns, grave goods, demographic composition, and results obtained detailing the possible ancestry of male individuals in this sample, are all consistent with this having been a migrant worker population.

The grave goods (see Appendix 2), clearly reflect that the sample population had rural African connections and constitute an important archaeological indicator that the population in question was most likely comprised of migrant labourers. A comparison of these finds with grave goods recovered from a small number of documented African interments from the 1870s in the Transvaal Road area of Kimberley (Morris, 2004) indicates a striking contrast: these earlier graves contained a wide range of probably locally-purchased items such as pipes, enamel ware and buttoned clothing, reflecting a more open socio-economic context for migrant workers in Kimberley in the pre-compound era. The picture emerging from the 1890s interments at Gladstone Cemetery suggests a situation with greater restriction, with migrants having limited access to the kinds of goods available in shops outside the compounds.

By far, the majority of individuals within this study were male, with only a few females and three children. These findings also match the historical documents stating that the majority of those working on the mines were migrant workers and that they were predominantly male (Stoney, 1900a; McNish, 1970; Worger, 1987; Jochelson, 2001). Men left their families at their distant rural homes and came to Kimberley - initially on a voluntary basis, with the expectation of financial benefits and the opportunity to purchase a firearm. But after the mid-1880s, however, migrant workers were forced to sell their labour at reduced rates when conquest was depriving 'black' societies of a viable agricultural base and ways had to be found to pay hut taxes which had been imposed (Williams, 1902; McNish, 1970; Worger, 1987).

Results of the study into the possible ancestry of individuals from the Gladstone skeletal sample also concurred with a migrant working hypothesis. As described in Chapter 9, the results support the historically described cosmopolitan nature of the labour force in Kimberley. Most of the individuals in this very heterogeneous male sample population

were most probably from Bantu-speaking sub-Saharan African descent, particularly of southern African origin. Interestingly, morphological features resembling the geographically closest population (Khoe-San) were not frequently observed. As was suggested in historical documents, the Khoe-San seemed not to have contributed much to the labour force at the Kimberley mine (van der Merwe *et al.*, in print).

It is clear that while the sex distribution within this skeletal sample does not represent a normal population distribution, it accords well with the known population profile of Kimberley at the end of the 19th century. Neither female labour nor the employment of sick and emaciated men was allowed in the mines. Therefore, the majority of individuals working in Kimberley were young, healthy male adults when they entered the mines (Williams, 1902). This demographic profile was reflected in a census held in 1898, from which it was reported that 65% of the 'black' individuals within Kimberley were aged between 15 and 45 years (Stoney, 1900a).

The high death rate of black labourers between 30 and 45 years of age, apparent in the skeletal remains examined, was well-documented in archival reports from the Officer of Health (Stoney, 1900a). These reports ascribed the high mortality rate to mining accidents associated with shaft blasting, the poor living conditions of the workers, as well as their increased susceptibility to 'Western diseases' (Stoney, 1900a).

Unhealthy living conditions, the unusual gender distribution (encouraging the spread of venereal diseases), as well as the absence of antibiotics at the time, combine to explain why tertiary stages of syphilis could be observed in this skeletal population (Harries, 1994). Although skin lesions associated with syphilis were commonly treated with mercury during the 19th century, intervention with penicillin was only implemented around 1941. Hence, treponematosis could develop to its tertiary phase, not often seen in modern populations with access to antibiotics (Ortner, 2003).

The prevalence of skeletal involvement during treponemal infection has been shown to vary greatly. Some authors have found that 1% of patients present with skeletal lesions, whereas others reported up to 20% of infected individuals showing bone alterations (Ortner, 2003). Accordingly, care should be taken when reconstructing the prevalence of treponematosis in the Gladstone population, since the occurrence of skeletal indications of syphilis might not be representative of the true prevalence of the disease within the living population. It should also be kept in mind that since the graves in question are seemingly associated with a hospital context, the population sample is biased.

Skeletal lesions suggestive of treponemal infection were observed in 8.4% of individuals within this population. The prevalence is not necessarily higher than that observed in other populations, such as in skeletal samples from the Mariana Islands (10.5%), Guam (6.6%), the Dominican Republic (8.8%) and Metaponto (17.3%), but it is extremely high when compared to other South African populations, where only single isolated cases have been reported (Henneberg & Henneberg, 1993; Douglas *et al,* 1997; Pietrusewsky *et al*., 1997; Rothschild *et al.,* 2001; Steyn *et al.,* 2003). The high prevalence rate in the Gladstone sample does correlate, however, with the reported incidence of syphilis reflected in contemporary documents in late 19th century Kimberley (Jochelson, 2001). Although no clear numbers were stated, it was reported by the Senior House Surgeon in 1899 that "syphilis is playing havoc among the coloured races" (CGHVPP, 1900:42). One may therefore assume that many individuals were affected by the condition.

Another infectious disease which was reported to have spread rapidly among the migrant labourers was tuberculosis, or phthisis, as it was referred to in archival documents (Collins, 1982; Packard, 1989; Meyer *et al.,* 2002). There are no reports of any occurrence of tuberculosis in South Africa prior to 1652 and it is suggested that the disease was introduced during European colonization, rapidly breaking out and spreading among the indigenous societies (Donald, 2001). According to the Officer of Health, a higher susceptibility amongst migrant workers to contract this condition was the reason for the epidemic. Furthermore, the overcrowded living conditions in the compounds and locations in Kimberley definitely spurred the spread of the disease (Stoney, 1900a; Packard, 1989). As indicated by archival documents, huts in the location were crowded together, with at least six individuals per hut, while in the compounds, several individuals shared a shed (Stoney, 1900b; Packard, 1989). With people living in such close quarters, the prevailing conditions were conducive to the spread of any infectious disease, not only tuberculosis. Another factor predisposing labour migrants to infection was their generally poor health induced by exhaustion from long working hours and limited nutritional resources (Harries, 1994; Packard, 1989).

Taking into consideration that skeletal lesions resulting from tuberculosis develop in only 5-7% of individuals infected by the disease, the prevalence of tuberculosis in this sample population correlates well with its frequency as described in the living migrant worker population in Kimberley (Steinbock, 1976; Santos & Roberts, 2001).

It should be kept in mind, though, that the terminology used in archival documents is sometimes ambiguous. The term “phthisis” is also given to lung diseases induced by the constant inhalation of microscopic particles of dust generated by shovelling, drilling and blasting. However, according to the *Oxford Concise Medical Dictionary* (2003), it is also a former name for tuberculosis (Harries, 1994; Packard, 1989). Nevertheless, the inhalation of dust particles also leads to fibrosis, the symptoms of which may be mistaken for those of tuberculosis. This condition is extremely prevalent in individuals working in underground mines, and it would be expected to have occurred in Kimberley, where shafts for underground mining had begun to be sunk by 1885 (Turrell, 1987; Harries, 1994; Packard, 1989).

The unavailability of antibiotic treatment in this period resulted not only in the observed skeletal lesions associated with treponematosis and tuberculosis in this population, but also in advanced non-specific osteomyelitis for which the treatment in the late 19th century was amputation. Non-specific osteomyelitis is considered to be more prevalent in rural environments with poor sanitation in the home and/or hospital settings (L’Abbé, 2005; L’Abbé & Steyn, 2007). In late 19th century Kimberley, notoriously bad conditions were reported even from the Kimberley Hospital, specifically in its pauper wards. According to reports, the ‘Native Medical Ward’ was in an appalling state in 1897 (Medical Officer of Health, 1897). It was described as being "low, hot, badly lighted and badly ventilated, and worst of all there [was] a scullery opening into it" (CGHVPP, 1898).

Although only one case of non-specific osteomyelitis was observed, it is possible that some of the osteomyelitis cases admitted to hospital were treated by amputation. In some of the amputated limbs observed, clear signs of infection were present. If all the amputations observed in this population were indeed the result of infection, the prevalence of osteomyelitis would increase to 6.5%, possibly being more representative of the true prevalence rate of the condition. However, it should be kept in mind that some of the amputations may have been the result of untreatable crushing injuries, as may be expected in a hazardous mining environment, without time for a secondary infection to develop.

The high prevalence of skeletal lesions suggestive of healed scurvy also correlates well with contemporary reports. Increased levels of scurvy can be expected in a population following a diet consisting of mainly maize meal and occasional coarse meat, as was described in historical documents and supported by the investigation of the population’s dental health (see Chapter 7) (Harries, 1994). Supplementary food could be purchased

from company stores, but was extremely costly (Worger, 1987). The potential for scurvy would have been exacerbated by the regular consumption of homemade beer and alcohol. Opportunities to cultivate supplementary foods, such as vegetables and fruit containing vitamin C, were limited by the harsh environment and restrictions in the compounds (Van der Merwe *et al.*, 2010a; 2010c).

Histological investigations proved to be a valuable tool in distinguishing tibial lesions caused by ossified haematomas (which most likely developed as a result of scurvy) from those caused by osteomyelitis, specifically treponematosis. As was described in Chapter 6, ossified haematomas were microscopically characterized by normal original cortical bone and radiating trabecular appositional bone. Three phases of ossified haematoma formation and remodelling in humans were proposed, with the various stages resulting in gradual remodeling of the appositional trabecular bone to more compact Haversian bone, while retaining an outwards radiating bone structure (van der Merwe *et al.*, 2010a).

It was found that histological features, such as those described by Schultz (2003) as being characteristic of treponemal infection, could not be identified in the sections taken from lesions macroscopically diagnosed as resulting from treponematosis. Although the preservation of the bone material as well as the variability in distribution of these features may be the reason why they were not observed, it is also possible that these features cannot be exclusively associated with treponematosis. It was proposed as very likely that the same histological picture will be observed in samples taken from lesions caused by non-specific osteomyelitis, treponematosis and leprosy (Blondiaux *et al.*, 1994; Ortner, 2003).

Although ossified haematomas observed in the Gladstone skeletal sample are suggested to have been the result of scurvy, traumatic events, which were also documented as begin numerous during this time period, could also have been the responsible cause.

Nearly one third of individuals in the study population had at least one fracture (n=28) and 48.8% of the fractures observed could be classified as blunt force cranial fractures. This extremely high prevalence of cranial fractures is suggestive of high levels of interpersonal violence (Jurmain & Bellifemine, 1997; Standen & Arriaza, 2000). Cultural differences amongst migrant workers, competition for resources, and overindulgence in alcohol, must have caused friction between labourers or between themselves and their employers (Harries, 1994; Turrell, 1987; Worger, 1987). The frequency of lesions suggesting interpersonal violence is in accord with the historical documentation of violence and disputes in the workplace (Worger, 1987; Harries, 1994, Van der Merwe *et al.*, 2010b).

As was mentioned in Chapter 4, the hazardous mining environment should also be considered when interpreting the fractures observed in this sample (Van der Merwe *et al.,* 2010b). There is often no sure way to distinguish blunt force cranial fractures, as evidence of violent conflict, from cranial fractures resulting from mining accidents such as a rock fall. Therefore, the latter as a cause for the observed cranial fractures, also well documented in archival sources, cannot be discounted.

Injuries resulting from rock falls, mud rushes, mine shaft accidents, and the like, were a regular occurrence in Kimberley (Turrell, 1987; Harries, 1994). The high prevalence of long bone fractures, spondylolysis and longstanding subluxation of the shoulder observed in this population, most likely related to these kinds of injuries, are testimony of the hazards and strenuous demands of daily work in the mines (Van der Merwe *et al*., 2010b).

Fortunately, medical care was available to treat most of these injuries, infections and nutritional diseases. Apart from documentation which clearly describes the treatment of patients in the Kimberley and compound hospitals, the presence of well-healed and reduced fractures and surgical amputations observed in the population provides testimony to this fact (CGHVPP,1898; CGHVPP, 1899).

Several other skeletal and dental changes and anomalies, which would not in themselves have resulted in hospitalization and therefore would be more representative of the non-hospitalized population in Kimberley, were also observed during the investigation of this sample. These included lesions indicative of joint degeneration resulting from strenuous physical labour, nine cases of cribra orbitalia, as well as six cases of individuals presenting with supernumerary teeth.

The prevalence of lesions such as myositis ossificans, spondylolysis, Schmörl's nodes, other degenerative bone changes and enthesopathies were high considering the young age of individuals within the study sample, and can most likely be ascribed to regular engagement in strenuous physical activities. It may be argued that these lesions were not associated solely with mining activities, but could also have resulted from agricultural and other physical enterprises in which these individuals took part at their rural homes. However, when comparing the prevalence of lesions such as Schmörl's nodes (31% of individuals in the Gladstone sample) with other South African rural populations such as the Venda (2.6%), it becomes evident that the Gladstone skeletal sample was significantly more exposed to its causes than would be a group only engaged in regular rural living (L'Abbé, 2005). Dar *et al*. (2009a) recently suggested that Schmörl's nodes may rather be

of congenital origin and not be occupational/activity or disease related. Their conclusions are however not consistent as they, in a later paper, implicate morphological differences and the consequently ability of the vertebrae and vertebral discs to withstand torsion to be responsible for the distribution pattern of Schmörl's nodes across the spine (Dar *et al.*, 2009a,b).

The prevalence of vertebral osteophyte formations (as a result of degenerative disc disease) observed in the Gladstone (14.9%) and Koffiefontein (22.2%) (a contemporary mining sample) samples was statistically comparable (L'Abbé *et al., 2*003). Taking the age distribution of the Gladstone population into account, it is obvious that factors such as strenuous activities associated with mining, or, to a lesser degree, physical labour associated with a rural lifestyle, are more likely to have influenced degenerative changes observed in this population than naturally occurring degeneration patterns related to aging.

Cribra orbitalia was observed in 11% of individuals with orbits in the Gladstone skeletal sample. The cause of this condition is still under debate (Steinbock, 1976; Stuart-Macadam, 1989; Mann & Murphy, 1990; Stuart-Macadam, 1992). Iron-deficiency, vitamin B_{12} and folic acid deficiency, haemolytic anaemia, scurvy, malnutrition, chronic gastrointestinal bleeding, ancylostomiasis, osteoporosis, as well as infectious diseases have all been implicated in the development of the condition (Mann & Murphy, 1990; Thillaud, 2008; Walker *et al.,* 2009). It has even been suggested that the lesions may be a non-specific trait or the result of post-mortem damage (Thillaud, 2008). The prevalence of cribra orbilatia in the Gladstone population (11% of individuals with orbits) was relatively low in comparison with its frequency in other adult South African skeletal samples such as the Griqua (34.6%), Khoe (36.1%) and the 20th Century 'Black' peoples (46.6%) studied by Peckmann (2003) (Griqua $\chi^2 = 11.1$, Khoe $\chi^2 = 11.8$, 'Black' peoples $\chi^2 = 14.9$, p-value < 0.05 for all).

However, it should be considered that cribra orbitalia usually develops during childhood (Steinbock, 1976; Mann & Murphy, 1990; Fairgrieve & Molto, 2000). Therefore, the prevalence of cribra in this population should be interpreted with caution. The lesions may be the remnants of a childhood condition and therefore would not be representative of conditions present (be they nutritional, pathological or hereditary factors resulting in haemolytic anaemia) in the Kimberley context at the time these individuals were working there, since this is a migrant worker population. It would, however, suggest that the majority of individuals within the Gladstone population came from population

groups that were relatively well-adapted to their environments (Larsen, 1997; Wapler *et al.*, 2004).

Should it be possible for cribra orbitalia to develop in adults, conditions resulting in acquired haemolytic anaemia (e.g. malaria) could be the reason for the presence of this lesion in the Gladstone population (Harries, 1994; Walker *et al.*, 2009.). Again, it must be stressed that because the majority of individuals within this sample population were most likely migrant workers, these cribra lesions may be more representative of the various places the migrant worker came from.

The high prevalence of supernumerary teeth in the Gladstone skeletal sample did not add to the understanding of the health status of this 19th century migrant working population, but it did add interesting detail to the demography of the skeletal sample. As was discussed in Chapter 8, the high prevalence of supernumerary teeth (6.7%) observed in this population could not be explained by their ancestry or the presence of syndromal pathological conditions. Therefore, taking the similarity and distribution of these extra teeth into consideration, it was suggested that there may have been a genetic relationship between some of the individuals presenting with the anomaly (van der Merwe & Steyn, 2009). This can be expected in a migrant working population such as this, where young men from the same rural area often traveled to Kimberley in groups, laboured in the mines, and returned to their rural homes once their contracts had expired.

Result obtained in this study gave substance to contemporary reports on the appalling conditions and hazards to which migrant workers were exposed when selling their labour to the mines in late 19th century Kimberley. Migrant workers came on contract, recruited from distant rural areas, to meet the demands for labour. In closed compounds and in the mines they were subjected to harsh and restrictive living conditions, disease, violence and a hazardous working environment. Many of them would never make the return journey home. The remains of some of these latter individuals were unwittingly disturbed from unmarked, forgotten pauper graves. It is hoped that this study will have contributed to the recollection and recognition of these anonymous dead whom Kimberley and South Africa had forgotten, foregrounding something of the real cost in human hardship and loss of life against which the wealth of the nation was built.

References

Blondiaux, J., Duvette, J., Eisenberg, L. and Vatteoni, S. 1994. Microradiographs of leprosy from an osteoarchaeological context. *International Journal of Osteoarchaeology* 4:13-20.

Cape of Good Hope Votes and Proceedings of Parliament. 1899. *Hospitals and Asylums Report for 1898.* Appendix I.

Cape of Good Hope Votes and Proceedings of Parliament. 1900. *Hospitals and Asylums Report for 1899.* Appendix I.

Collins, T.F.B. 1982. The history of southern Africa's first tuberculosis epidemic. *South African Medical Journal* 62:780-788.

Dar, G., Peleg, S., Masharawi, Y., Steinberg, N., May, H. and Hershkovitz, I. 2009a. Demographical aspects of Scmorl nodes, a skeletal study. *Spine* 34:E312-E315.

Dar, G., Masharawi, Y., Peleg, S., Steinberg, N., May, H., Medlej, B., Peled, N., Hershkovitz, I. 2009b. Schmorl's nodes distribution in the human spine and its possible etiology. *European Spine Journal* DOI 10.1007/s00586-009-1238-8.

Donald, P.R. 2001. The epidemiology of tuberculosis in South Africa. In: Chadwick, D.J. and Cradew, G. (eds): *Novartis Foundation Symposium 217 – Genetics and Tuberculosis*. John Wiley & Sons Inc. pp.24-41.

Douglas, M.T., Pietrusewsky, M. and Ike-Quebral, R.M. 1997. Skeletal biology of Apurguan: a precontact chomorro site of Guam. *American Journal of Physical Anthropology* 104:291-313.

Fairgrieve, S.I. and Molto, J.E. 2000. Cribra orbitalia in two temporally disjunct population samples from the Dakhleh Oasis, Egypt. *American Journal of Physical Anthropology* 111:319-331.

Harries, P. 1994. *Work, Culture and Identity. Migrant Laborers in Mozambique and South Africa, c 1860 - 1910.* Johannesburg: Witwatersrand University Press.

Henneberg, R.J. and Henneberg, M. 1993. Possible occurrence of treponematosis in the ancient Greek colony of Metaponto, Italy. *American Journal of Physical Anthropology* S36:107-108.

Jochelson, K. 2001 *The Colour of Diseases, Syphilis and Racism in South Africa 1880 - 1950*. New York: Palgrave.

Jurmain, R. and Bellifemine, V.I. 1997. Patterns of cranial trauma in a prehistoric population from central California. *International Journal of Osteoarchaeology* 7:43-50.

L'Abbé, E.N., Henderson, Z.L. and Loots, M. 2003. Uncovering the nineteenth-century typhoid epidemic at the Koffiefontein Mine, South Africa. *World Archaeology* 35:306-318.

L'Abbé, E.N. 2005. *A Palaeodemographic, Paleopathologic and Macrophologic study of the 20th Century Venda.* Unpublished Ph.D. dissertation. University of Pretoria.

L'Abbé, E.N. and Steyn, M. 2007. Health status of the Venda, a post-antibiotic community in rural South Africa. *International Journal of Osteoarchaeology* 17:492-503.

Larsen, C.S. 1997. *Bioarchaeology. Interpreting Behavior from the Human Skeleton.* Cambridge: Cambridge University Press.

Mann, R.W. and Murphy, S.P. 1990. *Regional Atlas of Bone Disease: A Guide to Pathologic and Normal Variation in the Human Skeleton.* Springfield: Charles C Thomas.

Martin, E. (ed.). 2003. *Oxford Concise Medical Dictionary*. Oxford: Oxford University Press.

McNish, J.T. 1970. *The Glittering Road*. Cape Town: C.Struik.

Medical Officer of Health. 1897. *Ibid.*

Meyer, C., Jung, C., Poenicke, A., Poppe, A. and Alt, K.W. 2002. Syphilis 2001 -a palaeopathological reappraisal. *Homo* 53:39-58.

Morris, D. 2004. Skeletons found at 78 Transvaal Road, Kimberley: report to SAHRA. Unpublished report to the South African Heritage Resources Agency.

Ortner, D.J. 2003. *Identification of Pathological Conditions in Human Skeletal Remains*, 2nd ed. Amsterdam: Academic Press.

Packard, R.M. 1989. *White Plague, Black Labor. Tuberculosis and the Political Economy of Health and Disease in South Africa.* Berkeley: University of California Press.

Peckmann, T. 2003. Possible relationship between porotic hyperostosis and smallpox infections in nineteenth-century populations in the northern frontier, South Africa. *World Archaeology* 35 289-305.

Pietrusewsky, M., Douglas, M.T. and Ike-Quebral, R.M. 1997. As Assessment of health and disease in the Prehistoric inhabitants of the Mariana Islands. *American Journal of Physical Anthropology* 104:315-342.

Rothschild, B.M., Luna Calderon, F., Coppa, A. and Rothschild, C. 2001. First European exposure to syphilis: The Dominican Republic at the time of Columbian contact. *Clinical Infectious Diseases* 31:936-941.

Santos, A.L. and Roberts, C.A. 2001. A picture of tuberculosis in young Portuguese people in the early 20th century: a multidisciplinary study of the skeletal and historical evidence. *American Journal of Physical Anthropology* 115:38-49.

Schultz, M. 2003. Light microscopic analysis in skeletal paleopathology. In: *Identification of Pathological Conditions in Human Skeletal Remains*, 2nd ed. Ortner, D.J. (ed.). Amsterdam: Academic Press, pp.73-108.

Standen, V.G. and Arriaza, B.T. 2000. Trauma in the pre-ceramic coastal population of Northern Chile: violence or occupational hazards? *American Journal of Physical Anthropology* 112:239-249.

Steinbock, R.T. 1976. *Paleopathological Diagnosis and Interpretation*. Springfield: Charles C. Thomas.

Steyn, M., Nienaber, W.C. and Meiring, J.H. 2003. An assessment of the health status and physical characteristics of an early 20th century community at Maroelabult in the North West Province, South Africa. *Homo* 53:131-145.

Stoney, W.W. 1900a. *Annual Report of the Medical Officer of Health, Kimberley, for the Years 1898*.

Stoney, W.W. 1900b. *Annual Report of the Medical Officer of Health, Kimberley, for the Years 1899*.

Stuart-Macadam, P. 1989. Nutritional deficiency diseases: a survey of scurvy, rickets and iron deficiency anemia. In: İşcan, M.Y. and Kennedy, K.A.R. (eds): *Reconstruction of Life from the Skeleton*. New York:Alan R. Liss.

Stuart-Macadam, P. 1992. Porotic hyperostosis: a new perspective. *American Journal of Physical Anthropology* 87:39-47.

Thillaud, P.L. 2008. A new approach to the identification and the interpretation of the various forms of cribra orbitalia. *Histoire des sciences medicales* 42:49-62.

Turrell, R.V. 1987. *Capital and Labour on the Kimberley Diamond Fields 1871-1890.* Cambridge: Cambridge University Press.

Van der Merwe, A.E. and Steyn, M. 2009. A report on the high incidence of supernumerary teeth in skeletal remains from a 19th century mining community from Kimberley, South Africa. *South African Dental Journal* 64:162-166.

Van der Merwe, A.E., Maat, G.J.R. and Steyn M. 2010a. Histomorphological observations of pathological lesions on the anterior tibiae of individuals from a 19th century mining community in Kimberley, South Africa. *International Journal of Osteoarchaeology* 20(2):227-239.

Van der Merwe, A.E., Steyn, M. and L'Abbé E.N. 2010b. Trauma and amputations in 19th century miners from Kimberley, South Africa. *International Journal of Osteoarchaeology* 20(3):291-306

Van der Merwe, A.E., Steyn, M. and Maat, G.J.R. 2010c. Adult scurvy in skeletal remains from late 19th century mineworkers from Kimberley, South Africa. *International Journal of Osteoarchaeology* 20(3):307-316.

Walker, P.L., Bathurst, R.R., Richman, R., Gjerdrum, T. and Andrushko, V.A. 2009. The causes of porotic hyperostosis and cribra orbitalia: a reappraisal of the iron-deficiency-anemia hypothesis. *American Journal of Physical Anthropology* 139:109-125.

Wapler. U, Crubezy, E. and Schultz, M. 2004. Is cribra orbitalia synonymous with anemia? Analysis and interpretation of cranial pathology in Sudan. *American Journal of Physical Anthropology* 123:333-339.

Williams, G.F. 1902. *The Diamond Mines of South Africa: Some Account of their Rise and Development*. London: Macmillan & Co.

Worger, W.H. 1987. *South Africa's City of Diamonds: Mine Workers and Monopoly Capitalism in Kimberley, 1867-1895*. Craighall: AD. Donker.

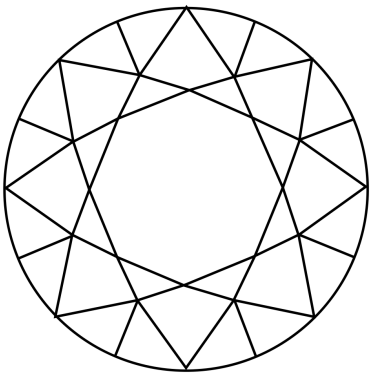

APPENDIX 1

Individual Catalogue



Wesselton mine compound, early1900
(McGregor Museum Kimberley photography nr.834)

Kimberley mine 1876
(McGregor Museum Kimberley photography nr.7615)

Key to abbreviations and terminology used

Stage of preservation

Modified from Gordon and Buikstra (1981)

Excellent	Strong complete bones
Good	Fragile bone
Fair	Fragmented bones
Poor	Extremely fragmented bones

Symbols on dental charts

A	Periapical granulomata/cysts
C	Caries lesions present on tooth
E	Erupting
EH	Enamel hypoplasia
I	Impacted tooth
NP	Tooth not present
P	Pegshaped
PW	Pipesmoker's wear
R	Only roots present due to postmortem damage
U	Unerupted
X	Antemortem tooth loss
Z	Congenitally absent
---	Jaw and teeth not present
/	Postmortem loss

Ancestry

Results based on morphological and metric assessments as described by İşcan *et al.* (2000) and De Villiers (1962)

SA	South African

Pathology abbreviations

DDD	Degenerative disc disease
OA	Osteoarthritis

Bone and joint name abbreviations

AC- joint	Acromioclavicular joint
SI-joint	Sacro-iliac joint
CV	Cervical vertebrae
TV	Thoracic vertebrae
LV	Lumbar vertebrae
C5	Fifth cervical vertebra
C6	Sixth cervical vertebra
L4	Fourth lumbar vertebra
L5	Fifth lumbar vertebra

GLD N8.1

Preservation: Excellent
Bones present: Complete, only phalanges missing
Sex: Female
Age: 15 – 19 years
Stature: 150.7 ± 2.8cm
Ancestry: SA Negroid and KhoeSan
Dentition:

1	2	3	4	5	6	Z	8	9	10	11	12	13	14	15	16
32	31	30	29	28	27	26	25	24	23	22	21	20	19	18	17

Dental Pathology: No
Pathology: Supernumerary vertebrae, Sacralisation L6
Grave goods: Wooden coffin
Comments: Separate amputated leg also found in coffin

GLD N8.1(b)

Preservation: Excellent
Bones present: Left tibia, fibula and foot bones
Sex: Male
Age: Adult
Stature: Unknown
Ancestry: Unknown
Dentition:

---	---	---	---	---	---	---	---	---	---	---	---	---	---	---	---
---	---	---	---	---	---	---	---	---	---	---	---	---	---	---	---

Dental Pathology: No teeth available
Pathology: Amputation and infection
Grave goods: Hospital dressing
Comments: Found in coffin with GLD N8.1

GLD N8.2

Preservation: Excellent
Bones present: Complete
Sex: Male
Age: 23 – 30 years
Stature: 169.9 ± 2.8cm
Ancestry: SA Negroid
Dentition:

1	2	3	4	5	6	7	8	9	10	11	12	13	14	15	16
32	31	30	29	28	27	26	25	24	23	22	21	20	19	18	17

Dental Pathology: Dental calculus
Pathology: Schmörl's nodes, spina bifida, L5 fracture, periostitis, enthesophytes
Grave goods: Iron beads
Comments: No

GLD N8.3

Preservation: Excellent
Bones present: Complete
Sex: Male
Age: 35 – 45 years
Stature: 161.2 ± 2.8cm
Ancestry: SA Negroid and KhoeSan
Dentition:

X	X	X	X	X	6	X	X	X	X	X	X	X	X	X	X
X	X	X	29	28	X	X	X	X	X	22	X	20	X	X	X
			C	C								C		A	

Dental Pathology: Periodontal disease
Pathology: Cribra orbitalia, tuberculosis, metatarsal fracture, enthesophytes
Grave goods: No
Comments: No

GLD N8.4

Preservation: Excellent
Bones present: Complete
Sex: Male
Age: 20 – 25 years
Stature: 172 ± 2.8cm
Ancestry: SA Negroid
Dentition:

1	2	3	4	5	6	7	8	9	10	11	12	13	14	15	16
32	31	30	29	28	27	26	25	24	23	22	21	20	19	18	17

Dental Pathology: Periodontal disease
Pathology: Schmörl's nodes, ossified haematoma (scurvy)
Grave goods: Leather band with iron disc
Comments: Histological investigation performed

GLD N8.5

Preservation: Excellent
Bones present: Complete, carpals, metacarpals and phalanges missing
Sex: Male
Age: 17 – 22 years
Stature: 161.7 ± 2.8cm
Ancestry: SA Negroid
Dentition:

1	2	3	4	5	6	7	8	9	10	11	12	13	14	15	16
32	31	30	29	28	27	26	25	24	23	22	21	20	19	18	17

Dental Pathology: Dental calculus
Pathology: Supernumerary vertebra, Schmörl's nodes, ossified haematoma (scurvy)
Grave goods: Two strands of iron beads
Comments: Histological investigation performed

GLD N 8.6

Preservation: Excellent
Bones present: Complete, only some carpals and phalanges missing
Sex: Female
Age: 15 – 18 years
Stature: 157.6 ± 2.8cm
Ancestry: SA Negroid
Dentition:

1	2	3	4	5	6	7	8	9	10	11	12	13	14	15	16
32	31	30	29	28	27	26	25	24	23	22	21	20	19	18	17

Dental Pathology: No
Pathology: Subperiosteal bone growth, enthesophytes
Grave goods: Iron beads
Comments: No

GLD N8.7

Preservation: Excellent
Bones present: Complete
Sex: Unknown
Age: 6.5 – 7 lunar months
Stature: Unknown
Ancestry: Unknown
Dentition:

NP	NP	NP	NP	NP	NP	NP	NP	NP	NP	NP	NP	NP	NP	NP	NP
NP	NP	NP	NP	NP	NP	NP	NP	NP	NP	NP	NP	NP	NP	NP	NP

Dental Pathology: No
Pathology: No
Grave goods: No
Comments: No

GLD N8.8

Preservation: Excellent
Bones present: Complete, only carpal bones and phalanges missing
Sex: Male
Age: 20-28 years
Stature: 165.2 ± 2.8cm
Ancestry: SA Negroid and KhoeSan
Dentition:

1	2	3	4	5	6	7	8	9	10	11	12	13	14	15	16
32	31	30	29	28	27	26	25	24	23	22	21	20	19	18	17

Dental Pathology: No
Pathology: Atlas congenitally unfused, Non-specific periostitis
Grave goods: Iron bracelet, string of glass bead, copper bangle
Comments: No

GLD N8.9

Preservation: Good
Bones present: Complete
Sex: Unknown
Age: 8 - 16 months
Stature: Unknown
Ancestry: Unknown
Dentition:

NP	NP	NP	NP	NP	NP	NP	NP	NP	NP	NP	NP	NP	NP	NP	NP
NP	NP	NP	NP	NP	NP	NP	NP	NP	NP	NP	NP	NP	NP	NP	NP

U	E	U					U	E	U
51	52	53	54	55	56	57	58	59	60
70	69	68	67	66	65	64	63	62	61
U	E	U					U	E	U

Dental Pathology: No
Pathology: No
Grave goods: Iron fragments
Comments: No

GLD N8.10

Preservation: Excellent
Bones present: Complete
Sex: Male
Age: 20 – 25 years
Stature: 157.8 ± 2.8cm
Ancestry: SA Negroid and KhoeSan
Dentition:

1	2	3	4	5	6	7	8	9	10	11	12	13	14	15	16
32	31	30	29	28	27	26	25	24	23	22	21	20	19	18	17

Dental Pathology: Dental calculus, supernumerary tooth, retained deciduous canine, EH
Pathology: Fracture, supernumerary vertebra, possible treponematosis
Grave goods: Copper earring, iron bracelet
Comments: No

GLD N31 E.1

Preservation: Excellent
Bones present: Complete
Sex: Male
Age: 30 – 40 years
Stature: 171.6 ± 2.8cm
Ancestry: SA Negroid and KhoeSan
Dentition:

1	2	3	4	5	6	7	8	9	10	11	12	13	14	15	X
32	31	30	29	28	27	26	25	24	23	22	21	20	19	18	17

Dental Pathology: EH
Pathology: Enthesophytes, sacralization L5, spondylolysis L4, cranial fractures
Grave goods: No
Comments: Histological investigation performed

GLD N31.E.2

Preservation: Excellent
Bones present: Complete only phalanges missing
Sex: Male
Age: 16 – 19 years
Stature: 161.2 ± 2.8cm
Ancestry: SA Negroid and Caucasoid
Dentition:

1	2	3	4	5	6	7	8	9	10	11	12	13	14	15	16
32	31	30	29	28	27	26	25	24	23	22	21	20	19	18	17
												C			

Dental Pathology: EH
Pathology: Cribra orbitalia, Schmörl's nodes, supernumerary vertebra
Grave goods: No
Comments: No

GLD N31.E.3

Preservation: Excellent
Bones present: Complete, only some tarsal bones, carpal bones and phalanges missing
Sex: Male
Age: 25 – 32 years
Stature: 155 ± 2.8cm
Ancestry: SA Negroid and Caucasoid
Dentition:

C									P						
1	2	3	4	5	6	/	/	9	10	11	12	13	14	15	/
32	31	30	29	28	27	26	25	24	23	22	21	20	19	18	17

Dental Pathology: Periodontal disease, dental calculus
Pathology: Cribra orbitalia, treponematosis, supernumerary vertebra
Grave goods: Iron bangle
Comments: No

GLD N31.E.4

Preservation: Excellent
Bones present: Complete, only some carpal and tarsal bones and phalanges missing
Sex: Male
Age: 35 – 45 years
Stature: 160 ± 2.8cm
Ancestry: SA Negroid and KhoeSan and Caucasoid
Dentition:

Z	2	3	4	5	6	7	8	9	/	11	12	13	X	X	Z
Z	31	30	29	28	27	26	25	24	23	22	21	20	19	18	Z
		C	C			P	P	P	P			C	C	C	
			A									A	A		

Dental Pathology: Dental wear, dental calculus, periodontal disease
Pathology: Cribra orbitalia, compression fracture, supernumerary vertebra, metacarpal fracture, subperiosteal bone growth
Grave goods: No
Comments: No

GLD N13.E.5

Preservation: Good
Bones present: Complete, only few tarsal bones and phalanges missing
Sex: Male
Age: 25 – 38 years
Stature: 158.1 ± 2.8cm
Ancestry: SA Negroid and KhoeSan
Dentition:

C															
1	2	3	4	5	6	7	8	9	10	11	12	13	14	15	16
32	31	30	29	28	27	26	25	24	23	22	21	20	19	18	17

Dental Pathology: Periodontal disease, dental calculus
Pathology: Schmörl's nodes, subperiosteal striations
Grave goods: Copper string, cloth
Comments: No

GLD N34.1

Preservation: Good
Bones present: Skull and mandible fragmented, postcranial remains complete
Sex: Male
Age: 18 – 21 years
Stature: 162.2 ± 2.8cm
Ancestry: Unknown
Dentition:

---	---	---	---	---	---	---	---	---	---	---	---	---	---	---	---
32	31	30	29	28	27	---	---	---	---	---	---	---	---	---	---
	C														

Dental Pathology: No
Pathology: Schmörl's nodes
Grave goods: No
Comments: No

GLD N34.2

Preservation: Good
Bones present: Skull, mandible, tibiae, fibulae, hands and left foot missing
Sex: Male
Age: 25 - 35 years
Stature: 172 ± 2.8cm
Ancestry:
Dentition:

---	---	---	---	---	---	---	---	---	---	---	---	---	---	---	---
---	---	---	---	---	---	---	---	---	---	---	---	---	---	---	---

Dental Pathology: No
Pathology: Possible sharp trauma
Grave goods: Iron bangle, white beads, green beads
Comments: No

GLD N34.3

Preservation: Excellent
Bones present: Complete
Sex: Male
Age: 25 – 35 years
Stature: 168.7 ± 2.8cm
Ancestry: SA Negroid and KhoeSan
Dentition:

	C	C									C				
1	2	3	X	5	6	7	8	9	10	11	12	X	X	15	16
32	X	X	29	28	27	26	/	24	/	22	21	20	19	18	X
C			A									C	C	C	

Dental Pathology: Periodontal disease
Pathology: Cribra orbitalia, amputation, supernumerary vertebra, fractures, enthesophytes
Grave goods: Ring, iron bangle, copper bangle
Comments: No

GLD N34.4

Preservation: Excellent
Bones present: Complete
Sex: Male
Age: 18 – 21 years
Stature: 180.7 ± 2.8cm
Ancestry: SA Negroid
Dentition:

1	2	3	4	5	6	7	8	9	10	11	12	13	14	15	16
32	31	30	29	28	27	26	25	24	23	22	21	20	19	18	17
		C												C	

Dental Pathology: EH
Pathology: Enthesophytes, Schmörl's nodes, localized superiosteal bone growth
Grave goods: No
Comments: No

GLD N34.5

Preservation: Excellent
Bones present: Complete
Sex: Male
Age: 15 – 18 years
Stature: 162.2 ± 2.8cm
Ancestry: SA Negroid and KhoeSan
Dentition:

1	2	3	4	5	6	X	X	X	X	11	12	13	14	15	16
32	31	30	29	28	27	26	25	24	23	22	21	20	19	18	17
	C													C	

Dental Pathology: Dental wear, dental calculus, EH
Pathology: Asymmetric sacrum, healed fracture
Grave goods: No
Comments: No

GLD N34.6

Preservation: Excellent
Bones present: Complete
Sex: Male
Age: 22 – 28 years
Stature: 165.6 ± 2.8cm
Ancestry: SA Negroid and KhoeSan
Dentition:

1	2	3	4	5	6	7	8	9	10	11	12	13	14	15	16
32	31	30	29	28	27	26	25	24	23	22	21	20	19	18	17

Dental Pathology: Dental wear, EH, stained
Pathology: Schmörl's nodes, healed fracture, subperiosteal bone growth
Grave goods: No
Comments: No

GLD N34.7

Preservation: Excellent
Bones present: Complete
Sex: Male
Age: 30 – 40 years
Stature: 157 ± 2.8cm
Ancestry: SA Negroid and KhoeSan
Dentition:

1	2	3	4	5	6	7	X	9	10	11	12	13	14	15	16
32	31	X	29	28	27	26	25	24	23	22	21	20	19	18	17
C		A											C		

Dental Pathology: Dental wear
Pathology: Enthesophytes, myositis ossificans
Grave goods: Beads
Comments: Received autopsy

GLD N34.8

Preservation: Excellent
Bones present: Complete, few carpal bones and phalanges missing
Sex: Female
Age: 20 – 28 years
Stature: 162 ± 2.8cm
Ancestry: SA Negroid and KhoeSan
Dentition:

	C														
1	2	3	4	5	6	7	8	9	10	11	12	13	14	15	16
32	31	30	29	28	27	26	25	24	23	22	21	20	19	18	17
												C			

Dental Pathology: Periodontal disease
Pathology: Spondylolysis, possible sharp trauma
Grave goods: Blue and white beads around neck, copper beads
Comments: No

GLD N34.9

Preservation: Excellent
Bones present: Complete
Sex: Male
Age: 22 – 30 years
Stature: 165.5 ± 2.8cm
Ancestry: SA Negroid and KhoeSan
Dentition:

1	2	3	4	5	6	7	8	9	10	11	12	13	14	15	16
32	31	30	29	28	27	26	25	24	23	22	21	20	19	18	17

Dental Pathology: Dental calculus
Pathology: Fracture, ankylosis of C2 and C3
Grave goods: No
Comments: No

GLD N34.10

Preservation: Excellent
Bones present: Complete
Sex: Male
Age: 22 – 30 years
Stature: 172.5 ± 2.8cm
Ancestry: SA Negroid
Dentition:

1	2	3	4	5	6	7	8	9	10	11	12	13	14	15	16
32	31	30	29	28	27	26	25	24	23	22	21	20	19	18	17
C	C													C	A

Dental Pathology: No
Pathology: Periostitis, Schmörl's nodes
Grave goods: No
Comments: No

GLD N34.11

Preservation: Excellent
Bones present: Mostly complete, ribs broken, carpals, tarsals and phalanges missing
Sex: Male
Age: 14 – 18 years
Stature: 172.5 ± 2.8cm
Ancestry: SA Negroid and KhoeSan
Dentition:

1	2	3	4	5	6	7	8	/	10	11	12	13	14	15	16
32	31	30	29	28	27	26	25	24	23	22	21	20	19	18	17

Dental Pathology: No
Pathology: No
Grave goods: No
Comments: No

GLD N34.12

Preservation: Excellent
Bones present: Complete, few carpal bones and phalanges missing, ribs fragmented
Sex: Male
Age: 20 – 28 years
Stature: 165.8 ± 2.8cm
Ancestry: SA Negroid
Dentition:

1	2	3	4	5	6	7	8	9	X	11	12	13	14	15	16
32	31	30	29	28	27	26	25	24	23	22	21	20	19	18	17
															C

Dental Pathology: Dental crowding
Pathology: Myositis ossificans, OA hip joint, nasal fracture
Grave goods: No
Comments: No

GLD N34.13

Preservation: Excellent
Bones present: Complete
Sex: Male
Age: 25 – 30 years
Stature: 168.9 ± 2.8cm
Ancestry: SA Negroid and KhoeSan
Dentition:

1	2	3	4	5	6	7	8	9	10	11	12	13	14	15	16
32	31	30	29	28	27	26	25	24	23	22	21	20	19	18	17

I

Dental Pathology: Slight dental calculus, dental wear
Pathology: Myositis ossificans, enthesophytes, Schmörl's nodes, ossified haematoma (scurvy)
Grave goods: No
Comments: Histological investigation performed

GLD N34.14

Preservation: Excellent
Bones present: Complete
Sex: Male
Age: 22 – 29 years
Stature: 173 ± 2.8cm
Ancestry: SA Negroid and KhoeSan
Dentition:

1	2	3	4	5	6	7	8	9	10	11	12	13	14	15	16
32	31	30	29	28	27	26	25	24	23	22	21	20	19	18	17

Dental Pathology: No
Pathology: Schmörl's nodes, enthesophytes, subperiosteal bone growth
Grave goods: Six strings of iron beads, two strings of copper beads
Comments: No

GLD N38.1

Preservation: Excellent
Bones present: Complete except for missing left mandibular ramus, left patella, one rib, a few carpal bones and phalanges
Sex: Male
Age: 23 – 30 years
Stature: 160 ± 2.8cm
Ancestry: SA Negroid and KhoeSan
Dentition:

1	2	3	4	5	6	7	8	9	10	11	12	13	14	15	16
32	31	30	29	28	27	26	25	24	23	22	21	20	19	18	17

Dental Pathology: No
Pathology: Rib fracture, Schmörl's nodes, enthesophytes, subperiosteal bone growth
Grave goods: Iron bead, metal fragments and coffin
Comments: No

GLD N38.2

Preservation: Excellent
Bones present: Complete, only phalanges missing
Sex: Male
Age: 25 – 30 years
Stature: 168.7 ± 2.8cm
Ancestry: SA Negroid and KhoeSan
Dentition:

									PW	PW					
1	2	3	4	5	R	R	8	9	10	11	12	13	14	15	16
32	31	30	29	28	27	26	25	24	23	22	21	20	19	18	17

Dental Pathology: No
Pathology: Enthesophytes, fractures, amputation, possible sharp trauma
Grave goods: No
Comments: No

GLD N38.3

Preservation: Excellent
Bones present: Complete only one metacarpal and few phalanges missing. Extra carpal bone
Sex: Male
Age: 30 – 40 years
Stature: 166 ± 2.8cm
Ancestry: SA Negroid and KhoeSan
Dentition:

							C	C							
X	2	3	4	5	6	7	8	9	10	11	12	13	14	15	X
32	31	30	29	28	27	26	25	24	23	22	21	X	19	18	17
	P												C		C

Dental Pathology: Dental calculus
Pathology: Colle's fracture, Pott's fracture, myositis ossificans
Grave goods: Copper bangle, iron bands, buttons, piece of leather with metal attached to it, cluster of shells, bones and buttons (ditaola)
Comments: No

GLD N38.5

Preservation: Excellent
Bones present: Complete, only few carpals and phalanges missing
Sex: Male
Age: 20 – 25 years
Stature: 173 ± 2.8cm
Ancestry: SA Negroid and Caucasoid
Dentition:

1	2	3	4	5	6	7	8	9	10	11	12	13	14	15	16
32	31	30	29	28	27	26	25	24	23	22	21	20	19	18	17
C															

Dental Pathology: No
Pathology: Possible sharp trauma, ossified haematoma, enthesophytes
Grave goods: No
Comments: Histological investigations performed

GLD N 38.6

Preservation: Excellent
Bones present: Complete, only few carpal bones and phalanges missing
Sex: Male
Age: 25 – 32 years
Stature: 158.1 ± 2.8 cm
Ancestry: SA Negroid and KhoeSan
Dentition:

1	2	3	4	5	6	/	8	9	10	11	12	13	14	15	16
32	31	30	29	28	27	26	25	24	23	22	21	20	19	18	17

Dental Pathology: Periodontal disease
Pathology: Ankylosis C5-C6, Schmörl;'s nodes, enthesophytes
Grave goods: No
Comments: No

GLD N38.7

Preservation: Excellent
Bones present: Complete, no hands
Sex: Male
Age: 38 – 46 years
Stature: 164.4 ± 2.8cm
Ancestry: SA Negroid and KhoeSan
Dentition:

1	2	3	4	5	6	7	8	9	10	11	12	13	14	15	16
32	31	30	29	28	27	26	25	24	23	22	21	20	19	18	17
C															C

Dental Pathology: Dental wear, dental calculus
Pathology: Possible treponematosis, OA shoulder joint, enthesophytes, DDD
Grave goods: No
Comments: No

GLD N 38.8

Preservation: Excellent
Bones present: Complete, extra pair of hands and feet
Sex: Male
Age: 30 – 40 years
Stature: 162.7 ± 2.8cm
Ancestry:
Dentition:

											C				
1	2	3	4	5	6	7	8	9	10	11	12	13	14	15	16
32	31	30	29	28	27	26	25	24	23	22	21	20	19	18	17

Dental Pathology: Supernumerary tooth (lost antemortem), dental crowding
Pathology: Schmörl's nodes, enthesophytes
Grave goods: No
Comments: No

GLD N38.9

Preservation: Good
Bones present: Complete. Skull, mandible, os coxae and ribs fragmented. Extra foot
Sex: Male
Age: 40 – 50 years
Stature: 159.1 ± 2.8cm
Ancestry: SA Negroid
Dentition:

	C				C									C	
1	2	3	4	5	6	7	8	9	10	11	12	13	14	15	16
32	31	30	29	28	27	26	25	24	23	/	21	20	19	18	17
														C	C

Dental Pathology: No
Pathology: Fractures, enthesophytes
Grave goods: No
Comments: No

GLD N74.1

Preservation: Excellent
Bones present: Complete, only a few phalanges missing
Sex: Female
Age: 40 – 50 years
Stature: 155.4 ± 2.8cm
Ancestry: SA Negroid and KhoeSan
Dentition:

									PW	PW					
1	2	3	4	5	6	7	8	9	10	11	12	13	14	15	16
32	31	30	29	28	27	26	25	24	23	22	21	20	19	18	17

Dental Pathology: Periodontal disease
Pathology: Healed fractures, enthesophyts, DDD
Grave goods: Two copper pins forming a cross
Comments: No

GLD N74.2

Preservation: Excellent
Bones present: Complete, some missing carpals, metacarpals and phalanges
Sex: Male
Age: 18 – 22 years
Stature: 164.6 ± 2.8cm
Ancestry: SA Negroid
Dentition:

	C											C			
1	2	3	4	5	6	7	8	9	10	11	12	13	14	15	16
32	31	30	X	28	27	26	25	24	23	22	21	20	19	18	17
												C			

Dental Pathology: Dental calculus, periodontal disease
Pathology: Healed fracture, subperiosteal bone growth
Grave goods: Leather, metal buttons, pearl button, remains of a shoe, fragments of iron bangle
Comments: No

GLD 74.3

Preservation: Excellent
Bones present: Complete, few carpals, metacarpals and phalanges missing
Sex: Male
Age: 17 – 22 years
Stature: 161.4 ± 2.8cm
Ancestry: SA Negroid and Caucasoid
Dentition:

1	2	3	4	5	6	7	8	9	10	11	12	13	14	15	16
32	31	30	29	28	27	26	25	24	23	22	21	20	19	18	17

Dental Pathology: No
Pathology: Treponematosis, spondylolysis of L5
Grave goods: Copper fragments
Comments: No

GLD N74.4

Preservation: Excellent
Bones present: Complete, only few phalanges missing
Sex: Male
Age: 30 – 40 years
Stature: 180.3 ± 2.8cm
Ancestry: SA Negroid
Dentition:

	C														
1	2	3	4	5	6	7	8	9	10	11	12	13	14	15	16
32	X	X	R	28	/	26	25	24	23	22	21	20	/	18	17
													A	C	C

Dental Pathology: Dental calculus, periodontal disease
Pathology: Parry fracture, myositis ossificans, Schmörl's nodes, enthesophytes
Grave goods: No
Comments: Histological investigation performed

GLD N74.5

Preservation: Excellent
Bones present: Complete, only carpals, metacarpals and phalanges missing
Sex: Male
Age: 40 – 55 years
Stature: 167.2 ± 2.8cm
Ancestry: SA Negroid
Dentition:

						A									
1	2	3	4	5	6	7	8	9	10	11	12	13	14	15	16
32	31	30	29	28	X	26	25	24	23	22	21	20	19	18	17

Dental Pathology: Dental calculus
Pathology: Schmörl's nodes, SI-joint fusion, enthesophytes, healed fracture, longstanding subluxation, OA left foot
Grave goods: Three small metal object, iron bangles, iron object attached to a piece of cloth
Comments: No

GLD N74.6

Preservation: Excellent
Bones present: Complete, only few carpal bones and phalanges missing
Sex: Male
Age: 30 – 46 years
Stature: 163.1 ± 2.8cm
Ancestry: SA Negroid
Dentition:

1	2	3	4	5	6	7	8	9	10	11	12	13	14	15	16
32	31	30	29	28	27	26	25	24	23	22	21	20	19	18	17
		C	C												
		A													

Dental Pathology: Dental wear, dental calculus, periodontal disease
Pathology: Healed fractures, OA AC-joint, non-specific periostitis, enthesophytes
Grave goods: No
Comments: Autopsy was performed

GLD N74.7

Preservation: Excellent
Bones present: Complete, only phalanges missing
Sex: Male
Age: 30 – 46 years
Stature: 158.3 ± 2.8cm
Ancestry: SA Negroid and KhoeSan
Dentition:

					PW	PW									
1	2	3	4	5	6	7	8	9	10	11	12	13	14	15	16
32	31	30	29	28	27	26	25	24	23	22	21	20	19	18	17

Dental Pathology: Dental calculus, dental wear
Pathology: DDD, spondylolysis, enthesophytes, OA hip joints, treponematosis
Grave goods: Iron and copper bangle
Comments: No

GLD N74.8

Preservation: Excellent
Bones present: Complete, few phalanges missing
Sex: Male
Age: 16 – 20 years
Stature: 171.3 ± 2.8cm
Ancestry: SA Negroid and KhoeSan
Dentition:

														C	
1	2	3	4	5	6	7	8	9	10	11	12	13	14	15	16
32	31	30	29	28	27	26	25	24	23	22	21	20	19	18	17
															C

Dental Pathology: No
Pathology: Subperiosteal bone growth, spondylolysis of L4, enthesophytes
Grave goods: No
Comments: No

GLD N 74.9

Preservation: Excellent
Bones present: Complete, few carpal bones and phalanges missing
Sex: Male
Age: 25 – 29 years
Stature: 172.5 ± 2.8cm
Ancestry: SA Negroid
Dentition:

1	2	3	4	5	6	7	8	9	10	11	12	13	14	15	16
32	31	30	29	28	27	26	25	/	23	22	21	20	19	18	17

Dental Pathology: No
Pathology: Ossified haematomas, enthesophytes
Grave goods: Copper ring
Comments: No

GLD N74.10

Preservation: Excellent
Bones present: Complete, only few missing phalanges
Sex: Male
Age: 20 – 24 years
Stature: 163.1 ± 2.8cm
Ancestry: SA Negroid
Dentition:

														C	
1	2	R	4	5	6	7	8	9	10	11	12	13	14	15	16
32	31	30	29	28	27	26	25	24	23	22	21	20	19	18	17
													C	C	

Dental Pathology: Supernumerary teeth, EH
Pathology: Enthesophytes, OA in AC-joint, Schmörl's nodes
Grave goods: No
Comments: No

GLD N74.11

Preservation: Excellent
Bones present: Complete, few missing phalanges
Sex: Male
Age: 16 – 20 years
Stature: 162 ± 2.8cm
Ancestry: SA Negroid and KhoeSan
Dentition:

1	2	3	4	5	6	7	8	9	10	11	12	13	14	15	16
32	31	30	29	28	27	26	25	24	23	22	21	20	19	18	17

Dental Pathology: EH
Pathology: Enthesophytes, Schmörl's nodes, premature synostosis of sagittal suture
Grave goods: Copper bangle
Comments: No

GLD N74.12

Preservation: Excellent
Bones present: Complete, only few missing phalanges
Sex: Male
Age: 30 – 45 years
Stature: 168 ± 2.8cm
Ancestry: SA Negroid and KhoeSan
Dentition:

1	2	3	4	5	6	7	8	/	10	11	12	13	14	15	16
32	31	30	29	28	27	26	25	24	23	22	21	20	19	18	17

Dental Pathology: Periodontal disease
Pathology: No
Grave goods: Copper leg band, 3 strings of copper beads, belt buckle
Comments: No

GLD N100.1

Preservation: Excellent
Bones present: Complete, only mandible and 3 vertebrae missing
Sex: Male
Age: 40 – 55 years
Stature: 167 ± 2.8cm
Ancestry: SA Negroid
Dentition:

1	2	X	4	5	6	/	/	/	10	11	12	13	X	X	16
---	---	---	---	---	27	26	---	---	---	---	---	---	---	---	---

Dental Pathology: Periodontal disease, dental wear
Pathology: Enthesophytes, non-specific periostitis, DDD, healed fracture
Grave goods: No
Comments: No

GLD N100.2

Preservation: Excellent
Bones present: Complete, few tarsal bones, carpals and phalanges missing
Sex: Male
Age: 28 – 38 years
Stature: 166.3 ± 2.8cm
Ancestry: SA Negroid
Dentition:

1	2	3	4	5	6	7	8	9	10	11	12	13	14	15	16
32	31	30	/	28	27	26	25	/	23	22	/	20	19	18	17
C														C	

Dental Pathology: No
Pathology: Treponematosis, healed fracture, DDD, enthesophytes
Grave goods: No
Comments: No

GLD N100.3

Preservation: Excellent
Bones present: Complete
Sex: Male
Age: 25 – 30 years
Stature: 166 ± 2.8cm
Ancestry: SA Negroid
Dentition:

1	2	3	4	5	6	/	X	X	/	R	12	13	14	15	16
32	31	30	29	28	27	X	X	X	X	X	R	20	19	18	17

Dental Pathology: No
Pathology: Enthesophytes
Grave goods: No
Comments: No

GLD N100.4

Preservation: Excellent
Bones present: Complete, hands and feet are incomplete
Sex: Male
Age: 18 – 23 years
Stature: 160 ± 2.8cm
Ancestry: SA Negroid
Dentition:

1	2	3	4	5	6	7	8	9	10	11	12	13	14	15	16
32	31	30	29	28	27	26	25	24	23	22	21	20	19	18	17

Dental Pathology: Slight dental calculus
Pathology: Cribra orbitalia, craniostenosis, supernumerary vertebrae
Grave goods: No
Comments: Possible burn marks on some bones

GLD N100.5

Preservation: Excellent
Bones present: Complete, hands and feet incomplete
Sex: Female
Age: 19 – 23 years
Stature: 157.3 ± 2.8cm
Ancestry: SA Negroid and KhoeSan
Dentition:

1	2	3	4	5	6	7	8	9	10	11	12	13	14	15	16
32	31	30	29	28	27	26	25	X	X	22	21	20	19	18	17
		C											C		

Dental Pathology: Supernumerary tooth, EH
Pathology: Non-specific periostitis
Grave goods: Copper bangle
Comments: No

GLD NOP3/4.1

Preservation: Excellent
Bones present: Complete, few phalanges missing
Sex: Male
Age: 25 – 35 years
Stature: 161.9 ± 2.8cm
Ancestry: SA Negroid
Dentition:

			C												
1	2	3	4	5	6	7	8	9	10	11	12	13	14	15	16
32	31	30	29	28	27	26	25	24	23	22	21	20	19	18	17

Dental Pathology: Dental wear
Pathology: Spondylolysis of L5, DDD, possible kyphoscoliosis, possible treponematosis
Grave goods: No
Comments: No

GLD NOP3/4. 2

Preservation: Excellent
Bones present: Complete, missing phalanges
Sex: Male
Age: 25 – 35 years
Stature: 165.3 ± 2.8cm
Ancestry: SA Negroid and KhoeSan
Dentition:

C	C					C			C		C			C	
1	2	3	4	5	6	7	8	9	10	11	12	13	14	15	16
X	X	X	29	28	27	26	25	24	23	22	21	20	X	X	17
				C											C

Dental Pathology: EH
Pathology: Treponematosis
Grave goods: Button
Comments: Histological investigations performed

GLD S1.1

Preservation: Good
Bones present: Only skull, right scapula, 6 CV, 1TV
Sex: Male
Age: 30 – 50 years
Stature: Unknown
Ancestry: SA Negroid
Dentition:

1	2	3	4	5	6	7	8	9	10	11	12	13	14	15	16
---	---	---	---	---	---	---	---	---	---	---	---	---	---	---	---

Dental Pathology: EH, dental calculus
Pathology: No
Grave goods: No
Comments: No

GLD S1.2

Preservation: Good
Bones present: Only skull, mandible, 6 ribs, 4 LV, 1 CV
Sex: Male
Age: 30 – 45 years
Stature: Unknown
Ancestry: SA Negroid
Dentition:

1	2	3	4	5	6	7	8	9	10	11	12	13	14	15	16
32	31	30	29	28	27	26	25	24	23	22	21	20	19	18	17

Dental Pathology: Periodontal disease, dental calculus
Pathology: Nasal fracture
Grave goods: No
Comments: No

GLD S1.3

Preservation: Good
Bones present: Missing ulnae, radii, 5 CV, 5 LV, some carpal bones and phalanges
Sex: Male
Age: 20 – 24 years
Stature: 170.4 ± 2.8cm
Ancestry: SA Negroid and KhoeSan
Dentition:

															C
1	2	3	4	5	6	7	8	9	10	11	12	13	14	15	16
32	31	X	29	28	27	26	25	24	23	22	21	20	19	18	17
	C														

Dental Pathology: No
Pathology: Non-specific periostitis, enthesophytes, possible treponematosis, ossified haematoma (scurvy)
Grave goods: No
Comments: Histological investigations performed

GLD S1.4

Preservation: Good
Bones present: Missing 1 TV, several ribs, 6 carpals, 4 metacarpals and phalanges
Sex: Male
Age: 20 – 25 years
Stature: 164.8 ± 2.8cm
Ancestry: SA Negroid
Dentition:

	C					C								C	
1	2	3	4	5	6	7	8	9	10	11	12	13	X	15	16
32	31	30	29	28	27	26	25	24	23	22	21	20	19	18	17
		C	C												

Dental Pathology: EH
Pathology: Enthesophytes, Schmörl's nodes, OA interphalangeal joints
Grave goods: Metal plate
Comments: No

GLD S1.5

Preservation: Good
Bones present: Hands and feet incomplete
Sex: Male
Age: 35 – 45 years
Stature: 162.9 ± 2.8cm
Ancestry: SA Negroid and KhoeSan
Dentition:

1	2	3	4	5	R	7	8	9	10	11	12	13	14	15	16
32	31	30	29	28	27	26	25	24	23	22	21	20	19	18	17

Dental Pathology: EH, periodontal disease, dental calculus
Pathology: Enthesophytes, OA of AC-joint
Grave goods: Copper bangle
Comments: No

GLD S1.6

Preservation: Good
Bones present: Complete, missing phalanges
Sex: Male
Age: 18 – 23 years
Stature: 172.8 ± 2.8cm
Ancestry: Unknown
Dentition:

---	---	---	---	---	---	---	---	---	---	---	---	---	---	---	---
32	31	30	29	28	27	26	25	24	23	22	21	20	19	18	17

Dental Pathology: No
Pathology: OA talocalcaneal joint
Grave goods: No
Comments: No

GLD S2.1

Preservation: Good
Bones present: Complete, phalanges missing.
Sex: Male
Age: 35 – 45 years
Stature: Unknown
Ancestry: KhoeSan
Dentition:

														C	
1	2	3	4	5	6	7	8	9	10	11	12	13	14	15	16
32	31	30	29	28	27	26	25	/	23	22	21	20	19	18	17

Dental Pathology: Periodontal disease, dental calculus
Pathology: Subperiosteal bone growth, enthesophytes
Grave goods: No
Comments: No

GLD S2.2

Preservation: Good
Bones present: 3 individuals A (fragmented postcranial remains), individual B (left femur and patella), individual C (distal radius and ulna)
Sex: Individual A – Male
Individual B – Male
Individual C – unknown
Age: Individuals A, B and C – adult
Stature: Unknown
Ancestry: Unknown
Dentition:

---	---	---	---	---	---	---	---	---	---	---	---	---	---	---	---
---	---	---	---	---	---	---	---	---	---	---	---	---	---	---	---

Dental Pathology: No
Pathology: Individuals A – Subperiosteal bone growth, enthesophytes
Individuals B – No
Individuals C – No
Grave goods: No
Comments: No

GLD S2.3

Preservation: Good
Bones present: Missing scapulae, claviculae, os coxae and feet
Sex: Male
Age: 20 – 25 years
Stature: Unknown
Ancestry: SA Negroid and KhoeSan
Dentition:

1	2	3	4	5	6	7	8	/	10	/	12	13	14	15	16
32	31	30	29	28	27	26	25	24	23	22	21	20	19	18	17

Dental Pathology: No
Pathology: Ankylosis left tibio-talar joint, fractures
Grave goods: No
Comments: No

GLD S2.4

Preservation: Excellent
Bones present: Complete, only phalanges missing
Sex: Female
Age: 33 – 43 years
Stature: 159.8 ± 2.8cm
Ancestry: SA Negroid and KhoeSan
Dentition:

														C	
1	2	3	4	5	6	7	8	9	10	11	12	13	14	15	16
32	X	30	29	28	27	26	25	24	23	22	21	20	19	X	17
A			C										A		

Dental Pathology: Periodontal disease, dental calculus
Pathology: Fractures, enthesophytes, myositis ossificans, ossified haematoma
Grave goods: Copper ring, piece of woven material
Comments: Histological investigations performed

GLD S2.5

Preservation: Fair
Bones present: Hands and feet missing
Sex: Male
Age: 25 – 30 years
Stature: 162.9 ± 2.8cm
Ancestry: SA Negroid
Dentition:

1	2	3	4	5	6	7	8	9	10	11	12	13	14	15	16
32	31	30	29	28	27	26	25	24	23	22	21	20	19	18	17

Dental Pathology: Periodontal disease
Pathology: OA AC-joint, enthesophytes,
Grave goods: Piece of metal
Comments: No

GLD S2.6

Preservation: Excellent
Bones present: Complete, left foot missing
Sex: Male
Age: 35 – 46 years
Stature: 165.8 ± 2.8cm
Ancestry: SA Negroid and KhoeSan
Dentition:

1	2	3	4	5	6	7	8	9	10	11	12	13	14	15	X
32	31	30	29	28	27	26	25	24	23	22	21	20	19	18	17

Dental Pathology: Slight dental calculus
Pathology: Amputation left foot, enthesophytes, OA SI-joint, healed metacarpal fracture, longstanding subluxation sternoclavicular joint
Grave goods: No
Comments: No

GLD S2.7

Preservation: Excellent
Bones present: Three individuals were present. Individual A – Complete, individual B – humeral shaft, individual C – radius, ulna and hand
Sex: Individual A – Male
Individual B and C – Unknown
Age: Individual A – 38 – 50 years
Individual B – Unknown
Individual C – Adult
Stature: Individual A – 163.1 ± 2.8cm
Individuals B and C – Unknown
Ancestry: Individual A – SA Negroid
Individuals B and C – Unknown
Dentition: Only individual A

C															
1	2	3	4	5	6	7	8	9	10	11	12	13	14	15	16
32	31	30	29	28	27	26	25	24	23	22	21	20	19	18	17
	C														

Dental Pathology: Individual A - Periodontal disease, dental calculus
Pathology: Individual A – OA AC-joint, enthesophytes, Schmörl's nodes
Individual B – Distal and proximally amputated humeral shaft
Individual C – Amputated forearm, infection, ankylosis of carpal bones
Grave goods: Hospital dressing
Comments: No

GLD S2.8

Preservation: Good
Bones present: Missing hands and right patella
Sex: Male
Age: 22 – 30 year
Stature: 163.1 ± 2.8cm
Ancestry: SA Negroid
Dentition:

	C			C			A				C		A		C
---	R	3	4	5	6	/	R	9	10	11	12	13	/	X	16
32	X	X	29	28	27	26	/	/	23	22	X	X	19	X	17
													C		C

Dental Pathology: Periodontal disease, retained deciduous canine, dental wear
Pathology: Supernumerary vertebrae, enthesophytes
Grave goods: No
Comments: No

GLD S2.9

Preservation: Excellent
Bones present: Complete, carpal bones missing
Sex: Male
Age: 35 – 48 years
Stature: 167.5 ± 2.8cm
Ancestry: SA Negroid and KhoeSan
Dentition:

1	2	3	4	5	6	7	8	9	10	11	12	13	14	15	16
32	31	30	29	28	27	26	25	24	23	22	21	20	19	18	17
	C												C	C	

Dental Pathology: Periodontal disease
Pathology: Enthesophytes, healed fractures, OA of AC-joints, Schmörl's nodes
Grave goods: No
Comments: Histological investigations performed

GLD S2.10

Preservation: Good
Bones present: Complete, one carpal bone and phalanges missing
Sex: Female
Age: 25 – 32 years
Stature: 149.6 ± 2.8cm
Ancestry: Negroid
Dentition:

C															
1	2	3	4	5	6	7	8	9	10	11	12	13	14	15	16
32	31	30	29	28	27	26	25	24	23	22	21	20	19	18	17

Dental Pathology: Dental wear, dental calculus
Pathology: No
Comments: No

GLD S3.1

Preservation:	Good
Bones present:	Individuals A – Skull, mandible, right humerus, radius and ulna, os coxae, sacrum, femora, hands and feet Individuals B – Maxilla
Sex:	Individual A – Male Individuals B – Unknown
Age:	Individual A – 40 – 50 years Individual B – Adult
Stature:	Individual A – 165.8 ± 2.8cm Individual B – Unknown
Ancestry:	Individual A – SA Negroid Individual B – Unknown

Dentition:

Individual A

												C			
1	2	X	4	5	6	7	8	9	10	11	12	13	X	15	16
32	31	30	29	28	27	26	25	24	23	22	21	X	19	18	17
	C		C												

Individual B

	C														
---	2	3	4	5	6	7	8	9	10	11	---	---	---	---	---
---	---	---	---	---	---	---	---	---	---	---	---	---	---	---	---

Dental Pathology:	Individual A – EH, periodontal disease Individual B – No
Pathology:	Individual A – Enthesophytes, healed metacarpal fracture, sacralization of L5 Individual B – No
Grave goods:	No
Comments:	No

GLD S3.2

Preservation: Excellent
Bones present: Complete, missing hand and foot bones
Sex: Male
Age: 30 – 40 years
Stature: 162.7 ± 2.8cm
Ancestry: SA Negroid
Dentition:

1	2	3	4	5	6	7	8	9	10	11	12	13	14	15	16
32	31	30	29	28	27	X	25	24	23	22	21	20	19	18	17
				A							A				

Dental Pathology: EH, periodontal disease, dental calculus
Pathology: Fractures, enthesophytes, spina bifida atlantis
Grave goods: No
Comments: No

GLD S3.3

Preservation: Excellent
Bones present: Complete, some phalanges and carpal bones missing
Sex: Male
Age: 25 – 30 years
Stature: 165.6 ± 2.8cm
Ancestry: SA Negroid
Dentition:

1	2	3	4	5	6	7	8	9	10	11	12	13	14	15	16
32	31	30	29	28	27	26	25	24	23	22	21	20	19	18	17

Dental Pathology: No
Pathology: Enthesophytes, OA of AC-joints
Grave goods: Black woven textile, copper bangle
Comments: No

GLD S3.4

Preservation: Excellent
Bones present: Complete, missing some phalanges and carpal bones
Sex: Male
Age: 38 – 50 years
Stature: 166.8 ± 2.8cm
Ancestry: SA Negroid and KhoeSan
Dentition:

C				C											
1	2	3	4	5	6	7	8	9	10	11	12	13	14	15	16
32	31	X	29	28	27	26	25	24	/	22	21	20	X	18	17
			C								C	C		C	

Dental Pathology: Periodontal disease
Pathology: Enthesophytes
Grave goods: Iron bracelet, copper beads, fabric
Comments: Received autopsy

GLD S3.5

Preservation: Excellent
Bones present: Complete, few phalanges carpal bones. Two extra tarsal bones
Sex: Male
Age: 25 – 30 years
Stature: 162.7 ± 2.8cm
Ancestry: SA Negroid
Dentition:

			A C												
1	2	3	R	5	6	7	8	9	10	11	12	13	14	15	16
32	31	30	29	28	27	26	25	24	23	22	21	20	R	18	17
	C	C A												C	

Dental Pathology: Periodontal disease
Pathology: Enthesophytes, fracture, Schmörl's nodes
Grave goods: Coffin wood and nails, copper bracelet
Comments: Buried in coffin, received autopsy

GLD S3.6

Preservation: Excellent
Bones present: Complete, some hand bones missing
Sex: Male
Age: 16 – 20 years
Stature: 163.4 ± 2.8cm
Ancestry: SA Negroid
Dentition:

1	2	3	4	5	6	7	8	9	10	11	12	13	14	15	16
32	31	30	29	28	27	26	25	24	23	22	21	20	19	18	17
												C			

Dental Pathology: No
Pathology: Schmörl's nodes
Grave goods: String of beads
Comments: No

GLD S4.1

Preservation: Poor
Bones present: Complete, 2 carpals and some phalanges missing
Sex: Female
Age: 28 – 32 years
Stature: 146.5 ± 2.8cm
Ancestry: SA Negroid and KhoeSan
Dentition:

	C	C		A		C	C	C	C				C	C	
Z	2	3	4	5	6	R	R	9	R	11	12	13	R	R	Z
32	31	30	29	28	27	26	25	24	23	22	21	20	R	18	17
	C	C		C					C		C		C	C	

Dental Pathology: Periodontal disease
Pathology: Enthesophytes
Grave goods: Coffin remains, iron disc
Comments: Buried in coffin

GLD S5.1

Preservation: Good
Bones present: Complete, missing phalanges
Sex: Male
Age: 28 – 34 years
Stature: 163.4 ± 2.8cm
Ancestry: SA Negroid
Dentition:

	C	AC													
1	2	R	4	5	6	7	8	9	10	11	12	13	14	15	16
32	31	30	29	28	27	26	25	24	23	22	21	20	19	18	17

Dental Pathology: Periodontal disease, dental calculus
Pathology: Fractures, enthesophytes,
Grave goods: Pieces of iron
Comments: Buried in coffin

GLD SE7.2

Preservation: Good
Bones present: Only postcranial remains, missing right arm, 1TV, 5CV, some hand and foot bones
Sex: Female
Age: 44 – 60 years
Stature: 148.7 ± 2.8cm
Ancestry: Possible SA Negroid
Dentition:

---	---	---	---	---	---	---	---	---	---	---	---	---	---	---	---
---	---	---	---	---	---	---	---	---	---	---	---	---	---	---	---

Dental Pathology: No
Pathology: OA of hip joint and AC-joint, DDD
Grave goods: Ring
Comments: No

GLD SE7.3

Preservation: Good
Bones present: Complete
Sex: Male
Age: 28 – 32 years
Stature: 162.3 ± 2.8cm
Ancestry: SA Negroid and KhoeSan
Dentition:

1	2	3	4	5	6	7	8	9	10	11	12	13	14	15	16
32	31	30	29	28	27	26	25	24	23	22	21	20	19	18	17

Dental Pathology: No
Pathology: Ossified haematoma
Grave goods: No
Comments: Histological investigation performed

GLD SE7.4

Preservation: Good
Bones present: Complete. Left pisiform and some phalanges missing
Sex: Male
Age: 30 – 40 years
Stature: 159.5 ± 2.8cm
Ancestry: KhoeSan
Dentition:

				A											
1	2	3	4	X	6	7	8	9	/	11	12	13	14	15	16
32	31	30	29	28	27	26	25	24	/	22	21	20	19	18	17

Dental Pathology: No
Pathology: Schmörl's nodes, subperiosteal bone growth, enthesophytes
Grave goods: Pair of boots, Hessian type cloth with buttons
Comments: Histological investigation performed

GLD SE7.5

Preservation: Excellent
Bones present: Complete, some missing ribs, carpals and phalanges
Sex: Female
Age: 30 – 43 years
Stature: 154.7 ± 2.8cm
Ancestry: SA Negroid and KhoeSan
Dentition:

1	2	3	4	5	6	7	8	9	10	11	12	13	14	15	16
32	31	30	29	28	27	26	25	24	23	22	21	20	19	18	17

Dental Pathology: Periodontal disease, dental calculus
Pathology: Healed fracture, enthesophytes, ossified haematoma, myositis ossificans, Schmörl's nodes
Grave goods: Hessian bag
Comments: No

GLD SE7.6

Preservation: Good
Bones present: Complete, few phalanges missing
Sex: Male
Age: 25 – 30 years
Stature: 165.6 ± 2.8cm
Ancestry: SA Negroid
Dentition:

													C		
1	2	3	4	5	6	7	8	9	10	X	12	13	14	15	16
R	31	30	29	28	27	26	25	24	23	22	21	20	X	18	17
A															C

Dental Pathology: Dental calculus, periodontal disease, extra deciduous tooth found with skull
Pathology: Healed fractures, enthesophytes, ossified haematoma, myositis ossificans, treponematosis
Grave goods: No
Comments: No

GLD SE7.7

Preservation: Excellent
Bones present: Complete, few missing phalanges
Sex: Male
Age: 20 – 25 years
Stature: 172.5 ± 2.8cm
Ancestry: SA Negroid
Dentition:

1	2	3	4	5	6	7	8	9	10	11	12	13	14	15	16
32	31	30	29	28	27	26	25	24	23	22	21	20	19	18	17
	C														

Dental Pathology: Supernumerary teeth, periodontal disease, dental crowding
Pathology: Subperiosteal bone growth, treponematosis, possible scurvy
Grave goods: Hessian sacking, copper earring
Comments: Histological investigation performed

GLD SE7.8

Preservation: Excellent
Bones present: Complete, few phalanges missing
Sex: Male
Age: 35 – 45 years
Stature: 160.1 ± 2.8cm
Ancestry: SA Negroid
Dentition:

1	2	3	4	5	6	7	8	/	10	11	12	13	14	15	16
												C	C		
32	31	30	29	28	27	26	25	24	23	22	21	20	19	18	17

Dental Pathology: Dental wear, periodontal disease, supernumerary teeth
Pathology: Cribra orbitalia, enthesophytes, DDD, possible treponematosis
Grave goods: No
Comments: No

GLD SE7.9

Preservation: Excellent
Bones present: Complete
Sex: Male
Age: 35 – 45 years
Stature: 168.7 ± 2.8cm
Ancestry: SA Negroid and KhoeSan
Dentition:

						C							C	C	
1	2	3	4	5	6	7	8	9	X	11	12	13	14	15	16
Z	R	X	29	28	27	26	25	24	23	22	21	20	19	18	X
	C												C	C	A

Dental Pathology: Periodontal disease, dental calculus
Pathology: Supernumerary vertebra, ossified haematoma, myositis ossificans, enthesophytes, Schmörl's nodes, healed fractures, ankylosis between proximal 4th and 5th metacarpals
Grave goods: Copper ring, coin
Comments: Histological investigation performed

GLD SE7.10

Preservation: Poor
Bones present: Incomplete and fragmented
Sex: Unknown
Age: 2 – 3 months
Stature: 62.98 ± 1.8cm
Ancestry: Unknown
Dentition:

---	---	---	---	---	---	---	---	---	---	---	---	---	---	---	---
---	---	---	---	---	---	---	---	---	---	---	---	---	---	---	---

Dental Pathology: No
Pathology: No
Grave goods: No
Comments: No

GLD SE7.11

Preservation: Good
Bones present: Complete. Few phalanges missing
Sex: Female
Age: 30 – 40 years
Stature: 148.5 ± 2.8cm
Ancestry: KhoeSan
Dentition:

Z	2	3	4	5	6	7	8	9	10	11	12	13	14	15	Z
Z	31	30	29	28	27	26	25	24	23	22	21	20	19	18	Z

Dental Pathology: Periodontal disease, dental calculus
Pathology: Enthesophytes, Schmörl's nodes,
Grave goods: Safety pin
Comments: No

GLD SE11.1

Preservation: Good
Bones present: Two individuals were represented. Individual A – Complete, Missing left femur, sacrum, os coxae and a few phalanges. Individual B – 2 complete arms and hands
Sex: Individual A – Male
Individual B – Male
Age: Individual A – >50years
Individual B – Adult
Stature: Individuals A and B – Unknown
Ancestry: Individuals A and B – Unknown
Dentition:

Individual A

1	2	3	4	5	6	7	/	/	/	11	12	13	14	15	X
32	31	30	29	28	27	26	25	24	23	22	21	20	19	18	X
C															

Dental Pathology: Individual A – Dental wear, periodontal disease, dental calculus
Pathology: Individuals A and B – No
Grave goods: No
Comments: No

GLD SE11.2

Preservation: Good
Bones present: Presented by femora, tibiae, fibulae and feet, few phalanges missing
Sex: Male
Age: Adult
Stature: 168.4 ± 2.8cm
Ancestry: Unknown
Dentition:

---	---	---	---	---	---	---	---	---	---	---	---	---	---	---	---
---	---	---	---	---	---	---	---	---	---	---	---	---	---	---	---

Dental Pathology: No
Pathology: Enthesophytes, non-specific osteomyelitis
Grave goods: No
Comments: No

GLD SE11.3

Preservation: Excellent
Bones present: Missing skull, mandible, upper extremities and phalanges
Sex: Female
Age: 45 – 60 years
Stature: 164.2 ± 2.8cm
Ancestry: Unknown
Dentition:

---	---	---	---	---	---	---	---	---	---	---	---	---	---	---	---
---	---	---	---	---	---	---	---	---	---	---	---	---	---	---	---

Dental Pathology: No
Pathology: OA hip joint, DDD, enthesophytes
Grave goods: Metal bangle
Comments: No

GLD SE11.4

Preservation: Excellent
Bones present: Complete, missing a few phalanges, carpals and left 5th metatarsal. Extra patella
Sex: Female
Age: 19 – 25 years
Stature: 154.3 ± 2.8cm
Ancestry: SA Negroid and KhoeSan
Dentition:

1	2	3	4	5	6	7	8	9	10	11	12	13	14	15	16
32	31	30	29	28	27	26	25	24	23	22	21	20	19	18	17

Dental Pathology: No
Pathology: Enthesophytes
Grave goods: Buttons with red fabric
Comments: No

GLD SE11.5

Preservation: Excellent
Bones present: Complete, hand and foot bones missing. Extra 5th metatarsal
Sex: Male
Age: 20 – 25 years
Stature: 164.6 ± 2.8cm
Ancestry: SA Negroid
Dentition:

1	2	3	4	5	6	7	/	9	10	11	12	13	14	15	16
32	31	30	29	28	27	26	25	24	23	22	21	20	19	18	17
C	C														C

Dental Pathology: Impacted supernumerary teeth
Pathology: No
Grave goods: Beads, earring and ring
Comments: No

GLD SE11.6

Preservation: Excellent
Bones present: Complete, few carpal bone and phalanges missing, ribs fragmented
Sex: Female
Age: 30 – 37 years
Stature: 152.6 ± 2.8cm
Ancestry: SA Negroid
Dentition:

1	2	3	4	5	6	7	8	9	10	11	12	13	14	15	16
32	31	30	29	28	27	26	25	24	23	22	21	20	19	18	17

Dental Pathology: Periodontal disease, dental calculus
Pathology: Healed fracture, enthesophytes
Grave goods: No
Comments: No

GLD SE12.1

Preservation: Good
Bones present: Mandible, fragmented skull, humerii, 7 fragmented vertebrae and ribs
Sex: Male
Age: >40years
Stature: Unknown
Ancestry: Unknown

														C	
/	2	/	4	5	6	7	8	9	10	11	12	13	14	15	16
32	31	30	29	28	27	/	/	/	23	22	21	20	19	18	17
	C	C										C			
		A													

Dental Pathology: Supernumerary teeth, dental calculus
Pathology: Schmörl's nodes
Grave goods: No
Comments: No

GLD SE15.1

Preservation: Good
Bones present: Complete, missing tibiae, fibulae and feet
Sex: Female
Age: 15 – 18 years
Stature: Unknown
Ancestry: SA Negroid
Dentition:

1	2	3	4	5	6	7	8	9	10	11	12	13	14	15	16
32	31	30	29	28	27	26	25	24	23	22	21	20	19	18	17
	C														

Dental Pathology: No
Pathology: Cribra orbitalia
Grave goods: Three pieces of iron, string of green and white beads, string of blue and white beads, copper ring, leather band with buckle, viscous material
Comments: No

GLD SE15.2

Preservation: Good
Bones present: Left radius and ulna, femora, fragmented os coxae, scapulae, vertebrae, ribs and hand bones
Sex: Male
Age: 45 – 55 years
Stature: Unknown
Ancestry: Unknown
Dentition:

---	---	---	---	---	---	---	---	---	---	---	---	---	---	---	---
---	---	---	---	---	---	---	---	---	---	---	---	---	---	---	---

Dental Pathology: No
Pathology: DDD
Grave goods: No
Comments: No

GLD SE16

Preservation: Good
Bones present: Skull and mandible
Sex: Male
Age: Adult
Stature: Unknown
Ancestry: SA Negroid
Dentition:

/	2	3	4	5	6	7	8	9	10	11	12	13	14	15	16
32	31	30	29	28	27	26	25	24	23	/	21	20	19	18	17
				C										C	

Dental Pathology: Periodontal disease, dental calculus
Pathology: No
Grave goods: No
Comments: No

GLD SE16.1

Preservation: Good
Bones present: Missing skull, mandible, tibiae, fibulae, hands and feet
Sex: Male
Age: 45 – 60 years
Stature: Unknown
Ancestry: Unknown
Dentition:

---	---	---	---	---	---	---	---	---	---	---	---	---	---	---	---
---	---	---	---	---	---	---	---	---	---	---	---	---	---	---	---

Dental Pathology: No
Pathology: No
Grave goods: No
Comments: No

References

De Villiers, H. 1968. The skull of the South African Negro: A biometrical and morphological study. Johannesburg: Witwatersrand University Press.

Gordon, C.C. and Buikstra, J.E. 1981. Soil pH, bone presenvation and sampling bias at mortuary sites. *American Antiquity* 46: 566 – 571.

İşcan, M.Y., Loth, S.R., and Steyn, M. 2000. Determination of racial affinity. In: Siegal J, Saukko P, and Knupfer G, editors. *Encyclopedia of Forensic Sciences*. London: Academic. pp. 227-235.

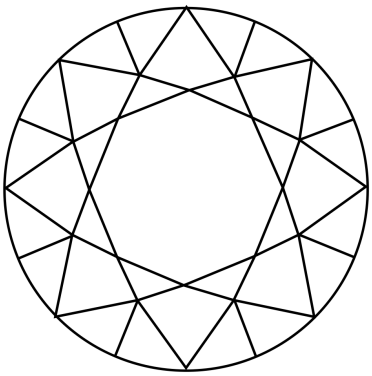

APPENDIX 2

List of Grave Goods

Gowie Brothers & Co, 1890s
(McGregor Museum Kimberley photography nr.954_001)

Bultfontein mine compound, 1900s
(McGregor Museum Kimberley photography nr.5356)

Table A2.1 List of grave goods excavated in association with each individual

Individual nr.	Associated grave goods
GLD N8.1	Wooden coffin
GLD N8.1(b)	Hospital dressing
GLD N8.2	Iron beads
GLD N8.4	Leather band and iron disc
GLD N8.5	Two strands of iron beads
GLD N8.6	Iron beads
GLD N8.8	Iron bracelet, copper bangle, glass beads
GLD N8.9	Iron fragments
GLD N8.10	Copper earring, iron bracelet
GLD N34.2	Iron bangle, white beads, green beads
GLD N31.E.3	Iron bangle
GLD N31.E.5	Copper string, cloth
GLD N34.3	Ring, iron and copper bangles
GLD N34.7	Beads
GLD N34.8	Copper beads, blue and white beads around neck
GLD N34.14	Eight strands of copper and iron beads
GLD N38.1	Coffin, metal fragments, iron bead
GLD N38.3	Copper bangle, iron bands, buttons, piece of leather with metal attached to it, ditoala
GLD N74.1	Copper pins forming a cross
GLD N74.2	Metal buttons, leather, shoe, iron bangle, pearl buttons
GLD N74.3	Copper fragments
GLD N74.5	Metal objects, iron bangles, cloth
GLD N74.7	Iron and copper bangle
GLD N74.9	Copper ring
GLD N 74.11	Copper bangle
GLD N74.12	Copper leg band, belt buckle, three strings of copper beads
GLD N100.5	Copper bangle
GLD NOP3/4.2	Button
GLD S1.4	Metal plate
GLD S1.5	Copper bangle
GLD S2.4	Copper ring, woven material
GLD S2.5	Metal pieces
GLD S2.7	Hospital dressing
GLD S3.3	Copper bangles, black woven textile
GLD S3.4	Copper beads, iron bracelets and fabric
GLD S3.5	Coffin, copper bracelet

Table A2.1 List of grave goods excavated in association with each individual (Cont.)

Individual nr.	Associated grave goods
GLD S3.6	String of beads
GLD S4.1	Coffin, iron disc
GLD S5.1	Coffin, iron pieces
GLD SE7.2	Ring
GLD SE7.4	Fabric, buttons, boots
GLD SE7.5	Hessian bag
GLD SE7.7	Sacking, copper earring
GLD SE7.9	Copper ring, coin
GLD SE7.11	Safety pin
GLD SE11.3	Metal bangle
GLD SE11.4	Button and textile, possibly military
GLD SE11.5	Beads, earring, ring
GLD SE15.1	Two strings of beads, copper ring, leather band with buckle, textile, three pieces of iron

APPENDIX 3

Commingled Remains Catalogue

Kimberley Sanatorium, 1899
(McGregor Museum Kimberley photography nr.4924)

Kimberley Hospital, 1882
(McGregor Museum Kimberley photography nr.7872)

Key to abbreviations and terminology used

Column headings

Nr	Element number
MNI	Minimum number of individuals represented by the remains
Path.	Pathology
Ass.	Possible association with another element
n	Minimum number of individuals represented by the element

Pathological lesions

Pd	Periodontal disease
AMTL	Antemortem tooth loss
Fr	Fracture
Enth.	Enthesophytes
Subp.b.g.	Subperiostel bone growth
Ex.	Exostosis
Ns.p.	Non-specific periostitis

Elements

M1	First molar
M2	Second molar
M3	Third molar
PM2	Second premolar
C	Canine

Age

J	Juvenile (≤19 years)
YA	Young adult (20 – 34 years)
MA	Middle aged adult (35 -49 years)
A	Adult (≥20 years)
U	Unknown age

Sex

M	Male
F	Female
U	Unknown sex

Other

R	Right
L	Left
T	Total

Table A3.1 Summary of commingled elements recovered from the dump.

Element	Males						Females						Unknown						Total					
Age	J	YA	MA	A	U	T	J	YA	MA	A	U	T	J	YA	MA	A	U	T	J	YA	MA	A	U	T
Occipital bones		2	1	6		9										1	3	4		2	1	7	3	13
Parietal bones		2	1	6		9										1	4	5		2	1	7	4	14
Temporal bones		1	1	9	3	14										1	3	4		1	1	10	6	18
Frontal bones		2	1	6		9										1	3	4		2	1	7	3	13
Maxillae		2	1	8		11										1	1	2		2	1	9	1	13
Mandibulae			2	10		12										4	2	6			2	14	2	18
Vertebrae														1		17		18		1		17		18
Sterna																	11	11					11	11
Sacra		1		2	2	5		1		1		2					3	3		2		3	5	10
Claviculae														4		6	10	20		4		6	10	20
Scapulae																4	11	15				4	11	15
Humeri	1			14	1	16				4		4				1	5	6	1			19	6	26
Radii				1		1							2			20	2	24	2			21	2	25
Ulnae													3			20	1	24	3			20	1	24
Os coxae	2	2		8		12	1			2		3	1			4		5	4	2		14		20
Femora	2			15		17				5		5							2			20		22
Tibiae	2			11		13				4		4				1		1	2			16		18
Fibulae				1		1							1			12	5	18	1			13	5	19
MNI	2	2	2	15	3	17	1	1		5		5	3	4		20	11	24	4	4	2	21	11	26

Table A3.2 List of occipital bones recovered from the dump.

Nr.	Description	Age	Sex	Path.	Ass.	n
D10	Occipital bone fragment	U	U	No	D9	1
4.65	Occipital bone	YA	M	No	4.64	1
4.69	Frontal bone associated with parietal & occipital bones	U	U	No		1
4.70	Occipital bone associated with parietal & R. temporal	A	M	No		1
H79	Occipital bone	A	M	No		1
H91	Occipital bone associated with parietal & L. temporal	A	M	No		1
I98	Occipital bone as part of complete calvarium	U	U	No		1
I100	Occipital bone				I98	
D11	Occipital bone as part of complete calvarium	A	U	No		1
1'2'3'.56	Occipital bone as part of complete cranium	A	M	No		1
1'2'3'.58	Occipital bone as part of complete cranium	A	M	No		1
4.72	Occipital bone as part of complete cranium	YA	M	No		1
H74	Occipital bone as part of complete cranium	MA	M	Fr		1
H95	Occipital bone as part of complete cranium	A	M	No		1
				MNI represented		**13**

Table A3.3 List of parietal bones recovered from the dump.

Nr.	Description	Age	Sex	Path.	Ass.	n
D9	R. parietal & fragment of L. parietal bones	U	U	No		1
4.64	L. parietal bone	YA	M			1
4.66	R. parietal bone				4.64	
4.69	R. & L. parietal bones	U	U	No		1
4.70	R. & L. parietal bones	A	M	No		1
H80	R. parietal bone	A	M	No	H79	1
H81	L. parietal bone				H80	
H91	L. parietal bone	A	M	No		1
I98	R. & L. parietal bones as part of calvarium	U	U	No		1
I99	Part of L. parietal bone				I98	
D11	R. & L. parietal bones as part of calvarium	A	U	No		1
1'2'3'.56	R. & L. parietal bones as part of complete cranium	A	M	No		1
1'2'3'.58	R. & L. parietal bones as part of complete cranium	A	M	No		1
4.72	R. & L. parietal bones as part of complete cranium	YA	M	No		1
H74	R. & L. parietal bones as part of complete cranium	MA	M	Fr		1
H95	L. parietal bone as part of complete L. cranium	A	M	No		1
				MNI represented		**14**

Table A3.4 List of temporal bones recovered from the dump.

Nr.	Description	Age	Sex	Path.	Ass.	n
D12	R. temporal bone	A	U	No		1
D14	R. temporal bone	U	M	No		1
D15	L. temporal bone	U	M	No		1
4.62	L. temporal bone	A	M	No	4.61	1
4.70	R. temporal	A	M	No		1
H80	R. temporal	A	M	No	H79	1
H81	L. temporal				H80	
H87	Part of L. temporal bone	A	M	No	H88	1
H90	R. temporal bone	U	U	No		1
H91	L. temporal	A	M	No		1
H93	L. temporal bone	U	U	No		1
H94	R. temporal bone	U	U	No		1
H96	R. temporal bone	A	M	No	H95	1
C105	L. temporal bone	U	M	No		1
1'2'3'.56	R. & L. temporal bones as part of complete cranium	A	M	No		1
1'2'3'.58	R. & L. temporal bones as part of complete cranium	A	M	No		1
4.72	R. & L. temporal bones as part of complete cranium	YA	M	No		1
H74	R. & L. temporal bones as part of complete cranium	MA	M	Fr		1
H95	L. temporal bone as part of complete L. cranium	A	M	No		1
					MNI represented	**18**

Table A3.5 List of frontal bones recovered from the dump.

Nr.	Description	Age	Sex	Path.	Ass.	N
D13	Fragment of L. frontal bone	U	U	No		1
4.64	Frontal bone	YA	M	No		1
4.71	Frontal bone	A	M	No	4.70	1
H80	Fragment of frontal bone	A	M	No	H79	1
H81	Fragment of frontal bone				H80	
H86	Frontal bone as part of complete face	A	M	No		1
I98	Frontal bone as part of calvarium	U	U	No		1
D11	Frontal bone as part of calvarium	A	U	No		1
4.69	Frontal bone	U	U	No		1
1’2’3’.56	Frontal bone as part of complete cranium	A	M	No		1
1’2’3’.58	Frontal bone as part of complete cranium	A	M	No		1
4.72	Frontal bone as part of complete cranium	YA	M	No		1
H74	Frontal bone as part of complete cranium	MA	M	FR		1
H95	L. part of frontal bone as part of complete L. cranium	A	M	No		1
					MNI represented	**13**

Table A3.6 List of maxillae recovered from the dump.

Nr.	Description	Age	Sex	Path.	Ass.	N
D1	Maxilla	A	U	No		1
D4	R. maxilla (M1 – C)	A	M	No		1
4.61	L. half of maxilla	A	M	No		1
4.67	R. half of maxilla	YA	M	No	4.64	1
4.68	L. half of maxilla				4.67	
4.73	Maxilla with teeth				4.72	
H75	Maxilla, teeth & 7 associated pieces	A	M	Pd		1
H88	Maxilla	A	M	Pd		1
I101	L. maxilla	U	U	No		1
I102	R. maxilla				I101	
H86	Maxilla as part of complete viscerocranium	A	M	No		1
1’2’3’.56	Maxilla as part of complete cranium	A	M	No		1
1’2’3’.58	Maxilla as part of complete cranium	A	M	AMTL		1
4.72	Maxilla as part of complete cranium	YA	M	No		1
H74	Maxilla as part of complete cranium	MA	M	Fr		1
H95	L. half of maxilla as part of partial L. cranium	A	M	No		1
					MNI represented	**13**

Table A3.7 List of mandibulae recovered from the dump.

Nr.	Description	Age	Sex	Path.	Ass.	n
D2	R. mandibular ramus & condyle	A	M	No	D4	1
D3	Mandible with teeth from R. M1 - L. M1				D2	
D5	R. mandibular ramus without condyle	A	U	No		1
D6	R. gonion with M3 & M2				D5	
D7	Coronoid process	U	U	No		1
D8	Lower M1 & PM2 with piece of mandible	U	U	No		1
1'2'3'.57	Complete mandible	A	M	Pd		1
1'2'3.59	Mandible	A	M	AMTL	1'2'3'.58	1
4.60	Complete mandible	A	M	No		1
4.63	R. half of mandible	A	U	No		1
H74	Mandible accompanied by matching skull	MA	M	Fr		1
H76	Mandible	A	M	Pd	H75	1
H77	Chin with 4 central teeth	A	M	No	H79	1
H78	Part of mandible with 2 molars	A	U	No		1
H89	Mandible with both ramii missing	A	M	Pd	H88	1
H92	R. half of mandible	A	M	No	H91	1
H97	R. half of mandible	A	M	No	H95	1
C103	Mandible	A	M	No		1
C104	L. half of mandible	A	U	No		1
H74	Mandible accompanied by matching skull	MA	M	Fr		1
					MNI represented	**18**

Table A3.8 List of vertebrae recovered from the dump.

Nr	Description	Age	Sex	Path.	Ass.	N
C	Axis	A	U	No		1
D	Axis	A	U	No		1
4	Atlas	A	U	No		1
H	Atlas	A	U	No		1
H	Atlas, Axis & 2 cervical vertebrae	A	U	No		1
C	Atlas, Axis, 4 cervical,10 thoracic & 5 lumbar vertebrae	A	U	No		1
4	1 Cervical & 1 thoracic vertebra	A	U	No		1
D,E	2 Cervical, 8 thoracic & 2 lumbar vertebrae	YA	U	No		1
H	Atlas & axis	A	U	No		1
H	Atlas, Axis & 2 cervical vertebrae	A	U	No		1
H	Atlas & axis	A	U	No		1
H	1 Lumbar & 4 thoracic vertebrae	A	U	No		1
C	8 Thoracic & 5 lumbar vertebrae	A	U	No		1
H	2 Thoracic & 5 lumbar vertebrae	A	U	No		1
D	4 Lumbar vertebrae	A	U	No		1
D	14 Thoracic vertebrae	A	U	No		2
D	3 Lumbar vertebrae	A	U	No		1
	84 Unmatched fragments					
					MNI represented	**18**

Table A3.9 List of sterna recovered from the dump.

Nr.	Description	Age	Sex	Path.	Ass.	n
H1	Manubrium	U	U	No		1
C2	Manubrium	U	U	No		1
C3	Manubrium	U	U	No		1
C4	Manubrium & corpus fragment	U	U	No		1
H5	Manubrium	U	U	No		1
D6	Manubrium	U	U	No		1
D7	Corpus				D6	
C8	Corpus	U	U	No		1
C9	Corpus	U	U	No		1
H10	Corpus fragment	U	U	No		1
H11	Corpus fragment	U	U	No		1
D12	Corpus fragment	U	U	No		1
				MNI represented		**11**

Table A3.10 List of sacra recovered from the dump.

Nr.	Description	Age	Sex	Path.	Ass.	N
C1	Complete sacrum	U	M	No		1
D2	R. ½ of sacrum	U	M	No		1
C3	Complete sacrum	YA	M	No		1
D4	Complete sacrum	A	M	No		1
D5	Complete sacrum	A	F	No		1
D6	Sacrum	YA	F	No		1
D7	Sacrum	A	M	No		1
C8	Sacral fragments	U	U	No		1
D9	Sacral fragments	U	U	No		1
I10	L. auricular surface & S1	U	U	No		1
				MNI represented		**10**

Table A3.11 List of claviculae recovered from the dump.

Nr	Description	Side	Age	Sex	Path.	Ass.	n
H1	Mid portion of clavicle	R	U	U	No		1
D2	Medial ⅓ of clavicle	R	A	U	No		1
I3	Complete clavicle	R	YA	U	No		1
H4	Lateral ⅔ of clavicle	R	U	U	No		1
±D5	Mid portion of clavicle	R	U	U	No		1
H6	Complete clavicle	R	A	U	No		1
±D7	Lateral part of clavicular shaft	R	U	U	No		1
C8	Lateral part of clavicular shaft	R	U	U	No		1
I9	Medial ⅔ of clavicle	R	A	U	No		1
C10	Complete clavicle	R	A	U	No		1
C11	Complete clavicle	L				C10	
C12	Lateral ½ of clavicle	L	U	U	No		1
C13	Lateral ½ of clavicle	L	U	U	No		1
C14	Complete clavicle	L	YA	U	No		1
C15	Complete clavicle	L	YA	U	No		1
4.16	Complete clavicle	L	A	U	No		1
D17	Complete clavicle	L	YA	U	No		1
D18	Complete clavicle	L	A	U	No		1
D19	Lateral ⅔ of clavicle	L	U	U	No		1
D20	Lateral ½ of clavicle	L	U	U	No		1
D21	2cm of mid shaft	U	U	U	No		1
							MNI represented 20

Table A3.12 List of scapulae recovered from the dump.

Nr	Description	Side	Age	Sex	Path.	Ass.	N
1'2'3.1	Superior & lateral portion of scapula	L	U	U	No		1
C2	Inferior ½ of glenoid fossa, spinous process	L	A	U	No		1
C3	Fragment of medial border	L				C2	
C4	Inferior angle, fragments of medial & lateral border	L				C2	
D5	Inferior angle, fragments of medial & lateral border	L	A	U	No		1
H6	Complete Scapula	L	A	U	No		1
H7	Glenoid fossa & acromion	R	U	U	No		1
D8	Coracoid, glenoid fossa, medial border, inferior angle	R	U	U	No		1
±D9	Almost complete scapula, medial border damaged	R	A	U	No		1
C10	Spinous process, glenoid fossa, coracoid, acromion	R	U	U	No		1
H11	Spinous process, glenoid fossa , acromion, lateral border	R	U	U	No		1
D12	Glenoid fossa , coracoid, superior & lateral border	R	U	U	No		1
D13	Spinous process & acromion	R				D12	
D14	Tip of acromion	R	U	U	No		1
H15	Coracoid process	U	U	U	No		1
H16	Acromion	R	U	U	No		1
H17	Glenoid fossa & fragment of coracoid process	R				H16	
H18	Corpus fragment	R				H16	
H19	Corpus fragment	R				H16	
H20	Spinous process, glenoid fossa, coracoid, acromion	L	U	U	No		1
D21	Acromion	L	U	U	No		1
D22	Acromion	R				D21	
							MNI represented 15

Table A3.13 List of humeri recovered from the dump.

Nr.	Description	Side	Age	Sex	Path.	Ass.	n
D1	Humeral shaft	L	U	U	No		1
I2	Distal humeral shaft	L	U	U	No		1
D3	Distal humeral shaft	L	U	U	No		1
D4	Epichondyles	L	A	M	No		1
D5	Distal ⅓ of humerus	L	A	M	No		1
D6	Complete humerus	L	A	U	No		1
C7	Proximal ⅓ of humerus	L	A	M	No		1
D8	Humeral head & 1cm of shaft	L	A	M	No		1
D9	Proximal ⅔ of humerus	L	A	M	No		1
D10	Proximal ⅓ of humerus	L	A	M	No		1
D11	Humerus with proximal end missing	R	A	M	No		1
D12	Complete humerus	R	A	M	No		1
D13	Complete humerus	R	U	U	No		1
I14	Complete humerus, head missing	R	A	M	No		1
D15	Proximal ½ of humeral shaft	R	U	U	No		1
D16	Complete humerus, head missing	R	A	M	No		1
D17	Complete humerus, head missing	R	J	M	No		1
D18	Distal ⅓ of humerus	R	A	M	No		1
D19	Distal ⅔ of humerus	R	A	M	No		1
D20	Distal ½ of humerus	R	A	M	No		1
D21	Humeral head	R				D17	
H22	Humeral head fragments	U	U	M	No		1
D23	Humeral head	L	A	F	No		1
D24	Humeral head	R				D15	
C25	Humeral head & 3cm of anterior shaft	L	A	F	No		1
C26	2 matching humeri	L&R	A	F	No		1
H27	2 matching humeri	L&R	A	F	No		1
C28	Humeral shaft	R	A	M	No		1
D29	Complete humerus	L				C28	
D30	Distal ½ of humerus	L				D10	
						MNI represented	**26**

Table A3.14 List of radii recovered from the dump.

Nr	Description	Side	Age	Sex	Path.	Ass.	N
±D1	Proximal ⅔ of radius	L	A	U	No		1
D2	Distal ⅓ of radius	L				±D.1	
C3	Complete radius	L	A	U	No		1
±D4	Complete radius	L	J	U	No		1
C5	Complete radius	L	A	U	No		1
H6	Complete radius	L	A	U	No		1
C7	Complete radius	L	A	U	No		1
D8	Distal ⅔ of radius	L	A	U	No		1
D9	Proximal ⅔ of radius	L	A	U	No		1
C10	Complete radius	L	A	M	No		1
C11	Distal ⅔ or radius	L	A	U	No		1
±D12	Proximal ¼ of radius	L	A	U	No		1
C13	Distal ½ of radius	L	A	U	No		1
C14	Proximal ¼ of radius	L	A	U	No		1
C16	Distal ¼ of radius	L	A	U	No		1
±D17	Complete radius	R	A	U	No		1
H18	Complete radius	R				H.6	
D19	Complete radius	R	A	U	No		1
H20	Proximal ½ of radius	R	A	U	No		1
C21	Radius with distal end missing	R	A	U	No		1
C22	Proximal ⅓ of radius	R	A	U	No		1
C23	Distal end of radius	R	A	U	No		1
±D24	Radius with distal end missing	R	J	U	No		1
D25	Distal end of radius	L				±D.24	
C26	Proximal radial fragment	U	U	U	No		1
C27	Proximal ¼ of radius	R	A	U	No		1
C28	Radial head	U	U	U	No		1
D29	Proximal ¼ of radius	R	A	U	No		1
						MNI represented	**25**

Table A3.15 List of ulnae recovered from the dump.

Nr	Description	Side	Age	Sex	Path.	Ass.	n
C1	Proximal ⅔ of ulna	L	A	U	Enth.		1
±D2	Complete ulna	L	A	U	Enth.		1
±D3	Complete ulna	L	A	U	No		1
C4	Proximal ⅔ of ulna	L	A	U	No		1
D5	Complete ulna	L	A	U	Enth.		1
D6	Distal ⅓ of ulna	L	A	U	Fr.		1
D7	Proximal ⅔ of ulna	L				D6	
D8	Distal ½ of ulna	L	A	U	No		1
D9	Proximal ½ of ulna	L				D8	
D10	Proximal ¼ of ulna	R	A	U	No		1
D11	Proximal ½ of ulna	R	A	U	Enth.		1
D12	Proximal ½ of ulna	R	A	U	No		1
D13	Distal ½ of ulna	R				D12	
C14	Proximal ⅔ of ulna	R	A	U	No		1
C15	Distal ⅓ of ulna	R				C14	
D16	Complete ulna	R	A	U	No		1
±D17	Ulna with distal ¼ missing	R	A	U	Enth.		1
C18	Ulna with distal ¼ missing	R	A	U	No		1
H19	Proximal ⅔ of ulna	L	A	U	No		1
D20	Complete ulna	R	A	U	No		1
C21	Olecranon process	U	U	U	No		1
C22	Distal ½ of ulna	R	A	U	No		1
C23	Distal ⅔ of ulna	L	A	U	No		1
D24	Distal ½ of ulna	L	A	U	No		1
C25	Distal ¼ of ulna	R	A	U	No		1
D26	Complete ulna with distal end missing	R	J	U	No		1
D27	Ulna with no proximal or distal ends	L	J	U	No		1
C28	Distal ⅓ of ulna	L	J	U	No		1
H29	Complete Ulna	R				C28	
						MNI represented	**24**

Table A3.16 List of os coxae recovered from the dump.

Nr	Description	Side	Age	Sex	Path.	Ass.	n
C1	Os Ilium fragment	L	J	F	No		1
C2	Complete os coxa	L	A	F	No		1
C3	Complete os coxa	L	J	M	No		1
H4	Os Ilium	L	J	M	No		1
±D5	Os pubic fragment	L				H4	
±D6	Complete os coax	L	A	M	No		1
D7	Complete os coax	L	A	M	No		1
D8	Os Ilium & part of acetabulum	L	YA	M	No		1
D9	Os Pubic	L				D8	
C10	Os Ilium fragment	R	A	U	No		1
±D11	Complete os coax	R	A	F	Enth.		1
D12	Os coxa missing pubic bone	R	A	M	No		1
4.13	Complete os coxa	R	A	M	No		1
D14	Os Ilium fragment	R	A	M	No		1
D15	Os Ilium fragment	L	A	M	No		1
D16	Os Pubic fragment	L				D15	
D17	Ischial tuberosity	L	A	U	No		1
H18	Ischial tuberosity	L	A	U	No		1
H19	Os Ilium fragment	L				H18	
H20	Os Pubic fragment	L				H18	
H21	Ischial tuberosity	R	A	U	No		1
D22	Ischial tuberosity	R	J	U	No		1
1'2'3.23	Os Pubis	L	YA	M	No		1
C24	Os Pubis	L	A	M	No		1
C25	Os coax, missing os pubis	R	A	M	No		1
C26	Complete os coax	L				C25	
	Fragments					H18	
						MNI represented	**20**

Table A3.17 List of femora recovered from the dump.

Nr	Description	Side	Age	Sex	Path.	Ass.	N
4.1	Femur with distal & proximal ends missing	L	J	M	No		1
C2	Complete femur	L	A	M	No		1
H3	Femoral head, neck & trochanters	L	A	M	No		1
4.4	Femur with proximal end missing	L	A	M	No		1
D5	Complete femur	L	A	M	No		1
H6	Complete femur	L	A	M	No		1
D7	Complete femur	L	A	M	No		1
H8	Distal end of femur	L	A	M	No		1
D9	Femur with distal end missing	L	A	M	No		1
±D10	Complete femur	L	A	M	No		1
4.11	Complete femur	R				4.1	
H12	Unfused distal femoral epiphysis	R	J	M	No		1
C13	Complete femur	R				C2	
H14	Femoral head, neck & trochanters	R				H3	
C15	Distal ½ of femur	R	A	M	No		1
±D16	Complete femur	R	A	M	Ex		1
H17	Proximal ½ of femur	R	A	M	No		1
D18	Complete femur	R				D7	
1’2’3.19	Complete femur	R				D9	
D20	Femur with proximal end missing	R	A	F	No		1
4.21	Two complete femura	L&R	A	F	No		1
D22	Piece of femoral head	U	A	F	No		1
H23	Two femura, R missing distal half	L&R	A	M	No		1
±D24	Two complete femura	L&R	A	F	No		1
C25	Two complete femura, only proximal halves	L&R	A	F	No		1
C26	Two complete femura	L&R	A	M	No		1
D27	Complete femur	R	A	M	No		1
						MNI represented	**22**

Table A3.18 List of tibiae recovered from the dump.

Nr	Description	Side	Age	Sex	Path.	Ass.	n
±D1	Distal ⅓ of tibia	L	A	M	No		1
D2	Lateral proximal ½ of tibia	L				±D1	
D3	Medial proximal ½ of tibia	L				±D1	
C4	Proximal ½ of tibia	L	A	F	No		1
C5	Distal ½ of tibia	L				C4	
C6	Proximal ⅓ of tibia	L	A	M	No		1
D7	Proximal end of tibia	L	A	M	No		1
±D8	Complete tibia	L	J	M	No		1
D9	Complete tibia	L	A	F	Subp.b.g.		1
±D10	Complete tibia	L	A	M	No		1
±D11	Complete tibia with distal end missing	L	A	M	No		1
D12	Distal ½ of tibia	L	A	F	No		1
D13	Distal ⅓ of tibia	L	A	M	No		1
D14	Complete tibia	L	A	F	No		1
D15	Distal ⅔ of tibia	R	A	M	Ex		1
D16	Proximal ¼ of tibia	R				D15	
D17	Complete	R				±D11	
D18	Complete tibia	R				D14	
4.19	Complete tibia	R	A	M	Subp.b.g.		1
D20	Complete tibia	R				±D10	
±D21	Complete tibia	R				±D8	
D22	Complete tibia	R	A	M	Ns.p		1
C23	Distal 3/4 of tibia	R				C5	
C24	Unfused distal epiphysis	R	J	M	No		1
C25	Complete tibia	R	A	M	No		1
C26	Proximal ⅓ of tibia	L				C25	
C27	Distal ½ of tibia	L				C26	
D28	Tibial shaft fragment	U	A	U	No		1
D30	Complete tibia	R	A	M	No		1
						MNI represented	**18**

Table A3.19 List of fibulae recovered from the dump.

Nr	Description	Side	Age	Sex	Path.	Ass.	n
C1	Fibula with proximal end missing	L	A	U	Ns.p.		1
D2	Complete fibula	L	A	U	No		1
D3	Complete fibula	L	A	U	No		1
D4	Fibula with proximal end missing	L	A	U	No		1
D5	Fibula with proximal end missing	L	A	U	No		1
±D6	Fibula with proximal epiphysis missing	L	J	U	No		1
C7	Distal ½ of fibula	L	A	U	No		1
D8	Fibula with distal end missing	L	A	U	No		1
D9	Fibula shaft fragment	U	U	U	No		1
D10	Distal end of fibula	L	A	M	No		1
D11	Proximal end of fibula	L	A	U	No		1
D12	Proximal end of fibula	R	A	U	No		1
D13	Distal end of fibula	R	U	U	No		1
D14	Proximal end of fibula	R	U	U	No		1
D15	Complete fibula	R	A	U	No		1
D16	Complete fibula	R	A	U	No		1
D17	Distal ¼ of fibula	R	A	U	No		1
D18	Fibular shaft	R	U	U	No		1
1'2'3.20	Fibular shaft	R	U	U	No		1
						MNI represented	**19**

APPENDIX 4

Discriptive Craniometry Data



Bultfontein Mine aerial gear, 1900s
(McGregor Museum Kimberley photography nr.5494)



Bultfontein mine, 1890
(McGregor Museum Kimberley photography nr.7621)

Table A4.1 Descriptive data for the male sample under study: Gladstone population including the eight comparative groups.

	Gladstone		Sotho/Tswana South Africa		Zulu South Africa		Khoe-San Southern Africa		Riet River South Africa		Basuku DRC		Bahutu Rwanda		Gizeh Egypt		Indonesia	
Variables[1]	M	S.D.	M	S.D.	M	S.D.	M	S.D.	M	S.D.	M	S.D.	M	S.D.	M	S.D.	M	S.D.
g-op	185.7	7.1	187.7	5.7	185.1	5.9	178.37	6.23	179.9	8.3	178.0	5.2	184.1	6.1	185.6	6.2	171.5	8.8
eu-eu	133.1	5.7	133.8	5.8	134.1	5.1	133.59	5.12	134.8	5.4	128.9	4.9	135.3	4.5	139.3	5.0	141.5	6.3
ba-b	135.6	6.5	133.7	5.4	133.7	6.0	122.54	4.71	127.6	6.4	130.9	5.0	125.6	6.3	133.8	5.2	135.0	6.0
b-n	103.5	4.4	101.1	4.4	102.0	5.0	94.76	4.84	97.5	6.7	96.8	3.1	99.4	4.0	101.5	3.7	98.4	4.3
b-pr	104.3	5.7	101.2	4.4	102.4	6.1	93.66	5.28	97.0	7.2	99.6	5.7	101.9	6.3	96.6	3.8	96.6	4.5
n-pr	67.6	6.2	67.7	4.7	67.3	4.1	57.51	5.32	63.7	6.2	63.3	5.2	69.1	5.2	68.5	2.9	69.3	3.9
n-ns	48.9	3.1	48.7	3.4	50.0	2.6	43.76	2.94	45.5	3.9	46.5	3.1	49.0	3.2	51.8	2.7	-	-
al-al	28.1	1.9	28.1	2.6	28.7	1.9	27.17	2.27	25.8	2.7	27.6	2.4	27.1	1.7	24.9	1.7	26.4	1.6
obb	40.4	4.4	39.8	2.3	40.4	1.9	39.27	1.86	38.5	2.1	39.0	1.7	40.4	1.8	39.5	1.8	-	-
obh	33.0	2.9	33.2	2.4	33.8	1.8	30.83	2.41	31.8	2.3	33.2	2.2	35.0	1.7	33.0	2.0	-	-
zy-zy	129.8	5.7	129.2	5.5	130.0	4.2	129.19	5.45	124.7	6.9	126.0	4.9	133.5	5.8	128.9	4.2	-	-

[1]g–op=cranial length or *glabella-opistocranion*, eu-eu=cranial breadth or *euryon-euryon*, ba-b=*basion-bregma* height, b-n=*basion-nasion* length, b-pr=*basion-prosthion* length, n-pr=*nasion-prosthion* distance, n-ns=*nasal height or naso-spinale*, al-al=nasal breadth or *alare-alare*, obb=orbital breadth, obh=orbital height, zy-zy=bizygomatic breadth or *zygion-zygion*. M=Mean, S.D=Standard Deviation.

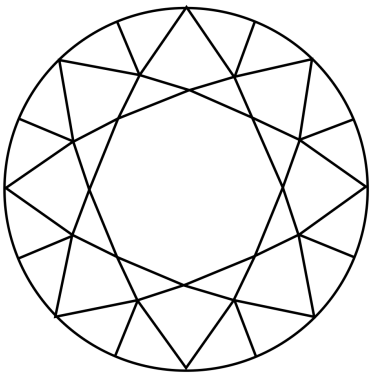

SUMMARY

Health and Demography in Late 19th Century Kimberley

A Palaeopathological Assessment

Kimberley Mine, 1893
(McGregor Museum Kimberley Photography nr.1680)

Dutoitspan Road, early 1900s
(McGregor Museum Kimberley Photography nr.1065)

The assessment of palaeopathological lesions present in skeletal population samples plays an important role in the study of human disease through time. Despite the various inherent difficulties to this field of research, described in **Chapter 1**, studying pathology in skeletal material and interpreting it in the light of the demographic composition of the sample population, archaeological findings and historical records still proves to be valuable. The purpose of this thesis was to assess and describe the palaeopathological lesions present in a sample of previously unknown skeletons accidentally uncovered from next to the fenced Gladstone cemetery in Kimberley, South Africa. Lesions were interpreted in association with the archaeological findings at the site, as well as the demographic composition and possible ancestry of the excavated remains.

Trenching by the Sol Plaatje municipality in Kimberley accidentally intersected 145 unmarked graves outside the fenced Gladstone cemetery in 2003. The McGregor Museum in Kimberley became responsible for the recovery and investigation of the disturbed material. Fifteen graves containing 107 skeletons were exhumed from the trench, and remains representing a minimum number of 26 individuals were rescued from another site where material dug out of the trench was dumped. All skeletal remains were analyzed using standard anthropometric techniques, and visually examined for signs of pathology as described in **Chapter 2**.

Archaeological and historical evidence suggested that the skeletal remains were most likely those of migrant mine workers who died between 1897 and 1900. As was reported in **Chapter 3**, the majority of the population consisted of young male individuals of low socio-economic status. Infectious diseases such as treponemal disease (8%), non-specific osteomyelitis (1%) and tuberculosis (1%), was observed. Several cranial and long bone fractures (26%) were also noted and 15% of the individuals in the sample presented with lesions most likely associated with healed scurvy. A high prevalence of Schmörl's nodes (31%) was observed and despite the young age of the individuals in this sample population, degenerative disc disease (15%%) and degenerative joint changes (22%) were frequent.

Special attention was given to the high prevalence of mechanical trauma in **Chapter 4**. The frequencies and types of trauma within a population can give important information regarding their lifestyle and the level of medical care available to them. The purpose of this chapter was to assess and interpret the prevalence of trauma in the Gladstone sample population with regards to interpersonal violence, a hazardous working environment, strenuous working requirements expected to be associated with mining, and the availability

of medical care. It was concluded that the high prevalence of cranial fractures within this population is suggestive of high levels of interpersonal violence, while long bone fractures, spondylolysis and evidence of longstanding subluxations are testament to the strenuous work requirements and the high-risk environment these individuals were exposed to. The presence of well-reduced fractures and healed amputations suggested that adequate medical care was available to at least some individuals.

Since skeletal evidence of adult scurvy is rarely seen, two chapters were devoted to it: firstly, skeletal lesions suggested to be evidence of adult scurvy were presented in **Chapter 5** and the histological structure of these lesions and the remodeling thereof was dealt with in **Chapter 6**.

An extremely high prevalence of scurvy was well documented as being present among the mining labourers by the end of the 19th century (approximately 17% of hospital admissions). A decision was therefore made to investigate the skeletal remains for any skeletal lesions that may be suggestive of adult scurvy. Lesions indicative of possible healed adult scurvy were observed in 16 individuals. These lesions included bilateral ossified haematomas, widespread subperiosteal bone remodelings and periodontal disease. Hospital records and historical documents describing the prevalence of scurvy in the local hospitals as well as the daily diet of the black mine workers supported these findings.

The histological structure of palaeopathological lesions has been described as being diagnostic by some authors. A decision was therefore made to assess whether histological features, as described in the literature, could confirm the macroscopic diagnoses of ossified subperiosteal haematomas, associated with healed scurvy, and syphilitic bone changes observed on the tibiae of some individuals from this skeletal sample.

As was described in **Chapter 6**, a section of bone was removed from lesions on the anterior surface of the tibiae of 14 individuals. These bone changes were macroscopically diagnosed as being indicative of either treponematosis, ossified subperiosteal haematomas, or non-specific periostitis. Ossified haematomas could be histologically identified in seven individuals and three phases of ossified subperiosteal haematoma formation and remodeling were described. Infectious bone changes, most likely associated with treponematosis, were observed in one individual. Histological features described as characteristic of this condition in literature could not be identified in the affected section. It was concluded that although specific pathological conditions can most likely not be diagnosed purely on the basis of histomorphological observations, broad distinctions could be made between lesions

caused by the ossification of subperiosteal haematomas and bone changes due to infectious diseases.

In order to make the study on the health of the 19th century miners from Kimberley complete, their dental health was also assessed. As was explained in **Chapter 7**, it can be expected that the dental health of a population may deteriorate when they have easier access to refined carbohydrates and sugars as a result of economic growth in a previously rural society. Historical documents, on the other hand, suggested that, even though these labourers from rural societies were working in an urban setting, restrictions imposed by the compounds prevented them from getting access to the refined foods and sugars which would cause deterioration in dental health. Investigation indicated that the prevalence of dental caries, periapical granulomata and periodontal disease as well as the pattern of antemortem tooth loss observed in the Gladstone sample concurred with dietary descriptions for paupers in historical documents. The relatively low prevalence of carious lesions was ascribed to the limited time migrant labourers spent in Kimberley and the diet restrictions they had to comply with during their stay in the compounds.

Although the presence of supernumerary teeth is not regarded as being pathological and the presence of these teeth does not add any information to the general health status of the sample under study, the teeth described in **Chapter 8** did add interesting detail to the demography of the study population. The high prevalence of this anomaly and the similarities in morphology and location among them suggested that, although several factors may influence the development of supernumerary teeth, there was a possibility of a genetic relationship between some of the individuals affected by hyperdontia in this sample population.

The last paper presented in **Chapter 9** of this thesis deals with the demography of the skeletal population, and specifically with their possible ancestry. An attempt was made to determine the possible ancestry of the unknown individuals excavated from next to the fenced Gladstone cemetery in Kimberley using cranio-morphometry. Results obtained supported the historical documents stating that the majority of labour at the Kimberley mine was done by migrant workers and that the local communities (Khoe-San) did not contribute much to the labour force. Of great importance was that this study reiterated the value of craniometric analyses as a tool to determine the possible ancestry of unknown individuals when used in association with contextual historical information.

All of the abovementioned results were taken into consideration to paint a general picture of the demographic composition and the health of the Gladstone skeletal sample in **Chapter 10**. It was concluded that this skeletal sample was representative of what one would expect of a migrant working population. The unhealthy living conditions, unsanitary hospital settings, as well as the absence of antibiotics at the time, combine to explain why tertiary stages of treponemal disease, osteomyelitis and tuberculosis could be observed in this skeletal population. As was suggested by the presence of scurvy and the dental health of this sample population, they followed a diet lacking fresh fruit and vegetables with very limited access to refined carbohydrates and sugars despite the urban setting they were labouring in. Furthermore, high levels of interpersonal violence were suggested by the frequency of cranial fractures observed. Lastly, the frequency of long bone fractures spondylolysis and longstanding subluxations as well as the high prevalence of degenerative lesions observed was testimony of the hazardous environment these individuals were performing hard physical labour in.

This study gave substance to contemporary reports on the appalling conditions and hazards to which migrant workers were exposed when selling their labour to the mines in the late 19th century.

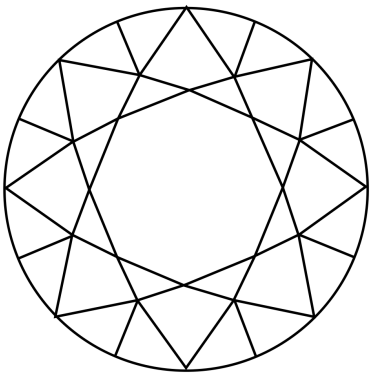

NEDERLANDSE SAMENVATTING

Gezondheid en Demografie in Kimberley aan het Einde van de 19e Eeuw

Een Paleopathologische Studie



Bultfontein mine compound, 1900s
(McGregor Museum Kimberley Photography nr.5356)

Kimberley Government buildings, 1880s
(McGregor Museum Kimberley Photography nr.4275)

Onderzoek van paleopathologische veranderingen in menselijke skeletresten speelt een belangrijke rol bij het bestuderen van menselijke ziekten door de eeuwen heen. Bij dergelijk onderzoek moet rekening worden gehouden met de demografische samenstelling van de onderzochte populatie en met de relevante archeologische en historische documentatie.

De doelstelling van dit proefschrift was het beschrijven en diagnosticeren van letsels bij skeletten, die bij toeval werden blootgelegd nabij de afgebakende begraafplaats Gladstone in Kimberley in Zuid Afrika. De ziektekundige veranderingen werden geïnterpreteerd in samenhang met de op die plek aangetroffen archeologische vondsten en gereconstrueerde populatiesamenstelling.

In **hoofdstuk 1** wordt beschreven welke moeilijkheden inherent zijn aan het paleopathologisch skeletonderzoek.

In **hoofdstuk 2** wordt beschreven hoe in 2003, bij het graven van een greppel in opdracht van de gemeente Sol Plaatje in Kimberley, per toeval een stuk grond met 145 ongemerkte graven werd doorsneden. Het McGregor museum in Kimberley nam de taak op zich om het verstoorde materiaal veilig te stellen en te laten onderzoeken. Vijftien gemeenschappelijke graven met daarin totaal 107 skeletten werden uit de greppel naar boven gehaald. Verder werden op een naburige locatie de overblijfselen van ten minste 26 personen verzameld uit het uit de greppel opgegraven stortmateriaal. Alle overblijfselen werden met behulp van standaard antropologische methoden geanalyseerd en op afwijkingen onderzocht.

Archeologisch en historisch bewijsmateriaal deed vermoeden dat de aangetroffen botresten afkomstig waren van migrant-mijnwerkers, die tussen 1897 en 1900 waren overleden. In **hoofdstuk 3** wordt uiteengezet, dat het merendeel van het botmateriaal afkomstig was van jonge mannen van lage socio-economische afkomst. Tekenen van infectieziekten kwamen, in vergelijking met andere Zuid Afrikaanse populaties, bij veel skeletten voor, zoals treponematosen (8%), aspecifieke osteomyelitis (1%) en tuberculose (1%). Daarnaast werden frequent geheelde fracturen in schedels en lange pijpbenen aangetroffen (26%). Vijftien procent van de individuen in de onderzochte groep vertoonde langs de pijpbeenschachten bot veranderingen, die hoogstwaarschijnlijk een uiting waren van genezen scheurbuik. Ondanks de jonge leeftijd van de overledenen werden bij een groot aantal van hen noduli van Schmörl (31%) en degeneratieve gewrichtsveranderingen (22%) aangetroffen.

In **hoofdstuk 4** wordt speciale aandacht besteed aan het veelvuldige voorkomen van tekenen van mechanisch trauma binnen de onderzochte groep. Traumafrequentie en het soort traumata in een populatie kunnen belangrijke informatie opleveren over de levenswijze van de onderzochte groep en over het niveau van de medische zorg dat beschikbaar was. De doelstelling van het in **hoofdstuk 4** beschreven onderzoek was om vast te stellen hoe frequent tekenen van mechanisch trauma voorkwamen en of er een samenhang zou kunnen zijn met het in historische bronnen beschreven onderlinge geweld, de gevaarlijke werkomgeving en de mate van beschikbaarheid van medische zorg. De conclusie was dat de frequent aangetroffen schedelfracturen waarschijnlijk (indicatief) gerelateerd zijn aan het veelvoorkomende onderlinge geweld, terwijl de vele pijpbeen fracturen en spondylolysen getuigen van de lichamelijk inspannende en risicovolle werkomstandigheden waaraan de onderzochte individuen werden blootgesteld.

Beschrijvingen van botveranderingen bij volwassenen ten gevolge van scheurbuik zijn zeldzaam. De volgende twee hoofdstukken handelen over de bij de onderzochte skeletten aangetroffen veranderingen die waarschijnlijk door scheurbuik zijn ontstaan: in **hoofdstuk 5** worden de macroscopische veranderingen beschreven en in **hoofdstuk 6** komt de histologie van deze laesies aan de orde.

In medische documenten wordt uitgebreid vermeld dat scheurbuik aan het eind van de 19^{e} eeuw onder de mijnwerkers in Kimberley zeer frequent voorkwam. Daarom werd besloten om het skeletmateriaal specifiek te onderzoeken op alle letsels die het gevolg zouden kunnen zijn van scheurbuik. Bij 16 individuen werden veranderingen aangetroffen die zouden kunnen passen bij genezen scheurbuik zoals bilaterale geossifiseerde hematomen en periodontitis. Deze bevindingen bevestigden de vermeldingen in de ziekenhuisregisters en beschikbare historische documenten en kunnen worden verklaard door de aard van het dieet van de zwarte mijnwerkers.

De histologische structuur van paleopathologische letsels wordt door sommige onderzoekers beschouwd als pathognomisch voor bepaalde aandoeningen. Daarom werd besloten om te onderzoeken in hoeverre de in de literatuur beschreven histopathologische kenmerken de macroscopisch gestelde diagnose konden bevestigen. In **hoofdstuk 6** wordt beschreven hoe daartoe een botschijfje uit de anteriore zijde van de tibia van 14 individuen werd genomen. Tevoren was bepaald of de macroscopische afwijkingen pasten bij die van een treponematose, een geossifiseerd subperiostaal hematoom of een aspecifieke beenvlies-ontsteking. Bij zeven individuen werden geossifiseerde hematomen histologisch

geïdentificeerd, in alle gevallen passend bij de macroscopie. Drie stadia van ossificatie en ombouw van subperiostale hematomen konden daarbij worden onderscheiden. In een ander individu met macroscopische afwijkingen passend bij een treponematose konden de in de literatuur beschreven histologische kenmerken daarvan in het aangedane deel niet worden vastgesteld. Daaruit werd geconcludeerd dat, hoewel specifieke ziekten niet altijd puur op basis van histomorfologische observatie kunnen worden gediagnosticeerd, er wel verschillen kunnen worden aangetoond tussen veranderingen veroorzaakt door ossificatie van subperiostale hematomen en veranderingen die door infectieziekten ontstaan.

In het kader van het onderzoek naar de gezondheid van de 19e- eeuwse mijnwerkers in Kimberley werd ook een tandheelkundig onderzoek gedaan. Men zou verwachten dat de tandheelkundige gezondheid van een bevolkingsgroep afneemt naarmate de betrokkenen, bijvoorbeeld als gevolg van veranderende economische omstandigheden, gemakkelijker toegang krijgen tot geraffineerde koolhydraten en suikers. In historische documenten wordt gesuggereerd dat de van het platteland afkomstige mijnwerkers weliswaar in een stedelijke omgeving kwamen te werken, maar dat de in de arbeiderskampementen opgelegde beperkingen hen de toegang tot geraffineerde koolhydraten en suikers beletten. Het onderzoek beschreven in **hoofdstuk 7** laat een relatief lage frequentie van cariës laesies, periapicale granulomata/abcessen en periodontitis en een patroon van tandverlies tijdens het leven zien overeenkomend met de dieetbeperkingen waaraan de arbeiders gedurende hun verblijf in het kampement werden onderworpen. Ook de beperkte tijd die de migrant-arbeiders in Kimberley doorbrachten speelt in dit verband mogelijk een rol.

De aanwezigheid van boventallige tanden wordt niet als pathologisch beschouwd en het voorkomen ervan draagt niet bij aan informatie over de algemene gezondheid van een onderzochte groep. In **hoofdstuk 8** wordt het frequent voorkomen van deze anomalie bij de onderzochte populatie beschreven. Bovendien werd een opmerkelijke overeenkomst in morfologie en positie van de boventallige tanden gevonden. Deze bevindingen suggereren dat er mogelijk een genetische relatie bestond tussen een aantal individuen binnen de groep. Het ontstaan van boventallige tanden zou echter ook door andere factoren beïnvloed kunnen zijn.

Het laatste artikel van dit proefschrift wordt in **hoofdstuk 9** gepresenteerd en betreft de herkomst van de mijnwerkers. Door middel van cranio-morfometrie werd getracht om de herkomst te reconstrueren van de onbekende mijnwerkers die naast de begraafplaats Gladstone werden opgegraven. De verkregen resultaten ondersteunen de beweringen in

historische documenten dat het merendeel van de arbeid in de mijn van Kimberley werd uitgevoerd door migrant-arbeiders en dat de lokale gemeenschap (KhoeSan) nauwelijks aan dit werk deelnam. Dit onderzoek laat zien dat craniometrie in samenhang met historische informatie informatief kan zijn.

Alle hierboven beschreven resultaten werden betrokken bij het in **hoofdstuk 10** geschetste beeld van de demografische samenstelling en de gezondheidstoestand van de Gladstone skeletten**.** Concluderend kan gezegd worden dat de in dit onderzoek aangetroffen afwijkingen aan skeletoverblijfselen passen bij wat men zou verwachten bij een migrant-arbeiderspopulatie. De ongezonde leefomstandigheden, de onhygiënische situatie in ziekenhuizen, als ook het ontbreken van antibiotica maken begrijpelijk waarom afwijkingen aan het skelet passend bij een treponematose of tuberculose en tekenen van aspecifieke osteomyelitis in dit onderzoek konden worden waargenomen. Zoals bij de aanwezigheid van bij scheurbuik passende afwijkingen en bij de algemene gebitstoestand aangeven, hadden de mijnwerkers met grote waarschijnlijkheid een gebrek aan vers fruit en groenten. Kennelijk hadden zij ook weinig toegang tot geraffineerde koolhydraten en suikers, ondanks de niet-rurale omgeving waarin zij hun werk uitvoerden. De hoge frequentie van schedelfracturen bevestigt het gedocumenteerde veel voorkomende onderlinge geweld. Ten slotte getuigen de vele geheelde fracturen van de pijpbeenderen en de spondylolysen samen met de veelvuldig voorkomende degeneratieve wervelkolombeschadigingen van een gevaarlijke werkomgeving waarin men fysiek zeer belastend werk moest uitvoeren.

Het onderzoek bevestigt de berichtgevingen over de slechte arbeidsomstandigheden en gezondheidsrisico's waaraan de migrant-arbeiders werden blootgesteld toen zij zich tegen het einde van de 19^{e} eeuw voor het werk in de mijnen beschikbaar stelden.

CURRICULUM VITAE

Carnarvon Hospital
(McGregor Museum Kimberley Photography nr.4832)

Kimberley Club and St Marys' RC, 1880s
(McGregor Museum Kimberley Photography nr.7792)

Alie Emily van der Merwe was born on June 27, 1982 in Vanderbijlpark, South Africa and graduated from school in 2000 (Hoërskool Transvalia, Vanderbijlpark, South Africa) with distinctions in Science, Accounting and Afrikaans. She started her bachelors study in Medical Sciences with specialization in Anatomy and Integrated Physiology at the University of Pretoria (UP), South Africa, and graduated in 2003 (*Cum laude*).

In 2004 she was invited by Prof. M.Y. İşcan to study the distribution of vertebral osteophytes across the spinal columns of a South African black skeletal population sample at the Forensic Institute of the University of Istanbul, Turkey. In collaboration with him and under the supervision of Prof. Dr. M Steyn she completed a B.Sc Honours degree with specialization in Physical Anthropology that same year (*Cum laude*).

The aforementioned research sparked her interest in the field of palaeopathology. Subsequently she enrolled for a M.Sc in Anatomy at UP and jumped at the opportunity to study the skeletal remains accidentally disturbed next to the fenced Gladstone cemetery in Kimberley, as a project. Under the supervision of Prof. Dr. M. Steyn and Prof. Dr. G.J.R. Maat she wrote an unpublished M.Sc. dissertation and was awarded a master degree in anatomy in 2007 (*Cum laude*).

She started as a Ph.D candidate supervised by Prof. Dr. G.J.R. Maat at the Leiden University Medical Centre (LUMC), the Netherlands, in October 2007. The unpublished data obtained during her masters project was reanalyzed and published and is presented to you in this thesis.

She is currently continuing research at the Leiden University Medical Centre studying the prevalence and skeletal manifestations of Diffuse Idiopathic Skeletal Hyperostosis in two 16th century skeletal sample populations as well as in modern skeletal material obtained from dissection hall at the LUMC. Furthermore she is collaborating as the Dutch partner in a SANPAD funded research project entitled: Skeletal identity of past populations: origins, sexual dimorphism and health, headed by Prof. Dr. M. Steyn at the University of Pretoria.

Publications (Full length peer reviewed articles)

Van der Merwe A.E., L'Abbé E.N., İşcan M.Y. (2006) The pattern of vertebral osteophyte development in a South African sample. *International Journal of Osteoarchaeology* 16:45-464.

Van der Merwe A.E., Steyn M. (2009) A report on the high incidence of supernumerary teeth in skeletal remains from a 19th century mining community from Kimberley, South Africa. *South African Dental Journal* 64(4):162 - 166.

Van der Merwe A.E., Steyn M., Maat G.J.R. (2009). Dental health of 19th century migrant mineworkers from Kimberley, South Africa. *International Journal of Osteoarchaeology* DOI: 10.1002/oa.1143.

Van der Merwe A.E., Steyn M., Maat G.J.R. (2010) Adult scurvy in skeletal remains from late 19th century mineworkers from Kimberley, South Africa. *International Journal of Osteoarchaeology* 20(3):307-316.

Van der Merwe A.E., Maat G.J.R., Steyn M. (2010) Histomorphological observations of pathological lesions on the anterior tibiae of individuals from a 19th century mining community in Kimberley, South Africa. *International Journal of Osteoarchaeology* 20(2):227-239

Van der Merwe A.E., Steyn M., L'Abbé E.N. (2010) Trauma and amputations in 19th century miners from Kimberley, South Africa. *International Journal of Osteoarchaeology* 20(3):291-306.

Van der Merwe A.E., Morris D., Steyn M., Maat G.J.R. (2010) The history and health of a nineteenth-century migrant mine-worker population from Kimberley, South Africa. *Archaeological Bulletin of South Africa* (Accepted).

Van der Merwe A.E., Ribot I., Steyn M., Maat G.J.R. (2010) The Origins of late 19th century migrant diamond miners uncovered in Kimberley, South Africa. *Archaeological Bulletin of South Africa* (Accepted).

Abstract publications and presentations

Van der Merwe A.E., L'Abbé E.N., İşcan M.Y. Occurrence of vertebral osteophytes in a black South African population. *2nd Annual Meeting of the Balkan Academy of Forensic Science.* Serres, Greece, June 2004. (Oral presentation)

Van der Merwe A.E., L'Abbé E.N., İşcan M.Y. The distribution of vertebral osteophytes in relation to the line of gravity. *Faculty Day, University of Pretoria.* August 2004. (Poster presentation)

Van der Merwe A.E., L'Abbé E.N., İşcan M.Y. Occurrence of vertebral osteophytosis in a South African sample. *35th Conference of the Anatomical Society of Southern Africa*. Buffalo city, South Africa, April 2005. (Oral presentation)

Van der Merwe A.E., Steyn M. Human skeletal remains from Kimberley: Preliminary results of an assessment of health in a 19th century mining community *Faculty Day, University of Pretoria*.. Pretoria, South Africa, August 2005. (Poster and oral presentation)

Van der Merwe A.E., Steyn M. Human skeletal remains from Kimberley: Preliminary results of an assessment of health in a 19th century mining community. *Three Universities Archaeology Seminar*, Pretoria, South Africa, March 2006. (Oral presentation)

Van der Merwe A.E., Steyn M. (2006) Human skeletal remains from Kimberley, South Africa: An assessment of health in a 19th century mining community. *Conference Proceedings of the 16th European Meeting of the Paleopathology Association,* pp.128. (Oral presentation)

Van der Merwe A.E., Steyn M. Human skeletal remains from Kimberley: Preliminary results of an assessment of health in a 19th century mining community. *36th Conference of the Anatomical Society of Southern Africa*. Golden Gate, South Africa, April 2006. (Oral presentation)

Van der Merwe A.E., Maat G.J.R., Steyn M. (2007) Histological investigations of ancient skeletal lesions as an aid for accurate diagnosis of disease. *Conference Proceedings of the 37th Annual Conference of the Anatomical Society of Southern Africa,* pp.38. (Oral presentation)

Van der Merwe A.E., Maat G.J.R. Histological investigations of ancient skeletal lesions as an aid for accurate diagnosis of disease. *Nederlandse Vereniging voor Fysische Antropologie, Autumn Symposium*. Leiden, The Netherlands, November 10, 2007. *Newsletter of the Dutch Association of Physical anthropologists* 16:2-3. (Lecture)

Van der Merwe A.E., Maat G.J.R. (2008) Diffuse Idiopathic Skeletal Hyperostosis: a review and new research questions. *Conference Proceedings of the 38th Annual Conference of the Anatomical Society of Southern Africa* pp.27. (Oral presentation)

Van der Merwe A.E., Maat G.J.R., Steyn M. (2008) Ossified haematomas and infectious bone changes on the anterior tibia: Histomorphological features as an aid for accurate diagnosis. *Supplement to the Palaeopathological Newsletter* pp.44. *17th European Meeting of the Paleopathology Association*. (Oral presentation)

Van der Merwe A.E., M.Steyn, G.J.R. Maat (2010). Dental health of 19th century migrant mineworkers from Kimberley, South Africa. *Newsletter of the Dutch Association of Physical Anthropologists* 18:4-5.

Prizes and Awards

Johan J. Theron prize for best student in Homeostasis at 300 level (2003).

Academic Honorary Colours from the University of Pretoria (2003).

Wirsam Scientific Prize for best achievement in anatomy for B.Sc. Medical Sciences at 300 level (2003).

Third place for best student researcher in the Faculty of Health Sciences at the University of Pretoria (2004).

Van Schaik Achievement Award for best academic achievement in anatomy on Honours level (2004).

Granted membership to the Golden Key International Honour Society in recognition of outstanding scholastic achievement and excellence (2004).

Received Bob Symington Award for the best young presenter at the 37th Annual Conference of the Anatomical Society of Southern Africa (2007).

ACKNOWLEDGEMENTS



Du toitspan Mine open cast operations, early 1900s
(McGregor Museum Kimberley Photography nr.1690)



Du toitspan mine compound
(McGregor Museum Kimberley Photography nr.786)

This project would never have been possible without the support and guidance of various people at the University of Pretoria, McGregor Museum and the Leiden University Medical Centre.

Firstly I would like to thank George Maat for giving me the wonderful opportunity to complete my Ph.D thesis under his supervision, it is truly an honor. Thank you for all the advice, ideas, moral support and patience in guiding me through this project. Thank you for your enthusiasm for the study of palaeopathology. Your wealth of knowledge in the field of palaeopathology and palaeohistopathology in particular is inspiring. Thank you for giving me the opportunity to grow in this field of research. Your ability to repair things, be it situations or even my handbag keeps astonishing me, thank you for making me feel at home in the Netherlands.

Special thanks should also be given to Maryna Steyn. Thank you for introducing me to the study of Basic Medical Sciences ten years ago, for your continuous support and guidance in the years that followed and for keeping me motivated throughout the writing and editing of the articles bound in this thesis. Thank you for creating various opportunities for me, believing in me and giving me the necessary pep-talks whenever I started doubting myself. Your passion for the field of anthropology is contagious. I hope that there will be many more collaborations between us in the time to come.

Without the persons that excavated, cleaned and curated the skeletal remains this study would not have been possible. I would therefore like to acknowledge the late Mrs. Elizabeth Voigt who co-directed the excavation, together with Karen van Ryneveld. Field assistants and help with cleaning of the skeletal remains came from the community including, principally, Koot Msawula, Kobus Saaiman, Bafana Ndebele, Petrus Wilson, Jane Joubert, Roger Bosch, Sandra Dodd, Bellin Hoffman, Abraham de Wee, Willem Eland, Stephen Seleku, Jacqueline Phetheni, Tanja Kruger, Vincent Dinku and Nomalinde Msuthu. Sephai Mngqolo recorded consultation proceedings.

I extend my sincere gratitude to David Morris and the McGregor Museum for giving me the opportunity to investigate the Gladstone skeletal remains. Special thanks to David for making arrangements and obtaining special permits from SARHA when it was decided to extend the project beyond macroscopic investigations. I would also like to thank you for always being available to give extra information about individual cases, archaeological findings associated with the remains or historical information. Your meticulous writing

style and thorough reviewing of articles as well as wealth of knowledge made it a pleasure to work with you.

Further I would like to give special thanks to Maureen Klemp. Thank you for your hospitality every time I came to Kimberley, as well as for volunteering to help with cleaning skeletal material and writing down measurements. You are an inspirational lady!

Marius Loots and Renee Botha, thanks for helping me with the photography of the remains. Special thanks to Marius Loots for also merging several photographs for the histological section of the thesis.

I would also like to express my appreciation to Sunet Swanepoel, Robert Hart and staff at the Africana Library in Kimberley for assistance in finding historical documents, reports and photographs referred to in this thesis, and Marinda Pretorius, from the Department of Anatomy, for the preparation of maps.

Job Aarents at the Leiden University Medical Centre gave technical support with the making of histological slides. Thank you for teaching me to produce these histological sections, and helping to optimize my samples for microscopic investigation.

I am greatly indebt to Darlene Weston for proofreading this thesis and to Wies Groeneboer and Marion Maat-Schieman for translating the English summary to Dutch. I would also like to acknowledge Drs. R. Wolterbeek for his statistical assistance, and Daniel Jansma and Anne Marie de Wit for their technical support in producing the dissertation.

Thanks to the following persons for providing various craniometrical comparative data sets: Alan Morris, William W. Howells, Alain Froment and Hertha De Villiers.

A special note of thanks should also be given to Ericka L'Abbé. Your patience while explaining statistics and continuous moral support was greatly appreciated.

I also thank members of the public who came forward with information and advised us in community meetings. I acknowledge the help of Sol Plaatje Municipality (the developer), SAHRA, De Beers Consolidated Mines Ltd, and the local press and radio in Kimberley.

Lastly I would like to thank my mom and sister, Retha and Jana van der Merwe and Johan Schutte. Your devotion, unconditional love and support, sense of humour, patience, optimism and advice was more valuable than you could ever imagine.