



Universiteit
Leiden
The Netherlands

Molecular markers in renal transplant biopsies

Groningen, M.C. van

Citation

Groningen, M. C. van. (2008, October 30). *Molecular markers in renal transplant biopsies*. Retrieved from <https://hdl.handle.net/1887/13209>

Version: Corrected Publisher's Version

License: [Licence agreement concerning inclusion of doctoral thesis in the Institutional Repository of the University of Leiden](#)

Downloaded from: <https://hdl.handle.net/1887/13209>

Note: To cite this publication please use the final published version (if applicable).



Chapter 7

Summary and General Discussion



Summary and General Discussion

Despite major improvements in immunosuppressive agents and a reduction in acute rejection episodes, there has been no significant improvement in overall kidney transplant survival beyond the first 3 months after transplantation¹. Up to sixty percent of all renal allografts are lost within 10 years after transplantation. Apart from death, the main cause of graft loss is chronic allograft nephropathy (CAN)^{2,3}. CAN is characterized by the deterioration of graft function and structure as a consequence of immunological processes (i.e., chronic rejection) and/or a variety of often co-existing non-immunological factors that include: advanced donor age, ischemic injury to the graft during implantation, chronic calcineurin inhibitor induced nephrotoxicity, hypertension, reflux, infection, increased ureteral pressure, and glomerular hyperfiltration. The initial histological characteristics of CAN are the presence of tubulointerstitial fibrosis and tubular atrophy (IF/TA)⁴. Over time, additional features evolve including vasculopathy, glomerulopathy, and glomerulosclerosis.

Unfortunately, functional studies significantly underestimate the incidence of graft injury. One of the largest studies with repeated protocol biopsies clearly showed that CAN is a process that develops early after transplantation. Up to 94% of protocol biopsies obtained one year after renal transplantation exhibited IF/TA in patients with stable graft function⁵. In addition, Solez *et al.* have shown that 2 years after transplantation two thirds of all kidney allografts exhibit CAN without deterioration of renal function⁶. The most significant predictors for the development of CAN were the occurrence of acute rejection episodes, acute calcineurin toxicity, and the initial quality of the transplanted kidney.

Often, the first clinical sign of CAN is the progressive decline in renal function as measured by increasing serum creatinine or the development of overt proteinuria². Although renal function correlates with glomerulosclerosis, unfortunately the clinical tests currently available for renal function are not sensitive enough to detect early lesions associated with CAN. Inulin and iothalamate clearances are more reliable and precise techniques for measuring renal function, but they are expensive, difficult to perform, and time consuming; thus they are unlikely to become routine in daily practice. This situation has given rise to intensified interest in studies using protocol biopsies that may identify surrogate markers and provide insight into the development of CAN. Ideally, a surrogate marker is minimally invasive and amenable to frequent assessment. However, the least invasive markers in blood or urine samples can only identify qualities and quantities of structural lesions in the renal allograft that typically occur in the advanced stages of disease. Currently, protocol biopsies are considered 'the gold standard' for discovering novel surrogate markers that better predict long-term outcomes for patients.

In this thesis, we focused on identifying molecular markers in kidney transplant biopsies that could predict long-term allograft survival. The identification of molecular markers provides a means for superior monitoring of the transplant condition in order to maintain drug efficacy and limit drug-related nephrotoxicity. Moreover, potential new therapeutic targets might be discovered for developing therapies that improve long-term graft survival.

In **chapter 2**, a methodological study was described that focused on the optimization of several steps in the protocol for the extraction and handling of RNA from renal cortical tissue. We found that the Trizol method was superior to the NP40 method with RNeasy spin columns and the Trizol method allowed storage for up to two months at -70°C without affecting RNA integrity. We then found that cDNA synthesis could be enhanced by using AMV reverse transcriptase; this provided a better yield of cDNA compared to Sensiscript® and Superscript RT. Degradation of mRNA is due to exposure to RNase enzymes during the processing and storage of RNA. Therefore, tissue should be snap-frozen immediately to maintain mRNA integrity. We found that during storage and processing at room temperature, incubation of renal tissue in RNA/ater proved beneficial to RNA integrity in whole cortical tissue. We were able to detect two-fold more mRNA in the glomeruli of microdissected cortical tissue treated with RNA/ater compared to the glomeruli of untreated tissue. However, light microscopy and immunofluorescence revealed that tissue integrity was diminished after RNA/ater treatment; thus it may not be practical to use this solution in routine diagnostic practice. This study highlights the need for an optimal mRNA preservation method that facilitates mRNA expression studies in routine diagnostic practice.

In **chapter 3**, we compared the fibrogenic effects of cyclosporine (CsA) and tacrolimus (Tac) at the mRNA and the protein levels in transplant protocol biopsies of cortical tissue. The biopsies were from rejection-free patients that were exposed to tailored regimens of these drugs. Since the introduction of calcineurin inhibitors in the early 1980's, there has been a reduction in the occurrence of acute renal transplant rejection episodes¹. However, calcineurin inhibitors are nephrotoxic and long-term use can lead to the development of CAN and result in loss of graft function^{7,8}. Previous studies have shown that CsA exerted a fibrogenic effect on the kidney⁹; however, there was no conclusive evidence that Tac had the same effect^{2,10}. It has also been shown that calcineurin inhibitors caused nephrotoxicity in the form of fibrosis brought about through the induction of TGF- β in the kidney¹¹⁻¹³. Thus, TGF- β can mediate the nephrotoxic effects of CsA, in accordance with its capacity to induce extracellular matrix (ECM) deposition¹⁴⁻¹⁶.

To investigate the fibrogenic effect that CsA and Tac exert in renal allografts, we employed Q-PCR to assess steady-state levels of TGF- β , collagen $\alpha 1$ (I), and collagen $\alpha 1$ (III) mRNA in protocol cortical biopsies. Furthermore, we used computer-aided digital image analysis to measure the extent of protein deposition of TGF- β , α -smooth muscle actin (α -SMA), and interstitial collagens in the renal cortex. We found that both CsA and tacrolimus induced an increase in the expression of fibrogenic molecules over time, and we found no difference between treatment groups. These findings suggest that these drugs have similar effects on the mRNA synthesis of TGF- β and collagens $\alpha 1$ (I) and $\alpha 1$ (III). A previous study showed that CsA targeted the promoter of collagen $\alpha 1$ (III)¹⁷ and thus affected the rate of mRNA transcription. The same may be true for collagen $\alpha 1$ (I). It is not clear whether Tac has the capacity to interact with response elements in the collagen genes.

Thus, in chapter 3 we showed that the extent of TGF- β and interstitial collagen

protein deposition did not significantly differ in patients receiving CsA or Tac. From these results, we conclude that in renal allografts the fibrogenic response is similar for both calcineurin inhibitors. Future investigations into the exact mechanisms underlying calcineurin inhibitor induction of ECM deposition will aid clinicians in adjusting therapeutic strategies to better maintain stable long-term graft function.

In **chapter 4** focused on the investigation of prognostic markers in renal transplant biopsies taken during an episode of acute rejection. The occurrence of acute rejection episodes is a major risk factor for the development of CAN¹⁸⁻²⁰. Through the use of microarray analyses, we identified several genes that were associated with the progression to CAN within 5 years after transplantation. Some markers showed a two-fold difference in expression between patient groups with different outcomes; these were validated by Q-PCR and immunohistochemical analysis. Furthermore, *in situ* hybridization was performed to localize the cells that expressed the prognostic markers identified. We found that differences in the mRNA levels of surfactant protein-C (SP-C), S100 calcium-binding proteins A8 (S100A8), and A9 (S100A9) allowed distinction between acute rejections that were associated with stable graft function and acute rejections that were associated with progression to CAN within 5 years post transplantation.

This study was the first to show the presence of SP-C in renal transplant biopsies. SP-C is a molecule that reduces surface tension at the air-liquid interface in the lung. It was shown to be expressed during embryogenesis of the ureteric bud^{21;22}. SP-C causes amyloid fibril formation in the lung, and thus might be associated with the development of pulmonary disease^{23;24}. We found that increased SP-C expression was associated with progression to CAN, suggesting that it may represent a process of tissue remodeling. In this study cohort we also showed that increased mRNA expression of S100A8 and S100A9 in acute rejection biopsies were associated with stable graft function at 5 years post transplantation. These molecules have been shown to play a role in wound repair, and may contribute to TGF- β and IL-10 mediated inhibitory effects on macrophages and lymphocytes²⁵⁻²⁷. It remains to be clarified whether the presence of these markers in renal transplant protocol biopsies may be of predictive and therapeutic value. Currently, studies in a S100A9 knock out mouse model are underway to investigate the roles of S100A8 and S100A9 in fibrogenesis.

In **chapter 5** we investigated whether EMT-related markers were associated with early renal transplant fibrosis in protocol biopsies. Tubulointerstitial fibrosis results from the disruption of homeostasis in the extracellular matrix (ECM)²⁸. Differentiated myofibroblasts are key players in the homeostasis of ECM during tissue repair, but they can also cause an overt accumulation of ECM that results in interstitial fibrosis²⁹. It was recently proposed that the epithelial cell transition into an ECM-producing mesenchymal phenotype (EMT) may be involved in the development of fibrosis³⁰⁻³². To investigate this pathway, we used the molecule S100A4, homologous to mouse fibroblast specific protein-1, to identify the mesenchymal phenotype. We first optimized a double stain (with Alexa[®] Dyes) that included a tubular epithelial marker and the mesenchymal marker,

S100A4. We investigated the colocalization of these markers in ten renal transplant biopsies. Some were obtained on clinical indication (showing acute rejection, ischemia, or acute tubular necrosis) and some obtained via protocol after transplantation (showing either fibrosis or no obvious morphological alterations). Only three out of the ten evaluated biopsies showed colocalization of S100A4 and the tubular epithelial marker, indicating EMT: one showed remains of acute tubular necrosis, one protocol biopsy without morphological abnormalities, and one protocol biopsy showed fibrosis. These findings were not sufficiently conclusive to indicate an association between EMT and a particular type of damage or lesion.

When the whole cohort of protocol biopsies at 6 and 12 months were assessed for the percent of area stained by TGF- β , BMP-7, S100A4, and α -SMA antibodies, we found that none of the markers predicted renal function over time. However, in 6-month and 12-month biopsies, increased TGF- β staining was associated with reduced scores for tubular atrophy. In addition, increased α -SMA staining at 6 months was associated with increased tubular atrophy scores. Bone morphogenetic protein-7 (BMP-7) is a natural antagonist of TGF- β . Accordingly, we found a positive relationship between the protein deposition of these markers at 6 and 12 months. Both S100A4 and α -SMA are markers for a mesenchymal phenotype; thus, it was not surprising to find that the protein expression of these markers correlated with each other at both time points. Due to the absence of an indisputable relationship between the expression of EMT-markers and renal function or histomorphology, we concluded that EMT does not play an evident dominant role in the development of early renal transplant fibrosis.

Following the protein expression study described in chapter 5, in **chapter 6** we investigated EMT at the mRNA level. We used protocol biopsies obtained at 6 months in the same patient cohort. Here, we compared the 6 month protocol biopsies from patients with improvement in renal function between 6 and 24 months to patients with deterioration in renal function. Interestingly, we found that improvements in renal function were associated not only with an increase in S100A4 mRNA expression, suggesting an increase in EMT, but also an increase in TGF- β , collagen α (I), and collagen α (III) mRNA expression, indicating an increase in ECM production.

These results go against the current dogma presented in the literature that EMT in the kidney contributes to the development of interstitial fibrosis leading to long-term graft failure. There are two main points that may explain the discrepancy between our findings and those from others. First, the biopsies in our study were obtained according to protocol from patients that received a tightly controlled immunosuppressive regimen. These might not be comparable to biopsies used in other studies as those biopsies were obtained based on clinical indications and at an advanced state of disease. Second, we obtained the biopsies at 6 months after transplantation. It is known that renal function improves and stabilizes within the first year after transplantation. The results presented in this study might therefore represent a process of connective tissue remodeling. This hypothesis is illustrated in Figure 1. In response to environmental changes in the kidney, for example ischemia, damaged tubular epithelial cells may either de-differentiate (EMT) into cells that express

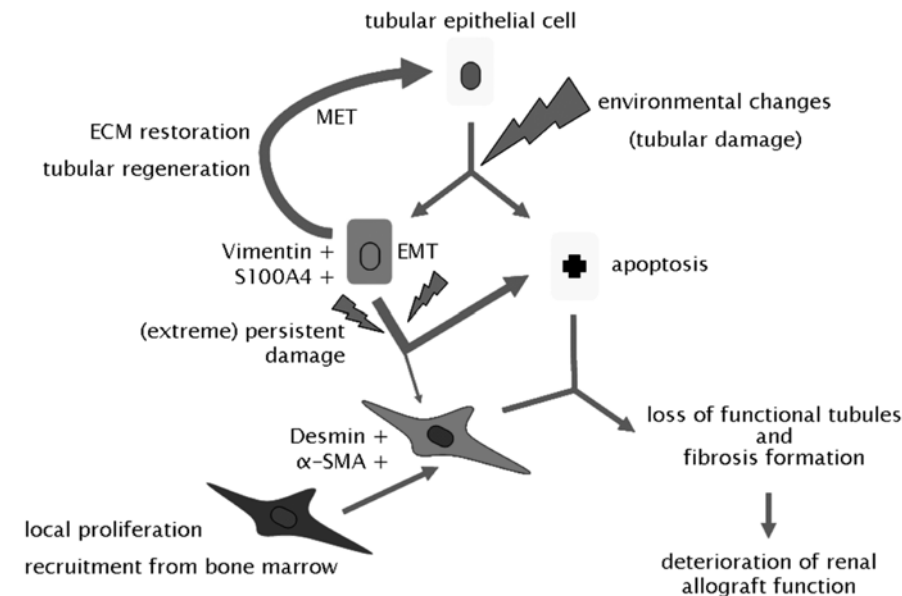


Figure 1. Speculative schematic illustration of a possible role for EMT in the renal allograft.

ECM: extracellular matrix, EMT: epithelial to mesenchymal transition, MET: mesenchymal to epithelial transition, S100A4: human homologue to fibroblast specific protein-1, α -SMA: α -smooth muscle actin.

myofibroblastic markers like vimentin and S100A4, or may enter into apoptosis. The cells that de-differentiate produce ECM proteins, including collagens, and aid in tubular regeneration; thus they help restore kidney tissue architecture and function. After restoration of the kidney, the tubule cells that transiently expressed myofibroblastic markers revert to functioning tubule cells by entering the mesenchymal to epithelial transition (MET). Under extreme conditions, when environmental damage persists, most of the tubular epithelial cells that expressed myofibroblastic markers eventually enter into apoptosis, thus contributing to tubular atrophy. The small fraction that does not enter into apoptosis may permanently change into a mesenchymal phenotype. These cells, together with mesenchymal cells acquired through local proliferation and recruitment from bone marrow, will produce extracellular matrix molecules and thus contribute to the development of interstitial fibrosis. The result of (extreme) persistent environmental damage is the development of IF/TA, the initial histological characteristic of CAN, and eventually the deterioration and loss of renal allograft function.

The results presented at the mRNA level in chapter 6 are not completely consistent with the results presented at the protein level in chapter 5. First and foremost, the relationships presented at the mRNA level were significant, but not strong, and results at the protein level were insignificant. We therefore challenge the notion that EMT plays a dominant role in the development of early interstitial fibrosis in human renal transplants.

Through the work in this thesis, we aimed to identify key factors that would help develop therapies that maintain long-term renal allograft function. We have found several prognostic markers that require further evaluation and testing in larger patient cohorts. Future research should focus on the crystallization of the role of (acute) rejection and its mediators in the development of interstitial fibrosis and subsequent renal function deterioration. In addition, future studies should aim to elucidate the role of calcineurin inhibitors in the development of fibrosis.

Future Perspectives

Chapter 3 was devoted to the investigation of the differences in the fibrogenic potential of the calcineurin inhibitors CsA and Tac. In this study we showed that there was no difference between the calcineurin inhibitors in the expression of fibrogenic markers either at the mRNA or the protein levels. Another way to interpret these results is that both calcineurin inhibitors have a fibrogenic effect that is associated with increased ECM production, leads to the development of interstitial fibrosis, and eventually leads to loss of renal function^{2;9;10}. Calcineurin is a signaling molecule made up of two subunits, the catalytic A subunit and the regulatory B unit. The calcineurin inhibitors, CsA and Tac, target the catalytic A subunit of calcineurin^{33;34}. This A subunit has three isoforms, α , β , and γ . The $A\gamma$ isoform is mainly found in testis and brain, and the $A\alpha$ and $A\beta$ isoforms are found in most tissues³⁵. Mouse models lacking either the $A\alpha$ or the $A\beta$ isoform have been developed^{33;36}. Mice lacking the $A\beta$ isoform exhibit a defective immune response that is similar to that exhibited by mice after administration of CsA. Indeed, Bueno *et al.* have shown that calcineurin $A\beta$ plays a critical role in the development and function of lymphocytes³³. Isoform $A\alpha$ -null mice have a short, infertile lifespan and exhibit failure to thrive. The $A\alpha$ -null mice also exhibit impaired kidney function and increased collagen deposition³⁷. Furthermore, inactivation of calcineurin $A\alpha$ has been shown to cause an increase in fibronectin expression in fibroblasts in culture. This increase was accompanied by an increase in active TGF- β ³⁸. Heterozygous mice that lacked only one allele of the $A\alpha$ isoform developed histological changes and ECM deposition similar to those associated with progressive nephrotoxicity in patients³⁸.

With the current understanding of calcineurin isoforms and their function, three distinct research paths can be pursued. First, the area under the concentration-over-time curves of calcineurin inhibitors should be linked to the levels of mRNA expression of individual calcineurin isoforms in cortical renal allograft tissue. Through analyzing mRNA steady-state levels of the calcineurin isoforms it might be possible to assess which concentration of calcineurin inhibitor is potent enough to prevent an acute rejection episode without causing the development of interstitial fibrosis. Second, a noninvasive method should be developed to assess the expression levels of individual calcineurin isoforms. For example, urine proteomics could be used to investigate urine calcineurin isoform concentrations, and thus allow clinicians to optimally dose therapy. Finally, more research should be directed towards the development of new immunosuppressive drugs that specifically target the calcineurin $A\beta$ isoform.



This may further increase long-term survival by diminishing the negative side effects observed with conventional calcineurin inhibitors that target both the α and β isoforms.

Identification of the underlying cause of the slow development of interstitial fibrosis and tubular atrophy in renal allografts remains a major objective of many research groups. One potential mechanism that might be involved in this process is the silent presence of cytotoxic T-lymphocytes that induce apoptosis and thus promote tubular atrophy and subsequent deterioration of graft function. It was previously shown that a higher percentage of cells contained cytotoxic granule protein GMP-17 (TIA-1) in allograft biopsies that exhibited acute cellular rejection compared to biopsies that represented other histological diagnoses³⁹. Eighty percent of the TIA-1 positive cells were cytotoxic T-cells; the remainder were T-helper cells, natural killer cells, and macrophages. Research directed towards quantifying the presence of cytotoxic T-cells in sequential renal transplant protocol biopsies might provide insight into the mechanisms underlying the development of CAN. A double-stain assay using TIA-1 with a background stain of Sirius red could be performed on paraffin sections to analyze the localization of TIA-1 positive cells in different cortical compartments⁴⁰. In addition, changes in the number of TIA-1 positive cells in atrophic tubules might be associated to the Banff score for chronic changes in follow-up biopsies. Furthermore, the presence of intra-epithelial TIA-1 positive cells in biopsies of patients with stable graft function might be a predictor of renal function over time.

The results presented in this thesis contribute to the search for prognostic markers for renal allograft outcome. In the future, through the combined efforts of the different subspecialties involved in treating renal transplant patients, more strategies can be designed for maintaining stable graft function and prolonging graft survival. Standardized methods in the histomorphological evaluation of the renal biopsy and in serum creatinine assessment should be combined with novel methods including urine genomics, proteomics, and/or metabolomics to identify therapeutic targets and subsequently guide and monitor therapeutic interventions. This interdisciplinary approach is likely to facilitate the ambitious goal of improving long-term renal allograft survival for our patients.

Reference List

1. Hariharan S, Johnson CP, Bresnahan BA, Taranto SE, McIntosh MJ, Stablein D: Improved graft survival after renal transplantation in the United States, 1988 to 1996. *N Engl J Med* 342:605–612, 2000
2. Paul LC: Chronic allograft nephropathy: An update. *Kidney Int* 56:783–793, 1999
3. Schweitzer EJ, Matas AJ, Gillingham KJ, Payne WD, Gores PF, Dunn DL, Sutherland DE, Najarian JS: Causes of renal allograft loss. Progress in the 1980s, challenges for the 1990s. *Ann Surg* 214:679–688, 1991
4. Racusen LC, Solez K, Colvin RB, Bonsib SM, Castro MC, Cavallo T, Croker BP, Demetris AJ, Drachenberg CB, Fogo AB, Furness P, Gaber LW, Gibson IW, Glotz D, Goldberg JC, Grande J, Halloran PF, Hansen HE, Hartley B, Hayry PJ, Hill CM, Hoffman EO, Hunsicker LG, Lindblad AS, Yamaguchi Y, et al.: The Banff 97 working classification of renal allograft pathology. *Kidney Int* 55:713–723, 1999
5. Nankivell BJ, Borrows RJ, Fung CL, O'Connell PJ, Allen RD, Chapman JR: The natural history of chronic allograft nephropathy. *N Engl J Med* 349:2326–2333, 2003
6. Solez K, Vincenti F, Filo RS: Histopathologic findings from 2-year protocol biopsies from a U.S. multicenter kidney transplant trial comparing tacrolimus versus cyclosporine: a report of the FK506 Kidney Transplant Study Group. *Transplantation* 66:1736–1740, 1998
7. Calne RY, White DJ, Thiru S, Evans DB, McMaster P, Dunn DC, Craddock GN, Pentlow BD, Rolles K: Cyclosporin A in patients receiving renal allografts from cadaver donors. *Lancet* 2:1323–1327, 1978
8. Halloran PF, Melk A, Barth C: Rethinking chronic allograft nephropathy: the concept of accelerated senescence. *J Am Soc Nephrol* 10:167–181, 1999
9. Myers BD, Ross J, Newton L, Luetscher J, Perlroth M: Cyclosporine-associated chronic nephropathy. *N Engl J Med* 311:699–705, 1984
10. Randhawa PS, Tsamandas AC, Magnone M, Jordan M, Shapiro R, Starzl TE, Demetris AJ: Microvascular changes in renal allografts associated with FK506 (Tacrolimus) therapy. *Am J Surg Pathol* 20:306–312, 1996
11. Islam M, Burke JF, Jr., McGowan TA, Zhu Y, Dunn SR, McCue P, Kanalas J, Sharma K: Effect of anti-transforming growth factor-beta antibodies in cyclosporine-induced renal dysfunction. *Kidney Int* 59:498–506, 2001
12. Shihab FS, Bennett WM, Tanner AM, Andoh TF: Mechanism of fibrosis in experimental tacrolimus nephrotoxicity. *Transplantation* 64:1829–1837, 1997
13. Ninova D, Covarrubias M, Rea DJ, Park WD, Grande JP, Stegall MD: Acute nephrotoxicity of tacrolimus and sirolimus in renal isografts: differential intragraft expression of transforming growth factor-beta1 and alpha-smooth muscle actin. *Transplantation* 78:338–344, 2004
14. Border WA, Noble NA, Yamamoto T, Harper JR, Yamaguchi Y, Pierschbacher MD, Ruoslahti E: Natural inhibitor of transforming growth factor-beta protects against scarring in experimental kidney disease. *Nature* 360:361–364, 1992
15. Jain S, Furness PN, Nicholson ML: The role of transforming growth factor beta in chronic renal allograft nephropathy. *Transplantation* 69:1759–1766, 2000
16. Ignatz RA, Massague J: Transforming growth factor-beta stimulates the expression of fibronectin and collagen and their incorporation into the extracellular matrix. *J Biol Chem* 261:4337–4345, 1986
17. Oleggini R, Musante L, Menoni S, Botti G, Duca MD, Prudenziati M, Carrea A, Ravazzolo R, Ghiggeri GM: Characterization of a DNA binding site that mediates the stimulatory effect of cyclosporin-A on type III collagen expression in renal cells. *Nephrol Dial Transplant* 15:778–785, 2000
18. Humar A, Payne WD, Sutherland DE, Matas AJ: Clinical determinants of multiple acute rejection episodes in kidney transplant recipients. *Transplantation* 69:2357–2360, 2000
19. Matas AJ, Gillingham KJ, Payne WD, Najarian JS: The impact of an acute rejection episode on long-term renal allograft survival (t1/2). *Transplantation* 57:857–859, 1994

20. Sijpkens YW, Doxiadis II, Mallat MJ, de Fijter JW, Bruijn JA, Claas FH, Paul LC: Early versus late acute rejection episodes in renal transplantation. *Transplantation* 75:204–208, 2003
21. Lin Y, Zhang S, Rehn M, Itaranta P, Tuukkanen J, Heljasvaara R, Peltoketo H, Pihlajaniemi T, Vainio S: Induced repatterning of type XVIII collagen expression in ureter bud from kidney to lung type: association with sonic hedgehog and ectopic surfactant protein C. *Development* 128:1573–1585, 2001
22. Vainio S, Lin Y, Pihlajaniemi T: Induced repatterning of type XVIII collagen associates with ectopic Sonic hedgehog and lung surfactant C gene expression and changes in epithelial epigenesis in the ureteric bud. *J Am Soc Nephrol* 14 Suppl 1:S3–S8, 2003
23. Johansson J: Molecular determinants for amyloid fibril formation: lessons from lung surfactant protein C. *Swiss Med Wkly* 133:275–282, 2003
24. Gustafsson M, Thyberg J, Naslund J, Eliasson E, Johansson J: Amyloid fibril formation by pulmonary surfactant protein C. *FEBS Lett* 464:138–142, 1999
25. Thorey IS, Roth J, Regenbogen J, Halle JP, Bittner M, Vogl T, Kaesler S, Bugnon P, Reitmaier B, Durka S, Graf A, Wockner M, Rieger N, Konstantinow A, Wolf E, Goppelt A, Werner S: The Ca²⁺-binding proteins S100A8 and S100A9 are encoded by novel injury-regulated genes. *J Biol Chem* 276:35818–35825, 2001
26. Aguiar-Passeti T, Postol E, Sorg C, Mariano M: Epithelioid cells from foreign-body granuloma selectively express the calcium-binding protein MRP-14, a novel down-regulatory molecule of macrophage activation. *J Leukoc Biol* 62:852–858, 1997
27. Yui S, Nakatani Y, Mikami M: Calprotectin (S100A8/S100A9), an inflammatory protein complex from neutrophils with a broad apoptosis-inducing activity. *Biol Pharm Bull* 26:753–760, 2003
28. Eddy AA: Molecular basis of renal fibrosis. *Pediatr Nephrol* 15:290–301, 2000
29. Desmouliere A, Chaponnier C, Gabbiani G: Tissue repair, contraction, and the myofibroblast. *Wound Repair Regen* 13:7–12, 2005
30. Kalluri R, Neilson EG: Epithelial-mesenchymal transition and its implications for fibrosis. *J Clin Invest* 112:1776–1784, 2003
31. Liu Y: Epithelial to mesenchymal transition in renal fibrogenesis: pathologic significance, molecular mechanism, and therapeutic intervention. *J Am Soc Nephrol* 15:1–12, 2004
32. Zeisberg M, Kalluri R: The role of epithelial-to-mesenchymal transition in renal fibrosis. *J Mol Med* 82:175–181, 2004
33. Bueno OF, Brandt EB, Rothenberg ME, Molkentin JD: Defective T cell development and function in calcineurin A beta-deficient mice. *Proc Natl Acad Sci U S A* 99:9398–9403, 2002
34. Liu J, Farmer JD, Jr., Lane WS, Friedman J, Weissman I, Schreiber SL: Calcineurin is a common target of cyclophilin-cyclosporin A and FKBP-FK506 complexes. *Cell* 66:807–815, 1991
35. Rusnak F, Mertz P: Calcineurin: form and function. *Physiol Rev* 80:1483–1521, 2000
36. Zhang BW, Zimmer G, Chen J, Ladd D, Li E, Alt FW, Wiederrecht G, Cryan J, O'Neill EA, Seidman CE, Abbas AK, Seidman JG: T cell responses in calcineurin A alpha-deficient mice. *J Exp Med* 183:413–420, 1996
37. Gooch JL, Toro JJ, Guler RL, Barnes JL: Calcineurin A-alpha but not A-beta is required for normal kidney development and function. *Am J Pathol* 165:1755–1765, 2004
38. Gooch JL, Roberts BR, Cobbs SL, Tumlin JA: Loss of the alpha-isoform of calcineurin is sufficient to induce nephrotoxicity and altered expression of transforming growth factor-beta. *Transplantation* 83:439–447, 2007
39. Meehan SM, McCluskey RT, Pascual M, Preffer FI, Anderson P, Schlossman SF, Colvin RB: Cytotoxicity and apoptosis in human renal allografts: identification, distribution, and quantitation of cells with a cytotoxic granule protein GMP-17 (TIA-1) and cells with fragmented nuclear DNA. *Lab Invest* 76:639–649, 1997



Summary and General Discussion

40. van Es LA, de HE, Vleming LJ, van der WA, Mallat M, Bajema I, Bruijn JA, de Fijter JW: GMP-17-positive T-lymphocytes in renal tubules predict progression in early stages of IgA nephropathy. *Kidney Int* 73:1426-1433, 2008

