

Cover Page



Universiteit Leiden



The handle <http://hdl.handle.net/1887/31632> holds various files of this Leiden University dissertation.

Author: Mensink, Gertjan

Title: Bilateral sagittal split osteotomy by the splitter-separator technique: technical aspects, safety, and predictability

Issue Date: 2015-01-29

8

Bilateral sagittal split osteotomy in a mandible, previously reconstructed with a non-vascularised bone graft

Int J Oral Maxillofac Surg. 2013;42(7):830-4

Mensink G
Verweij JP
Gooris PJJ
van Merkesteyn JPR

Abstract

This case reports of a bilateral sagittal split osteotomy (BSSO) in a reconstructed mandible. A 28-year old woman underwent a segmental mandibulectomy, due to a multicystic ameloblastoma in the left jaw. After primary plate reconstruction, final reconstruction was performed with a left posterior iliac crest cortico-cancellous autograft. Due to a pre-existing Class II malocclusion, the patient was analyzed for combined orthodontic-surgical treatment. Subsequently, after one year of orthodontic treatment, the BSSO was planned. The sagittal split was performed in the remaining right mandible and on the left side in the iliac crest cortico-cancellous autograft. Ten months later, oral rehabilitation was completed with implant placement in neo-mandible as well. Follow-up showed a Class I occlusion, with good function. The patient was very satisfied with the functional and aesthetic results. This shows a BSSO can be performed in a reconstructed mandible, without side effects and with good functional and aesthetic results.

Introduction

A bilateral sagittal split osteotomy (BSSO) is a procedure used frequently for the correction of a Class II malocclusion. Although the technique still presents a certain degree of technical difficulty, it has become a reliable procedure in orthognatic surgery. Reports of BSSO in a mandible, reconstructed with a non-vascularised bone graft, after hemimandibulectomy (because of an ameloblastoma), have not been published previously.

Multicystic ameloblastoma (MA) is an uncommon benign odontogenic neoplasm of the jaws. This cystic tumour is most often found in the mandible in the region of the molars and ramus. Ameloblastoma usually progresses slowly, but are locally invasive and, uncontrolled, may cause significant morbidity and sometimes death. MA is the most common ameloblastoma and is considered the most aggressive variant. As curative treatment segmental mandibulectomy with a 1- to 1.5-cm linear bony margin is the treatment of choice in these cases.¹

After (partial) resection of mandible, due to large benign tumours, reconstruction is necessary. Several reconstructive procedures, such as vascularised and non-vascularised bone flaps, can be considered.^{2,3} A common technique is reconstruction with a non-vascularised iliac crest bone graft.⁴

After mandibular reconstruction, oral rehabilitation can be completed with implant placement. High survival and success rates after implant placement in autogenous bone grafts are reported, with an excellent prognosis of implant-supported prostheses.⁵

This study reports a case of a bilateral sagittal split osteotomy, in combination with implant rehabilitation in the non-vascularised iliac crest bone graft in a 33-year old woman after hemimandibulectomy, due to a multicystic ameloblastoma.

Case report

A healthy, 28-year old, female patient was diagnosed with a follicular type multicystic ameloblastoma in the body of the mandible, near the mandibular angle on the left side. (Figure 1) The patient underwent a segmental mandibulectomy, starting between the first and second premolar to the ramus, with preservation of the left condyle.

Primary reconstruction was performed with a plate (UniLOCK Plate 2.4, angled, TiCP, SYNTHES, Oberdorf, Germany). Seven months later, after recovery and confirmation of clear pathologic margins, the mandible was reconstructed as described by Marx.⁴ Restoration of the left hemimandible was performed with a left posterior iliac crest cortico-cancellous autograft. The defect of the mandible was measured (17 mm by 56 mm) preoperatively, using an orthopantomogram (OPT). Via extra-oral approach the initial reconstruction plate was visualized and freed, because

it had been fractured, due to trauma. A new similar plate was placed to support and fixate the bone graft. The cortico-cancellous graft was adjusted to the lingual side of the plate and kept in place by primary closure of the soft tissues in several layers. Recovery was uneventful and the graft consolidated in a slightly inferior position. (Figure 2)

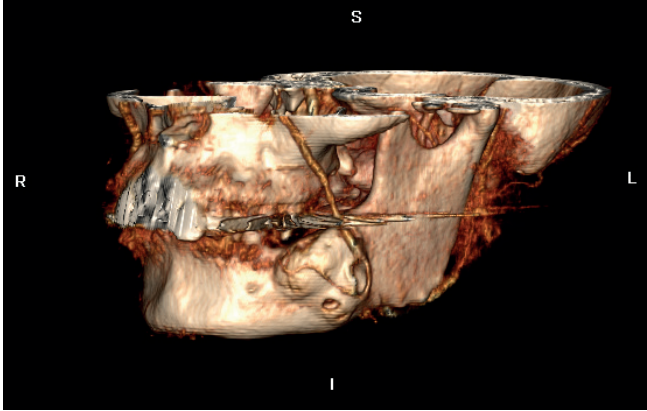


Figure 1 Three-dimensional image of the multicystic ameloblastoma in the body and angle of the left hemimandible.

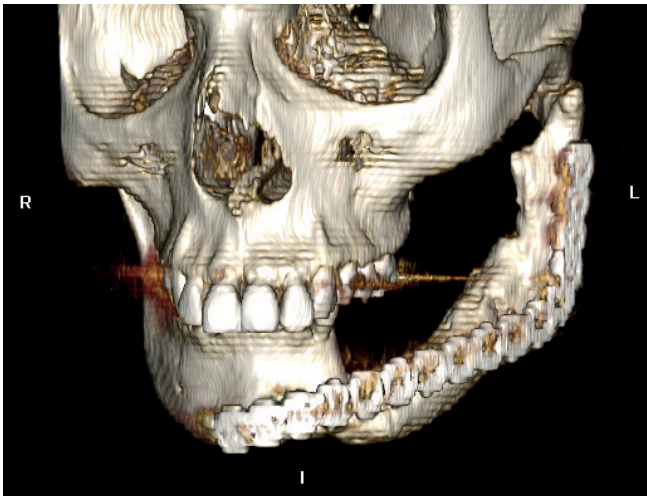


Figure 2 Three-dimensional image of the mandible after reconstruction with a plate and autologous bone from the left posterior iliac crest. The cortico-cancellous autograft consolidated in a slightly inferior position.

Postoperative follow-up showed a pre-existing Class II malocclusion with traumatic gingival recession in the maxillary incisors and generalized periodontitis. (Figures 3 and 4) The second molar in the upper left jaw was absent. The second premolar and first molar of the upper left jaw showed no occlusion because of missing antagonists, after the hemimandibulectomy.

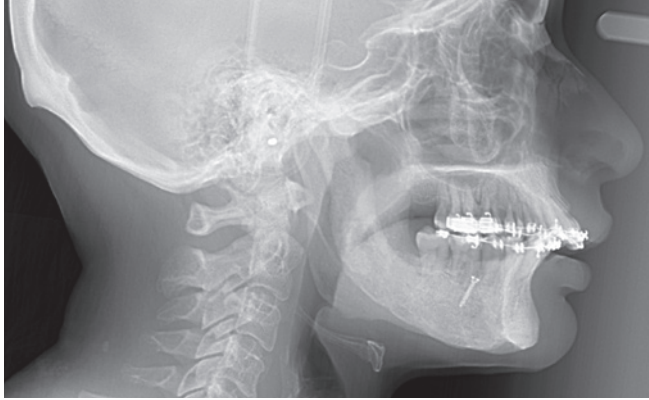


Figure 3 Lateral cephalogram taken 1 month before bilateral sagittal split osteotomy, showing a pre-existing Class II malocclusion.

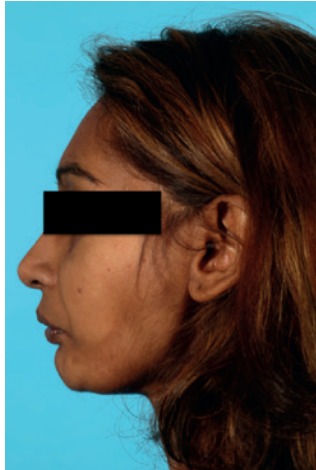

Figure 4 Photograph taken before BSSO, showing the contour of the successfully reconstructed mandible, resulting in a Class II profile, with a shortened vertical length of the face.

Due to her Class II malocclusion with palatal soft tissue trauma, she was analysed for a combined orthodontic-surgical treatment and occlusal rehabilitation with implants. Radiographic examination in preparation for BSSO showed a bony union of the cortico-cancellous graft, diffuse periodontal reduction of bone and an impacted third molar in the right mandible. Initial treatment of the periodontitis was started.

Preceding the orthognatic surgery, one year previous to BSSO, the reconstruction plate was removed, combined with remodelling of the left hemimandible with autogenous bone from the right anterior iliac crest and removal of the impacted third molar (Figure 5). After successful treatment and stabilization of the periodontitis, staged orthodontic and surgical treatment was initiated to restore occlusion and prevent further palatal and periodontal trauma.

After uneventful healing the patient was planned for orthognatic treatment, 5 years after the first operation. The bilateral sagittal ramus split on the right side was performed, with the use of sagittal splitters and separators instead of chisels, as first described by Van Merkesteyn et al.⁶ and Mensink et al.⁷ In the neomandible, the distal end of the iliac crest graft was found to be the site with the highest bone quality and quantity, therefore the split was planned in this section of the mandible. Horizontal, sagittal and vertical cuts were made with a saw (sagittal cut) and Lindeman burr (horizontal and vertical cut) and the split was completed with chisels in combination with sagittal splitters and separators. Chisels were necessary due to the small consistent cortical bone and could be used, because of the absence of the inferior alveolar nerve after hemimandibulectomy.

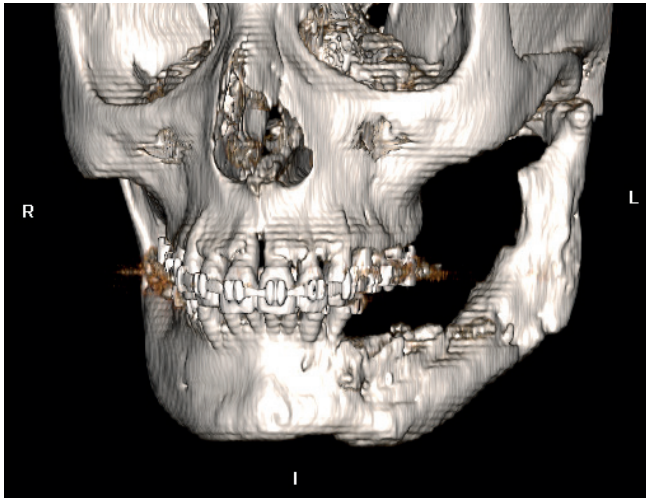


Figure 5 Three-dimensional image of the reconstructed mandible after removing the reconstruction plate and remodelling of the left hemimandible with autologous bone from the right anterior iliac crest.

After complete mobilisation of the proximal and distal parts, the mandible was placed into the new intermaxillary relationship using a wafer and intermaxillary wire fixation was applied.

After precise placement of the proximal segments, with normal clinical support of the temporomandibular joints, the right side was fixated with three bicortical screws in the upper border of the mandible. Then the iliac crest graft was subsequently fixated with two bicortical screws. After removal of the temporary intermaxillary fixation a new symmetrical Class I occlusion was created. (Figures 6 and 7)

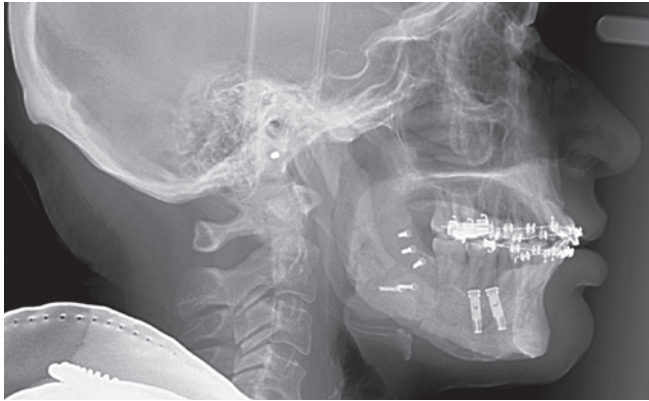


Figure 6 Lateral cephalogram showing a Class I occlusion after bilateral sagittal split osteotomy and subsequent implant placement.

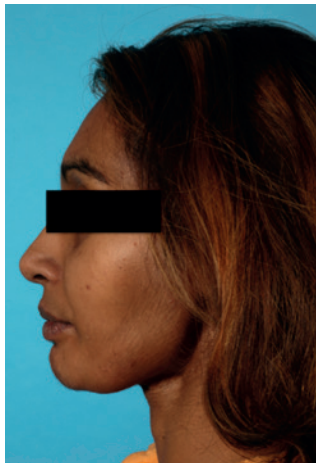

Figure 7 Photograph taken after BSSO, showing a Class I profile as a result of the operation, with a normalized vertical length of the face.

Three months after BSSO, the initial stage of implant treatment took place. Two submucosal implants (length 13mm, diameter 3.8mm, Branemark, Nobel biocare, Houten, the Netherlands) were placed in the position of the former second premolar and first molar of the left mandible. Seven months after implant placement, the implants were recovered to place 2 healing abutments. Subsequently the prosthetic phase started, after healing of the wound.

From the first operation to the Class I occlusal rehabilitation took about 6 years. At the last follow-up the patient had a good function and was satisfied with the result.

Discussion

The different treatment options for patients with ameloblastoma range from enucleation and curettage to more radical surgical management, such as marginal or segmental resection. MAs are more aggressive and associated with a higher rate of recurrence in comparison with unicystic or peripheral ameloblastoma.¹ MAs of the follicular type shows the highest percentage of recurrence. As this patient was diagnosed with a MA of the follicular type, radical surgical management was indicated. Segmental mandibulectomy with histopathologically clear bony margins is the most effective in preventing recurrence and was therefore the treatment of choice in this case.¹

After segmental resection of the mandible, different methods of reconstruction can be chosen. The two most frequently used techniques are reconstruction with a vascularized bone flap (VBF) or a non-vascularized bone graft (NVBG). VBF, often in the form of a vascularized fibular free flap, is the most commonly used technique for reconstruction, with high success rates and high endosseous implant success.⁸ In patients with prior radiation therapy or very large defects (>60 mm), reconstruction with a VBG is the therapy of choice, because these factors significantly decrease success rates of NVBG.⁹

However, NVBG are widely used as well and can be very useful, especially in secondary reconstructions. Non-vascularized bone grafts allow for an easier reconstruction, with higher functional success and create a better contour and bone volume for facial esthetics and subsequent implant insertion than VBF.^{9,10} In this case, no prior radiation therapy was necessary because of the nature of the tumor and the mandibular defect was less than 60 mm. Primary reconstruction with a plate was performed in order to be able to confirm histopathologically clear bony margins before secondary reconstruction. Owing to the mentioned advantages, secondary reconstruction was subsequently done with a non-vascularized iliac crest posterior autograft.

The most common complication after BSSO is damage to the inferior alveolar nerve, resulting in neurosensory disturbances of the lip and/or chin, also known as

hypoesthesia. In this patient hypoesthesia was already present on the left side, due to the previous hemimandibulectomy. This made the use of chisels in addition to our conventional technique favorable, because of small cortical bone in the iliac crest autograft. On the right side the inferior alveolar nerve was not damaged using only sagittal splitters and separators and no hypoesthesia was present after BSSO. Other complications after BSSO, such as bad splits, infection, non-union, bleeding complications and osteomyelitis are not very frequent and were not present in this patient.

Oral rehabilitation with implant placement is often an important part of the dental reconstruction after mandibular reconstruction and helps prevent recurrence of malocclusion. High success and survival rates after implant placement in bone grafts have been reported.⁸ Dental implants placed in a non-vascularized bone graft provide a reliable basis for dental rehabilitation.⁵ The moment of implant placement is normally several months (3-4 months) after bone augmentation or reconstruction. In this case implant placement concomitant with BSSO was considered, but postoperative implant placement was preferred, because of the altered position of the mandible after BSSO. When the patient discovered she was pregnant, placement of dental implants was delayed. Dental implant placement was nevertheless necessary, because of the proceeding bone reduction and was thus commenced later than planned, after more than five months of pregnancy.

In our patient, occlusion Class I remained present after BSSO, with good functional and aesthetic results. Anesthesia on the left side was pre-existing after hemimandibulectomy and hypoesthesia was absent on the right side. No other complications after BSSO were present and successful implant placement resulted in full oral rehabilitation. This shows the bilateral sagittal split osteotomy can be performed in a reconstructed mandible, with no side effects and a good result.

References

1. Carlson ER, Marx RE. The ameloblastoma: primary, curative surgical management. *J Oral Maxillofac Surg* 2006;64(3):484-494.
2. Wells MD. Part I. Mandibular reconstruction using vascularized bone grafts. *J Oral Maxillofac Surg* 1996;54(7):883-888.
3. Carlson ER, Marx RE. Part II. Mandibular reconstruction using cancellous cellular bone grafts. *J Oral Maxillofac Surg* 1996;54(7):889-897.
4. Marx RE. Mandibular reconstruction. *J Oral Maxillofac Surg* 1993;51(5):466-479.
5. Chiapasco M, Colletti G, Romeo E, Zaniboni M, Brusati R. Long-term results of mandibular reconstruction with autogenous bone grafts and oral implants after tumor resection. *Clin Oral Implants Res* 2008;19(10):1074-1080.
6. van Merkesteyn JP, Zweekers A, Corputty JE. Neurosensory disturbances one year after bilateral sagittal split mandibular ramus osteotomy performed with separators. *J Craniomaxillofac Surg* 2007;35(4-5):222-226.
7. Mensink G, Zweekers A, Wolterbeek R, Dicker GG, Groot RH, van Merkesteyn RJ. Neurosensory disturbances one year after bilateral sagittal split osteotomy of the mandibula performed with separators: A multi-centre prospective study. *J Craniomaxillofac Surg* 2012.
8. Foster RD, Anthony JP, Sharma A, Pogrel MA. Vascularized bone flaps versus nonvascularized bone grafts for mandibular reconstruction: an outcome analysis of primary bony union and endosseous implant success. *Head Neck* 1999;21(1):66-71.
9. Handschel J, Hassanyar H, Depprich RA. Nonvascularized iliac bone grafts for mandibular reconstruction--requirements and limitations. *In Vivo* 2011;25(5):795-799.
10. Pogrel MA, Podlesh S, Anthony JP, Alexander J. A comparison of vascularized and nonvascularized bone grafts for reconstruction of mandibular continuity defects. *J Oral Maxillofac Surg* 1997;55(11):1200-1206.

