

Cover Page



Universiteit Leiden



The handle <http://hdl.handle.net/1887/20556> holds various files of this Leiden University dissertation.

**Author:** Scherptong, Roderick Wiebe Conrad

**Title:** Characterization of the right ventricle : embryonic development, noninvasive imaging and electrocardiography

**Issue Date:** 2013-02-26

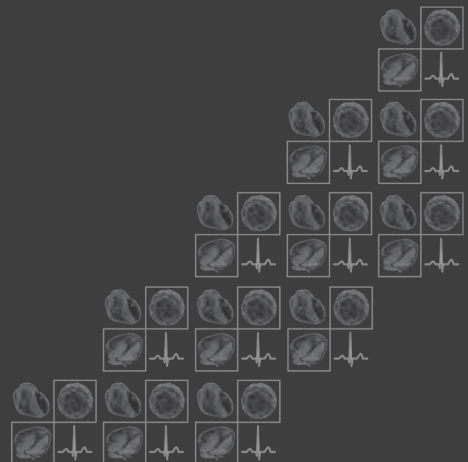# Chapter 4

---

## Tricuspid Valve Surgery in Adults with a Dysfunctional Systemic Right Ventricle: Repair or Replace?

Roderick WC Scherptong  
Hubert W Vliegen  
Michiel M Winter  
Eduard R Holman  
Barbara JM Mulder  
Ernst E van der Wall  
Mark G Hazekamp

*Circulation.* 2009 Mar 24;119(11):1467-72.



## ABSTRACT

---

### Background

In patients with a right ventricle (RV) in systemic position, tricuspid valve surgery for regurgitation beyond adolescence is subject of debate. The aim of this study was to evaluate complications, survival and benefit of tricuspid surgery in adult patients with an atrial-level correction for transposition of the great arteries or congenitally corrected transposition of the great arteries.

### Methods & Results

All adult patients (n=16; 7 male, 9 female; age:  $35 \pm 11$  yrs) who underwent tricuspid valvuloplasty (TVP, n=8) or replacement (TVR, n=8) in the period 1999–2008 were included. Complications and survival were analyzed and post-operative changes in RV function and functional class were evaluated. Tricuspid regurgitation was graded 1 to 4 according to the severity, right ventricular dysfunction was graded 1 to 4 (1; no dysfunction – 4; severe dysfunction) and functional status was determined according to NYHA class.

Although complications occurred in eleven patients, all could be managed adequately. Three patients died 109, 180 and 659 days after surgery respectively, the first patient after TVR and the latter two after TVP. Overall, tricuspid valve function improved (from grade  $3.1 \pm 0.8$  to  $0.9 \pm 1.0$ ;  $P = 0.001$ ), functional class improved (from  $2.7 \pm 0.6$  to  $2.1 \pm 0.8$ ;  $P = 0.007$ ), whereas RV function remained unchanged. After TVP, however, recurrent moderate TV regurgitation was frequently observed in three patients (37%).

### Conclusions

Mortality is low after tricuspid surgery in adult patients with mild to moderate RV dysfunction. In general, tricuspid valve function and functional class improve significantly after operation, whereas systemic RV function is preserved. TVP however, is associated with a high recurrence rate of regurgitation.

## INTRODUCTION

Patients with congenitally corrected transposition of the great arteries (ccTGA) and patients with atrially corrected transposition of the great arteries (acTGA), have a morphologically right ventricle (RV) that sustains the systemic circulation.<sup>1-3</sup> In these patients, regurgitation of the systemic atrioventricular valve, the tricuspid valve (TV), is a common finding. When TV regurgitation becomes severe, it is associated with RV failure and decreased survival.<sup>4</sup> In adolescent or younger patients, it can be opted to treat this surgically by retraining the left ventricle by means of pulmonary artery banding and subsequent relocation of the left ventricle into systemic position. In adults beyond the second decade of life however, results of these operations are still mainly negative.<sup>5-7</sup> Another surgical option, which is replacement or repair of the TV, is controversial, as data demonstrating favorable survival after these operations is currently insufficient. The only large study so far, in which beneficial effects of TV replacement are demonstrated, is the study by van Son et al. published in 1995, which reports the follow-up of 40 patients with ccTGA who were operated for TV regurgitation.<sup>8</sup> In other reports, attempts to repair the TV in patients with ccTGA are described as largely unsuccessful and in these reports consideration for the above described double switch procedure is advocated.<sup>9,10</sup> Study results of TV operations in patients with acTGA are even scarcer than in ccTGA. The general opinion in literature is that the role of TV surgery, as a treatment option for patients with acTGA and impending RV failure, should be limited.<sup>11</sup> However, studies that focus on systematic evaluation of TV surgery in adult patients with acTGA and RV dysfunction are lacking.<sup>12-15</sup> Therefore, the aim of this study was to evaluate complications, survival and benefit of tricuspid valvuloplasty (TVP) or replacement (TVR) as the first option in patients with important tricuspid regurgitation and a dysfunctional right ventricle in systemic position.

## METHODS

### Patient population

All patients, either referred from other medical centers or from the outpatient clinic of our center with ccTGA or acTGA, who underwent TVP or TVR for tricuspid regurgitation between 1998 and 2008, were included in this study. Patients were considered for surgery when the combination of important tricuspid regurgitation (grade 3 or 4) and mild to moderate systemic RV dysfunction was present on echocardiographic evaluation. RV function had to be sufficiently preserved, as tricuspid surgery in later stages of RV dysfunction had poor outcome in previous studies.<sup>8,16</sup> Furthermore, only those patients with functional impairment who were in New York Heart Association (NYHA) class 2 or 3 were regarded suitable for elective

tricuspid surgery. Cardiac function and anatomy was evaluated pre-operatively with cardiac magnetic resonance imaging or multi slice computed tomography if a recent evaluation was not available. These evaluations were also used to assess whether concomitant procedures, including baffle and/or conduit revisions, were necessary.

## **Study protocol**

Complications related to the procedure, survival and operation benefit in terms of TV competence, RV function and NYHA class were evaluated. First, primary diagnosis (ccTGA or acTGA), previous operations and pre-operative TV competence, RV function and NYHA class were noted. Secondly, the type of procedure (TVP or TVR) and concomitant procedures were documented. Thirdly, we observed post-operative complications and finally, to assess operation benefit, we analyzed post-operative changes in RV function, tricuspid valve competence and functional class during follow-up.

## **Complications and survival**

Post-operative complications were categorized into: arrhythmia, low cardiac output (defined as persistently low arterial pressures in the post-operative period, not responding to plasma volume expansion), renal insufficiency, infection and rethoracotomy. Maximum survival was defined as the period between the first day post-operative until the last available follow-up date or until the occurrence of the composite endpoint death or recurrent severe tricuspid regurgitation. Differences in survival were compared between the TVP and TVR procedure.

## **Operation benefit**

Echocardiography was used for the assessment of RV and TV function. For the purpose of this study, the echocardiograms, made pre-operatively and during periodical follow-up after surgery, were reviewed for RV and TV function. The echocardiographic evaluations were done three weeks, three months and ten months after operation. Tricuspid regurgitation was graded 1 to 4 according to the severity. RV function was analyzed semi-quantitatively and classified as either normal 1, mildly depressed 2, depressed 3 or severely depressed 4.<sup>17,18</sup> Furthermore, patient functional status was assessed pre- and post-operatively according to NYHA class.

## Operative technique

All patients were operated by the same surgeon, through median (re)sternotomy using total cardiopulmonary bypass and mild-to-moderate hypothermia that was combined with antegrade perfusion of a crystalloid cardioplegic solution. The TV was approached via either the right atrium (acTGA) or via the atrial septum and left atrium (ccTGA). Initially, TVP was intended in all patients. For this type of surgery, a classical Carpentier-Edwards or the newer Edwards MC<sub>3</sub> annuloplasty ring (Edwards LifeSciences Inc, Irvine, CA, USA) was used. However, when pre- or intraoperatively, either the quality of the TV leaflets was regarded insufficient (eg. dysplastic tricuspid leaflets), or when significant leaflet tethering was present, it was decided to replace rather than repair the TV. Moreover, when during the operation the initial TVP did not result in reduction of regurgitation, the TV was also replaced within the same operation. For this procedure, a CarboMedics bileaflet mechanical prosthesis (Sulzer CarboMedics Inc, Austin, Tx, USA), a St. Jude Medical mechanical prosthesis (St. Jude Medical Inc, St. Paul, MN, USA) or a Medtronic Mosaic porcine bioprosthesis (Medtronic Inc, Minneapolis, Minn, USA) was used.

## Statistical analysis

SPSS (12.0.1, SPSS Inc, Chicago, IL, USA) was used for statistical analysis. Data are presented as mean  $\pm$  standard deviation (SD), unless mentioned otherwise. Due to the small number of patients, the Friedman test and the Mann-Whitney U-test were used to compare pre- and postoperative TV function, RV function and functional class. Kaplan-Meier curves were drawn and the logrank test was used to compare the difference between the TVP and TVR procedure. *P*-values  $<0.05$  were considered statistically significant.

The authors had full access to and take full responsibility for the integrity of the data. All authors have read and agree to the manuscript as written.

## RESULTS

Sixteen patients were operated, nine with ccTGA and seven with acTGA. Characteristics of these patients are summarized in Table 1. Pre-operatively, grade  $3.1 \pm 0.8$  TV regurgitation was observed. Most patients exhibited mildly depressed RV function ( $n=12$ ) and pre-operative functional class according to NYHA was  $2.7 \pm 0.6$ . An overview of how patients were operated is depicted in figure 1. In 14 patients the mechanism of tricuspid regurgitation was regarded malcoaptation of the tricuspid leaflets. This was either due to annular dilatation with intact leaflets ( $n=9$ ) or due to structural abnormalities of the TV other than Ebstein(-like) malforma-

tions (n=5). In eleven patients, TVP was initially attempted. In three cases, this procedure did not result in improved TV competence, and it was decided to do TVR in the same operation. In four patients the TV leaflets were Ebstein-like or had important other malformations and in one patient the tricuspid annulus was too severely dilated to perform TVP, therefore TVR was done directly in these cases. In nine patients, concomitant procedures, mainly conduit or baffle revisions (n=6), were performed.

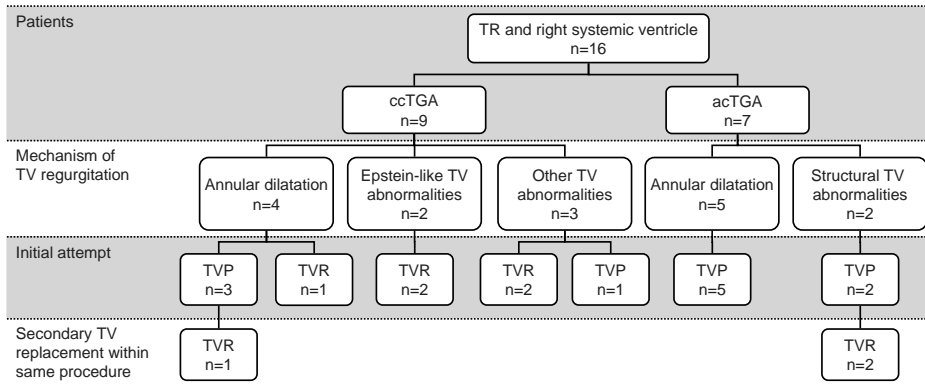
## Complications and survival

In Table 2, all major, post-operative complications are summarized. One patient, operated acutely after explantation of an infected ICD, died 109 days after surgery. This patient suffered from a multitude of complications and eventually died from therapy-refractory sepsis. Arrhythmia was the most frequently encountered short-term complication, occurring in eight patients. In one patient, recurrent ventricular fibrillation was observed post-operatively which required ICD implantation, five patients suffered from supraventricular tachycardia which was treated with cardioversion in three and with medication in two. One patient suffered from sinus arrest and one patient had AV block, both treated with pacemaker insertion. Another complication that occurred frequently was low cardiac output caused by ventricular

**Table 1.** Patient characteristics.

	ccTGA (n = 9)	acTGA (n = 7)
<b>Age (yrs)</b>	34.2 ± 14.5	35.0 ± 5.9
<b>Previous operations (n)</b>		
VSD closure	4	
ASD closure	1	
TVP	2	
PVR	2	
PA banding	1	
Mustard		5
Senning		2
<b>Current operation (n)</b>		
TVP	3	5
TVR	6	2
<b>Concomitant procedures (n)</b>		
Conduit/baffle revision	2	4
Mini MAZE procedure	3	
VSD closure	1	
PA banding	1	

acTGA: atrial correction for transposition of the great arteries; ASD: atrial septal defect; ccTGA: congenitally corrected transposition of the great arteries; PA: pulmonary artery; PVR: pulmonary valve replacement; TVP: tricuspid valvuloplasty; TVR: tricuspid valve replacement; VSD: ventricular septal defect.



**Figure 1.** Operative approach to patients. In total, 16 patients were operated, 9 ccTGA and 7 acTGA patients. Annular dilatation was the main mechanism of tricuspid regurgitation, but valvular abnormalities were also present. In three patients, the initial attempt to repair the tricuspid valve was unsuccessful and a “secondary” tricuspid valve replacement was done. acTGA, atrially corrected transposition of the great arteries; ccTGA, congenitally corrected transposition of the great arteries; TR, tricuspid regurgitation; TV, Tricuspid valve; TVP, tricuspid valvuloplasty; TVR, tricuspid valve replacement.

failure (n=5), requiring placement of an intra-aortic balloon pump in three patients and inotropic support in two patients. One patient was operated for gastric perforation and in another patient a rethoracotomy for persistent bleeding was performed. Five patients had renal insufficiency that required temporary dialysis with continuous veno-venous hemofiltration.

Fifteen patients were discharged in good condition after a mean duration of in hospital stay of  $27 \pm 28$  days. Two patients died after discharge. One patient was successfully resuscitated after an episode of ventricular fibrillation 180 days after operation, but died subsequently from ventricular failure, without signs of recurrent TR. The other patient died from recurrent TR and cardiac failure 659 days after surgery, before adequate treatment could be initiated. Follow-up of patients ranged from 92 days to 3101 days after operation with a 1-year survival rate of 86.7%. Kaplan-Meier curves (Figure 2) for the composite end-point death or recurrent severe tricuspid regurgitation revealed that TVR exhibited better survival as compared to patients who underwent TVP; the difference in survival, however was not statistically significant ( $P = 0.09$ ).

**Table 2.** Post-operative complications.

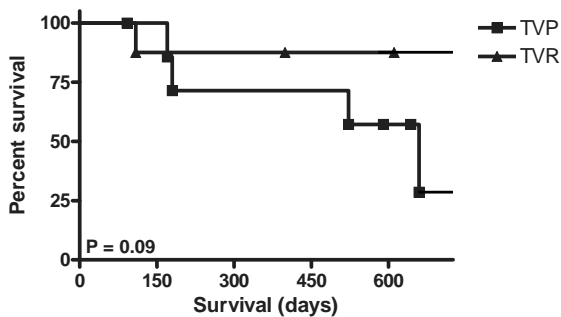
Complications	TVP	TVR	Total
None, n (%)	4 (25)	1 (6)	5 (31)
Arrhythmia, n (%)	3 (19)	5 (31)	8 (50)
Low Cardiac Output, n (%)	2 (13)	3 (19)	5 (31)
Renal insufficiency, n (%)	2 (13)	3 (19)	5 (31)
Infection, n (%)	1 (6)	1 (6)	2 (13)
Rethoracotomy, n (%)	1 (6)	1 (6)	2 (13)
Death, n (%)	0	1 (6)	1 (6)

TVP: tricuspid valvuloplasty; TVR: tricuspid valve replacement.



## Operation benefit

Overall, tricuspid function and functional class improved significantly after operation, whereas RV function remained stable. In figure 3 shows that tricuspid competence improved significantly after TVP and, as can be expected, after TVR. After TVP however, tricuspid function was not substantially improved in three patients (2 ccTGA, 1 acTGA) on post-operative echocardiographic evaluation. Therefore, the overall improvement of tricuspid function was less prominent as compared to TVR. Furthermore, three patients developed recurrent TV regurgitation resulting in regurgitation grade  $2.6 \pm 0.5$  at  $10.7 \pm 1.9$  months of follow-up after TVP. After TVR, on the other hand, the improvement of tricuspid competence was maintained at  $10.7 \pm 1.9$  months of follow-up, as can be expected. RV function, which was classified normal (grade 1) to severely depressed (grade 4), remained unchanged post-operatively and at  $10.7 \pm 1.9$  months follow-up (Figure 3). Pre-operatively, RV function was classified  $2.2 \pm 0.7$  and at maximum follow-up ( $3.2 \pm 1.9$  years) RV function was  $2.0 \pm 0.9$ . Moreover, no differences in RV function were noted pre-operatively and during follow-up between patients who underwent TVP and patients who underwent TVR. Overall, NYHA class improved from  $2.7 \pm 0.6$  to  $2.1 \pm 0.8$  ( $P=0.007$ ) at  $3.2 \pm 1.7$  months after surgery. At  $3.2 \pm 1.9$  years follow-up, functional class was  $2.0 \pm 0.9$ . Again, there was no difference in NYHA class between TVP and TVR pre-operatively or during follow-up.

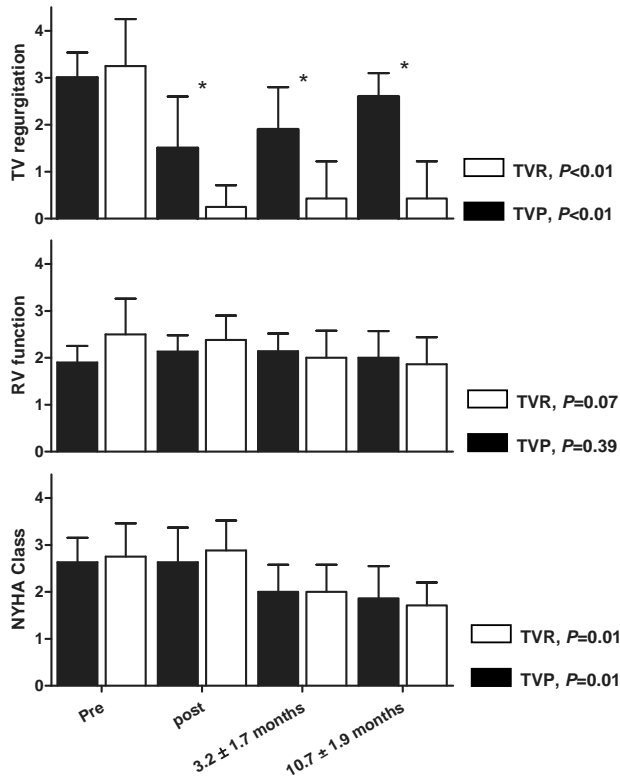


**Figure 2.** Survival curves for the composite end-point death or recurrent tricuspid regurgitation. A trend towards less favourable survival characteristics for patients who underwent tricuspid valvuloplasty was observed, which was, however, not statistically significant. TVP, tricuspid valvuloplasty; TVR, tricuspid valve replacement.

TVP	8	7	5	5	3
TVR	8	7	7	6	6

## DISCUSSION

In the current study we systematically evaluated complications, survival and benefit of TV surgery for substantial regurgitation in patients with a dysfunctional right ventricle in systemic position. Key findings were firstly that a high incidence of post-operative complications was observed. Furthermore, overall TV competence and functional class improved after operation. Finally, the survival characteristics of TVP appeared less favorable than those of TVR.



**Figure 3.** Follow-up of tricuspid function, right ventricular function and functional class. Significant improvement of tricuspid function was observed both after tricuspid valve replacement (TVR) as well as tricuspid valve plasty (TVP). After TVP however, the improvement was less prominent and recurrent tricuspid regurgitation was frequently observed. Right ventricular function remained stable during follow-up and there was no difference between patients who underwent TVP and patients who underwent TVR. NYHA class improved significantly both after TVP as well as TVR. The *P*-values denote the significance of the improvement after TV surgery separately for TVP and TVR. \* *P*<0.01 for the difference in TV competence between TVP and TVR. NYHA, New York Heart Association; RV, right ventricular; TV, tricuspid valve

The incidence of complications, related to the procedure, was high in our population. However, all complications were treated successfully in those patients who were operated electively and the presence of complications was not related to worse outcome. In the largest study on TV operations, so far, by van Son et al. comprising of 40 patients with ccTGA, similar types of post operative complications were described (arrhythmia, bleeding, infection) and a relation between post-operative complications and adverse outcome was also not reported.<sup>8</sup> In a report by Beauchesne et al. on patients with ccTGA, post-operative complications were again not related to post-operative outcome.<sup>19</sup> Therefore, provided that surgical treatment of TV regurgitation in patients with a right ventricle in systemic position is exclusively performed in specialized centers, complication rate should generally not be a reason to refrain from these operations.

Three patients, all with previous Mustard corrections, died in our population, making up a 1-year survival rate of 86.7%. In one of these patients, the cause of death was TV incompetence and associated systemic ventricular failure after tricuspid valvuloplasty. In the other patients, TV incompetence and systemic ventricular dysfunction was present but not indubitably related to the cause of death (sepsis, ventricular arrhythmia). In the previously mentioned study by van Son et al., survival rates of 78.0% at 5 years and 60.7% at 10 years were reported.<sup>8</sup> In other, smaller studies on patients with ccTGA, in which survival characteristics of TV surgery were reported as part of a larger study, 1-year survival rates range from 63% to 100%.<sup>10, 18–23</sup> To our knowledge, no studies are available that report data solely on TV operations in patients with acTGA. Incidentally, survival characteristics are reported as unfavourable in small groups of patients (n=3), with 1-year survival rates of 25% to 33%, which is much lower than the 1-year survival rate in our group of acTGA patients (71.4%).<sup>13, 15, 24</sup>

In general, TVP was intended in all patients. However, in patients with structural leaflet malformations or severe leaflet tethering, which was noted either pre-operatively or during surgery, it was decided to perform TVR. In these patients, the risk for recurrent TR after TVP was regarded higher as compared to patients with intact tricuspid leaflets, without signs of tethering.<sup>25, 26</sup> In our population, tricuspid competence demonstrated a significant improvement after operation. However, the results of TVP were less promising than the results of TVR. After TVP, the improvement was less prominent than after TVR and the rate of recurrence of regurgitation was relatively high after TVP (37%). Therefore, when comparing the survival curves of the TVP procedure to the TVR procedure there seems to be a disadvantage for TVP which was, however, not statistically significant. In our population, RV function remained stable during follow-up and no differences in RV function were noted between patients who underwent TVP and patients who underwent TVR. It should be noted that in most patients, the pre-operative degree of RV dysfunction was generally mild (n=12), and it could be questioned whether an important improvement in RV function is expected after TV surgery. The sparse results of earlier studies suggest that TV surgery in early stages of RV dysfunction is superior to TV surgery in more advanced stages of RV dysfunction.<sup>19</sup> Therefore, the strategy in most patients was to consider TV surgery on the basis of functional impairment, also when mild RV dysfunction was present. Although no improvement in RV function was observed on echocardiographic evaluation, functional class did improve in our population. A mechanism that may underlie this observation is that improved competence of the TV leads to more effective output of the systemic ventricle, whereas the ejection fraction might even decline. Before surgery, stroke volume is partially regurgitated back into the systemic atrium, whereas after surgery stroke volume completely attributes to cardiac output, leading to overall better function. Secondly, visual assessment of right ventricular function, although generally accepted, may not reveal subtle but important changes in RV function. Other imaging modalities, like cardiac magnetic resonance imaging, may demonstrate improved rather than stable RV function on the long term.

The combination of TR and progressive RV dysfunction is a frequent finding in patients with ccTGA or acTGA. It is associated with a rapid decline in functional class and decreased survival frequently necessitating surgical treatment.<sup>27</sup> Selection of the optimal surgical strategy, specifically in the “older” patients (3<sup>rd</sup> to 4<sup>th</sup> decade of life), is a complicated issue. It could be postulated that either relocation of the (morphologically) left ventricle in systemic position or cardiac transplantation, is the surgical treatment of choice in these cases. However, results after relocation of the left ventricle into systemic position, in terms of survival and benefit, are discouraging in the adult TGA population.<sup>28, 29</sup> The option of cardiac transplantation is probably the superior option from a functional point of view. Unfortunately, donor organs are scarcely available and cardiac transplantation can only be applied in a limited number of patients. Hence, cardiac transplantation as a treatment option in the approach to TGA patients with TR and a dysfunctional right ventricle is an exceptional solution. The results from our population, which is relatively old ( $34.2 \pm 14.5$  years in the ccTGA group and  $35.0 \pm 5.9$  years in the acTGA group), demonstrate that TVR and TVP are associated with low mortality and improvement of functional class. Therefore, it could be regarded as a first option in patients with a systemic right ventricle and TR. It should however be noted that survival characteristics tend to be worse after TVP, mainly caused by a high recurrence rate of TR. Tricuspid leaflet tethering may be the mechanism behind the recurrence of TR after TVP.

## Limitations

In the current study, semi-quantitative analysis of tricuspid and right ventricular function with echocardiography was used. Cardiac magnetic resonance imaging provides a more accurate modality for estimation of right ventricular function. However, an important number of patients have pacemakers and could not undergo magnetic resonance imaging. For consistency, we therefore chose echocardiography for comparison of data during follow-up. As another limitation, which is present in most studies on patients with congenital heart disease, the study population was small. Therefore, the results of this study remain to be confirmed prospectively in a larger patient population.

## CONCLUSION

Mortality is low after tricuspid surgery in patients with a right systemic ventricle. Although the incidence of post-operative complications is high, this should not be a reason to refrain from these operations. Short-term results demonstrate that tricuspid valve replacement in patients with a dysfunctional right ventricle is associated with an improvement of tricuspid valve function, stable right ventricular function and improvement of functional class. Valvulo-

plasty, which is associated with a high recurrence rate of regurgitation, is not advisable in this group of patients and tricuspid valve replacement should therefore be performed preferably.

## REFERENCES

1. Mustard WT. Surgical diagnosis and treatment of common paediatric cardiac anomalies. *R I Med J* 1964; 47:332-5.
2. Senning A. Surgical correction of transposition of the great vessels. *Surgery* 1959; 45:966-80.
3. Webb GD, McLaughlin PR, et al. Transposition complexes. *Cardiol Clin* 1993; 11:651-64.
4. Warnes CA. Transposition of the great arteries. *Circulation* 2006; 114:2699-709.
5. Duncan BW, Mee RB. Management of the failing systemic right ventricle. *Semin Thorac Cardiovasc Surg* 2005; 17:160-9.
6. Bove EL, Ohye RG, et al. Anatomic correction of congenitally corrected transposition and its close cousins. *Cardiol Young* 2006; 16 Suppl 3:85-90.
7. Mee RB. Severe right ventricular failure after Mustard or Senning operation. Two-stage repair: pulmonary artery banding and switch. *J Thorac Cardiovasc Surg* 1986; 92:385-90.
8. van Son JA, Danielson GK, et al. Late results of systemic atrioventricular valve replacement in corrected transposition. *J Thorac Cardiovasc Surg* 1995; 109:642-52.
9. Rutledge JM, Nihill MR, et al. Outcome of 121 patients with congenitally corrected transposition of the great arteries. *Pediatr Cardiol* 2002; 23:137-45.
10. Hraska V, Duncan BW, et al. Long-term outcome of surgically treated patients with corrected transposition of the great arteries. *J Thorac Cardiovasc Surg* 2005; 129:182-91.
11. Dodge-Khatami A, Kadner A, et al. In the footsteps of senning: lessons learned from atrial repair of transposition of the great arteries. *Ann Thorac Surg* 2005; 79:1433-44.
12. Chang AC, Wernovsky G, et al. Surgical management of late right ventricular failure after Mustard or Senning repair. *Circulation* 1992; 86:1140-1149.
13. Myridakis DJ, Ehlers KH, et al. Late follow-up after venous switch operation (Mustard procedure) for simple and complex transposition of the great arteries. *Am J Cardiol* 1994; 74:1030-6.
14. Horer J, Herrmann F, et al. How well are patients doing up to 30 years after a mustard operation? *Thorac Cardiovasc Surg* 2007; 55:359-64.
15. Horer J, Karl E, et al. Incidence and results of reoperations following the Senning operation: 27 years of follow-up in 314 patients at a single center. *Eur J Cardiothorac Surg* 2008;33:1061-67.
16. Prieto LR, Hordof AJ, et al. Progressive tricuspid valve disease in patients with congenitally corrected transposition of the great arteries. *Circulation* 1998; 98:997-1005.
17. Roos-Hesselink JW, Meijboom FJ, et al. Decline in ventricular function and clinical condition after Mustard repair for transposition of the great arteries (a prospective study of 22-29 years). *Eur Heart J* 2004; 25:1264-70.
18. Sano T, Riesenfeld T, et al. Intermediate-term outcome after intracardiac repair of associated cardiac defects in patients with atrioventricular and ventriculoarterial discordance. *Circulation* 1995; 92:11272-11278.
19. Beauchesne LM, Warnes CA, et al. Outcome of the unoperated adult who presents with congenitally corrected transposition of the great arteries. *J Am Coll Cardiol* 2002; 40:285-90.
20. Westerman GR, Lang P, et al. Corrected transposition and repair of associated intracardiac defects. *Circulation* 1982; 66:1197-1202.
21. Lundstrom U, Bull C, et al. The natural and "unnatural" history of congenitally corrected transposition. *Am J Cardiol* 1990; 65:1222-9.
22. Horvath P, Szufladowicz M, et al. Tricuspid valve abnormalities in patients with atrioventricular discordance: surgical implications. *Ann Thorac Surg* 1994; 57:941-5.

23. Acar P, Sidi D, et al. Maintaining tricuspid valve competence in double discordance: a challenge for the paediatric cardiologist. *Heart* 1998; 80:479-83.
24. Cochrane AD, Karl TR, et al. Staged conversion to arterial switch for late failure of the systemic right ventricle. *Ann Thorac Surg* 1993; 56:854-61.
25. Fukuda S, Song JM, et al. Tricuspid valve tethering predicts residual tricuspid regurgitation after tricuspid annuloplasty. *Circulation* 2005; 111:975-9.
26. Fukuda S, Gillinov AM, et al. Determinants of recurrent or residual functional tricuspid regurgitation after tricuspid annuloplasty. *Circulation* 2006; 114:1582-1587.
27. Voskuil M, Hazekamp MG, et al. Postsurgical course of patients with congenitally corrected transposition of the great arteries. *Am J Cardiol* 1999; 83:558-62.
28. Poirier NC, Yu JH, et al. Long-term results of left ventricular reconditioning and anatomic correction for systemic right ventricular dysfunction after atrial switch procedures. *J Thorac Cardiovasc Surg* 2004; 127:975-81.
29. Quinn DW, McGuirk SP, et al. The morphologic left ventricle that requires training by means of pulmonary artery banding before the double-switch procedure for congenitally corrected transposition of the great arteries is at risk of late dysfunction. *J Thorac Cardiovasc Surg* 2008; 135:1137-44.