



Universiteit
Leiden
The Netherlands

Maggot debridement therapy in surgery

Steenvoorde, P.

Citation

Steenvoorde, P. (2008, January 9). *Maggot debridement therapy in surgery*. Retrieved from <https://hdl.handle.net/1887/12552>

Version: Corrected Publisher's Version

License: [Licence agreement concerning inclusion of doctoral thesis in the Institutional Repository of the University of Leiden](#)

Downloaded from: <https://hdl.handle.net/1887/12552>

Note: To cite this publication please use the final published version (if applicable).



Chapter

5

Case reports and case series



5A Maggots in amputation sparing surgery

Based on the following article:

Clinical Infectious Diseases

G.N. Jukema¹, A.G. Menon¹, A.T. Bernards², P. Steenvoorde¹, A. Taheri Rastegar², J.T. van Dissel³
 Section of Traumatology, Department of Surgery¹, Department of Medical Microbiology², and Department of
 Infectious Diseases³, Leiden University Medical Center, Leiden, The Netherlands
Amputation-sparing surgery by nature : maggots revisited. Clin Infect Dis 2002; 35(12): 1566-71.

Introduction

In these times of high-tech medicine, it can still be efficacious to resort to basic principles that have evolved in nature and that may help the physician combat specific medical problems.^{9:116;117} For instance, traumatic wounds that fail to heal because of recurrent infections and underlying pathology, such as vascular insufficiency or diabetes mellitus, often leave physicians no choice but to resect the affected tissue. For minor wounds, this will not compromise the patient's quality of life, but for larger wounds on the extremities, as often occur in patients with vascular insufficiency or diabetes mellitus, amputation of part of a limb can be the only option. In selected cases, use of natural removers of necrotic and infected tissue—maggots (sterile larvae of *Lucilia sericata*)—may result in adequate wound healing and prevent the need to amputate a limb.^{13;54} In the past 3 years, we have applied sterile maggots to help remove infected necrotic tissue in 11 selected patients. We describe 2 of these patients in detail.

Case history 1.

A 16-year-old male patient was admitted to an intensive care unit because of meningococcal sepsis. The diagnosis was made on the basis of culture of skin biopsy samples, which yielded *Neisseria meningitidis* serogroup C. The patient received intravenous treatment with ceftriaxone in combination with gentamicin and rifampin; after a few days, therapy was changed to benzylpenicillin G, U iv 12_106 per day. The patient survived the acute episode of meningococcal sepsis but developed infectious necrosis of the extremities of the hands and feet (**Figure 1**). The patient was transferred to the trauma unit of our institution (Leiden University Medical Center, Leiden, The Netherlands); at admission, he was still febrile. Open partial borderline amputation of all middle phalanges of the second through the fifth fingers of the left and right hands and a resection of the distal phalanx of the left and right thumbs were done. In addition, Syme's amputation (amputation at the level of the ankle joint) of the right foot was done, as well as extensive soft-tissue debridement of the left foot. Empirical treatment with flucloxacillin, 1 g iv 6 times daily, was administered. *Staphylococcus aureus* susceptible to flucloxacillin were isolated from cultures of swabs of the amputation wounds of the fingers, of the stump from the Syme's amputation, and of the left foot wound. Seven hundred fifty sterile maggots (Polymedics Bioproducts) in 20 porous, polyvinyl alcohol (PVA) bags ("biobags") were placed on the wounds intraoperatively (**Figure 2**). After 3 days, the patient's clinical situation had improved substantially, and the high fever had subsided. The wounds showed significant improvement: granulating tissue had begun to grow and the amount of necrotic tissue was reduced. Therapy with maggots in biobags

was administered 7 times, and additional surgical debridement was not necessary. After 5 weeks, a superficial soft-tissue defect at the top of the partial amputation of the fifth finger of the right hand and the wound on the left foot were covered with autologous mesh grafts. After 2 months, the patient was discharged from the hospital to a rehabilitation center, and at 5 months all tissue defects had healed. The patient is able to walk with a prosthesis, without the help of crutches, and he is able to use both hands well (**figure 3**).

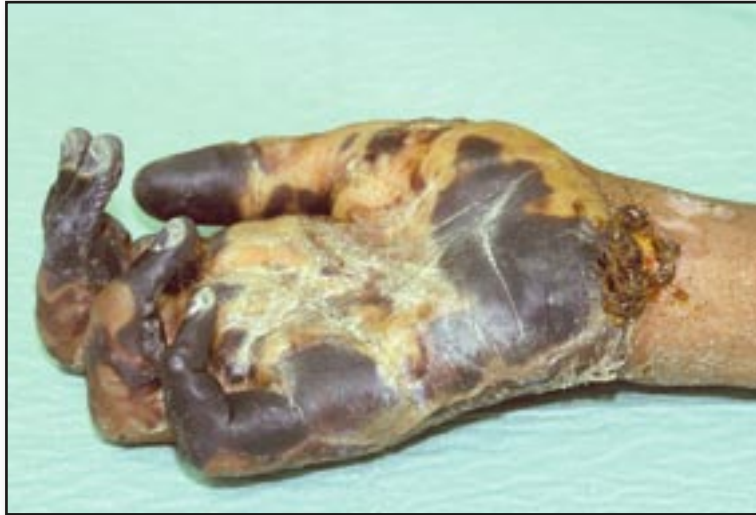

Figure 1: Patient 1. Necrosis of the hand, a sequela of meningococcal sepsis.

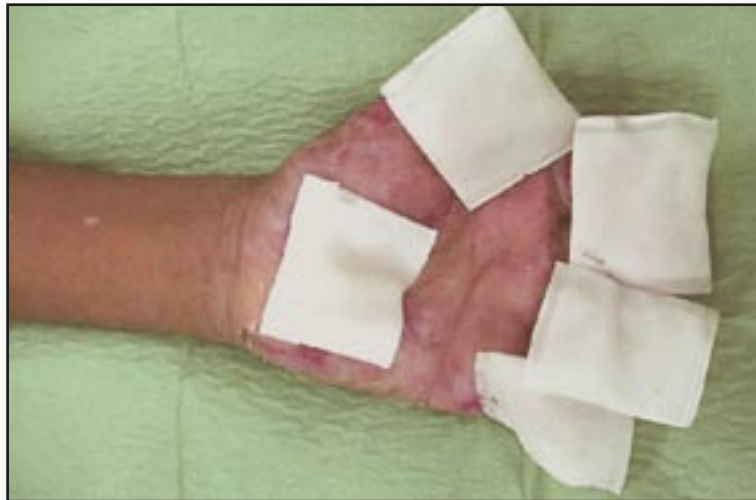

Figure 2: Patient 1. After partial amputation of the second through the fifth fingers, the left hand was covered with 5 “biobags” containing 20–30 maggots each. The porous polyvinyl alcohol membrane of the biobags allows free exchange of secretions and wound debris.

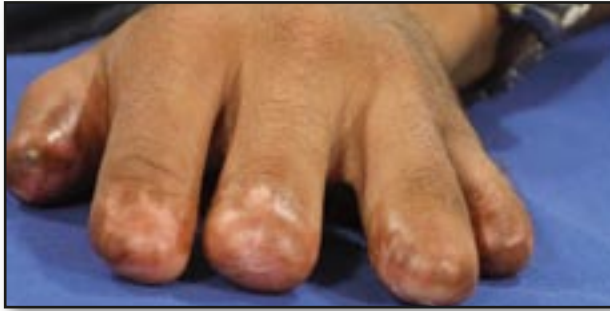

Figure 3: Patient 1. Left hand at the 1-year follow-up examination.

Case history 2.

A 54-year-old man with insulin-dependent diabetes mellitus and a smoking history of 35 pack-years had undergone an amputation of the first (great) toe of his left foot because of a nonhealing small wound. A surgical wound infection with *S. aureus* spread to the lower left leg, and amputation of the lower limb was done. Subsequently, the stump became infected and would have required an extended amputation (**Figure 4**). At this point, the patient was transferred to our hospital. At admission, he had a severe infection with wet gangrene of the stump, which required immediate surgical debridement and partial resection of the soleus and gastrocnemius muscle. The remaining tissue, however, showed poor vascularization. Postoperatively, maggot therapy was initiated; the patient did not receive systemic antibiotic therapy. The local inflammation rapidly decreased, and the condition of the lower extremity and upper leg improved (**Figure 5**). Within 1 week, signs of infection were subsiding, and the wound showed signs of granulation. For 2 weeks, the wound was treated with a combination of maggots and PVA foam (Biogard; Polymedics), after which maggot therapy was stopped and vacuum sealing treatment with PVA foam (Vacuseal/VAC Soft-Foam; KCI) was administered for another week. Finally, the wound was covered with a mesh graft transplant. The patient was discharged from the hospital after 5 weeks. Four months after discharge, the patient could walk with a prosthesis. After > 3 years of followup, no signs of infection have occurred (**Figure 6**).

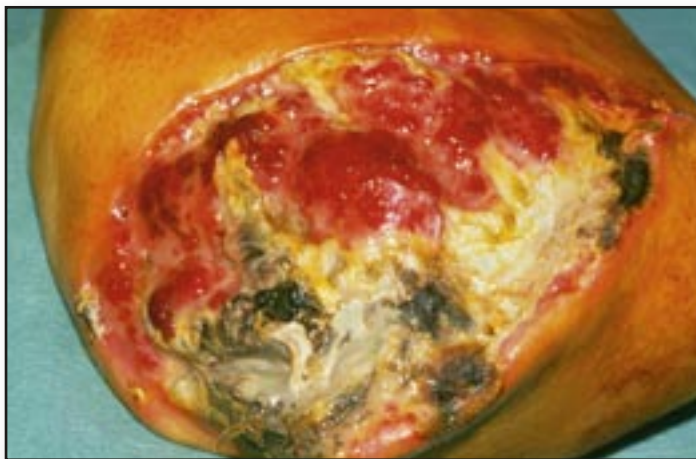

Figure 4: Patient 2. Gangrenous infection of the lower left leg stump.

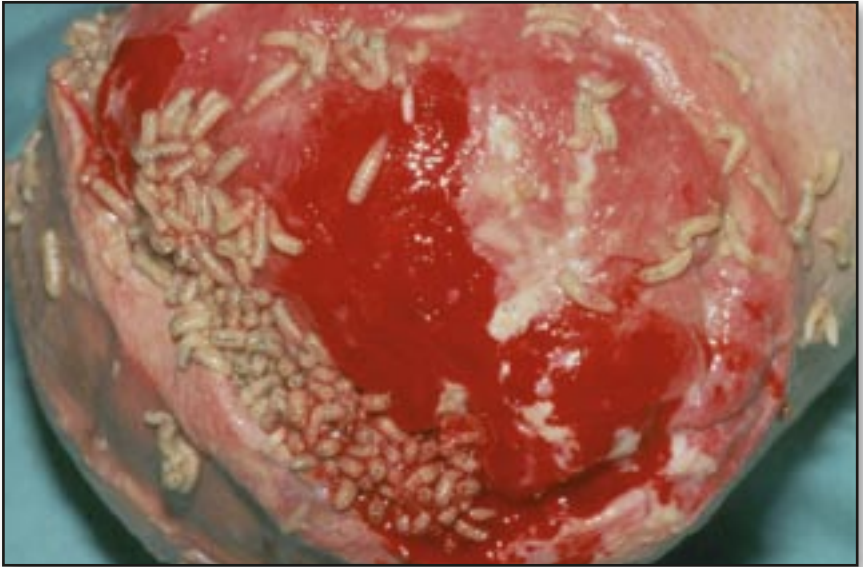

Figure 5: Patient 2. Lower left leg stump: 200–700 maggots were applied directly to the wound surface.

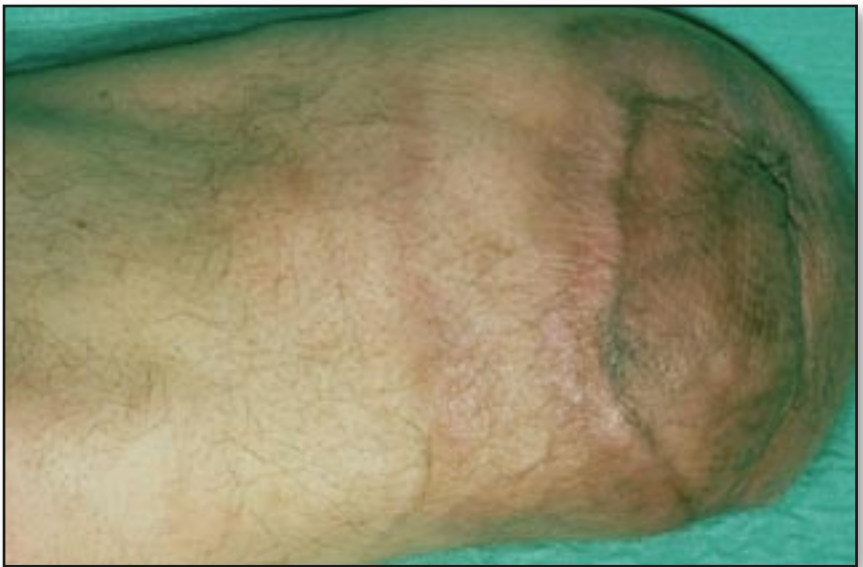

Figure 6: Patient 2. Lower left leg stump at the 1-year follow-up examination.

Discussion

These 2 patients with severe, secondarily infected necrotic wounds were treated with maggots, and this approach apparently helped remove necrotic tissue and prevented the need for disabling amputations of hands or limbs. For patient 1, an open amputation of both upper extremities below the elbow joint and both lower legs would have been necessary. For patient 2, who had diabetes, severe infection of the stump of the lower leg coincided with wet gangrene, a condition that usually necessitates amputation up to the upper leg. In both cases, maggots were applied to remove remaining necrotic tissue, thus helping to prevent the need for disabling amputations. In case of severe infections of a limb, natural “biosurgery” by sterile maggots may prevent the need for amputation and thus preserve the patient’s quality of life.¹¹⁸

We used 2 methods to apply maggots to the wounds of the 11 patients in our series. For the first 3 patients, sterile maggots were put freely on the wound surface, which was then covered with a loose net dressing (Table 1; patients 2, 3, and 6). After 3–4 days, maggots grow to 8–10 mm in length and the wound becomes painful because of their biting and crawling (Figure 5). Usually, large numbers of larvae (e.g., 1100) are applied to the wound surface, and administration of regional anesthesia often becomes necessary to reduce pain. Therefore, more recently, larvae have been incorporated within small “biobags,” the size of ordinary tea bags, made of porous PVA membrane. Maggots in biobags are no less active necrophages than are free maggots; they secrete enzymes and absorb wound debris through the permeable bag membrane, but do not cause the painful sensation of biting and crawling larvae directly on the wound (Figure 2). After the maggots have cleaned the wound, the biobags containing the maggots are removed, and rapid growth of granulating tissue may then be stimulated by vacuum sealing of the wound with PVA foam and polyurethane film⁸⁰ at a suction pressure of 50–60 kPa. In the 2 cases we describe here, amputation of extremities could be avoided, despite the serious medical problems of severe infection and vascular insufficiency secondary to smoking and diabetes mellitus. The preservation of the extremities was possible, at least in part, because of application of “surgical” maggots. During the last 3 years, we have used maggots as adjunct treatment for 11 patients (Table 1). The range of underlying diseases in these patients (open osteomyelitis in 5 patients, gangrene in 2, and soft-tissue infection or Charcot’s joint in 4) matches the indications mentioned in the sparse literature on the subject: for example, osteomyelitis¹¹⁹, venous ulcers^{100;120}, and diabetic foot infection.¹¹⁸

Although the methodological limitations of the present open-label, noncomparative cohort study precludes a definite conclusion concerning clinical efficacy, we believe that, for our patients, the local application of maggots, in most cases followed by vacuum sealing with PVA foam, may have helped prevent the need for disabling amputations. Nine of 11 patients recovered fully, and 2 died during follow-up. Deaths were not related to the primary infection for which maggots were applied: 1 patient died because of an accident and the other died months after treatment was finished because of an underlying hematologic disorder. Our experience shows that, even now, there may still be a place for an ancient treatment modality, such as application of “surgical” maggots.

Table 1: Summary of clinical characteristics of 11 patients treated locally with sterile maggots.

	Sex	Age (yr)	Diagnosis	Infected Region	Underlying condition(s)	Duration of Maggot therapy (days)	Dressing or no. of biobags used	Total no. of Maggots applied	No. of times maggots changed
1	M	50	Osteomyelitis	Tibia/fibula	Vascular	32	Net	800	9
2	M	60	Osteomyelitis	Knee joint	Vascular/ DM	12	Net	1000	4
3	M	41	Osteomyelitis	Both feet	Crush trauma both feet	28	Net	2900	7
4	M	81	Osteomyelitis	Femur	Trauma/ Steroid/ DM/Vascular	28	93	550	8
5	F	62	Osteomyelitis	Tibia/fibula	Trauma/ Vascular	20	31	360	6
6	M	54	Gangrene	Stump lower limb	Vascular/ DM	11	88	2000	3
7	M	16	Gangrene	Both hands and feet	Meningococcal Sepsis	27	78	2100	8
8	F	88	Soft Tissue Infection	Femur	Trauma	27	53	450	8
9	M	46	Soft Tissue Infection	Abdomen and perineal region	Fasciitis Necroticans	19	24	1200	5
10	M	51	Soft Tissue Infection	Femur	Trauma/ Vascular insufficiency	13	28	100	4
11	M	63	Ulcus Cruris Charcot feet	Lower leg	Chronic ulcers/ DM/ RA/ Steroid	34	78	1000	10

NOTE. DM = diabetes mellitus; F = female; M = male; RA = rheumatoid arthritis. “Biobags” indicates porous, polyvinyl alcohol bags containing maggots; “net” indicates a loose nylon mesh wound dressing over free maggots.

5B MDT for infection after breast-conserving surgery

Based on the following article:

Journal of Woundcare

P. Steenvoorde, J. Oskam

Department of Surgery Rijnland Hospital, Leiderdorp, The Netherlands.

Use of larval therapy to combat infection after breast-conserving therapy. *J Wound Care* 2005; 14(5): 212-213.

Introduction

Postoperative infection rates in breast conserving surgery, particularly with axillary clearance, can be as high as 18%.¹²¹ Treatment generally comprises standard wound care: drainage of pus, removal of necrotic tissue and targeted antibiotic therapy. The main indications for MDT are infected ulcers of the extremities^{89;102} with and without osteomyelitis, although all wounds with slough or necrosis can be treated with MDT.¹²² Rare indications are subacute mastoiditis¹²³, necrotising fasciitis¹²⁴ and even infected malignant wounds.^{3;125} Accidental myiasis in the breast has been reported,¹²⁶ but recent literature on the application of larvae in an infected breast is scarce. This paper presents a case study of a patient with an infected wound after breast conserving surgery for malignancy. Despite aggressive surgical and antibiotic therapy the wound persisted, healing only after MDT.

Case study

A 59-year-old woman underwent breast conserving surgery for a 4 x 2.5cm (Bloom Richardson grade III) adenocarcinoma of the breast. All lymph nodes were removed and were free of tumour. Adjuvant therapy comprised radiotherapy (66Gy) and chemotherapy. One day after surgery a large, uninfected haematoma was apparent post-surgery, which resolved leaving a fixed swelling. This was aspirated and clear fluid obtained. No malignant cells were identified and bacterial cultures were negative. The wound produced clear fluid and the breast was red and tender, despite broad spectrum antibiotic therapy. Eight months after initial surgery, when the patient was being treated on an outpatient basis, a fluid-producing fistula was excised in theatre. Initially this gave a good result, but a month later the patient reported high fever and presented at the A&E department with severe mastitis. The wound was opened revealing large quantities of pus, which grew *Staphylococcus aureus* on culture. The patient was re-admitted and given intravenous antibiotics (Floxapen). The wound, measuring 7 x 2cm and 4cm deep (**Figure 1**), was covered with yellow slough at the base (**Figure 2**). It was initially managed with alginate dressings and topical negative pressure. Pathological examination revealed no recurrence of tumour. It was decided to treat the wound with MDT, to which the patient willingly agreed. The alternative, in our opinion, was further surgery, which would mean a breast amputation. MDT was administered in the outpatient department. Some 60–80 maggots were applied twice three days apart. At the third application a

BioBag (BioMonde) was used as some maggots had ‘escaped’ on the previous occasion. To manage the wound odour, CarboFLEX (ConvaTec) was used, but with very limited effect. There was no alternative, except to change the outer dressing daily. Pain was adequately controlled with morphine (Durogesic 25µg plaster). After the first application the slough at the base of the wound had reduced. After the third (and final) application (10 days’ therapy) the wound bed was free of necrosis, pus and slough (**Figure 3**). An alginate (Kaltostat, ConvaTec) was used after this. The wound eventually healed and was fully closed four months after starting larval therapy. In total, 280 maggots were used.

Discussion

Breast-sparing surgery generally comprises removal of the tumour and ipsilateral sentinel lymph node removal. Standard radiotherapy and, depending on pathological examination, chemotherapy are given. Adjuvant chemotherapy does not produce significantly more wound infection.¹²⁷ Infection rates after breast-sparing surgery are between 10–18%, but axillary clearance seems to be a risk factor for infection.¹²¹

In our hospital the standard larvae application method is ‘free-range’ — the maggots are applied directly onto the wound. However, a BioBag is used as indicated by patient preference, and for difficult to-access wounds and uncontrollable pain. In the BioBag, live maggots are enclosed between two 0.5mm layers of polyvinyl alcohol hydrosponge, which are heat sealed over a small cube of spacer material to form a bag.¹⁰³ Maggot migration is reduced, as is pain sensation.¹⁰² Application is simple and acceptance of live maggots is improved.¹²⁸ The bag containing the maggots is placed inside the wound and covered with a non-sterile nylon net which is taped in place. Wet gauze is applied over the net and covered with a light bandage.

Conclusion

Infection after breast conserving surgery is not uncommon. If the infection does not respond to standard surgical and antibiotic care, maggot therapy seems to be a treatment of last resort. To lower the risk of escaped maggots and increase patient-acceptance, we recommend the use of contained maggots in this specific type of wounds.

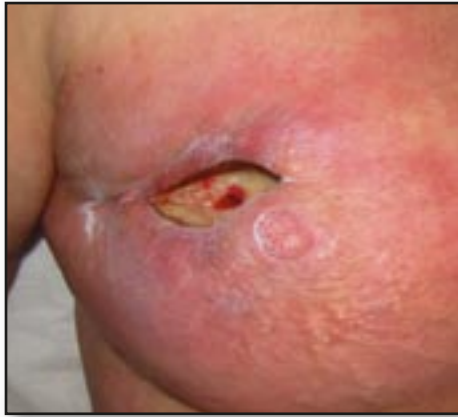

Figure 1: The wound before larval debridement therapy.

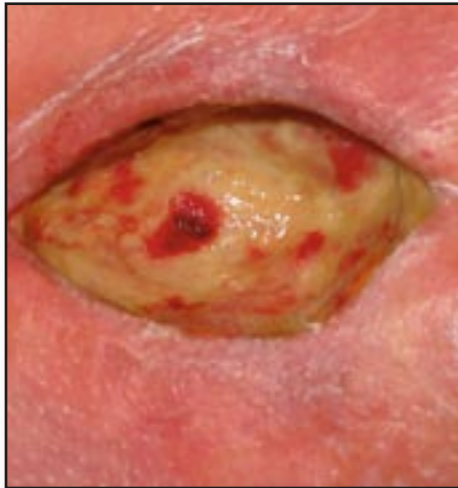

Figure 2: Yellow slough covering the base of the wound.

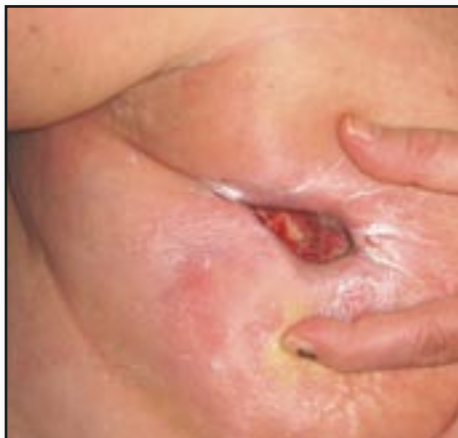

Figure 3: After three applications of MDT, the wound is clean and granulating.

5C MDT in Necrotizing fascitis

Based on the following article:

Wounds

P. Steenvoorde¹, C.E. Jacobi², Chun Yu Wong¹, G.N. Jukema¹

From the Department of Surgery, section Traumatology¹ and Department of Medical Decision Making² Leiden University Medical Center, the Netherlands.

Maggot debridement therapy in necrotizing fasciitis reduces the number of surgical debridements.

Report on 15 treated patients. Wounds 2007; 19(3): 73-78.

Journal of Woundcare

A.L. Rozeboom¹, P. Steenvoorde², H.H. Hartgrink¹, G.N. Jukema²

Department of Surgery¹ and Traumatology², Leiden University Medical Centre, Leiden, The Netherlands².

Necrotizing fasciitis following a simple pelvic fracture: case report and literature review. J Wound Care 2006; 15(3):117-120.

Introduction

Necrotizing fasciitis is a rare, but potential lethal, bacterial infection of the fascial and subcutaneous tissues. The aetiology is not yet fully understood. Patients, however, often have a prior history of some sort of (trivial) trauma, like insect bite, scratch or abrasion.¹²⁹ Risk factors are associated with immunosuppression, such as advanced age, chronic renal failure, peripheral vascular disease, diabetes mellitus, and drug misuse.¹³⁰ Mortality rates of this condition remain high, ranging from 6-76%.¹³¹ Early recognition and improved supportive measures lower mortality rates.¹³² Bacterial cultures may show a wide variety of organisms¹³³, but *Group A Streptococcus* (*Streptococcus Pyogenus*) is the causative agent in up to 71% of all human cases.¹³⁴⁻¹³⁵ *Streptococcus Pyogenus* is a Gram-positive, nonmotile, nonsporeforming coccus that occurs in chains or in pairs of cells. The treatment of choice, after the diagnosis necrotizing fasciitis has been made, is urgent radical surgical debridement in combination with broad-spectrum antibiotic therapy.¹³⁶ In most cases, repeated debridements are needed.

Maggot Debridement Therapy (MDT) has been proven to be very effective in the treatment of gram-positive bacterial infections^{78;83;137-138}, and therefore necrotizing fasciitis seems to be a logical indication for MDT. In this study, we report on the results of 15 patients, with necrotizing fasciitis treated with surgical debridement, antibiotic therapy in combination with MDT, in the period from November 2001 until November 2005. To illustrate, two patients will be presented in detail. Patient- and treatment characteristics of all treated patients will be presented and discussed. These characteristics were evaluated in order to provide insight into optimal MDT strategies for this condition.

Case 6 (Table 1)

A 79-year-old woman presented to our emergency department with a stable closed fracture of the left superior and inferior pubic ramus after a fall. Previous medical history included resection of the bladder, uterus and ovaries, and creation of a Bricker deviation (ureter-ileo-cutaneostomy) as a result of bladder cancer 23 years previously. The patient was admitted to the hospital and discharged three days after mobilisation. The fracture needed no special care, and full weight-bearing was allowed. Four days after discharge she returned to the hospital with a red, tender, swollen, left upper leg. She was severely

confused. On admission her vital signs were: Temperature: 35.6°C, Blood pressure: 115/80mmHg, Pulse rate: 95 beats per minute, Leucocytes: 17.5 x 10⁹/l (normal 4.5–10.0 x 10⁹/l) and C-reactive protein: 310mg/l (normal 0–20mg/l). An X-ray of the leg (**Figure 1**) showed free air in the subcutaneous tissue, which is indicative of a gasproducing bacterial infection. In theatre severe infection of the adductor muscles was found, and wide excision of necrosis, pus and a non-viable muscle fascia was performed. Initial Gram-staining of the necrotic tissue revealed Gram-negative and Gram-positive rods and Gram-negative and Gram-positive cocci, suggesting an abdominal focus. Indeed, the abdomen was rigid and distended without apparent peritonitis; computed tomography (**Figure 2**) showed fluid collection in the lower pelvis and free intraperitoneal air, indicating intestinal perforation. There seemed to be a connection between the fluid collection in the abdomen and the upper left leg. Further surgery revealed a perforation of the small bowel (**Figure 3**) in the lower pelvis near the fracture. A small segment of ileum was removed, and a side-to-side anastomosis performed. It was apparent that the perforation of the small bowel was related to the fracture site, where a sharp fracture line could be felt. To prevent a recurrence, a piece of vascularised omentum (fat) was sutured on the sharp edges of the fracture. To the medial side of the lacuna vasorum in the groin, we observed a false route where abdominal pus tracked to the upper leg. This was debrided, and a second debridement of the upper leg wound was undertaken. The femoral artery lay unprotected in the wound (**Figure 4**), extending from the groin to the knee. The wound was treated with local gentamicin beads and several suction drains. Definitive culture grew *Enterococcus faecalis*, *Hafnia alvei*, *Klebsiella oxytoca*, *Clostridium perfringens*, *Proteus mirabilis* and *Prevotella* species, for which the patient received meropenem intravenously for two weeks. Three days after the first operation, the gentamicin beads and drains were removed. TNP therapy (Vacuum Assisted Closure [VAC], KCI, San Antonio, USA) was applied the following day (**Figure 5**). Polyvinylalcohol foam (Versa Foam, KCI) covered the base of the wound and the exposed vessels, and was changed once in six days. Continuous pressure of 125mmHg was applied. After six days of TNP therapy, MDT was instigated because only the proximal part of the wound had improved; the distal wound still harboured large quantities of pus and necrosis. Thirteen polyvinylalcohol-biobags (Vitapad, Polymedics, Peer, Belgium), each containing 10 maggots, were placed in the wound at the same time (**Figure 6**). After eight days of MDT the wound had improved significantly, so VAC Instill Therapy (KCI) was applied. This dual system provides TNP and delivers controlled amounts of topical solutions to the wound, in this case rinsing the foam three times per hour with an antiseptic agent: polyhexamethylbiguanid combined with polyethylene glycol in Ringer's solution (Lavasept 0.2% solution, Fresenius, Bad Homburg, Germany).^{139;140} After two sessions (in total six days) the wound had improved considerably, and could be surgically closed over suction drains. Two weeks after the secondary closure the wound showed signs of healing and the patient was sent to a rehabilitation centre for further convalescence. The wound healed fully (**Figure 7**).

Case 8 (Table 1)

A 46-year old male with no relevant medical history, besides an appendectomy and a perianal-fistula more than 20 years before current presentation, was referred to our hospital with a Fournier's gangrene, after first he was examined on the emergency department of the referring hospital. The patient had a history of smoking and used about 36–56 grams of alcohol daily (3–4 units). The patient presented with a red and tender right scrotum, which, in retrospect, had been present for seven days. He had

been treated, by his general practitioner, with oral Ciprofloxacin® in the last 4 days, for a presumed infected sebaceous gland in the right groin. The patient was, after broad-spectrum antibiotic therapy with *netilmycin*, *amoxicyllin* and *metronidazol*, taken directly to theatre. An extensive fasciitis was found to be present on (predominantly) the right side of the abdomen, scrotum and perineum. A large part of the abdominal skin (including abdominal fascia) and scrotum had to be excised (**Figure 8**). Initial gram-staining showed a mixed culture. Definitive cultures showed *Bacteroides species*, *Diphtheroids* and a *Enterococcus Faecalis*. In the following 10 days, 6 surgical debridements were performed. Because sepsis persisted and the wound did not show any signs of healing, it was decided to perform MDT. Sterile maggots of the *Lucilia Sericata* were placed in biobags (containing an average of 20-30 maggots per bag) on the wound (**Figure 9**). The patient was treated with sterile maggots of the *Lucilia Sericata*, for a period of 19 days. In total, 1200 maggots were applied. The wound clearly showed signs of granulation, with being able to secondary close the wound partially and perform a mesh graft on the rest of the wound, only 3 days after stopping of MDT and 32 days after the initial presentation to our hospital. Post-operative course was uncomplicated following this last operation. The patient could be discharged from the hospital uneventfully. The patient returned to his work, and remained in a good condition now more than three years after the last operation (**Figure 10**).

Methods

Patients presented in our hospital with necrotizing fasciitis were treated with a combination of surgical debridement, antibiotic therapy and MDT. Patient- and treatment characteristics were, retrospectively, recorded from the patients' charts. Indications for MDT were necrosis and slough. All MDT-applications were discontinued when the wounds were 100% red and full of granulation tissue. The decision to discontinue the therapy was a clinical one, and was made by the last author in all patients. In an earlier study on patients with MDT, we have shown that leucocyte count were significantly lowered on the stopday of MDT compared to the startday of MDT.¹⁴¹ In this study all maggot applications were performed with the contained technique, using biobags.

In the Biobag-technique (Vitapad®, Polymedics Bioproducts, B.V.B.A. Peer, Belgium), larvae are enclosed between two 0.5-mm-thin layers of polyvinyl alcohol hydrosponge, which are heat sealed over a small cube of spacer material to form a bag.¹⁰³ The bag containing the maggots is placed inside the wound. A net is placed over the bag and taped to an adhesive on the wound edges. Over the net, wet gauze and a light bandage are wrapped. Catheters were placed inside the bandages, in order to wet the gauze 3-times daily with normal saline solution (0.9%); to prevent maggot's death by dehydration. Every three to four days new contained maggots were placed on the wound until thorough debridement was reached. Every day the gauze was changed.

Possible differences in patient- and treatment characteristics and outcome were statistically tested using SPSS 12.0.1 for Windows (SPSS, Chicago, IL, USA) and evaluated. For analysis, we did split the patients into 2 groups by the median number of days of starting MDT after diagnosis of the necrotizing fasciitis.

Results

From November 2001 until December 2005, a total of 15 patients with necrotizing fasciitis were treated in our hospital with a combination of surgical debridement, antibiotic therapy and MDT (**Table 1**). After diagnosis, all patients received broad-

spectrum antibiotic therapy, which was changed according to the antibiogram.

All patients were treated in theatre with a surgical debridement, after a clinical diagnosis of necrotizing fasciitis. There were 10 males (67%) and 5 females treated (**Table 2**). Their age ranged from 18-79 year, with an average of 51 years. The necrotizing fasciitis was located in the groin area (N=6; 40%), on the upper leg (N=3; 20%), on the arm (N=3; 20%), on the abdomen (N=2; 13%) and in the head and neck region (N=1; 7%). Three patients were diagnosed with Fournier's gangrene (20%). Some patients suffered from conditions that are known to influence necrotizing fasciitis. The most important were cancer (N=4), diabetes mellitus (N=3) and trauma (N=3).

In total, the patients needed 43 surgical debridements in theatre (average 2.9 per patient, range 1-6). In three patients one of the surgical debridements was combined with a laparotomy; in two cases a resection of a part of the jejunum was performed in one case a colostomy was created. In 5 of the 15 patients, *Streptococcus Pyogenus* was the sole causative agent, in 2 patients *Streptococcus Pyogenus* was found in the initial culture combined with another causative agent. Therefore, in almost half of the patients (N=7; 46%) *Streptococcus Pyogenus* was cultured. Three patients did not have to be treated at the ICU. The average number of days at the ICU was 15 days, with a median of 4 days (range 0-135). The total hospital stay ranged from 3 to 135 days (mean 44 days; median 36 days). Two patients died (13%). A 58-year old male patient, with necrotizing fasciitis at the upper leg unfortunately died during MDT of cardiogenic shock in combination with a pneumonia. His death was influenced by his co-morbidity. Another male, 56 years old, with necrotizing fasciitis at the abdomen, right scrotum and upper leg also died, because of extensive liver metastasis of a primary urothelialcell carcinoma. His wound showed signs of granulation and was scheduled for secondary closure, but the condition of the patient deteriorated leading to his death.

For the treatment of all 15 patients, a total of 10160 maggots were used (average 680 per patient; range 90-2000). The maggots were applied in 679 bags; indicating an average of 45 bags per patient (range 9-100 bags). The MDT period was on average 17 days (range 3-38 days). We split the patients into an early treated group (within 9 days after diagnosis; N=8) and a late treated group (more than 9 days after diagnosis; N=7), as the median number of days of MDT start after diagnosis was 9 days. This in order to gain insight if early application of maggots in necrotizing fasciitis might improve patient prognosis. Between the early and late-treated group there were no statistical significant differences in outcome, although it seemed that the early treated group had a shorter ICU stay (4 vs. 29 days; $P=0.213$) and a shorter total hospital stay (30 versus 59 days; $P=0.094$). The number of surgical debridements was statistically significantly lower in the patients where maggots were applied within 9 days after diagnosis (1.8 versus 4.1 surgical debridement; $P=0.001$). We could not show a statistical significant difference in other treatment characteristics, i.e. the number of maggots applied, the total MDT treatment time, and duration to wound closure, between the early and late-treated group. This lack of statistical significance, mostly due to small sample size, does not mean that these results do not have any clinical relevance.

In all patients, except the two patients who died, the wounds eventually healed. Of the 13 healed patients, two patients (15%) were treated with mesh graft and secondary closure, 6 patients with secondary closure (46%) and five patients with mesh graft only (39%). The average time until closure of the wound was performed was 12 days (range 0-39 days). Of all secondary closures and mesh grafts there were no failures. Secondary closure was performed on average after 10 days (range 0-21 days) and mesh graft at 19 days (range 0-39 days) after the end of MDT.

Discussion

In this report, 15 patients with necrotizing fasciitis are described, in whom the treatment consisted not only of surgical debridement and antibiotic therapy, but also of treatment with sterile maggots. We showed that this potentially lethal condition was, in most cases, successfully treated with this technique. The first description of necrotizing fasciitis in English literature was by the Confederate Army surgeon Joseph Jones in 1871, which he named 'hospital gangrene'.¹⁴² Hippocrates however, was the first to give a description of the disease.¹⁴³ Meleney described an outbreak in Beijing in 1924¹⁴⁴; it was not until 1952 when Wilson called it necrotizing fasciitis.¹⁴⁵ Other terms historically used include necrotizing erysipelas, haemolytic streptococcal gangrene, non-clostridial cellulites, non-clostridial gas gangrene, synergistic necrotizing cellulites, bacterial synergistic gangrene, necrotizing cellulites and gangrenous erysipelas.¹⁴⁶ Today the preferred term is necrotizing fasciitis.¹³¹ Necrotizing fasciitis can affect any part of the body, but the extremities, the perineum and the truncal areas are the most commonly involved.¹³² In this study most patients had a necrotizing fasciitis of the groin region (40%); the extremities were affected in 40% of the cases. Alfred Jean Fournier described necrotizing fasciitis of the perineum and scrotum, which is now referred to as Fournier's gangrene.¹⁴⁷ Fournier's gangrene predominantly occurs in the male population in a ratio of 1:10. Up to 2000, 1726 cases have been described in literature.¹⁴⁸ Fournier's gangrene is mostly due to infection from local skin, urinary tract of colorectal region.¹⁴⁸ Mortality rates for necrotizing fasciitis reported in English literature range from 6-76%; mortality rates are significantly increased if operative debridement is delayed.¹³¹ In our study two patients (13%) died, one of progressive cancer metastasis and the other due to co-morbidity. Failure to recognize and diagnose fasciitis probably contributes to the high mortality rate.¹⁴⁹ We believe in our patients, mortality was not related to late diagnosis, nor was it due to postponed surgical debridement. Diagnosing necrotizing fasciitis is not simple. Pathognomonic for the disease are crepitus (present in 37% of cases) and soft tissue air on plain radiograph (57% of cases).¹³⁰ However, diagnosis remains a clinical one; severe pain disproportionate to local findings in association with systemic toxicity should raise the suspicion.¹³²

In modern times, MDT has proven to be a valuable treatment option for various indications. In 2000, Wollina et al. described indications for MDT; fasciitis necroticans was not separately mentioned.

In-vitro and in-vivo investigations have shown that sterile maggots (larvae of *Lucilia sericata*) are especially capable in the treatment of infected wounds with gram-positive bacteria. Necrotizing fasciitis, which is mainly caused by gram-positive bacteria, therefore seems to be a perfect indication for MDT.^{78;83;137;138} The treatment of choice after the diagnosis necrotizing fasciitis has been made, is urgent radical surgical debridement in combination with broad-spectrum antibiotic therapy.¹³⁶ In most cases, repeated debridements are needed. There have been reports of necrotizing fasciitis treated with maggots; but only in the form of case-reports. In recent literature, successful debridement with MDT of fasciitis of head and neck¹²⁴ and Fournier's gangrene¹⁵⁰ has been described by others as well. In literature it's debated that MDT is contraindicated in cases of rapidly advancing infections (like necrotizing fasciitis).¹⁵¹⁻¹⁵² We disagree, although we would like to stress, that we believe the first debridement in case of necrotizing fasciitis should always be surgical. Only after administration of broad-spectrum antibiotic therapy and surgical debridement, maggots may be placed on the wound, as an additional treatment method, not as the only one. After a few day's when the results of bacterial cultures of the

wound are present, antibiotic treatment can be adjusted to a smaller spectrum if needed. In this patient series, we have shown that relatively early application of maggots reduced the number of performed surgical debridements. In the early treated group the number of surgical debridements was considerably lower compared to the late treated group (1.8 versus 4.1; $P=0.001$). This means that the use of maggots reduced the necessity to go back to theatre and perform a surgical debridement. We would like to stress that MDT is not the only wound treatment available for necrotizing fasciitis, after adequate debridement and disinfection others treatments are sometime necessary before wound closure can be achieved. Vacuum assisted closure (VAC®) is a very potent wound therapy to stimulate further granulation tissue. In necrotizing fasciitis VAC has proven its value.¹⁵³⁻¹⁵⁵

We believe that any reduction in surgical debridement could, eventually, lower the high mortality rates associated with necrotizing fasciitis. Furthermore we believe cosmetic and functional outcome might be improved, for the extension of surgical procedures is reduced. This is because maggots are able to discriminate more effectively between viable and non-viable tissue, compared to the surgeon's knife. Caution should be taken to conclude definitively that MDT replaces the surgical debridement altogether, which can not be concluded from a retrospective case-series. We believe however that necrotizing fasciitis is such a dreadful disease with a high mortality and morbidity, that any possible reduction in the number of needed surgical debridements in this sick population might improve prognosis for these patients.

Table 1: Necrotizing Fasciitis: Characteristics of Patients treated with Maggot Debridement Therapy.

Nr	Sex	Age (yr)	Region	Underlying condition	Primary culture	Result (days after stopping MDT)
1	F	36	Lower Arm	Trauma	<i>Pseudomonas</i>	MG and SC (0 days)
2	M	62	Elbow/Arm	DM	<i>Streptococcus pyogenus</i>	SC (21 days)
3	F	30	Abdomen	Infected Lumbar Neurostimulator	Mixed culture	SC (2 days)
4	M	50	Head-Neck Thorax	RA (corticosteroid therapy)	<i>Streptococcus pyogenus</i> <i>Pseudomonas</i> <i>Candida albicans</i>	SC (14 days)
5	M	72	Gluteus/Upper Leg	CLI, bladder malignancy	<i>Clostridium septicum</i>	MG (14 days)
6	F	79	Upper leg	Trauma Menigeoma	<i>Enterococcus faecalis</i> , <i>Hafnia alvei</i> , <i>Klebsiella oxytoca</i> , <i>Clostridium perfringens</i> , <i>Proteus mirabilis</i> and <i>Prevotella</i> species	SC (3 days)
7	F	70	Groin	Obese. Incarcerated femoral hernia	Faecal flora	MG (39 days)
8	M	46	Abdomen/Perineum/Scrotum	-	<i>Streptococcus pyogenus</i>	MG + SC (3 days)
9	M	56	Groin and Scrotum	Prostatitis DM	<i>Streptococcus pyogenus</i> <i>Klebsiella oxytoca</i> <i>Pseudo-monas</i>	MG (0 days)
10	M	54	Scrotum	Surgery for a Hydrocele	<i>E. Coli</i>	MG (10 days)
11	M	58	Upper Leg	Pneumectomy: Thymoma, Grawitz, Pacemaker, Cardiac-Decompensation	<i>Klebsiella oxytoca</i>	† on day 3
12	M	40	Elbow/Arm	Trauma	<i>Streptococcus pyogenus</i>	SC (0 days)
13	M	30	Upper Leg	DM	<i>Streptococcus pyogenus</i>	SC (20 days)
14	M	56	Abdomen/Right Sacrum/Upper Leg/Perineum	Open abdomen after neobladder for urothelcarcinoma	<i>Stenotrophomonas maltophilia</i> <i>Enterococcus faecalis</i> .	† Died on day 73
15	F	18	Left Groin	-	<i>Streptococcus pyogenus</i>	MG (30 days)

abbreviations:

DM = Diabetes Mellitus, RA = Rheumatoid Arthritis, CLI = chronic limb ischemia, MG = Mesh Graft, SC = Secondary Closure

Patient nr. 8 has been briefly mentioned in a previous report, however in that article the number of biobags has been erroneously reported as 88 (instead of 64).

Table 2: Summary of Patient- and Treatment Characteristics of 15 Patients who presented with Necrotizing Fasciitis and were treated with Maggot Debridement Therapy.

		Total group	Early MDT (≤ 9 days)	Late MDT (> 9 days)	P-value†
Sex	Male (N;%) Female (N;%)	10 (66.7) 5 (33.3)	6 (75.0) 2 (25.0)	4 (57.1) 3 (42.9)	
Age	Mean (SD)	50.5 (17.2)	51.1 (20.9)	49.7 (13.5)	
MDT start (days after diagnosis)	Mean (SD)	9.4 (11.6)	2.3 (3.0)	17.6 (12.6)	‡
Number of Surgical Debridements	Mean (SD)	2.9 (1.6)	1.8 (0.9)	4.1 (1.3)	0.001
Number of maggots	Mean (SD)	713.3 (536.1)	603.8 (581.2)	838.6 (492.2)	
Number of bags (days)	Mean (SD)	45.3 (25.9)	41.9 (27.3)	49.1 (25.8)	
Duration of MDT	Mean (SD)	16.9 (8.9)	16.1 (10.8)	17.7 (7.0)	
ICU stay (days)	Mean (SD)	15.4 (34.0)	3.6 (3.3)	28.9 (47.8)	
Hospital stay (days)	Mean (SD)	43.5 (33.4)	30.0 (22.9)	59.0 (38.3)	0.094
Result	Mesh Graft Sec. Closure MG+SC Granulation Death*	4 (30.8) 6 (46.2) 2 (15.4) 1 (7.7) 2	1 (14.3) 5 (71.4) 0 (0.0) 1 (14.3) 1	3 (50.0) 1 (16.7) 2 (33.3) 0 (0.0) 1	
Time to result (after stopping MDT)	Mean (SD)	15.5 (19.9)	13.1 (10.5)	18.1 (27.9)	

* Death of these patients was not due to MDT.

† As the patient group consisted of so little patients, only P-values < 0.200 are presented.

‡ As the patients were split for this variable, the variable was, of course, statistically significantly different between the groups (P=0.005). **Figures**

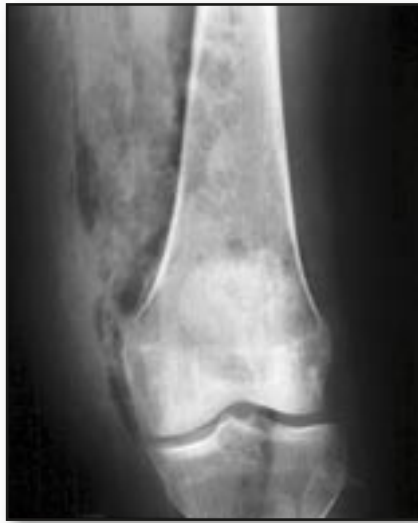

Figure 1: (patient 6). X-ray of the distal left femur showing air in the soft tissues, which is suggestive of necrotising fasciitis.

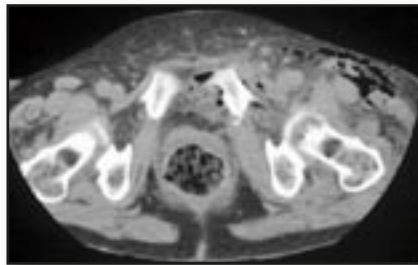


Figure 2: (patient 6). CT scan of the abdomen showing fluid and free intraperitoneal air near the fracture, which is suggestive of a gastrointestinal bowel perforation.

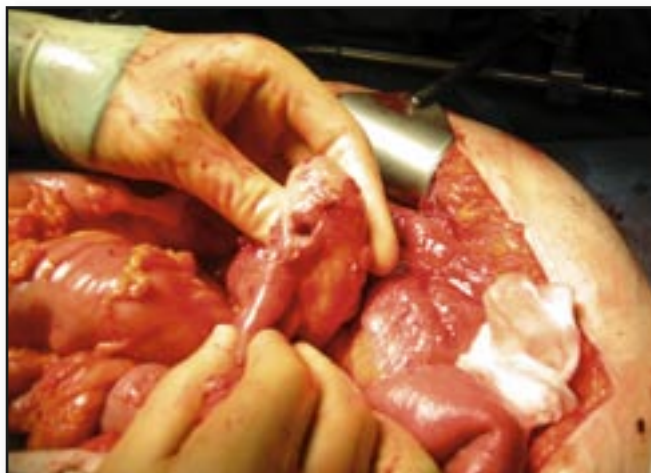

Figure 3: (patient 6). The perforation in the small bowel causing the necrotising fasciitis.

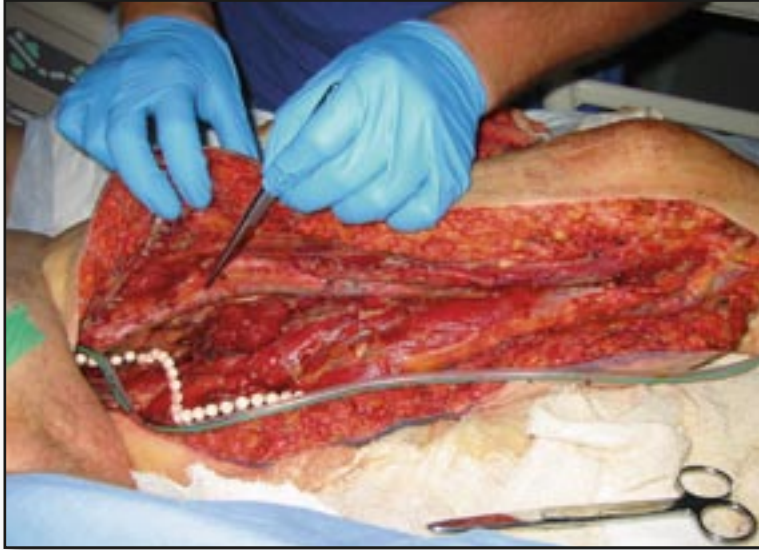

Figure 4: (patient 6). After debridement the wound was left open. Gentamicin beads and a suction drain were placed near the pubic bone. The exposed femoral artery is shown.

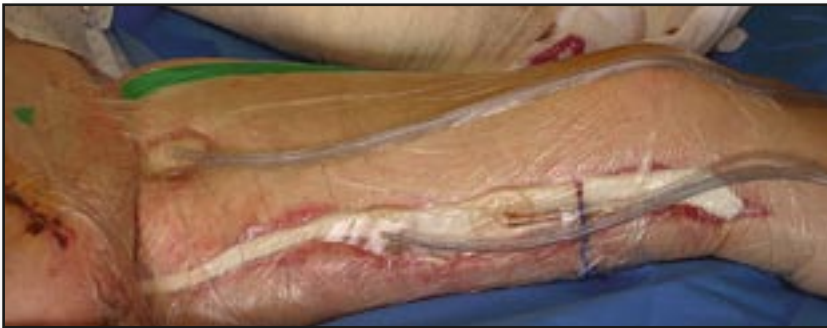

Figure 5: (patient 6). The wound was initially treated with TNP therapy.

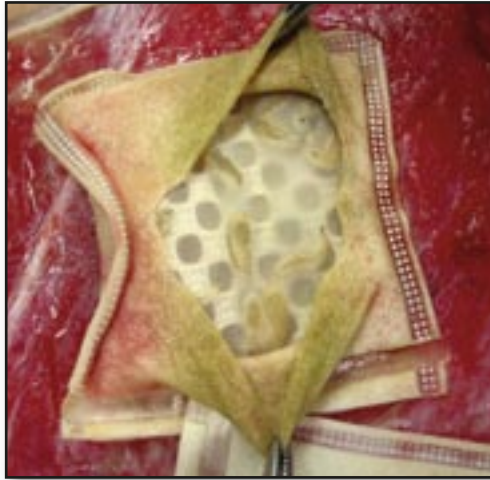

Figure 6: (patient 6). A Vitapad® is placed in the wound.

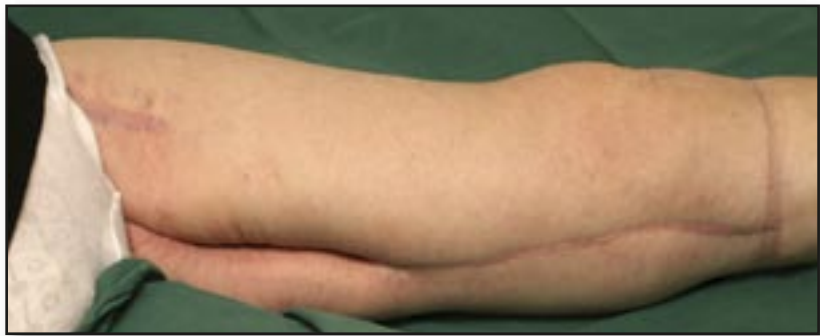

Figure 7: (patient 6). The wound is fully healed.

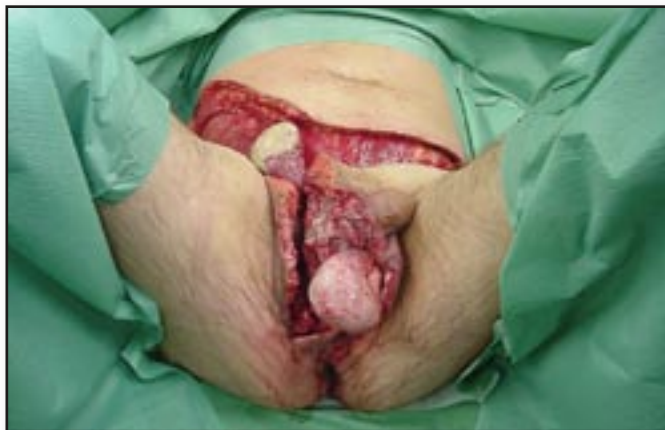

Figure 8: (patient 8). After surgical debridement and fasciectomy of the abdominal fascia, perineum and scrotal fascia.

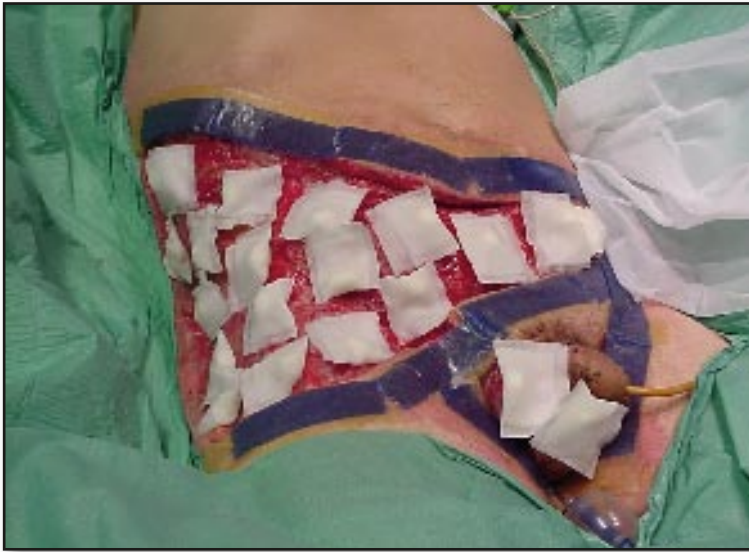

Figure 9: (patient 8). The Vitapads® are placed on the wound. The wound edges are taped with an adhesive tape in order to prevent maggot escapes.

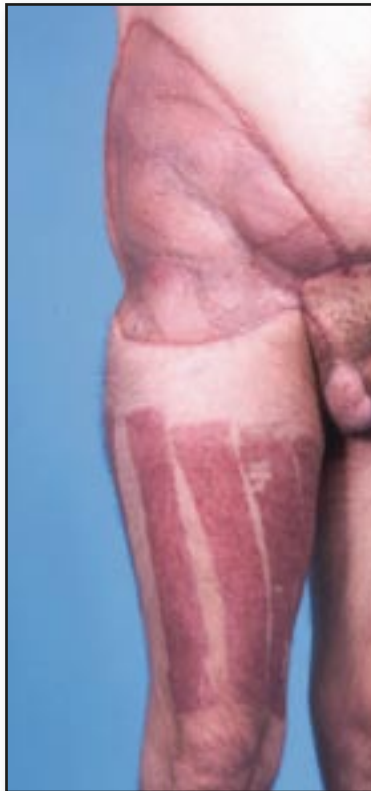

Figure 10: (patient 8). Post-operative end-result after 1 year; the wound fully healed after mesh grafting.

5D MDT in infected amputation wounds

Based on the following article:

Journal of Prosthetics and Orthotics

P. Steenvoorde, J. Oskam

Department of Surgery Rijnland Hospital, Leiderdorp, The Netherlands.

'Modern Wound treatment of infected transtibial amputation: JPO 2006; 18:17-20.

Introduction

One of the most disastrous complications of a transtibial amputation, besides death, is gangrene and opportunistic infection, necessitating a transfemoral amputation. This gives not only a higher mortality rate¹⁵⁶ but also reduced ambulation rates.¹⁵⁷ Wound complications occur in 5% to 22% of lower extremity amputations.¹⁵⁶⁻¹⁵⁸ Conversion rates to transfemoral amputation are estimated to be between 9% and 19%.^{156;158} MDT of infected transtibial amputation has been described before, but not in a large series.¹⁰² Since the first report of vacuum-assisted closure (VAC) therapy in 1997, more than 100 articles on the subject have been published.⁸¹ The technique is simple: a subatmospheric pressure is applied to a wound by means of an open-cell foam in the wound connected with a tube to a vacuum source. The fluid is then collected and removed.¹⁵⁹ The technique removes interstitial fluid and potential harmful inflammatory mediators.¹⁶⁰ Furthermore, it lowers interstitial pressure, thereby promoting the expansion of vessels. There is also a presumed reduction of bacterial load, although the latter is debated.¹⁶

Methods

From August 2002 to December 2004, five patients with infected transtibial wounds were treated with MDT in our hospital (**Table 1**). All applications were performed in our outpatient department, including our admitted patients. We used two application techniques: the contained technique and the free-range technique.

Case 1

A 59-year-old man with no relevant medical history was treated for a painful ingrown toenail with a complete nail resection. This was complicated by severe infection of the hallux, unresponsive to antibiotic treatment. A stenosis of the superficial femoral artery was successfully treated with radiological percutaneous transluminal angioplasty. The condition of the patient suddenly deteriorated, necessitating intensive care admission. He needed several laparotomies for a perforation of his colon, necessitating resection of the left colon and the creation of a colostomy. In the same period, a transtibial amputation was performed. The amputation wound deteriorated, with a severe infection unresponsive to antibiotic treatment (**Figure 1**). We advised the patient to undergo a transfemoral amputation, which the patient refused. He urged us to try maggot debridement therapy. We performed a stump revision, removing the black eschar on removing 1 to 2 cm of the tibia. We started treating the wound with maggots incorporated in a polyvinyl alcohol biobag (**Figure 2**). In this biobag, the maggots can still act as necrophages. The biobag was placed in the wound, which was subsequently covered with a nylon net and attached to the skin through several adhesive layers to prevent the

maggots from escaping and prevent further damage to the skin. The total maggot treatment time was 4 weeks, with two weekly changes. In total, 240 maggots were used. Eventually, the wound closed secondarily, and the patient is now ambulating with a prosthesis.

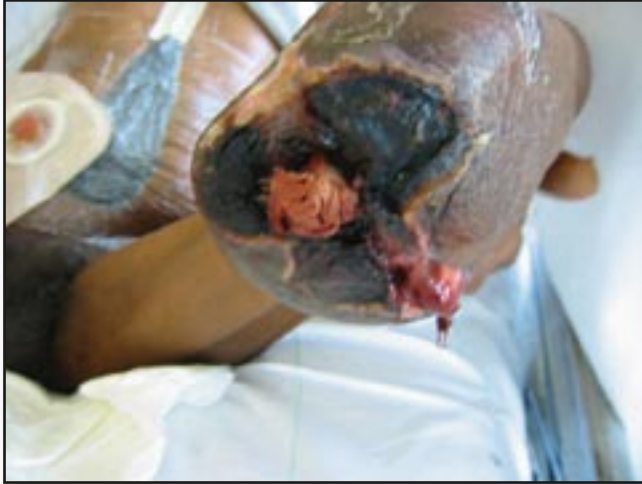

Figure 1: Patient 1. Severely infected transtibial amputation, with necrosis and pus draining on the lateral side. Wet gauze is placed in the marrow of the tibia.

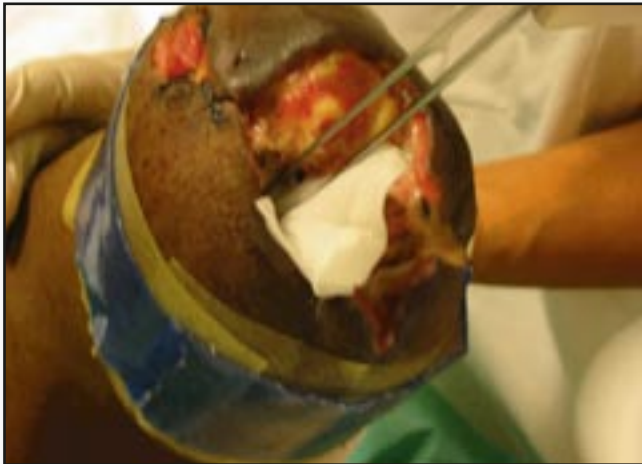

Figure 2: Patient 1. Polyvinyl alcohol bag filled with approximately 20 live maggots is placed in the wound.

Case 2

A 71-year-old man with a history of insulin-dependent diabetes was treated in our hospital for an osteomyelitis of the fourth toe of the left foot. The patient was obese and had a history of hypertension, hypercholesterolemia, and a cerebrovascular accident. Angiography revealed a complete stop of the popliteal artery just proximal to the trifurcation. A femoral- pedal bypass seemed feasible, but the infection progressed and we feared a possible infection of the distal anastomosis. Adequate debridement had to be performed first. The toe was amputated. Despite adequate debridement and appropriate antibiotic therapy, a plantar abscess developed, necessitating a transtibial amputation. Unfortunately, this wound did not heal. There was a wound dehiscence with necrosis and pus, but muscles seemed viable. At this time, MDT was started. The maggots were put freely on the wound, covered only by a net, to prevent the maggots escaping. The patient was treated in the outpatient department. After 1 week of MDT (200 maggots used), the wound was fully clean and VAC was started (**Figure 3**). VAC was also performed in the outpatient department, and after 2 weeks, the wound (**Figure 4**) could be secondarily closed. After removal of the stitches, the patient started ambulating and is now ambulating well with a prosthesis.

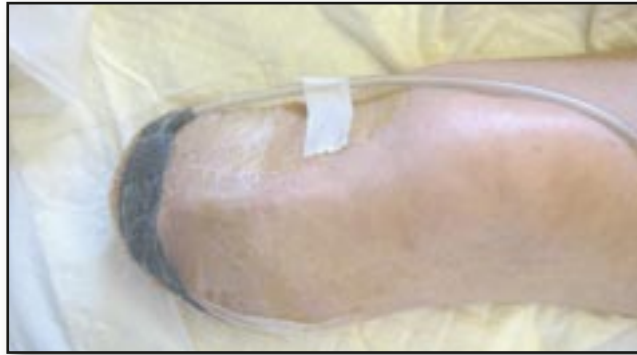

Figure 3: Patient 2. Wound treated with vacuum-assisted closure therapy.

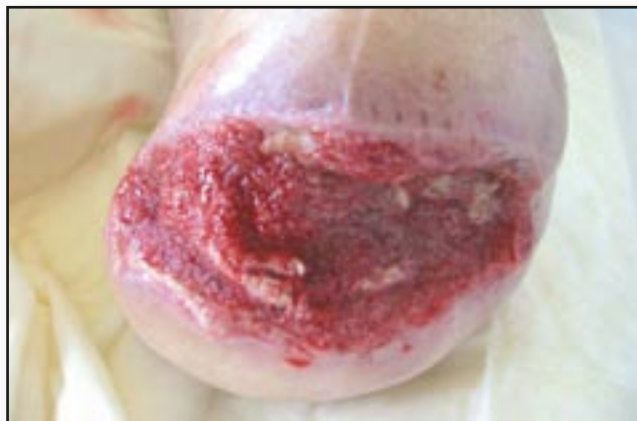

Figure 4: Patient 3. Granulating wound after vacuum-assisted closure therapy. The wound was subsequently successfully secondarily closed.

Results

In total there were five patients treated (see **Table 1** for characteristics) with maggots in order to prevent conversion of the amputation level. All patients (3 male, 2 female; mean age, 71 years; range, 59 to 85 years) had vascular insufficiency. None of the patients was on dialysis. Two patients were diabetic. Four patients had a severe infection of the transtibial amputation, with visible bone. Two patients were treated while admitted, two while in a nursing home, and one patient was treated ambulatory. One patient was treated with the biobag technique. Eventually, four wounds healed completely; one needed conversion to a transfemoral amputation. Three patients are ambulating now with a prostheses. In this article we have described five patients with severe infection of transtibial amputations in which the use of MDT and VAC resulted in fewer conversions to transfemoral amputation, with positive effects on mortality and morbidity.

Table 1: Characteristics of patients with infected transtibial amputation treated with maggots

	Sex	Age	DM	Osteomyelitis	Wound duration before MDT (mo)	Setting	No. of Maggot Applications	No. of maggots used	Technique	Outcome
1	M	59	-	+	0.5	Hospital	8	240	Biobag	Ambulating with a prosthesis
2	M	71	+	+	1	Outpatient	2	200	Loose	Ambulating with a prosthesis
3	F	74	+	+	1	Nursing home	3	200	Loose	Ambulating with a prosthesis
4	M	64	-	+	6	Hospital	5	500	Loose	Above knee amputation, wheelchair
5	F	85	-	-	3	Nursing home	3	90	Loose	Wheelchair, wound healed.

5E MDT in palliative medicine

Based on the following article:

American Journal of Hospice & Palliative Medicine

P. Steenvoorde¹, L. P. van Doorn¹, C.E. Jacobi², J. Oskam¹

Department of Surgery Rijnland Hospital¹, Leiderdorp, The Netherlands.

And the Department of Medical Decision Making², Leiden University Medical Center, The Netherlands.

Maggot Debridement Therapy in the palliative setting? Accepted for publication Am J Hosp Palliat Care 2007; 24(4): 308-10.

Introduction

Success-rates of MDT in literature differ but range from 70-80%.^{55;89;90;162} Patient selection seems to be a critical factor in predicting success. In previous studies we have shown that traumatic wounds for example, treated with maggots will heal almost always and wounds with open joints on the other hand, will generally lead to an amputation of the affected joint. Wound healing is clearly impaired in older patients with co-morbidity. It's not difficult to predict that an infected traumatic ulcer which is present for 1 month in a 30 year old patient treated with MDT will heal earlier compared to a three-year old foul smelling wound in an ischemic leg in 93-year old female. In this article we would like to argue that wound closure is not always feasible and is not always the aim of the treatment. Sharp debridement of a necrotic or infected ulcer is not always feasible, for sometimes this is too painful. Admittance and performing sharp debridement in theatre is not always possible due to co-morbidity. Maggot debridement therapy does not need admittance of the patient; it can be performed simply in the outpatient clinic. We argue that infection-removal, pain- or odour reduction could also be defined as a succesful outcome in some patients. We would like to present a typical patient, with a reduced life expectancy in whom the goal of MDT was not closure of the wound but infection control, odour and pain control, and moreover prevention of major amputation. We will also discuss MDT results in patients that died within a year after MDT compared to the group still alive, one year after MDT.

Patient

A 94-year old female presented to our wound clinic with a chronic, non-healing wound, after referral from the dermatology department. Previous history revealed a history of Chronic Obstructive Pulmonary Disease (COPD), atrial fibrillation, cardiac decompensation and the patient had a history of a peptic ulcer. A chronic ulcer on the left lower leg, present more than a year, showed no healing tendency under compression therapy and treatment with an alginate dressing. The patient had received several antibiotics without any result. Wound aetiology was not clear; it presented after a minor trauma. Due to the ulcer, the patient was unable to walk, and came to our clinic with the use of a wheelchair. On physical examination we saw a large, foul smelling, ulcer on the left lower leg. There were no arterial pulsations on the lower leg. Ankle/brachial index was 0.4. Angiography showed a single peroneal artery only, there were multiple stenosis of the popliteal artery. Unfortunately operative and endovascular intervention, was not feasible. The aetiology of the ulcer was not completely clear, for she had psoriatic problems on other places of her body. We concluded there was a psoriatic mixed arterial/venous ulcer. Pathological examination showed no signs of malignancy.

The base of the wound was covered with thick yellow layer (see **Figure 1**). It was decided to remove the necrosis. This was too painful in the outpatient department. As we believed surgical debridement in theatre not to be without serious risks, due to the co-morbidity of the patient, the patient was treated with an alternative form of debridement: Maggot Debridement Therapy (MDT). From our own experience we did not believe MDT alone could completely heal the ulcer. With the MDT we hoped to remove the infection and hopefully, reduce pain problems. Our secondary goals were to prevent a below knee-amputation which the patient and family feared. We clearly observed a full debridement after three applications (see **Figure 2**), and despite all negative factors influencing wound healing we even observed some healing tendency (see **Figure 3**). Most importantly a reduction in pain, as stated by the patient, and odour, as stated by the patient, her family, and the treating physician, was achieved. The patient eventually died within a year; her death was unrelated to the ischemic ulcer. She died with a stable ulcer, without any pain and without any signs of infection.

Results

From August 2002 until the first of January 2006, a total of 101 patients presenting with 117 wounds were treated in our hospital.¹⁶² On the first of January 2006, 77 patients (76%) were still alive. Patients that died within the study period significantly more often were (like the patient presented in this paper) of ASA III or IV (91.7% vs. 64.5%, $p=0.007$).

They also more often had diabetes mellitus (70.8% vs. 36.8%, $p=0.004$). (**Table 1**). There was no significant difference regarding age, sex, quetelet index, outcome of the wound and smoking. More importantly outcome did not differ between the two groups. In other words even if the wound was completely closed, or there was no effect at all, mortality remained the same.

Discussion

According to Church's outcome classification of MDT⁸⁸, the effect of MDT in the present case would have been classified as *Significantly beneficial* (long-term considerable pain relief, without full wound healing) or at least *Partially beneficial* (no full wound healing, but there has been some improvement in the patient's clinical state, with reduction of specific symptoms such as pain, odour, and wound secretion). We believe for our patient, this was the best possible outcome. We used MDT in order to remove infection, reduce odour, reduce pain and eventually prevent a below knee amputation. This succeeded; the pain was diminished, the odour reduced and the wound showed signs of healing. Still the patient died. In maggot literature, as with other wound treatments, outcome is recorded as succesful or as failed; Healed or non-healed. This wound did not heal, therefore in some outcome-measures this would be regarded as a failed treatment.

We believe that MDT should not only be instituted in order to close wounds, but it could also be applied in patients in whom the wounds will never heal, no matter what therapy is instituted. It could be used to rapidly clean a wound, to remove infection, after which for example smell is reduced, enabling the patient to socialize more. Unfortunately more than 20% of our patients died within the study-period. We believe this reflects our idea and our policy to use MDT for different indications; not only in the curation of wounds but also in the palliative setting in the last years of a patients life, like was the case in the patient presented in detail.

Table 1

	Deceased (n=24)	Alive (n=77)	P
ASA III/IV	91.7%	64.5%	0.007 *
Diabetes	70.8%	36.8%	0.004 *
Age at presentation	75.4 year	69.8 year	0.098
Vascular patient	66.7%	48.1%	0.086
Number of MDT-applications	3.2	2.2	0.008 *
Outcome beneficial	61% (14/23)	71.4% (55/77)	P=0.337

* significant ($p < 0.05$)

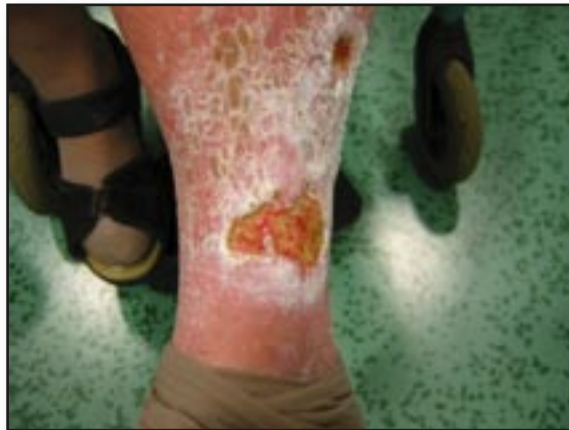

Figure 1: A 93-year old female with an active psoriasis presented with a mixed arterial-venous ulcer that had been present for 6 months.

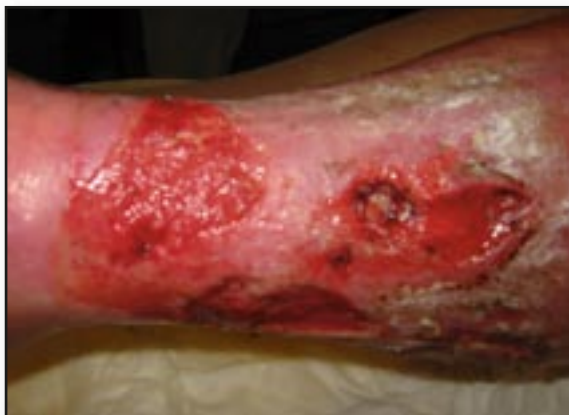

Figure 2: After 3 applications of maggots the wound is clearly fully debrided.

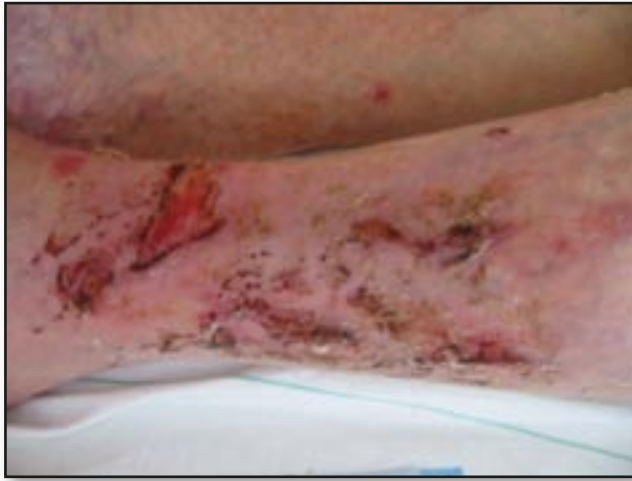

Figure 3: The wounds have a good healing tendency and are reducing in size; more importantly odour and pain are reduced.

