



Universiteit  
Leiden  
The Netherlands

## **Fetoscopic interventions in complicated monochorionic twin pregnancies**

Middeldorp, J.H.

### **Citation**

Middeldorp, J. H. (2007, April 17). *Fetoscopic interventions in complicated monochorionic twin pregnancies*. Department of Obstetrics, Faculty of Medicine, Leiden University Medical Center (LUMC), Leiden University. Retrieved from <https://hdl.handle.net/1887/11952>

Version: Corrected Publisher's Version

License: [Licence agreement concerning inclusion of doctoral thesis in the Institutional Repository of the University of Leiden](#)

Downloaded from: <https://hdl.handle.net/1887/11952>

**Note:** To cite this publication please use the final published version (if applicable).

**Laparoscopically guided uterine  
entry for fetoscopy  
in twin-to-twin transfusion  
syndrome  
with completely anterior placenta:  
a novel technique**

Johanna M Middeldorp  
Enrico Lopriore  
Marieke Sueters  
Frank W Jansen  
Jan Ringers  
Frans JCM Klumper  
Dick Oepkes  
Frank PHA Vandenbussche

*(based on: Fetal Diagnosis and Therapy, in press)*



## **Abstract**

*Objective:* Laser coagulation of anastomotic vessels on the placental surface is the treatment of choice in severe second trimester twin-to-twin transfusion syndrome (TTTS). This procedure is associated with technical difficulties when the placenta is located on the anterior side of the uterus. We describe a novel technique for fetoscopy in TTTS with completely anterior placenta where laparoscopy is used to guide safe percutaneous insertion of the fetoscope through the lateral abdominal wall and the dorsal side of the uterus.

*Methods:* Prospective controlled series of 16 TTTS pregnancies with completely anterior placenta (study group) treated with this novel technique. Studied outcomes were technical result of the procedure and perinatal survival. Outcome in the study group was compared with outcome of 49 TTTS pregnancies treated with conventional percutaneous fetoscopic laser without laparoscopy, 9 of these with partially anterior placenta (control group A) and 40 with lateral or posterior placenta (control group B).

*Results:* In the study group, the procedure-related complication rate was 25% (4/16). In one case uterine entry of the fetoscope from the lateral abdominal wall was not possible due to complex bowel adhesions. In 3 patients, intraamniotic haemorrhage occurred after fetoscopic entry, preventing complete laser coagulation of anastomoses. One of these patients required two units of blood transfusion. The procedure-related complication rate in control group A and B was 22% (2/9) and 5% (2/40), respectively (intraamniotic haemorrhage n =3, severe leakage of amniotic fluid into the peritoneal cavity, n=1). Perinatal survival in the study group, control group A and control group B was 63% (20/32), 78% (14/18) and 70% (56/80), respectively.

*Conclusions:* Combined laparoscopy and fetoscopy is a novel technique that enables safe uterine entry and creates optimal visualisation for laser coagulation of intertwin anastomoses in TTTS pregnancies with completely

*Chapter 5*

anterior placenta. Procedure-related complication rate and perinatal survival rate were similar compared to the conventional percutaneous technique. Procedure-related complications occur more often with partially or completely anterior placenta.

## **Introduction**

Monochorionic twin pregnancies are at risk for developing twin-to-twin transfusion syndrome (TTTS) due to unbalanced intertwin blood-flow through placental vascular anastomoses. TTTS occurs in approximately 15% of monochorionic twin pregnancies during the second trimester.<sup>1</sup> The prognosis for untreated severe second trimester TTTS is poor.<sup>2</sup> Since 1980, serial amniodrainage has been used as a symptomatic therapy. A decade later, a cause-oriented approach for TTTS was developed: fetoscopic laser coagulation of placental vascular anastomoses.<sup>3-5</sup> In a recent randomised trial of severe second trimester TTTS, perinatal survival rates and neurological outcome at six months of age were significantly better after laser treatment compared to amniodrainage.<sup>6</sup>

In patients with placental localisation on the posterior wall of the uterus, percutaneous insertion of the fetoscope for laser coagulation gives perpendicular access to the chorionic plate and the vascular anastomoses on its surface, and is, in experienced hands, a straightforward procedure. An angle of approximately 90 degrees between chorionic plate and fetoscope and laser fibre provides maximal visualisation of the vascular equator and optimal laser effectiveness. An anterior placenta, however, presents a technical challenge, because perpendicular access is not possible. Several authors have claimed that the problem of anterior placentas could be solved either by open uterine access via mini-laparotomy, or by lateral percutaneous entry combined with the use of a curved shaft and flexible fetoscope, with the use of multiple ports, or with lateral view fetoscope and side firing laser.<sup>7-11</sup> These methods, however, still entail a higher risk of transplacental entry, maternal bowel or uterine vessel damage, increased risk of iatrogenic rupture of membranes, or incomplete placental visualisation and diminished laser effectiveness and thus of incomplete laser treatment. We report on a novel minimally invasive technique, developed to enable safe uterine entry and optimal placental visualisation in patients with completely anterior placenta by combining laparoscopy with fetoscopy. Laparoscopy with open entry technique has been shown before to

be a safe procedure in pregnant women.<sup>12;13</sup>

In this study, we describe this new technique and report on the procedure-related complications and on perinatal survival in the first 16 patients with completely anterior placenta treated with combined laparoscopy and fetoscopy. We compared procedure-related complications and perinatal survival in this study group with those of two control groups that underwent fetoscopy without laparoscopy for TTTS: control group A with partially anterior placenta and control group B with lateral or posterior placenta.

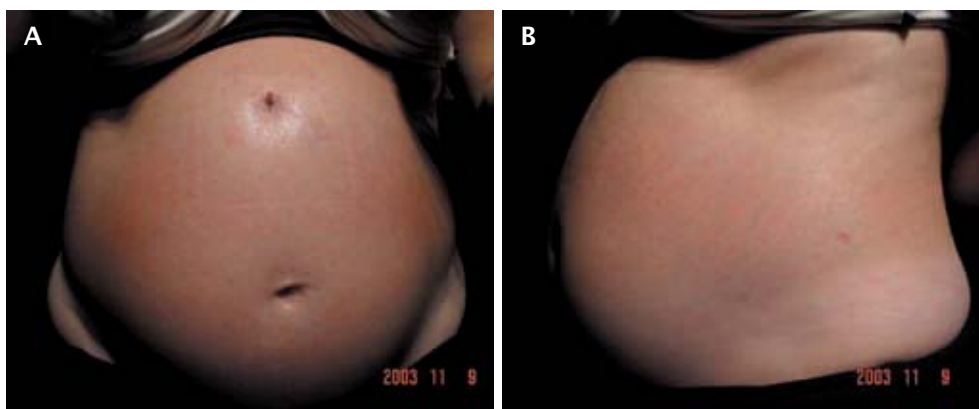
## **Patients**

Our centre is the national referral centre for invasive fetal therapy in the Netherlands. In August 2000, we started our program of fetoscopic laser coagulation of anastomotic vessels for severe TTTS.<sup>14</sup> In September 2003, we performed our first combined open laparoscopy and fetoscopy for completely anterior placenta. Completely anterior placenta was defined as a placenta and stuck twin covering almost the entire ventral uterine wall, thereby excluding the avoidance of transplacental entry, or enhancing the risk of damaging maternal bowel or vessels, or excluding complete visualisation of the vascular equator with percutaneous fetoscopic entry. To evaluate this new technique, we compared the procedure-related complications and the perinatal survival with those of 49 routine laser procedures performed by our team during the same time period. Perinatal survival was assessed until 4 weeks after birth. Inclusion criteria for laser surgery were: monochorionic twin pregnancy, gestational age between 15 and 27 completed weeks, TTTS Quintero stage 1 with severe clinical symptoms of polyhydramnios, or TTTS Quintero stage  $\geq 2$ . Patients in active labour or with a fetus with congenital malformations were excluded. Before fetoscopy, detailed sonographic evaluation was performed to exclude congenital anomalies, to confirm the diagnosis of TTTS, and to determine the Quintero stage. The sonographic investigation included: fetal anatomy and biometry, deepest vertical pocket of amniotic fluid of each fetus, bladder filling, arterial and venous Doppler studies, placental localisation, and localisation of umbilical

cord insertions. Based on the placental localisation, the position of both fetus and the insertion site of the umbilical cords, an estimation was made of the localisation of the vascular equator on the placenta.

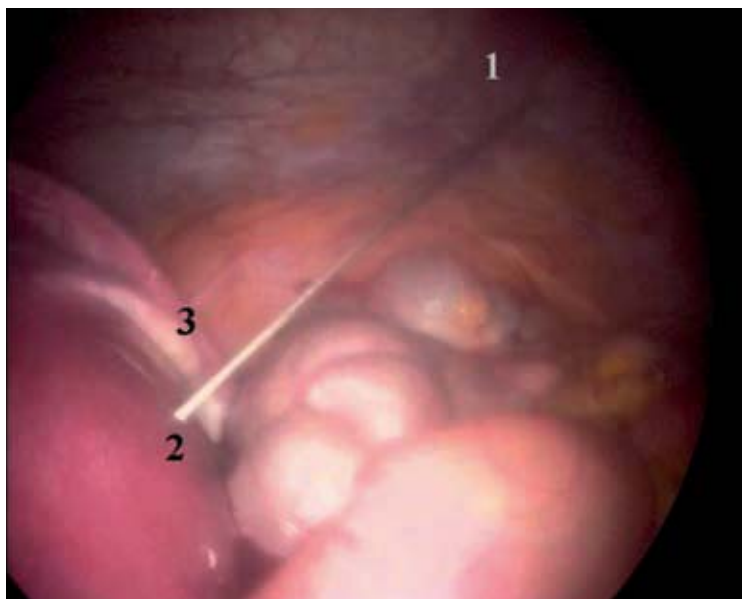
### **Operative technique**

Under general anaesthesia and with the patient in supine position, open laparoscopy was performed according to the technique first described by Hasson.<sup>15</sup> We modified the technique by introducing the Origin balloon trocar (Autosuture®, Tyco Healthcare, Gosport, UK) with blunt tip, after the abdomen had been opened, via a 2 to 3 cm median or paramedian incision. This incision was made 2 cm above the fundus of the uterus (figure 1a). Pneumoperitoneum was established under direct vision of the laparoscope. The intra-abdominal CO<sub>2</sub> insufflation pressure was automatically regulated and maintained at 12-14 mm Hg. After insertion of the laparoscope, the patient was turned to lateral tilt position and stabilised using a desufflatable beanbag. The fetoscopic insertion site was chosen near the mid-axillary line, between the lower ribs and the iliac crest (figure 1b). At this site, an 18-G needle was inserted into the abdominal cavity under laparoscopic vision, away from bowel. In some cases, in order to obtain better visualisation, a second trocar was inserted close to the needle insertion site and the laparoscope was then switched to the second trocar.



**Figure 1a and 1b** Skin incisions made for open laparoscopy (a), and fetoscopic entry (b).

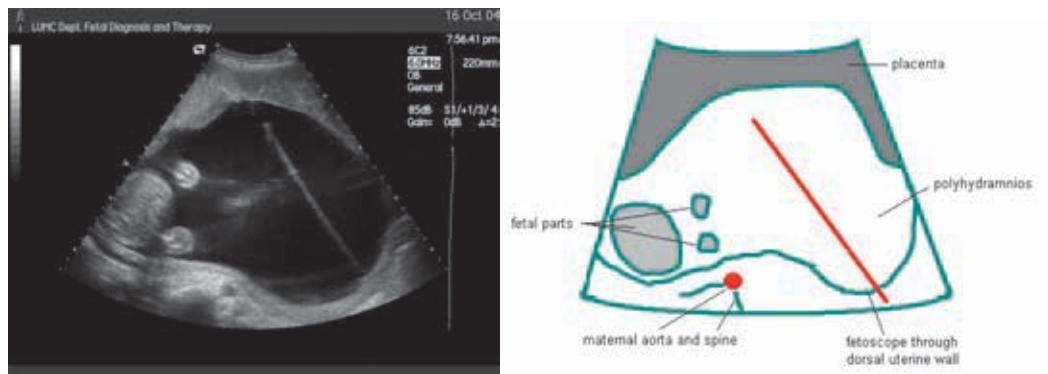




**Figure 2**  
*Laparoscopic view of the needle in the intraperitoneal cavity just after entering the dorsal uterine wall. Open laparoscopy was performed in the right upper quadrant, 3 cm under lower ribs. 1 right dorsolateral abdominal wall, 2 needle insertion at posterior side of uterus, 3 right adnexa.*

Under direct laparoscopic view, the 18-G needle was inserted safely into the posterior uterine wall, away from the large vessels on the lateral side of the uterus (figure 2). Simultaneously, ultrasound was used to guide the needle into the amniotic cavity of the recipient fetus. Then a Seldinger technique was used with a 0.085 inch soft J-tipped guide wire that was introduced through the needle, which was then removed.<sup>7</sup> A 10 F teflon cannula, loaded with a dilator, was advanced over the guide wire (Cook®). When the cannula had entered the amniotic cavity, the guide wire and dilator were removed and the shaft loaded with a 2 mm fetoscope (Storz, Vianen, the Netherlands) and laser fibre (400 µm) (Dornier Medizin Technik, Germering, Germany) was inserted. This procedure was also sonographically guided. For this purpose, the pneumoperitoneum had to be partly released. Figure 3 shows an ultrasound picture with the ultrasound probe at the maternal umbilicus and pushed against the uterus, and the fetoscope entered through the dorsal uterine wall. The fetoscopic laser coagulation then took place following the standard procedure, with the advantage of perpendicular access to and complete visualisation of the placenta.<sup>14</sup>

In the control group an 18-G needle that was inserted percutaneously in the uterine cavity under ultrasound guidance. The same procedure as described



**Figure 3** Transverse sonographic view (transducer at maternal umbilicus) of the uterus with fetoscopic entry site in the dorsal uterine wall.

above was then used for insertion of the fetoscopic shaft. Curved shafts up to 40 degrees and a semi rigid fetoscope were used when indicated. Patients underwent this conventional percutaneous entry procedure under local or loco-regional anaesthesia. In both groups, a prophylactic dose of tocolytics (indomethacin) and antibiotics (amoxicillin/clavulanate) was given routinely.

### Statistics

Differences in gestational age between study and control groups were analysed with one-way analysis of variance. Categorical variables were analysed with Fisher exact test, chi square test, and linear by linear association for trend. A p-value < 0.05 was considered to indicate a statistical significance. Statistical analysis was performed with SPSS version 11.0 (SPSS, Inc., Chicago, Illinois, USA).

### Results

Between September 2003 and December 2005, treatment with fetoscopic laser coagulation of anastomotic vessels was performed in 65 patients. Anterior placenta was detected in 38% (25/65) of patients. In 64% of these (16/25),

the placenta completely covered the anterior uterine wall. These 16 patients underwent the combined open laparoscopy and fetoscopy procedure. Of the 49 patients without completely anterior placenta, 9 (18%) patients had an anterior placenta that only partially covered the anterior uterine wall (control group A), and 40 (82%) patients had lateral or posterior placenta (control group B). Details of the 16 patients in the study group are listed in Table 1. In 2 of the 16 patients, the combined open laparoscopy and fetoscopy was the second procedure for the treatment of TTTS. One patient underwent a prior amniodrainage and in another patient a routine laser procedure had been attempted 9 days earlier, which had to be abandoned after the occurrence of significant intraamniotic haemorrhage at uterine entry. In 4 of the 16 patients, laser coagulation could not be performed. In one patient, uterine entry was not possible despite assistance of the laparoscope, because of complex bowel adhesions along the lateral side of the uterus. Instead, an amniodrainage procedure was performed. In three other patients, severe intraamniotic haemorrhage occurred. Because of impaired visualisation shortly after entry, the procedure was abandoned. One of these patients also suffered from an intraperitoneal bleeding from the uterine wall and received two units of blood transfusion.

In 4 of the 49 patients in the control groups, laser coagulation was not or incompletely achieved. In 3 of these 4 patients (2 in control group A and 1 in control group B) intraamniotic haemorrhage occurred. In the fourth patient (in control group B), no visualisation could be reached, due to rapid leakage of all of the amniotic fluid into the intraperitoneal cavity after a sudden movement of the patient. In two other cases in control group B, recurrence of the syndrome and reversal of the syndrome were diagnosed, respectively. There was no significant difference in procedure-related complication rate between the laparoscopy (study) group and the conventional fetoscopy group (combination of control group A and B) ( $p = 0.094$ ). When comparing the women with anterior placenta (combination of study group and control group A) with the women with posterior placenta (control group B), a significantly higher procedure-related complication rate was found in the anterior placenta group ( $p = 0.047$ ). There was a significant linear-by-linear trend for higher procedure-

**Table 1** Characteristics of 16 cases of laparoscopically assisted fetoscopic intervention for twin-to-twin transfusion syndrome with completely anterior placenta

case number	Quintero stage	GA at intervention	GA at delivery (completed)	survivors 4 weeks after birth	procedure-related complications leading to incomplete treatment
1	II	15	31	2	
2	IV	21	33	2	
3	II	17	37	2	
4	III	20	33	2	
5 <sup>†</sup>	I	24	37	2	
6	I	17	23	0	no intra-uterine access due to bowel adhesions, amniodrainage
7	III	19	29	0	
8	III	24	35	2	
9	II	18	19	0	
10 <sup>‡</sup>	III	26	28	1	
11	III	20	29	1	intraamniotic haemorrhage, laser coagulation not achieved, amniodrainage + cord coagulation
12	III	20	29	2	
13	I	19	20	0	intraamniotic haemorrhage, laser coagulation not achieved, amniodrainage
14	III	15	28	2	intraamniotic haemorrhage, laser coagulation not achieved, intraperitoneal haemorrhage, amniodrainage
15	III	20	22	0	
16	III	16	31	2	

<sup>†</sup> previous amniodrainage at 20 weeks

<sup>‡</sup> previous attempt to percutaneous laser coagulation at 25 weeks

related complication rate towards less favourable placenta localisation ( $p = 0.029$ ).

No significant differences in 0, 1 and 2 survivors and perinatal survival were found between the three groups ( $p = 0.348$ ). Further details on procedure-related complication rate and perinatal survival in study group and control groups are reported in table 2.

**Table 2** Perinatal outcome after laser coagulation of vascular anastomoses in the study group (laparoscopically assisted fetoscopic entry with completely anterior placenta), control group A (percutaneous fetoscopic entry with partial anterior placenta) and control group B (percutaneous fetoscopic entry with lateral or posterior placenta)

	study group N=16	Control group A Partial anterior placenta N=9	Control group B Lateral or posterior placenta N=40
gestational age at intervention <sup>†</sup> -	20 (15-26)	18 (15-26)	20 (15-26)
procedure-related complication - no.(%)	4 (25%)	2 (22%)	2 (5%)
gestational age at birth <sup>†</sup> -	29 (19-37)	31 (15-36)	31 (16-38)
0 survivors <sup>‡</sup> - no.(%)	5 (31%)	2 (22%)	7 (17%)
1 survivor <sup>‡</sup> - no.(%)	2 (13%)	0 (0%)	10 (25%)
2 survivors <sup>‡</sup> - no.(%)	9 (56%)	7 (78%)	23 (58%)
at least 1 survivor <sup>‡</sup> - no.(%)	11 (69%)	7 (78%)	33 (83%)
neonatal death - no.(%)	1/32(3%)	0/18 (0%)	1/80 (1%)
perinatal survival <sup>‡</sup> - no.(%)	20/32 (63%)	14/18 (78%)	56/80 (70%)

<sup>†</sup> median (range) in completed weeks

<sup>‡</sup> 4 weeks after birth

## **Discussion**

We describe a novel minimally invasive technique for safe fetoscopic entry through the posterior uterine wall in patients where the placenta completely covers the anterior uterine wall. This safe entry was accomplished by laparoscopic guidance of the fetoscope, thus avoiding the risk of bowel damage at peritoneal entry and of vascular damage at uterine entry. Our findings suggest that perinatal survival rate and procedure-related complications rate associated with this novel technique are similar compared to the conventional percutaneous laser technique without laparoscopy. However, procedure-related complication rate remained higher in the group with partly and completely anterior placenta compared to the group with posterior placenta.

Since the development of the technique of fetoscopic laser coagulation, patients with an anterior placenta have presented a technical challenge. In the first series of De Lia et al, patients with anterior placenta were excluded from fetoscopic laser surgery.<sup>4</sup> In the second series of De Lia et al, 46% of patients had an anterior placenta and underwent midline laparotomy with the uterus exteriorised for optimal insertion of the fetoscope.<sup>16</sup> Nowadays, De Lia is still using this operation technique in patients with a completely anterior placenta (personal communication). In the first series of Ville *et al*, 40% of the patients had an anterior placenta.<sup>5</sup> In this study, a rigid fetoscope was used and the same procedure was used for anterior placenta as for posterior placenta localisation. The author stated that adequate visualisation of the intertwin membrane and coagulation of the crossing vessels was more difficult to achieve in the patients with anterior placenta. In the second series of Ville *et al*, which included patients of their first series, 43% of the patients had an anterior placenta.<sup>10</sup> In this series of 57 patients, the percutaneous insertion site of the fetoscope was chosen as lateral as possible and sonographically guided by colour Doppler to avoid the uterine vessels. Nevertheless, in 9 of their patients the entry was transplacental. They state, however, that good visualisation of intertwin membrane and crossing vessels was achieved in all cases. Deprest *et al* also recognised the technical problems of an anterior placenta. They

described an alternative technique for fetoscopic access in patients with anterior placenta, using mini-laparotomy mainly in the region of the uterine fundus, Seldinger technique for uterine entry and a curved shaft with a semi-rigid fiberscope.<sup>7</sup> In the series of Zikulnig *et al*, 36% of the patients had an anterior placenta.<sup>8</sup> They mentioned that, when using the lateral percutaneous technique, the procedure succeeded in most cases, though more technical difficulties were encountered in achieving good visualisation and coagulation of vessels. Hecher *et al*, stated that, in most patients with anterior placenta, the lateral percutaneous fetoscopic access provided good visualisation of most vascular anastomoses, although detailed results were not reported.<sup>9</sup> Quintero *et al* described two techniques for the laser treatment in women with anterior placenta. The first technique entails the use of a flexible scope through a single port. The second technique is based on the use of a side-firing laser fibre through one port and a rigid angled-view endoscope through a second port. No significant differences in survival were found, but operating time was significantly increased for those with an anterior placenta.<sup>11</sup> Yamamoto *et al* reported on incidence and impact of perioperative complications in 175 fetoscopy-guided laser coagulation procedures.<sup>17</sup> Transplacental entry occurred in 27% of the cases and was 5 times more frequent when the placenta was anterior. Intraamniotic haemorrhage was 3 times more frequent with transplacental entry. However, position of the placenta and transplacental entry were not correlated with the outcome.

Although the majority of authors do not find significant differences in perinatal survival between cases with anterior and with posterior placenta, many authors mention the fact that anterior placenta presents a technical challenge because of impaired visualisation of the placental surface. All but one published series of fetoscopic laser coagulation of vascular anastomoses were non-randomised prospective studies. Possibly, some of the patients with a completely anterior placenta would not have been included in these series, because of the anticipation on technical problems of percutaneous fetoscopic laser coagulation.

Our technique is an alternative to the existing techniques aimed on being

minimally invasive and providing a close to 90 degrees perpendicular intra-uterine access for optimal visualisation and laser effectiveness, with simultaneous avoidance of the maternal intraperitoneal structures. We agree with other authors that in a substantial number of patients with an anterior placenta, lateral percutaneous fetoscopic access provides acceptable conditions for laser surgery. During the study period, 9 of 25 patients with an anterior placenta underwent fetoscopic laser coagulation using the conventional percutaneous fetoscopic entry. However, in patients with completely anterior placenta, this procedure still entails a risk of transplacental entry or incomplete laser surgery.<sup>17</sup> Procedure-related complication rates in completely anterior placenta have not yet been reported. We found that 2 of 4 procedure-related complications in the control groups occurred in the control group with partially anterior placenta, confirming the suggestion that fetoscopic procedures carry more risks in patients with an anterior placenta. Procedure-related complications also occurred in the study group in which we performed the laparoscopic procedure. However, this group of patients was a highly selective group where the placenta covered the complete anterior uterine wall and no placenta-free site could be identified for safe lateral percutaneous fetoscopic entry. This may explain the higher number of procedure-related complications towards less favourable placental localisation.

Laparoscopically guided fetoscopy also has some limitations. Firstly, abdominal adhesions may hamper application of this technique. Secondly, we found an 18% risk of intraamniotic bleeding in our study group. This may be by coincidence, as the incidence of intraamniotic bleeding did not differ significantly between the study group and the two control groups, and as the overall incidence, 6/65 (9.2%), of intraamniotic bleeding in both study and control groups was very similar to the 8.6% found by Yamamoto *et al.*<sup>17</sup> However, the high risk of intraamniotic bleeding in the study group may also be explained by the limited value of colour Doppler for identification and avoidance of vasculature when the uterine entry site is posterior. Also, the use of general anaesthesia for laparoscopy may promote uterine relaxation and thus the risk of bleeding at perforation.



## **Conclusions**

Laparoscopically assisted fetoscopic uterine access through the dorsal uterine wall for laser coagulation of vascular anastomoses in patients with severe TTTS is a novel technique. This technique enables safe uterine entry in a selected group of patients with an anterior placenta covering the complete anterior uterine wall. There were no significant differences in perinatal survival between the laparoscopically guided and the conventional percutaneous fetoscopic entry technique. However, procedure-related complication rate remained higher in women with anterior than in women with posterior placental localisation. Further comparison between laparoscopically guided fetoscopy and alternative approaches may form the subject of prospective controlled trials.

## References

1. Sebire NJ, Souka A, Skentou H, Geerts L, Nicolaides KH: Early prediction of severe twin-to-twin transfusion syndrome. *Hum Reprod* 2000; 15:2008-10.
2. Gemert JC van, Umur A, Tijssen JGP, Ross MG: Twin-twin transfusion syndrome: etiology, severity and rational management. *Curr Opin Obstet Gynecol* 2001;13:193-206.
3. De Lia JE, Cruikshank DP, Keye WR Jr: Fetoscopic neodymium:YAG laser occlusion of placental vessels in severe twin-twin transfusion syndrome. *Obstet Gynecol* 1990;75:1046-53.
4. De Lia JE, Kuhlman RS, Harstad TW, Cruikshank DP: Fetoscopic laser ablation of placental vessels in severe previable twin-twin transfusion syndrome. *Am J Obstet Gynecol* 1995;172:1202-11.
5. Ville Y, Hyett J, Hecher K, Nicolaides K: Preliminary experience with endoscopic laser surgery for severe twin-twin transfusion syndrome. *N Engl J Med* 1995;332:224-7.
6. Senat MV, Deprest J, Boulvain M, Paupe A, Winer N, Ville Y: Endoscopic laser surgery versus serial amnioreduction for severe twin-to-twin transfusion syndrome. *N Engl J Med* 2004;351:136-44.
7. Deprest JA, Van Schoubroeck D, Van Ballaer PP, Flageole H, Van Assche FA, Vandenberghe K: Alternative technique for Nd: YAG laser coagulation in twin-to-twin transfusion syndrome with anterior placenta. *Ultrasound Obstet Gynecol* 1998;11:347-52.
8. Zikulnig L, Hecher K, Bregenzer T, Baz E, Hackeloer BJ: Prognostic factors in severe twin-twin transfusion syndrome treated by endoscopic laser surgery. *Ultrasound Obstet Gynecol* 1999;14:380-7.
9. Hecher K, Diehl W, Zikulnig L, Vetter M, Hackeloer BJ: Endoscopic laser coagulation of placental anastomoses in 200 pregnancies with severe mid-trimester twin-to-twin transfusion syndrome. *Eur J Obstet Gynecol Reprod Biol* 2000;92:135-9.
10. Ville Y, Hecher K, Gagnon A, Sebire N, Hyett J, Nicolaides K: Endoscopic laser coagulation in the management of severe twin-to-twin transfusion syndrome. *Br J Obstet Gynaecol* 1998;105:446-53.
11. Quintero RA, Bornick PW, Allen MH, Johnson PK: Selective laser photocoagulation of communicating vessels in severe twin-twin transfusion syndrome in women with an anterior placenta. *Obstet Gynecol* 2001;97:477-81.
12. Kolkman W, Scherjon SA, Gaarenstroom KN, Jansen FW: Laparoscopic management of adnexal masses with the open entry technique in second-trimester pregnancy. *Gynecol Surg* 2004;1:21-5.
13. SAGES (Society of American Gastrointestinal Endoscopic Surgeons): Guidelines for laparoscopic surgery during pregnancy. *Surg Endosc* 1998;12:189-90.
14. Middeldorp JM, Sueters M, Lopriore E, Klumper FJ, Oepkes D, Devlieger R, Kanhai HH, Vandebussche FP: Fetoscopic surgery in 100 pregnancies with severe twin-to-twin transfusion syndrome in the Netherlands. *Fetal Diagn Ther* 2007;22:190-194.
15. Hasson HM: A modified instrument and method for laparoscopy. *Am J Obstet Gynecol* 1971;110:886-7.

*Chapter 5*

16. De Lia JE, Kuhlmann RS, Lopez KP: Treating previable twin-twin transfusion syndrome with fetoscopic laser surgery: Outcomes following the learning curve. *J Perinat Med* 1999;27:61-7.
17. Yamamoto M, El Murr L, Robyr R, Leleu F, Takahashi Y, Ville Y: Incidence and impact of perioperative complications in 175 fetoscopy-guided laser coagulations of chorionic plate anastomoses in fetofetal transfusion syndrome before 26 weeks of gestation. *Am J Obstet Gynecol* 2005;193:1110-6.