Universiteit Leiden
The Netherlands

Fetoscopic interventions in complicated monochorionic twin pregnancies

Middeldorp, J.H.

Citation

Middeldorp, J. H. (2007, April 17). *Fetoscopic interventions in complicated monochorionic twin pregnancies*. Department of Obstetrics, Faculty of Medicine, Leiden University Medical Center (LUMC), Leiden University. Retrieved from https://hdl.handle.net/1887/11952

Version:	Corrected Publisher's Version
License:	Licence agreement concerning inclusion of doctoral thesis in the Institutional Repository of the University of Leiden
Downloaded from:	https://hdl.handle.net/1887/11952

Note: To cite this publication please use the final published version (if applicable).

Fetoscopic interventions in complicated monochorionic twin pregnancies

Annemieke Middeldorp

Fetoscopic interventions in complicated monochorionic twin pregnancies

ISBN 90-9021623-2

Printed by: Pasmans Offsetdrukkerij BV, Den Haag

Financial support by:
Karl Storz BV
Stichting FEMAR

© 2007 J.M.Middeldorp

Fetoscopic interventions in complicated monochorionic twin pregnancies

Proefschrift

ter verkrijging van
de graad van Doctor aan de Universiteit Leiden,
op gezag van Rector Magnificus prof.mr. P.F. van der Heijden,
volgens besluit van het College voor Promoties
te verdedigen op dinsdag 17 april 2007
klokke 16:15 uur

door

Johanna Maria Middeldorp
geboren te Den Haag
in 1962

Promotiecommissie

Promotor:	Prof. Dr H.H.H. Kanhai
Copromotor:	Dr F.P.H.A. Vandenbussche
Referent:	Prof. Dr Ir M.J.C. van Gemert
Overige leden:	Prof. Dr J.F. Hamming Dr F.W. Jansen

ter nagedachtenis aan mijn vader

voor Martien, Marleen en Julia

Table of contents

Chapter 1	**General introduction**	**9**
Chapter 2	**Timely diagnosis of twin-to-twin transfusion syndrome by biweekly ultrasound and patient instructions** *(Ultrasound in Obstetrics and Gynecology 2006;28:659-64)*	**25**
Chapter 3	**Fetoscopic laser surgery in 100 pregnancies with severe twin-to-twin transfusion syndrome in the Netherlands** *(Fetal Diagnosis and Therapy 2007; 22:190-194)*	**43**
Chapter 4	**Residual anastomoses after fetoscopic laser surgery in twin-to-twin transfusion syndrome: frequency, associated risks and outcome** *(Placenta 2007;28:204-8)*	**57**
Chapter 5	**Laparoscopically guided uterine entry for fetoscopy in twin-to-twin transfusion syndrome with completely anterior placenta: a novel technique** (*Fetal Diagnosis and Therapy, in press)*	**71**
Chapter 6	**Long-term neurodevelopmental outcome in twin-to-twin transfusion syndrome treated with fetoscopic laser surgery** *(American Journal of Obstetrics and Gynecology, in press)*	**89**
Chapter 7	**Selective feticide in monoamniotic twin pregnancies by umbilical cord occlusion and transection** *(Fetal Diagnosis and Therapy, accepted for publication)*	**103**

Chapter 8 **TTTS after 26 weeks gestation: is there a role for fetoscopic laser surgery?** **117**
(British Journal of Obstetrics and Gynecology, accepted for publication)

Chapter 9 **General discussion and future perspectives** **131**

Chapter 10 **Summary/samenvatting** **149**

List of abbreviations **159**
Authors and affiliations **163**
Publications **167**
Dankwoord **171**
Curriculum Vitae **175**

General introduction

1

Background

Twin gestations represent 1% to 2% of all pregnancies. Two thirds of twin gestations are fraternal or dizygotic twins and one third of twin gestations are identical or monozygotic twins. Of live born monozygotic twins, 25-30% has completely separate placentas with dichorionic diamniotic membranes, whereas 70-75% shares one placenta with monochorionic diamniotic membranes. Whether the membranes are monochorionic or dichorionic, and vascular anastomoses between both circulations do or do not exists, depends on whether cleavage occurred before or after day 3 post-conception.[1] Only 1-2% of live born monozygotic twins share one placenta with monochorionic monoamniotic membranes. Monozygotic twins have a significantly higher risk of adverse outcome than dizygotic twins (RR 2.5; 95% CI, 1.1-2.5).[2] It is chorionicity, rather than the zygosity, that determines the adverse outcome. Perinatal statistics often underestimate the problem, because the highest fetal loss rate occurs before viability. In fact, monochorionic twins have a six fold higher fetal loss rate (12%) between 10 and 24 weeks' gestation compared with dichorionic twins and singletons.[3]

Vascular anastomoses are almost invariably present in monochorionic placentas, but not in dichorionic placentas.[4] These vascular anastomoses are an important cause of morbidity and mortality. Three types of placental vascular anastomoses have been documented: the superficial bidirectional artery to artery (AA) and vein to vein (VV) anastomoses, and the so-called deep unidirectional artery to vein (AV) anastomoses. (Figure 1)

The major complications of monochorionic twin gestation are twin-to-twin transfusion syndrome (TTTS), intra-uterine growth restriction (IUGR), and discordant fetal anomalies, e.g. twin reversed arterial perfusion (TRAP). These complications are associated with a very high rate of perinatal morbidity and mortality. In monochorionic twin pregnancies, the occurrence of single intrauterine fetal demise of one twin carries a risk of co-twin demise and neurological abnormality in the surviving co-twin of 12% and 18%, respectively, compared to 4% and 1% in dichorionic twin pregnancies.[5] In case of single intrauterine fetal demise in monochorionic twin pregnancies, the vascular

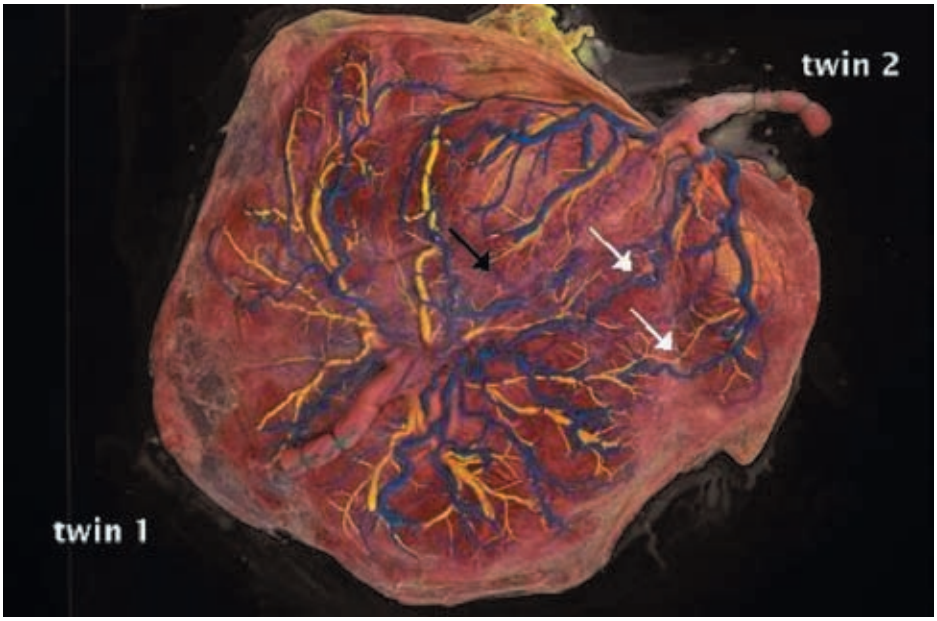

Figure 1 *Placenta from a monochorionic twin pregnancy without twin-to-twin transfusion syndrome after dye-injection (blue for arteries and orange or yellow for veins). The left white arrow indicates an arterioarterial anastomose and the right white arrow indicates a venovenous anastomose. The black arrow indicates an arteriovenous anastomose from twin 1 to twin 2 (from J. vd Wijngaard, Laser Centre AMC, with permission).*

anastomoses allow transfer of blood from the surviving twin to the dead co-twin, the so-called acute perimortem intertwin transfusion, giving rise to periods of hypo perfusion, hypotension and acute fetal anaemia.[6] The risk of mortality of the healthy co-twin is higher in the presence of superficial AA and VV anastomoses than in the presence of only AV and VA anastomoses.[7]

Twin-to-twin-transfusion syndrome

TTTS only occurs in monochorionic twin pregnancies and is one of the most lethal conditions in perinatal medicine. Several forms of TTTS have been described: chronic, acute perimortem, acute perinatal and TRAP. Chronic TTTS is the most common form, complicating approximately 15% of monochorionic diamniotic twin pregnancies, and is the consequence of a chronic imbalance

in the net blood flow across the vascular anastomoses on the monochorionic placenta.[8;9] The imbalance occurs when blood flow from one twin through unidirectional AV anastomoses is insufficiently compensated by blood flow through AV anastomoses in the opposite direction or through bidirectional superficial anastomoses (AA and VV). The number, size and type of the vascular anastomoses appear to play an important role in the development of TTTS.[10] For the development of TTTS the presence of at least one AV anastomosis is essential. The presence of AA anastomoses is thought to offer protection against the development of TTTS, which has also been demonstrated in a mathematical computer model of chronic TTTS.[11-13] Large AA anastomoses are also known to be present in the vast majority of monoamniotic twin pregnancies and are held responsible for the fact that TTTS develops five times less frequently in monoamniotic twins then in diamniotic twins.[14;15]

Vascular anastomoses are already present in the first trimester, but clinical signs occur in the second trimester of pregnancy (14-26 weeks). In general, polyhydramnios with or without premature contractions is the first clinical sign of TTTS. The first sonographic signs of TTTS are oliguria in the donor, resulting in oligohydramnios in the donor sac, and polyuria in the recipient, resulting in a polyhydramnios in the recipient sac. Hereafter, more severe signs may occur such as anuria in the donor, heart failure and hydrops in the recipient, and single or double fetal demise. Polyhydramnios may result in premature contractions or preterm rupture of membranes, leading to preterm birth. Intertwin growth discrepancy and haemoglobin discordance are often reported, bur are not key criteria for the diagnosis of chronic TTTS.[16;17] Quintero proposed a staging system in order to classify the severity of the syndrome.[18] Stage 1 is the poly/oligohydramnios sequence with a deepest vertical pocket of ≥ 8cm before 20 weeks of gestation or ≥ 10cm after 20 weeks of gestation in the sac of the recipient and a deepest vertical pocket of ≤ 2 cm in the sac of the donor, with the bladder of the donor still visible. In stage 2, the bladder of the donor remains empty as the result of anuria. Stage 3 is characterised by severely abnormal Doppler measurements: absent or reversed end-diastolic flow in the umbilical artery of the donor or abnormal venous Doppler patterns

in the recipient, such as reverse flow in the ductus venosus or pulsatile umbilical venous flow. In stage 4, the recipient is hydropic and in stage 5 a single or double fetal demise has occurred. (Table 1)

Table 1 *Staging classification of chronic TTTS according to Quintero*[18]

Stage	Sonographic criteria
stage 1	combination of polyhydramnios* and oligohydramnios**
stage 2	bladder of the donor twin not visible
stage 3	critically abnormal Doppler studies†
stage 4	ascites, pericardial or pleural effusion, scalp oedema, or overt hydrops are present
stage 5	single or double fetal demise

* *deepest vertical pocket of amniotic fluid ≥ 8 cm (below 20 weeks) or ≥10 cm (above 20 weeks)*

** *deepest vertical pocket ≤ 2 cm*

† *reversed flow in the ductus venosus or pulsatile umbilical venous flow in the recipient, and/or absent or reversed end-diastolic flow in the umbilical artery of the donor*

Therapeutic options that have been used include expectant management, empiric medical treatment (e.g. digoxin), septostomy, selective feticide, serial amnioreduction and laser coagulation of vascular anastomoses. In severe TTTS, conservative treatment is associated with mortality rates of more than 80%, although more recently an overall survival rate of 37% was reported.[19-21] Medical treatment with maternal digoxin administration to improve cardiac function in the recipient, although anecdotically associated with success, and indomethacin therapy to reduce polyhydramnios have not been proven to be of benefit.[22;23] Septostomy, the intentional puncturing of the intertwin membrane, has not proven to be a superior treatment option in previable TTTS. The only advantage of septostomy over serial amnioreduction, was that there were less invasive procedures in the septostomy group.[24] In addition, results of a study with a mathematical model for chronic TTTS suggest that septostomy is unlikely to offer significant therapeutic efficacy.[25]

Selective feticide by occlusion of the umbilical cord through ligation or bipolar coagulation in order to save one infant and optimise its prognosis can be a treatment modality in selected cases, for example in the case of poor prognosis of one fetus.[26] Serial amnioreduction is a symptomatic treatment for TTTS and involves the repetitive removal of large volumes of amniotic fluid. It has been used since the 1980s. The transient reduction of amniotic fluid reduces pressure on the placenta with improvement of transplacental fluid flow between mother and foetus, and reduces the risk of preterm delivery.[25] The overall perinatal survival rate in uncontrolled published series with cases diagnosed before 26 weeks was approximately 60% with a risk of severe neurological sequelae in 16% of survivors.[21;27]

Fetoscopic laser coagulation of vascular anastomoses on the placental surface, a cause-oriented approach for TTTS, was developed in the United States and the United Kingdom and first described by De Lia *et al* in 1990.[28-30] After fetoscopic coagulation of the anastomotic vessels, the polyhydramnios in the sac of the recipient is drained. The reported overall perinatal survival rates in case series treated with fetoscopic laser coagulation vary from 48 to 71%.[18;28-38] The technique of laser coagulation has been adapted over the years. The earlier described technique of coagulating all vessels crossing the intertwin membrane is no longer first choice treatment, because it leads to unnecessary placental loss.[30] Although the theoretical concept of coagulating only the causative AV anastomoses has been discussed, most groups do adhere to an approach of selectively coagulating all visualised anastomoses.[39;40] A recent randomised trial reported significantly higher perinatal survival and improved neurological outcome in TTTS survivors after fetoscopic laser surgery compared to serial amnioreduction.[41] The overall survival in the laser group compared to the amnioreduction group was 57% versus 41%, respectively (p=0.01). Survival of at least one twin at the age of six months was 76% in the laser group and 51% in the amnioreduction group (p=0.002). At the age of six months, major neurological sequelae were found in 19% of the surviving children after amnioreduction and in 7% after laser surgery (p=0.05). Long-term neurodevelopmental outcome of the surviving children has not yet been reported.[41]

Early complications occurring in the first week after fetoscopic laser surgery include miscarriage (12% of cases), premature rupture of membranes (7%), placental abruption (1.7%), and intrauterine fetal death (13% to 33%) and double intrauterine fetal death (3% to 22%).[42;43] Late complications include preterm premature rupture of membranes before 32 weeks (17%), recurrence of TTTS (14%), isolated marked discordant haemoglobin levels (13%), and double intrauterine fetal demise (1% of cases).[43]
Whether fetoscopic laser coagulation is the treatment modality of choice in all stages of chronic TTTS is still unclear. Some authors suggest a stage-based treatment of chronic TTTS, with amnioreduction in milder cases of TTTS and laser surgery in the more advanced stages of TTTS.[44] However, the randomised study of Senat *et al* showed significant better outcome in the laser surgery group compared to the amnioreduction group in all stages.[41] Another prospective study showed a significant trend towards reduced survival rates with increasing stage (p=0.038) and concludes that fetoscopic laser surgery is an effective therapeutic option for all stages of TTTS.[45]

Discordant growth retardation in monochorionic twins

The proportion of pregnancies with a birth weight discordance of more than 25% is similar in monochorionic and dichorionic twin pregnancies, 11 and 12% respectively. However, the proportion of pregnancies with one fetus with a birth weight below the 10th percentile is significantly higher in monochorionic than in dichorionic twin pregnancies, 53% and 37% respectively.[3] With a birth weight discordance of more than 25%, the smaller twin will have a birth weight below the 10th percentile in 62% of pregnancies.[46] The differential diagnosis between TTTS en discordant intrauterine growth retardation in monochorionic twins can easily be made by the absence of polyhydramnios in the sac of the appropriately grown fetus. Birth weight discordance carries a greater risk in monochorionic compared to dichorionic twin pregnancies because of the vascular anastomoses on the placental surface. Intrauterine fetal demise of the growth retarded fetus can lead to acute perimortem intertwin transfusion,

resulting in neurological damage or death of the co-twin.[6] Management options in discordant growth retardation include expectant management, selective feticide of the severely growth retarded twin through cord coagulation, fetoscopic laser coagulation of vascular anastomoses to convert to a dichorionic twin pregnancy or elective delivery. The best way of management in these complex situations is not yet clear.

Discordant structural anomalies in monochorionic twins

Structural anomalies are more common in twins than in singletons. The frequency of malformations in dizygotic twins is thought to be similar to that of singletons (2-3%), while it has been reported to be two to three times higher in monozygotic twins. However, the true incidence is difficult to assess since most studies failed to determine zygosity, and some assumed dizygosity in the presence of a discordant anomaly.[47] Anomalies include malformations like conjoined twins, acardiac twins, neural tube defects, brain defects, facial clefts, cloacal and abdominal wall anomalies.[48] Structural heart malformations in monochorionic twins without TTTS are four times more common than in the general population.[49] Overall, it has been estimated that in approximately 15% of cases only one twin is affected.[50] Although monozygotic twins are thought to be genetically identical, a number of discordances for common chromosomal anomalies have been noted.[51] The most frequently reported heterokaryotypia is the discordance for Turner syndrome.[52] The major risk of a discordant anomaly in a monochorionic twin is single intrauterine fetal demise of the affected twin with acute perimortem intertwin transfusion.
Management options for discordant anomaly in monochorionic twin pregnancy include expectant management, selective feticide or pregnancy termination. The presence of vascular anastomoses does not allow the injection of any lethal agent to achieve selective feticide in monochorionic twin pregnancies. The injected drug may leak into the unaffected twin's circulation causing direct death, or may lead to acute perimortem intertwin transfusion from the healthy co-twin into the dying fetus and result in intrauterine fetal death or

organ damage in this co-twin.[53] In monochorionic twin pregnancies, selective termination needs to be performed by ensuring complete and permanent occlusion of both the arterial and venous flows in the umbilical cord of the affected twin, in order to avoid acute perimortem intertwin transfusion from the co-twin into the dying twin. Several techniques have been described to interrupt the blood flow in the umbilical cord including embolisation of the umbilical cord using sclerosant agents, fetoscopic umbilical cord ligation, fetoscopic laser coagulation of the umbilical cord and sonographically guided bipolar coagulation of the umbilical cord.[54-57] On the basis of current data, it seems best to consider fetoscopically guided laser coagulation of the cord up to 20 weeks' gestation.[58] After 20 weeks, the thickness of the cord and the quantity of Wharton's jelly content limit the effects of laser, and in these cases bipolar coagulation is probably more successful.[59]

Outline of the thesis

Leiden University Medical Centre (LUMC) is a tertiary medical centre in the Netherlands and serves as the national referral centre for fetal therapy. The fetoscopic surgery program started in August 2000. Since then, several study projects associated with the fetal surgery program were initiated, with an ongoing collaboration between the obstetric and neonatology departments of the LUMC. The studies in this thesis can be summarised as follows:

Chapter 2 - Study to assess the value of serial ultrasound examinations together with patient instructions in achieving timely detection of TTTS in a cohort of monochorionic diamniotic twin pregnancies, and to evaluate sonographic TTTS predictors.

Chapter 3 - Study on the initial results of fetoscopic laser surgery for severe second trimester TTTS treated at the LUMC and on the relation between outcome and Quintero stage at the time of treatment.

Chapter 4 – Study on the frequency of residual placental vascular anastomoses after fetoscopic laser surgery for TTTS and their relation to complications and outcome.

Chapter 5 – Study on the technical result and perinatal survival of a novel technique, developed at the LUMC. Laparoscopy is used to guide safe percutaneous insertion of the fetoscope through the lateral abdominal wall and the dorsal side of the uterus to allow fetoscopy in TTTS with completely anterior placenta.

Chapter 6 – Study on the long-term neurodevelopmental outcome in TTTS treated with fetoscopic laser surgery at the LUMC between August 2000 and December 2003.

Chapter 7 – Description of technical details of selective feticide and outcome of three monoamniotic twin pregnancies, discordant for fetal anomaly (two cases of anencephaly and one case of congenital heart block), in which cord occlusion was followed by transection of the cord, using contact laser.

Chapter 8 – Study on the outcome in TTTS, diagnosed after 26 weeks' gestation. Cases treated with fetoscopic laser surgery were compared to a control group, treated with amniodrainage.

Chapter 9 – Summary of the acquainted knowledge, general discussion concerning the results of the studies and proposals for future research.

References

1. Hollenbach KA, Hickok DE. Epidemiology and diagnosis of twin gestation. Clin Obstet Gynecol 1990;33:3-9.

2. Dube J, Dodds L, Armson BA. Does chorionicity or zygosity predict adverse perinatal outcomes in twins? Am J Obstet Gynecol 2002;186:579-83.

3. Sebire NJ, Snijders RJ, Hughes K, Sepulveda W, Nicolaides KH. The hidden mortality of monochorionic twin pregnancies. Br J Obstet Gynaecol 1997;104:1203-7.

4. Robertson EG, Neer KJ. Placental injection studies in twin gestation. Am J Obstet Gynecol 1983;147:170-4.

5. Ong S, Zamora J, Khan K, Kilby M. Prognosis for the co-twin following single-twin death: a systematic review. BJOG 2006;113:992–998.

6. Bajoria R, Kingdom J. The case for routine determination of chorionicity and zygosity in multiple pregnancy. Prenat Diagn 1997;17:1207-25.

7. Bajoria R, Wee LY, Anwar S, Ward S. Outcome of twin pregnancies complicated by single intrauterine death in relation to vascular anatomy of the monochorionic placenta. Hum Reprod 1999;14:2124-30.

8. Lopriore E, Vandenbussche FP, Tiersma ES, de Beaufort AJ, de Leeuw JP. Twin-to-twin transfusion syndrome: new perspectives. J Pediatr 1995;127:675-80.

9. Sebire NJ, Souka A, Skentou H, Geerts L, Nicolaides H. Early prediction of severe twin-to-twin transfusion syndrome. Hum Reprod 1997;15:2008-10.

10. Benirschke K. The placenta in twin gestation. Clin Obstet Gynecol 1990;33:18-31.

11. Machin G, Still K, Lalani T. Correlations of placental vascular anatomy and clinical outcomes in 69 monochorionic twin pregnancies. Am J Med Genet 1996;61:229-36.

12. Bajoria R, Wigglesworth J, Fisk NM. Angioarchitecture of monochorionic placentas in relation to the twintwin transfusion syndrome. Am J Obstet Gynecol 1995;172:856-63.

13. Umur A, van Gemert MJ, Nikkels PG, Ross MG. Monochorionic twins and twin-twin transfusion syndrome: the protective role of arterio-arterial anastomoses. Placenta 2002; 23: 201-9.

14. Heyborne KD, Porreco RP, Garite TJ, Phair K, Abril D; Obstetrix/Pediatrix Research Study Group. Improved perinatal survival of monoamniotic twins with intensive inpatient monitoring. Am J Obstet Gynecol 2005;192:96-101.

15. Schaap AH, van den Wijngaard JP, Nikkels PG, van den Broek AJ, Snieders I, van Gemert MJ. Significance of donor anuria differs between monoamniotic and diamniotic twin-twin transfusion syndrome. Placenta 2006;[Epub ahead of print].

16. Danskin FH, Neilson JP. Twin-to-twin transfusion syndrome: What are appropriate diagnostic criteria? Am J Obstet Gynecol 1989;161:365-9.

17. Wee LY, Fisk NM. The twin-twin transfusion syndrome. Semin Neonatol 2002;7:187-202.

18. Quintero RA, Morales WJ, Allen MH, Bornick PW, Johnson PK, Kruger M. Staging of twin-twin transfusion syndrome. J Perinatol 1999;19:550-5.

19. Berghella V, Kaufmann M. Natural history of twin-twin transfusion syndrome. J Reprod Med 2001;46:480-4.

20. Urig MA, Clewell WH, Elliott JP. Twin-twin transfusion syndrome. Am J Obstet Gynecol 1990;163:1522-6.

21. van Gemert MJ, Umur A, Tijssen JG, Ross MG. Twin-twin transfusion syndrome: etiology, severity and rational management. Curr Opin Obstet Gynecol 2001;13:193-206.

22. De Lia J, Emery MG, Sheafor SA, Jennison TA. Twin transfusion syndrome: successful in utero treatment with digoxin. Int J Gynaecol Obstet 1985;23:197-201.

23. Jones JM, Sbarra AJ, Dilillo L, Cetrulo CL, D'Alton ME. Indomethacin in severe twin-to-twin transfusion syndrome. Am J Perinatol 1993;10: 24-6.

24. Moise KJ Jr, Dorman K, Lamvu G, Saade GR, Fisk NM, Dickinson JE, Wilson RD, Gagnon A, Belfort MA, O'Shaughnessy RO, Chitkara U, Hassan SS, Johnson A, Sciscione A, Skupski D. A randomised trial of amnioreduction versus septostomy in the treatment of twin-twin transfusion syndrome. Am J Obstet Gynecol 2005;193:701-7. Erratum in: Am J Obstet Gynecol 2005;193:2183.

25. Umur A, van Gemert MJ, Ross MG. Fetal urine and amniotic fluid in monochorionic twins with twin-twin transfusion syndrome: simulations of therapy. Am J Obstet Gynecol 2001;185:996-1003.

26. Taylor MJ, Shalev E, Tanawattanacharoen S, Jolly M, Kumar S, Weiner E, Cox PM, Fisk NM. Ultrasound-guided umbilical cord occlusion using bipolar diathermy for Stage III/IV twin-twin transfusion syndrome. Prenat Diagn 2002;22:70-6.

27. Skupski DW, Gurushanthaiah K, Chasen S. The effect of treatment of twin-twin transfusion syndrome on the diagnosis-to-delivery interval. Twin Res 2002;5:1-4.

28. De Lia JE, Cruikshank DP, Keye WR Jr: Fetoscopic neodymium. YAG laser occlusion of placental vessels in severe twin-twin transfusion syndrome. Obstet Gynecol 1990;75:1046-53.

29. De Lia JE, Kuhlman RS, Harstad TW, Cruikshank DP. Fetoscopic laser ablation of placental vessels in severe previable twin-twin transfusion syndrome. Am J Obstet Gynecol 1995;172:1202-11.

30. Ville Y, Hyett J, Hecher K, Nicolaides K. Preliminary experience with endoscopic laser surgery for severe twin-twin transfusion syndrome. N Engl J Med 1995;332:224-7.

31. Hecher K, Diehl W, Zikulnig L, Vetter M, Hackeloer BJ. Endoscopic laser coagulation of placental anastomoses in 200 pregnancies with severe mid-trimester twin-to-twin transfusion syndrome. Eur J Obstet Gynecol Reprod Biol 2000;92:135-9.

32. Hecher K, Plath H, Bregenzer T, Hansmann M, Hackeloer BJ. Endoscopic laser surgery versus serial amniocenteses in the treatment of severe twin-twin transfusion syndrome. Am J Obstet Gynecol 1999;180:717-24.

33. De Lia JE, Kuhlmann RS, Lopez KP. Treating previable twin-twin transfusion syndrome with fetoscopic laser surgery: outcomes following the learning curve. J Perinat Med 1999;27:61-7.

34. Ville Y, Hecher K, Gagnon A, Sebire N, Hyett J, Nicolaides K. Endoscopic laser coagulation in the management of severe twin-to-twin transfusion syndrome. Br J Obstet Gynaecol 1998;105:446-53.

35. Allen MH, Garabelis NS, Bornick PW, Quintero RA. Minimally invasive treatment of twin-to-twin transfusion syndrome. AORN J 2000;71: 796, 801-796, 810.

36. Quintero RA, Bornick PW, Morales WJ, Allen MH. Selective photocoagulation of communicating vessels in the treatment of monochorionic twins with selective growth retardation. Am J Obstet Gynecol 2001;185:689-96.

37. Quintero RA, Morales WJ, Mendoza G *et al*. Selective photocoagulation of placental vessels in twin-twin transfusion syndrome: evolution of a surgical technique. Obstet Gynecol Surv 1998;53:S97-103.

38. Middeldorp JM, Klumper FJ, Oepkes D, Lopriore E, Kanhai HH, Vandenbussche FP. The initial results of fetoscopic laser treatment for severe second trimester twin-to-twin transfusion syndrome in the Netherlands are comparable to international results. Ned Tijdschr Geneeskd 2004;148:1203-8.

39. Feldstein VA, Machin GA, Albanese CT, Sandberg P, Farrell JA, Farmer DL, Harrison MR. Twin-twin transfusion syndrome: the 'Select' procedure. Fetal Diagn Ther 2000;15:257-61.

40. Quintero RA, Comas C, Bornick PW, Allen MH, Kruger M. Selective versus non-selective laser photocoagulation of placental vessels in twin-to-twin transfusion syndrome. Ultrasound Obstet Gynecol 2000;16:230-6.

41. Senat MV, Deprest J, Boulvain M, Paupe A, Winer N, Ville Y. Endoscopic laser surgery versus serial amnioreduction for severe twin-to-twin transfusion syndrome. N Engl J Med 2004;351:136-44.

42. Yamamoto M, El Murr L, Robyr R, Leleu F, Takahashi Y, Ville Y. Incidence and impact of perioperative complications in 175 fetoscopy-guided laser coagulations of chorionic plate anastomoses in fetofetal transfusion syndrome before 26 weeks of gestation. Am J Obstet Gynecol 2005;193:1110-6.

43. Robyr R, Lewi L, Salomon LJ, Yamamoto M, Bernard JP, Deprest J, Ville Y. Prevalence and management of late fetal complications following successful selective laser coagulation of chorionic plate anastomoses in twin-to-twin transfusion syndrome. Am J Obstet Gynecol 2006;194:796-803.

44. Quintero RA, Dickinson JE, Morales WJ, Bornick PW, Bermudez C, Cincotta R, Chan FY, Allen MH. Stage-based treatment of twin-twin transfusion syndrome. Am J Obstet Gynecol 2003;188:1333-40.

45. Huber A, Diehl W, Bregenzer T, Hackeloer BJ, Hecher K. Stage-related outcome in twin-twin transfusion syndrome treated by fetoscopic laser coagulation. Obstet Gynecol 2006;108:333-7.

46. Blickstein I. Monochorionic pregnancy - where have we been? Where are we going? Am J Obstet Gynecol 2004;191:383-4;author reply 384.

47. Baldwin VJ. Anomalous development in twins. In: Pathology of multiple pregnancies. New York:Springer-Verlag;1994:169-197.

48. Hall JG. Twinning. Lancet 2003;362:735-43.

49. Karatza AA, Wolfenden JL, Taylor MJ, Wee L, Fisk NM, Gardiner HM. Influence of twin-twin transfusion syndrome on fetal cardiovascular structure and function: prospective case-control study of 136 monochorionic twin pregnancies. Heart 2002;88:271-7.

50. Bryan E, Little J, Burn J. Congenital anomalies in twins. Baillieres Clin Obstet Gynaecol 1987;1:697-721.

51. Nieuwint A, Van Zalen-Sprock R, Hummel P, Pals G, Van Vugt J, Van Der Harten H, Heins Y, Madan K. 'Identical' twins with discordant karyotypes. Prenat Diagn 1999;19:72-6.

52. Gilbert B, Yardin C, Briault S, Belin V, Lienhardt A, Aubard Y, Battin J, Servaud M, Philippe HJ, Lacombe D. Prenatal diagnosis of female monozygotic twins discordant for Turner syndrome: implications for prenatal genetic counselling. Prenat Diagn 2002;22:697-702.

53. Nicolini U, Poblete A. Single intrauterine death in monochorionic twin pregnancies. Ultrasound Obstet Gynecol 1999;14:297-301.

54. Denbow ML, Overton TG, Duncan KR, Cox PM, Fisk NM. High failure rate of umbilical vessel occlusion by ultrasound-guided injection of absolute alcohol or enbucrilate gel. Prenat Diagn 1999;19:527-32.

55. Quintero RA, Reich H, Puder KS, Bardicef M, Evans MI, Cotton DB, Romero R: Brief report: umbilical-cord ligation of an acardiac twin by fetoscopy at 19 weeks of gestation. N Engl J Med 1994;330:469-71.

56. Hecher K, Reinhold U, Gbur K, Hackeloer BJ: Interruption of umbilical blood flow in an acardiac twin by endoscopic laser coagulation. Geburtshilfe Frauenheilkd 1996;56:97-100.

57. Nicolini U, Poblete A, Boschetto C, Bonati F, Roberts A. Complicated monochorionic twin pregnancies: experience with bipolar cord coagulation. Am J Obstet Gynecol 2001;185:703-7.

58. Ville Y, Hyett JA, Vandenbussche FP, Nicolaides KH: Endoscopic laser coagulation of umbilical cord vessels in twin reversed arterial perfusion sequence. Ultrasound Obstet Gynecol 1994;4:396-8.

59. Challis D, Gratacos E, Deprest JA: Cord occlusion techniques for selective termination in monochorionic twins. J Perinat Med 1999;27:327-38.

Timely diagnosis of twin-to-twin transfusion syndrome by biweekly ultrasound and patient instructions

Marieke Sueters
Johanna M Middeldorp
Enrico Lopriore
Dick Oepkes
Humphrey HH Kanhai
Frank PHA Vandenbussche

(based on: Ultrasound in Obstetrics and Gynecology 2006;28:659-64)

2

Abstract

Objective: To assess the value of serial ultrasound examinations together with patient instructions to report the onset of symptoms in achieving timely detection of twin-to-twin transfusion syndrome (TTTS) in a cohort of monochorionic diamniotic twin pregnancies, and to evaluate sonographic TTTS predictors.

Methods: Timely detection of TTTS was defined as diagnosis before severe complications of TTTS occurred, such as preterm prelabour rupture of membranes, very preterm delivery (24-32 weeks of pregnancy), fetal hydrops, or intrauterine fetal death. During a 2-year period, a prospective series of 23 monochorionic twin pregnancies was monitored from the first trimester until delivery. At least every 2 weeks we performed ultrasound and Doppler measurements (nuchal translucency thickness, presence of membrane folding, estimated fetal weight, deepest vertical pocket, bladder filling, and Doppler waveforms of the umbilical artery, ductus venosus, and umbilical vein). Measurements of TTTS cases were compared with those of non-TTTS cases matched for gestational age. Furthermore, patients were informed about the symptoms caused by TTTS, and instructed to consult us immediately in case of rapidly increasing abdominal size or premature contractions.

Results: In all four TTTS cases, the diagnosis was timely. At the time of diagnosis, one case was at Quintero Stage 1, two at Quintero Stage 2, and one at Quintero Stage 3.Two of the TTTS cases became apparent after the patients' feeling of rapidly increasing girth. The identification of TTTS predictors was successful with respect to one parameter: isolated polyhydramnios in one sac, without oligohydramnios in the other, preceded the ultimate diagnosis of TTTS in two of the four TTTS cases. All other ultrasound measurements of TTTS cases, prior to the diagnosis of TTTS, were within the range of measurements of non-TTTS cases.

Conclusions: Biweekly ultrasound examinations, with special attention to amniotic fluid compartments of both fetuses, combined with detailed patient instructions to report the onset of symptoms resulted in timely diagnosis of all TTTS cases and appears to be a safe program for monitoring monochorionic twin pregnancies.

Introduction

Twin-to-twin transfusion syndrome (TTTS) occurs in 15% of monochorionic diamniotic twin pregnancies.[1] The syndrome is caused, at least partly, by unbalanced blood flow through vascular placental anastomoses between the twin fetuses, and presents sonographically as an oligo/polyhydramnios sequence. TTTS has been classified into five stages according to Quintero *et al*.[2] Untreated, it is associated with extremely high mortality and morbidity rates.[3-6] In a recent randomised comparison with serial amniodrainage, treatment by fetoscopic laser coagulation of the placental vascular anastomoses was associated with higher perinatal survival rates, more advanced gestational age at delivery and better neurological outcome.[7] Moreover, perinatal survival rates after laser therapy were higher in TTTS stage 1 or 2 than in stage 3 or 4.[7;8] Increasingly, therefore, attention is being paid to the timely diagnosis and treatment of TTTS.

Several studies have focused on the identification of sonographic markers that could forecast the development of TTTS. Sebire *et al* found that pregnancies with increased nuchal translucency thickness in the first trimester and folding of the intertwin membrane in the second trimester are at increased risk of developing TTTS.[1;9;10] Also, the presence of a velamentous umbilical cord insertion and sonographic absence of arterioarterial anastomoses have been found to be more common in pregnancies with TTTS.[11;12] The observation of such TTTS predictors could thus lead to increased surveillance during the pregnancy and hence to the timely detection of TTTS. Absence of these factors, however, does not guarantee that TTTS will not develop.

Symptoms and staging of TTTS are clearly defined, which makes the syndrome, if present, easy to diagnose.[2] Little is known, though, about the optimal surveillance strategy of monochorionic twins in order to detect TTTS before severe complications occur. The first objective of this prospective study was to assess the value of biweekly ultrasound examinations together with patient instructions to report the onset of symptoms in achieving timely detection of TTTS in a cohort of monochorionic diamniotic twin pregnancies. Timely detection was defined as diagnosis before the occurrence of severe

complications of TTTS. Patients were instructed to consult us if they had the impression of rapidly increasing abdominal girth or premature contractions, in which case an ultrasound examination was performed within 24 hours.
The second objective of this study was to assess the prognostic value of nuchal translucency thickness, folding of the intertwin membrane, estimated fetal weight (EFW) and ultrasound markers used for Quintero-staging in the development of TTTS (TTTS-predictors).

Methods

We performed a longitudinal, prospective study of all monochorionic diamniotic twin pregnancies referred to our obstetrical unit during a 2-year period (September 2002 - September 2004). Inclusion criteria were: gestational age below 16 completed weeks and no signs of TTTS at initial ultrasound examination, an absent lambda sign and thin dividing membrane on ultrasound (considered to be evidence of monochorionic diamniotic twinning), and absence of fetal abnormalities. In all cases, gestational age was based on the first day of last menstrual period and confirmed by ultrasound examination in the first or early second trimester. Placental pathological examination was used to confirm monochorionicity after birth.
The study involved serial abdominal ultrasound and Doppler examinations, carried out at least every 2 weeks from when the twin pregnancy was first discovered until delivery. In cases of abnormal ultrasound findings that raised the suspicion of future development of TTTS, the examination frequency was increased. Ultrasound examinations were performed by one of two experienced sonographers. Nuchal translucency thickness was measured only once in the first trimester in cases presenting before 14 weeks, and the following parameters were measured at each examination: folding of the intertwin membrane; EFW; deepest vertical pocket (DVP) of amniotic fluid for each fetus; bladder filling (viewed three times with 10-min intervals and classified as normal, collapsed or enlarged); end-diastolic flow (EDF) of the umbilical artery (UA) (recorded as present, absent or reversed); A-wave in the ductus venosus

(DV) (recorded as present, absent or reversed); flow pattern of the intrahepatic part of the umbilical vein (UV) (classified as pulsatile or non-pulsatile). All measurements were performed in the absence of fetal movements using an Acuson Sequoia (Acuson, Mountain View, California, USA) ultrasound machine with a 4.0- or 6.0-MHz-probe.

TTTS was diagnosed by the presence of oligo/polyhydramnios sequence in the absence of other causes. Polyhydramnios and oligohydramnios were defined as a DVP of amniotic fluid of >8 cm at ≤20 weeks (or >10 cm at >20 weeks) and <2 cm, respectively. TTTS severity was assessed based on Quintero's established criteria[2]: Stage 1, isolated oligo/polyhydramnios sequence; Stage 2, absent visible bladder of the donor twin; Stage 3, critically abnormal Doppler results (absent/reversed EDF of the UA, absent/reversal of flow during atrial contraction in DV, or pulsatile flow pattern of the intra-hepatic part of the UV); Stage 4, hydrops in either fetus; Stage 5, demise of one or both twins. Timely detection of TTTS was defined as diagnosis before the occurrence of severe complications of TTTS, such as preterm prelabour rupture of membranes, very preterm delivery (24-32 weeks of pregnancy), fetal hydrops, or intrauterine fetal death. TTTS diagnosed <26 weeks was treated by fetoscopic laser coagulation of communicating placental vessels. This was always combined with a single amniodrainage procedure. TTTS diagnosed >26 weeks was treated by (repeated) amniodrainage procedure(s). Additionally, patients were informed about the symptoms caused by TTTS and were instructed to consult us immediately in the case of rapidly increasing girth or premature contractions. In this case, sonography was performed as soon as possible (within 24 hours). The institutional review board approved this study and all patients gave informed consent. Pregnancies affected by TTTS were referred to as "TTTS cases", and those not complicated by TTTS were referred to as "non-TTTS cases". In order to identify TTTS predictors, sonographic measurements of TTTS cases were compared with the mean value of non-TTTS cases matched for gestational age. The range of values obtained from non-TTTS cases was considered to be normal. Values of TTTS cases outside this range were considered abnormal.

Results

During the 2-year period, 25 consecutive monochorionic diamniotic twin pregnancies were managed prospectively at our hospital. One pregnancy was excluded from the study because of fetal malformation (lower urinary tract obstruction) followed by selective feticide by cord coagulation. One patient refused to participate in the study because of concerns about the safety of frequent scanning. The remaining 23 patients were included. In total, 268

Table 1 *Pregnancy characteristics for cases with and without twin-to-twin transfusion syndrome (TTTS)*

Characteristic	TTTS (n=4)	non-TTTS (n=19)
Maternal age (years, median (range))	35.0 (33-40)	34.0 (23-39)
Parity (median (range))	4 (1-5)	2 (1-4)
Gestational age (weeks, median (range) at:		
- initial US examination	12.6 (11.3-14.6)	12.3 (11.0-15.6)
- TTTS diagnosis	23.4 (16.9-29.1)	-
- delivery	32.2 (18.3-37.0)	36.1 (19.1-38.7)
Pregnancies (n (%)) with:		
- double perinatal survival	3 (75%)	18 (95%)
- single perinatal survival	0 (0%)	0 (0%)
- no perinatal survival	1 (25%)*	1 (5%)†

**TTTS treated with uncomplicated laser therapy at 16+6 weeks. At 17+6 weeks' gestation, abrupt double intrauterine death was diagnosed. Autopsy was refused. †Sudden double intrauterine death at 19 weeks. At autopsy, one of the fetuses was found to have a frontonasal malformation and left cardiac ventricular hypertrophy with abnormal pulmonary venous return. The other twin was unaffected. US, ultrasound.*

ultrasound examinations of 23 twin pairs were performed. Median number of ultrasound examinations per patient was 12 (range, 4-17).
Four pregnancies (17%) were complicated by TTTS and were diagnosed before the occurrence of severe complications. They were treated by either fetoscopic laser coagulation (n=2), amniodrainage prior to laser therapy 4 weeks later (n=1), or amniodrainage alone (n=1). Two of these four TTTS-cases became apparent after the patient experienced rapidly increasing girth, which made them ask for an extra scan between regular visits. None of the 19 patients without TTTS presented between regular visits with similar complaints. Clinical details of TTTS cases and non-TTTS-cases are given in table 1. All ultrasound findings prior to the diagnosis of TTTS in the four TTTS-cases are given in table 2.

Nuchal translucency thickness >95th centile in at least one of the fetuses was found in 2/16 pregnancies (13%).[13] None of these pregnancies was complicated by TTTS. Folding of the intertwin membrane was seen at least once in six pregnancies (26%), of which one developed TTTS. One other pregnancy with membrane folding had large discrepancies in amniotic fluid (polyhydramnios without oligohydramnios and without other signs suggestive of TTTS) and fetal size that persisted until delivery but did not require any form of treatment.The other 4 cases with membrane folding had an uneventful course. Isolated polyhydramnios without further signs of TTTS was diagnosed in three (13%) pregnancies, of which two went on to develop TTTS. The third pregnancy with polyhydramnios in one sac (maximum DVP, 15.8 cm) was the one mentioned above with intertwin membrane folding that did not develop other signs of TTTS during pregnancy. Prior to the diagnosis of TTTS, TTTS and non-TTTS cases did not differ in: EFW, bladder filling, EDF of the UA, A-wave of the DV, and pulsations of the UV.
The first TTTS case had 2 normal ultrasound examinations until diagnosis of TTTS at 16+6 weeks. At this time, during a routine visit, oligo/polyhydramnios sequence was observed, with a DVP of 1.0 cm and 7.3 cm for donor and recipient, respectively. Also, the donor's bladder was collapsed and the recipient's bladder was enlarged. The flow in the UV was pulsatile. Despite

Table 2 *All ultrasound (US) findings prior to the diagnosis of twin-to-twin transfusion syndrome (TTTS)*

	Case 1	**Case 2**	**Case 3**	**Case 4**
1st ultrasound examination	GA: 12+6, CRL: 7.4/7.4, NT: 0.19/0.14, MF: -, DVP: 3.3/2.9, BF: nl/nl, UA EDF: +/+, pulsatility UV: -/-, DV A-wave: +/+	GA: 12+2, CRL: 4.5/5.0, NT: 0.12/0.13, MF: -, DVP: 2.4/2.1, BF: nl/nl, UA EDF: +/+, pulsatility UV: -/-, DV A-wave: +/+	GA: 14+4, EFW: 113/102, MF: -, DVP: 2.9/4.0, BF: -/-, UA EDF: +/+, pulsatility UV: -/-, DV A-wave: +/+	GA: 11+2, CRL: 4.6/4.5, NT: 0.11/0.15, MF: -, DVP: 3.5/3.5, BF: -/-, UA EDF: +/+, pulsatility UV: -/-, DV A-wave: +/+
2nd ultrasound examination	GA: 14+6, EFW: 113/101, MF: -, DVP: 2.2/3.2, BF: nl/nl, UA EDF: +/+, pulsatility UV: -/-, DV A-wave: +/+	GA: 14+2, CRL: 7.2/8.4, MF: -, DVP: 3.2/2.9, BF: nl/nl, UA EDF: +/+, pulsatility UV: -/-, DV A-wave: +/+	GA: 17+0, EFW: 182/182, MF: -, DVP: 4.8/6.4, BF: nl/nl, UA EDF: +/+, pulsatility UV: -/-, DV A-wave: +/+	GA: 13+2, CRL: 6.9/6.9, MF: -, DVP: 3.9/4.3, BF: nl/nl, UA EDF: +/+, pulsatility UV: -/-, DV A-wave: +/+
3rd ultrasound examination		GA: 16+0, EFW: 145/161, MF: -, DVP: 3.8/3.5, BF: nl/nl, UA EDF: +/+, pulsatility UV: -/-, DV A-wave: +/+	GA: 19+2, EFW: 312/339, MF: -, **DVP:** 3.8/**9.1**, BF: nl/nl, UA EDF: +/+, pulsatility UV: -/-, DV A-wave: +/+	GA: 15+1, EFW: 115/112, MF: -, DVP: 5.8/4.4, BF: nl/nl, UA EDF: +/+, pulsatility UV: -/-, DV A-wave: +/+
4th ultrasound examination		GA: 18+0, EFW: 202/219, MF: -, DVP: 3.7/4.1, BF: nl/nl, UA EDF: +/+, pulsatility UV: -/-, DV A-wave: +/+	GA: 19+4, MF: -, **DVP:** 4.7/**11.2**, BF: nl/nl, UA EDF: +/+, pulsatility UV: -/-, DV A-wave: +/+	GA: 17+1, EFW: 182/182, MF: -, DVP: 4.2/5.9, BF: nl/nl, UA EDF: +/+, pulsatility UV: -/-, DV A-wave: +/+
5th ultrasound examination		GA: 20+0, EFW: 296/314, MF: -, DVP: 4.8/5.1, BF: nl/nl, UA EDF: +/+, pulsatility UV: -/-, DV A-wave: +/+	GA: 20+3, MF: -, **DVP:** 4.7/**10.9**, BF: nl/nl, UA EDF: +/+, pulsatility UV: -/-, DV A-wave: +/+	GA: 18+1, EFW: 181/198, **MF: +**, DVP: 3.4/6.9, BF: nl/nl, UA EDF: +/+, pulsatility UV: -/-, DV A-wave: +/+
6th ultrasound examination			GA: 20+4 (after AR), MF: -, DVP: 4.7/6.5, BF: nl/nl, UA EDF: +/+, pulsatility UV: -/-, DV A-wave: +/+	GA: 19+1, **MF: +**, **DVP:** 4.0/**8.8**, BF: nl/nl, UA EDF: +/+, pulsatility UV: -/-, DV A-wave: +/+
7th ultrasound examination			GA: 21+0, EFW: 369/375, MF: -, DVP: 3.5/9.8, BF: nl/nl, UA EDF: +/+, pulsatility UV: -/-, DV A-wave: +/+	GA: 20+1, EFW: 237/339, **MF: +**, DVP: 3.8/8.6, BF: nl/nl, UA EDF: +/+, pulsatility UV: -/-, DV A-wave: +/+

8th ultrasound examination			GA: 22+2, EFW: 439/474, MF: -, DVP: 6.0/10.0, BF: nl/nl, UA EDF: +/+, pulsatility UV: -/-, DV A-wave: +/+	GA: 21+1, **MF:** +, DVP: 5.0/6.8, BF: nl/nl, UA EDF: +/+, pulsatility UV: -/-, DV A-wave: +/+
9th ultrasound examinationn			GA: 23+2, EFW 477/559, MF: -, **DVP:** 4.7/**10.8**, BF: nl/nl, UA EDF: +/+, pulsatility UV: -/-, DV A-wave: +/+	GA: 22+1, EFW 370/-, **MF:** +, DVP: 4.9/8.4, BF: nl/nl, UA EDF: +/+, pulsatility UV: -/-, DV A-wave: +/+
10th ultrasound examination			GA: 24+2, MF: -, **DVP:** 2.6/**11.9**, BF: nl/nl, UA EDF: +/+, pulsatility UV: -/-, DV A-wave: +/+	GA: 24+1, EFW: 652/606, **MF:** +, DVP: 4.3/8.9, BF: nl/nl, UA EDF: +/+, pulsatility UV: -/-, DV A-wave: +/+
11th ultrasound examination				GA: 26+1, EFW: 716/780, MF: -, **DVP:** 5.6/**10.2**, BF: nl/nl, UA EDF: +/+, pulsatility UV: -/-, DV A-wave: +/+

US findings at diagnosis of TTTS are not included in the table. Values presented in twins as " / " represent values of the future donor / recipient. Abnormal values are indicated in bold. -, absent; +, present; AR, amnioreduction; BF, bladder filling; CRL, crown-rump length (cm); DV, ductus venosus; DVP, deepest vertical pocket (cm); EFW, estimated fetal weight (g); GA, gestational age; MF, membrane folding; nl, normal; NT, nuchal translucency thickness(cm); UA-EDF, umbilical artery end-diastolic flow; UV, umbilical vein.

the DVP of the recipient being <8 cm, the combination of a collapsed and an enlarged bladder together with a critically abnormal Doppler suggested a TTTS Quintero Stage 3. Treatment by laser coagulation of the communicating placental vessels (three arteriovenous anastomoses from donor to recipient) was performed. There were no complications during the procedure. However, at 17+6 weeks' gestation, 1 week after treatment, an abrupt double intrauterine fetal death was diagnosed.

In the second case, TTTS was diagnosed at 22+1 weeks. All five previous ultrasound examinations had been unremarkable. At the regular, biweekly scan at 22+1 weeks' gestation, the DVP of Twin A and Twin B measured 3.7 and 11 cm, respectively. Throughout the 45-min examination, Twin A showed a collapsed bladder and Twin B had normal bladder filling. Doppler measurements were normal. Despite the donor's DVP measuring >2 cm, we considered this case (due to the absence of bladder filling in the donor twin) to be Quintero Stage 2. Treatment with fetoscopic laser coagulation of communicating placental vessels was performed (three arteriovenous anastomoses from donor to recipient and 1 arteriovenous anastomosis from recipient to donor). Spontaneous delivery occurred at 31+5 weeks.

In the third case the first ultrasound examination was at 14+4 weeks' gestation, too late for appropriate nuchal translucency thickness measurement. The first two scans, at 14+4 and 17+0 weeks, showed normal values for both fetuses. Ultrasound examination at 19+2 weeks revealed one of the twins to have a DVP of 9.1 cm, which increased to 11.2 cm at 19+4 weeks. There was, however, no oligohydramnios in the other sac (DVP, 3.8 and 4.7 cm, respectively) and bladder filling and Doppler measurements were within normal ranges for both fetuses. There were no fetal anomalies explaining the increase in amniotic fluid. At 20+3 weeks, effacement of the cervix prompted amniodrainage of 1100 mL and placement of a cerclage. In the next weeks, the recipient twin's DVP increased from 6.5 to 11.9 cm, whereas the donor twin did not develop oligohydramnios. The bladder filling and Doppler studies of both fetuses remained normal. At 24+5 weeks, 3 days after the last ultrasound examination, the woman contacted us with complaints of abdominal distension. At this time, a fetus with polyhydramnios (DVP, 13.5 cm)

and enlarged bladder was seen in one sac; while in the other sac a stuck twin with oligohydramnios (DVP, 0.5 cm) and normal bladder filling was identified (Quintero Stage 1). Laser coagulation of the communicating placental vessels (four arteriovenous anastomoses from donor to recipient) was performed. At 37+0 weeks, labour was induced.

The fourth case was diagnosed at 29+1 weeks. The four ultrasound scans obtained between 11+2 and 17+1 weeks of gestation were uneventful. At the next six weekly ultrasound examinations, between 18+1 and 24+1 weeks' gestation, we observed folding of the intertwin membrane. Other sonographic measurements were unremarkable. The patient came to the hospital between regular visits at 29+1 weeks, one week after the last examination, because of rapidly increasing abdominal size. On ultrasound examination, a stuck twin with oligohydramnios (DVP, 0.8 cm) and collapsed bladder was noted. The recipient twin had polyhydramnios (DVP, 14.0 cm) with an enlarged bladder. Doppler measurements were all normal. A diagnosis of TTTS Quintero Stage 2 was made. Previous ultrasound examinations had already shown an accumulation of amniotic fluid in the recipient's sac (DVP measuring 10.2 cm and 11.7 cm at 26+1 and 28+1 weeks). The amniotic fluid compartment of the donor twin, however, had remained within normal ranges during these previous examinations (5.6 cm at 26+1 and 7.7 cm at 28+1 weeks). Because the gestational age was >26 weeks, this patient was treated by repeated amniodrainage. She delivered spontaneously at 32+4 weeks.

The fetal loss rate was 25% (2/8) for TTTS cases and 5% (2/38) for non-TTTS cases (Table 1). All 42 fetuses that were born alive were structurally normal. At autopsy, one of the demised fetuses of the non-TTTS group was found to have a frontonasal malformation and left cardiac ventricle hypertrophy with abnormal venous pulmonary return. Its demised co-twin was unaffected. For the two fetuses that died after laser therapy, the parents refused autopsy. Monochorionicity of all placentas was confirmed histological.

Discussion

Our study evaluated prospectively the natural history of monochorionic diamniotic twin pairs with regard to the development of TTTS during fetal life. We succeeded in the timely diagnosis of TTTS cases by a program of frequent (biweekly) ultrasound examinations and patient instructions to report the onset of symptoms, diagnosing all TTTS cases before severe complications of TTTS were encountered: there were no cases of preterm prelabour rupture of membranes or very preterm deliveries caused by polyhydramnios, and no cases of fetal hydrops or fetal death. Patient instructions turned out to be highly relevant for the timely detection of TTTS; two of the four TTTS cases in our series became apparent the patient experienced rapidly increasing girth. None of the 19 patients without TTTS presented between their regular scheduled visits with similar complaints. Despite the anxiety during pregnancy that may be associated with patients being informed extensively on all the risks that may be involved with monochorionic twinning, we consider explicit patient instructions to be crucial for the timely detection of TTTS.

We identified the DVP of amniotic fluid was identified as being a TTTS predictor. In two of the four TTTS cases we found isolated polyhydramnios in one sac, without oligohydramnios in the other and with normal bladder filling of both fetuses, preceding the ultimate diagnosis of TTTS. Another pregnancy with polyhydramnios that lacked coexistence of oligohydramnios, however, did not develop TTTS. Polyhydramnios alone must certainly be considered an important sign, possibly indicative of the future development of TTTS, but it should not invariably lead to invasive treatment. We think it is very importance to locate the intertwin membrane and to measure the DVP of each fetus routinely at least every 2 weeks. Accumulation of amniotic fluid should alert obstetricians and lead to increased sonographic surveillance.

None of the other sonographic parameters was found to showed to be predictive of future TTTS. As polyhydramnios in TTTS is thought to originate mainly from excessive urine production of the recipient twin, it could be hypothesized that urinary bladder filling should also be increased. However, prior to diagnosis of TTTS, no differences in fetal bladder size between future

donor and recipient twins were detected in this study. It would be interesting to investigate more extensively whether a discrepancy in fetal urinary production precedes the development of an oligo/polyhydramnios sequence. To explore this properly, a more detailed approach is required.[14]

Although EFW differences have long been abandoned in diagnosing TTTS, there still exists a general belief that donor twins should be smaller than recipients. Formerly, a growth discordance of ≥20% has been used as a diagnostic criterion of TTTS. Such a birth weight difference, however, is seen as frequently in monochorionic as in dichorionic twins.[15] Consequently, a difference in EFW is not considered a mandatory feature of TTTS. Similarly, the Quintero staging system criteria do not include fetal biometry.[2] Differences in EFW are thus not expected to be of any help in forecasting TTTS. This was demonstrated in our study by the EFW of the donor twin exceeding that of the recipient twin in three of the four TTTS cases.

As stated in Quintero *et al*'s criteria, the more advanced stages of TTTS are characterized by critically abnormal Doppler studies of the UA, DV or UV.[2] Assuming that TTTS is the result of long-lasting circulatory imbalance and not a sudden incident, Doppler studies could be expected to deteriorate progressively in the weeks before TTTS is diagnosed. However, in our study we were unable to show differences between TTTS cases and non-TTTS cases in Doppler studies performed prior to the scan revealing TTTS.

We could not confirm findings of previous studies in which ultrasound markers such as nuchal translucency thickness and folding of the intertwin membrane were associated with the development of TTTS. Sebire *et al* suggested that the likelihood ratio of an increased fetal nuchal translucency for the prediction of TTTS was 3.5.[1] Although we found an increased nuchal translucency thickness in at least one fetus in 2/16 pregnancies (13%), which is similar to the frequency in Sebire's series, all four cases that later developed TTTS had normal nuchal translucency thickness values. Another association found by Sebire *et al* was the occurrence of folding of the intertwin membrane with subsequent development of TTTS.[10] In their study, folding occurred in 28% of monochorionic twin pregnancies and resulted in TTTS in 52% of the cases. We found a similar rate (26%) of folding of the intertwin membrane, but only

one of these six pregnancies (17%) was subsequently complicated by TTTS. Interestingly, 3/17 patients without intertwin membrane folding also developed TTTS. Matias *et al* proposed a role for the combination of increased nuchal translucency thickness and abnormal DV flow patterns in anticipating TTTS.[16] This could not be established in our study, since none of the fetuses showed absent or reversed flow of the DV during atrial contraction.

We realise that our study population was relatively small, which may well be the reason for our not confirming findings of larger studies. Our study, though, was unique for its prospective, longitudinal approach. The rarity of monochorionic twinning hampers prospective research in this area. A series of 23 patients may seem rather undersized, but should be considered relatively large in this context. Moreover, we think our study population is representative of a normal monochorionic diamniotic twin cohort. The 17% incidence of TTTS in our series is comparable with the reported 15%.[1] Another potential weakness was the lack of a control group, which leads us to refrains from drawing conclusions about the advantages of a monitoring program. Nevertheless, information on how to manage monochorionic twins is urgently needed and we think our study contributes realistic data to this information gap.

In conclusion, based on our study results, we think combined use of sonography and maternal symptom monitoring forms a safe program for monitoring monochorionic twin pregnancies. Hence, for the timely diagnosis of TTTS cases, we advise biweekly ultrasound examinations, with special attention being paid to the amniotic fluid compartments of both fetuses, combined with detailed patient instructions.

References

1. Sebire NJ, Souka A, Skentou H, Geerts L, Nicolaides KH. Early prediction of severe twin-to-twin transfusion syndrome. Hum Reprod 2000;15:2008-2010.2.

2. Quintero RA, Morales WJ, Allen MH, Bornick PW, Johnson PK, Kruger M. Staging of twin-twin transfusion syndrome. J Perinatol 1999;19:550-555.

3. Patten RM, Mack LA, Harvey D, Cyr DR, Pretorius DH. Disparity of amniotic fluid volume and fetal size: problem of the stuck twin--US studies. Radiology 1989;172:153-157.

4. Berghella V, Kaufmann M. Natural history of twin-twin transfusion syndrome. J Reprod Med 2001;46:480-484.

5. Gul A, Aslan H, Polat I, Cebeci A, Bulut H, Sahin O, Ceylan Y. Natural history of 11 cases of twin-twin transfusion syndrome without intervention. Twin Res 2003;6:263-266.

6. Urig MA, Clewell WH, Elliott JP. Twin-twin transfusion syndrome. Am J Obstet Gynecol 1990;163:1522-1526.

7. Senat MV, Deprest J, Boulvain M, Paupe A, Winer N, Ville Y. Endoscopic laser surgery versus serial amnioreduction for severe twin-to-twin transfusion syndrome. N Engl J Med 2004;351:136-144.

8. Middeldorp JM, Klumper FJ, Oepkes D, Lopriore E, Kanhai HH, Vandenbussche FP. The initial results of fetoscopic laser treatment for severe second trimester twin-to-twin transfusion syndrome in the Netherlands are comparable to international results. Ned Tijdschr Geneeskd 2004;148:1203-1208.

9. Sebire NJ, D'Ercole C, Hughes K, Carvalho M, Nicolaides KH. Increased nuchal translucency thickness at 10-14 weeks of gestation as a predictor of severe twin-to-twin transfusion syndrome. Ultrasound Obstet Gynecol 1997; 10:86-89.

10. Sebire NJ, D'Ercole C, Carvelho M, Sepulveda W, Nicolaides KH. Inter-twin membrane folding in monochorionic pregnancies. Ultrasound Obstet Gynecol 1998; 11:324-327.

11. Fries MH, Goldstein RB, Kilpatrick SJ, Golbus MS, Callen PW, Filly RA. The role of velamentous cord insertion in the etiology of twin-twin transfusion syndrome. Obstet Gynecol 1993; 81:569-574.

12. Taylor MJ, Denbow ML, Tanawattanacharoen S, Gannon C, Cox PM, Fisk NM. Doppler detection of arterio-arterial anastomoses in monochorionic twins: feasibility and clinical application. Hum Reprod 2000; 15:1632-1636.

13. Nicolaides K, Sebire N, Snijders R. The 11-14-week scan: The diagnosis of fetal abnormalities. The Parthenon Publishing Group Inc, 1999.

14. Rabinowitz R, Peters MT, Vyas S, Campbell S, Nicolaides KH. Measurement of fetal urine production in normal pregnancy by real-time ultrasonography. Am J Obstet Gynecol 1989; 161:1264-1266.

15. Danskin FH, Neilson JP. Twin-to-twin transfusion syndrome: what are appropriate diagnostic criteria? Am J Obstet Gynecol 1989; 161:365-369.

16. Matias A, Montenegro N, Areias JC. Anticipating twin-twin transfusion syndrome in monochorionic twin pregnancy. Is there a role for nuchal translucency and ductus venosus blood flow evaluation at 11-14 weeks? Twin Res 2000; 3:65-70.

Fetoscopic laser surgery in 100 pregnancies with severe twin-to-twin transfusion syndrome in the Netherlands

Johanna M Middeldorp
Marieke Sueters
Enrico Lopriore
Frans JCM Klumper
Dick Oepkes
Roland Devlieger
Humphrey HH Kanhai
Frank PHA Vandenbussche

(based on: Fetal Diagnosis and Therapy, 2007;22:190-194)

3

Abstract

Objective: In this prospective cohort study we evaluated the initial results of fetoscopic laser surgery for severe second trimester twin-to-twin transfusion syndrome (TTTS) treated at our centre.

Methods: A total of 100 consecutive pregnancies with severe second trimester TTTS treated at our centre with selective fetoscopic laser coagulation of vascular anastomoses on the placental surface between August 2000 and November 2004 were included in the study. Perinatal survival was analysed in relation to Quintero stage.

Results: Median gestational age was 20 weeks at fetoscopy (range 16-26) and 33 weeks at delivery (range 18-40). Perinatal survival rate was 70% (139/200). The treatment resulted in at least one survivor at the age of 4 weeks in 81% of pregnancies. Perinatal survival was significantly higher when treatment was performed in the early Quintero stages (95% in stage 1, 76% in stage 2, 70% in stage 3, 50% in stage 4) (p=0.02).

Conclusions: Results of fetoscopic laser surgery for TTTS in our centre are similar to those in specialised centres in other countries. Diagnosis and treatment in the early Quintero stages resulted in significantly higher perinatal survival.

Introduction

Monochorionic twin pregnancies are at risk for developing twin-to-twin transfusion syndrome (TTTS) due to unbalanced inter-twin blood-flow through placental vascular anastomoses. TTTS may occur in 10-15% of monochorionic twin pregnancies, mostly in the second trimester of pregnancy.[1] The first sonographic signs of TTTS are oliguria in the donor, resulting in oligohydramnios in the donor sac, and polyuria in the recipient, resulting in a polyhydramnios in the recipient sac. Hereafter, more severe signs may occur such as anuria, heart failure, hydrops and single or double fetal demise. Premature contractions or preterm rupture of membranes, leading to preterm birth, may result from the polyhydramnios. Quintero proposed a staging system to classify the severity of the syndrome.[2]

Until recently, it was unclear which treatment modality provided the best result in TTTS. Serial amnioreduction is a symptomatic treatment for TTTS that has been used for more than two decades. The transient reduction of amniotic fluid reduces pressure on the placenta with improvement of transplacental fluid flow between mother and fetus, and reduces the risk of preterm delivery.[3] More recently, a cause-oriented approach for TTTS was developed in the United States and the United Kingdom: fetoscopic laser coagulation of vascular anastomoses on the placental surface.[4-6] A recent randomised trial reported significantly higher perinatal survival and improved neurological outcome in TTTS survivors after fetoscopic laser surgery compared to serial amnioreduction.[7]

The number of TTTS pregnancies in the Netherlands, with 200,000 births annually, is estimated to be 60-90 per year. At Leiden University Medical Centre, the national referral centre for invasive fetal therapy, fetoscopic laser surgery has been the preferred treatment modality since August 2000. We report the perinatal outcome after fetoscopic laser surgery of a consecutive series of 100 pregnancies complicated by severe second trimester TTTS.

Methods

Inclusion criteria for fetoscopic laser surgery were: monochorionic twin pregnancy, gestational age between 16 and 26 weeks, not in labour, no congenital malformations, TTTS Quintero stage 1 with severe clinical symptoms of polyhydramnios, or TTTS Quintero stage ≥ 2. Before fetoscopy, detailed sonographic evaluation was performed to exclude congenital anomalies, to confirm the diagnosis of TTTS, and to determine the Quintero stage. The sonographic investigation included: fetal anatomy and biometry, deepest vertical pocket of amniotic fluid of each fetus, bladder filling, arterial and venous Doppler studies, placental location, location of umbilical cord insertions, and cervical length. On the basis of these findings, an estimation of the location of the vascular equator and the optimal insertion site of the fetoscope in the uterine wall was made. In the majority of cases, fetoscopic laser surgery was performed under regional anaesthesia, but in some cases with anterior placenta general anaesthesia was used. A prophylactic dose of tocolytics (indomethacin) and antibiotics (amoxycillin/clavulanate) was given routinely. In 85 women, the 2 mm semi rigid fetoscope (Storz, Vianen, the Netherlands) was introduced percutaneously in the sac of the recipient through a straight or curved (up to 40 degrees) shaft with an outer diameter of 3.3 mm. In 8 cases with an anterior placenta a small (3-5 cm) laparotomy was performed in the lateral abdominal wall near the mid-axillary line, between the lower ribs and the iliac crest. After opening the peritoneum, bowels were moved aside with gauze and the lateral uterine vessels were identified. The shaft was then inserted through the posterior uterine wall in order to obtain a perpendicular angle between the fetoscope and the vascular equator. In 7 women, introduction of the shaft in the posterior uterine wall was assisted by open entry laparoscopy instead of mini laparotomy. After introduction of the fetoscope, vessels crossing the inter-twin membrane were followed to identify the anastomotic vessels in the recipient's sac. When it could be confirmed that these crossing vessels belonged to just one twin, they were left intact. All vessels that connected to vessels of the other twin were coagulated by laser light (diode laser (Diomed Limited, Cambridge, UK) or ND:YAG laser

(Dornier Medizin Technik, Germering, Germany)). Isolated arteries and veins, coming from the recipient and crossing the inter-win membrane, that could not be followed any further, were also coagulated.[7;8] Finally, amniotic fluid was drained until the deepest vertical pool was less than 6 cm. During the procedure, fetal condition was evaluated continuously by ultrasound.

Percentage of fetal survival was defined as 100 x number of live born children/2 x number of pregnancies. Percentage of perinatal survival was defined as 100 x number of children alive at 4 weeks/2 x number of pregnancies. Differences in outcome between Quintero stages were analysed with Chi square test (linear by linear association). A p-value < 0.05 was considered to indicate a statistical significance. Statistical analysis was performed with SPSS version 11.0 (SPSS, Inc., Chicago, Illinois, USA).

Results

From August 2000 until November 2004, a consecutive series of 100 pregnancies complicated by severe second trimester TTTS were included in the study: 10 with Quintero stage 1 (10%), 42 with stage 2 (42%), 41 with stage 3 (41%) and 7 with stage 4 (7%). The median gestational age at intervention was 20 weeks (range 16-26). There were no cases of intra-amniotic bleeding that prevented completion of surgery. Rupture of membranes within 2 weeks of the procedure occurred in 13/100 (13%) cases. In 2 of these 13 cases there were clinical signs of chorioamnionitis. Of the 13 cases, 8 pregnancies ended within two weeks after the fetoscopic procedure and resulted in death of both fetus. The remaining 5 pregnancies resulted in at least one survivor at 4 weeks of age.

One woman suffered from a short episode of pulmonary oedema directly after laser procedure and was treated with oxygen and diuretics. Another woman presented a few months after delivery with complaints of bowel herniation in the mini-laparotomy scar. There were no other maternal complications.

In five pregnancies (5%), polyhydramnios recurred, either in the sac of the former recipient (recurrence n=2) or in the sac of the former donor (reversal n=3). In two of these cases re-intervention with laser coagulation of the residual anastomoses was performed, both at 20 weeks. In the other three cases, caesarean section was performed at 29, 31 and 31 weeks, respectively. Table 1 shows a comparison of the results of our series with those of other published series.[7-10] Follow-up was complete until 4 weeks after birth. In our series, the incidence of single intrauterine fetal demise was 17% (17/100) (12 former recipients and 5 former donors). The incidence of miscarriage was 14% and the incidence of double intrauterine demise was 4%. The overall incidence of fetal

Table 1 *Comparison of perinatal outcome after fetoscopic laser surgery in the Leiden University Medical Centre with other published series[7-10]*

	present study† ***N=100***	***De Lia†*** **1999[9]** ***N=67***	***Hecher†*** **2000[8]** ***N=200***	***Quintero†*** **2003[10]** ***N=95***	***Senat**** **2004[7]** ***N=72***
median gestational age at delivery	33	31	34	32	33
2 survivors (%)	58/100 (58%)°	38/67 (57%)°	100/200 (50%)°°	43/95 (45%)°	26/72 (36%)°°
1 survivor (%)	23/100 (23%)°	17/67 (25%)°	61/200 (30%)°°	36/95 (38%)°	29/72 (40%)°°
0 survivors (%)	19/100 (19%)°	12/67 (18%)°	39/200 (20%)°°	16/95 (17%)°	17/72 (24%)°°
neonatal death (%)	8/200 (4.0%)	5/134 (3.7%)	15/400 (3.8%)	14/190 (7.4%)	11/144 (7.6%)

† *cohort studies*
* *randomised controlled trial*
° *survival at 4 weeks*
°° *survival at 6 months*

demise was thus 53% (53/200). Most fetal losses (81%, 43/53) occurred within 4 weeks after the initial treatment.
Neonatal death occurred in 8 children. Overall perinatal mortality was 61/200 (30%). Perinatal survival of at least one child occurred in 81% (81/100) of TTTS pregnancies. There were no significant differences in perinatal survival according to placental localisation. Survival of at least one child was 30/38 (79%, 95% CI 63-89) in anterior (complete or partial), and 51/62 (82%, 95% CI 71-90) in posterior placental localisation. Table 2 shows the pregnancy outcome by Quintero-stage. Perinatal outcome was significantly better in the early Quintero stages (p=0.02).

Table 2 *Pregnancy outcome after fetoscopic laser surgery for severe TTTS in the Leiden University Medical Centre by Quintero stage.*

Stage by Quintero[2]	**1** **N=10**	**2** **N=42**	**3** **N=41**	**4** **N=7**
median gestational age at delivery	35	33	33	33
2 survivors at birth (%)	9/10 (90%)	29/42 (69%)	24/41 (59%)	3/7 (43%)
1 survivor at birth (%)	1/10 (10%)	6/42 (14%)	9/41 (22%)	1/7 (14%)
0 survivors at birth (%)	0/10 (0%)	7/42 (17%)	8/41(19%)	3/7 (43%)

(chi-square test, linear-by-linear association p=0.02)

Discussion

We report the initial results of fetoscopic laser coagulation of vascular anastomoses for severe TTTS at our centre. In 81% of pregnancies, laser treatment resulted in the birth of at least one surviving child. These results are similar to those of other published large series.[7-10] In contrast to Quintero *et al* who reported that stage is not an important prognostic factor when laser therapy is involved, we found that the earlier the stage at the time of treatment, the better the outcome.[10] Double perinatal survival decreased

from 90% in Quintero stage 1 to 43% in Quintero stage 4. Our findings are in accordance with the results of a recent study reporting significantly better perinatal outcome of fetoscopic laser surgery in Quintero stage 1 and 2 as compared to stage 3 and 4.[7]

In untreated severe TTTS, perinatal survival rate is reported to range between 20% and 37%.[11-13] In treated severe TTTS, with serial amnioreduction or fetoscopic laser coagulation of vascular anastomoses, perinatal survival rates increase up to 57% and 66%, respectively.[13] The incidence of neurological sequelae in TTTS is also related to the prenatal treatment modality. Severe neurological damage is found in 25% of survivors without prenatal treatment, in 16-22% in survivors after serial amniodrainage, and 5-11% after fetoscopic laser surgery.[11;13-17] In a recent randomised multi-centre study, Senat *et al* found significantly better outcomes after fetoscopic laser surgery compared to serial amnioreduction. Survival of at least one twin at the age of six months was 51% in the amnioreduction group and 76% in the laser group (p=0.002). At the age of six months, major neurological sequelae were found in 19% of the surviving children after amnioreduction and in 7% after laser surgery (p=0.05). The overall higher mortality rate in this randomised trial in comparison with cited retrospective studies is probably due to a higher proportion of severe TTTS cases included, and to the fact that the authors followed the intention-to-treat principle with inclusion of cases where intra-uterine death occurred between the moment of randomisation and treatment.[7;12;13]

In our centre, fetoscopic laser surgery was started in August 2000. To optimise the learning curve, each procedure was attended by two of the four operators. To evaluate the results of laser surgery we routinely perform placental injection study with coloured dye. The presence of four operators (presently FK, DO, FV, JM) guarantees the availability of at least one operator at all times, an obvious necessity for a national referral centre. In a recent editorial, Fisk *et al* debated the feasibility of fetoscopic laser surgery. They concluded that widespread adoption of this challenging and difficult procedure by fetal specialists without adequate training in endoscopy and placental

vascular anatomy has the potential to do more harm than good[18]. The results of fetoscopic laser treatment in our centre were from the beginning of the fetoscopy program comparable to those reported in the literature.[19] We think, our results positively underline the statement of Fisk *et al.*[18] Setting up a fetoscopic laser surgery program in a centre for fetal therapy is feasible, provided that adequate training is given, that operators receive feed-back by studying placental vascular anatomy after birth, that enough operators are available to run a 24 hours service, and that a minimum of 30 procedures per year are performed to ensure the maintenance of skills. The aim of each fetoscopic laser surgery program should also include accurate evaluation of short-term and long-term paediatric outcome. We have recently reported on the neonatal and short-term neurological outcome in TTTS treated with laser surgery at our centre.[20;21] Long-term neurodevelopmental outcome at 2 years of age is currently being evaluated.

In our study, treatment in earlier Quintero stages resulted in significantly better outcome. Care should be taken when interpreting these results. A potential bias could be that not all early Quintero stages necessarily progress to higher stages. Luks *et al* studied natural evolution of 18 TTTS women in week-to-week evaluations and found no change in 72%, down-staging in 12% and up-staging in 15%.[22] To prevent over-treatment in the 10-15% of cases that show spontaneous improvement, early TTTS stages can be followed closely, with laser treatment only in case of progression. On the other hand, waiting for TTTS to progress to higher stages may involve an increased risk of mortality and morbidity. It is still unknown, however, whether neurological damage in monochorionic twins treated with fetoscopic laser surgery occurs before, during or after laser surgery. As shown in a recent study, monochorionic twins without TTTS already are at considerable risk of developing neurological morbidity[23]. Thus, whether treatment in the early Quintero stages results in better outcome and prevents neurological morbidity can only be clarified in a randomised controlled trial between early laser and waiting for progression. Such a trial is urgently needed.

Conclusion

Perinatal outcome in TTTS after fetoscopic laser coagulation of vascular anastomoses treated at our centre was similar to that in specialised foreign centres. Perinatal survival was significantly higher after laser surgery in the early Quintero stages.

References

1. Sebire NJ, Souka A, Skentou H, Geerts L, Nicolaides H. Early prediction of severe twin-to-twin transfusion syndrome. Hum Reprod 1997;15:2008-10.

2. Quintero RA, Morales WJ, Allen MH, Bornick PW, Johnson PK, Kruger M. Staging of twin-twin transfusion syndrome. J Perinatol 1999;19:550-5.

3. Umur A, van Gemert MJC, Ross MG. Fetal urine and amniotic fluid in monochorionic twins with twin-twin transfusion syndrome: Simulation of therapy. Am J Obstet Gynecol 2001;185:996-1003.

4. De Lia JE, Cruikshank DP, Keye WR Jr. Fetoscopic neodymium:YAG laser occlusion of placental vessels in severe twin-twin transfusion syndrome. Obstet Gynecol. 1990;75:1046-53.

5. De Lia JE, Kuhlman RS, Harstad TW, Cruikshank DP. Fetoscopic laser ablation of placental vessels in severe previable twin-twin transfusion syndrome. Am J Obstet Gynecol 1995;172:1202-11.

6. Ville Y, Hyett J, Hecher K, Nicolaides K. Preliminary experience with endoscopic laser surgery for severe twin-twin transfusion syndrome. N Engl J Med 1995;332:224-7.

7. Senat MV, Deprest J, Boulvain M, Paupe A, Winer N, Ville Y. Endoscopic laser surgery versus serial amnioreduction for severe twin-to-twin transfusion syndrome. N Engl J Med 2004;351:136-44.

8. Hecher K, Diehl W, Zikulnig L, Vetter M, Hackeloer BJ. Endoscopic laser coagulation of placental anastomoses in 200 pregnancies with severe mid-trimester twin-to-twin transfusion syndrome. Eur J Obstet Gynecol Reprod Biol 2000;92:135-9.

9. De Lia JE, Kuhlmann RS, Lopez KP. Treating previable twin-twin transfusion syndrome with fetoscopic laser surgery: Outcomes following the learning curve. J Perinat Med 1999;27:61-7.

10. Quintero RA, Dickinson JE, Morales WJ, Bornick PW, Bermudez C, Cincotta R, Chan FY, Allen MH. Stage-based treatment of twin-twin transfusion syndrome. Am J Obstet Gynecol 2003;188:1333-40.

11. Haverkamp F, Lex C, Hanisch C, Fahnenstich H, Zerres K. Neurodevelopmental risks in twin-to-twin transfusion syndrome: preliminary findings. Eur J Paediatr Neurol 2001;5:21-27.

12. Lewi L, van Schoubroeck D, Gratacos E, Witters I, Timmerman D, Deprest J. Monochorionic diamniotic twins:complications and management options. Curr Opin Obstet Gynecol 2003;15:177-94.

13. Van Gemert JC, Umur A, Tijssen JGP, Ross MG. Twin-twin transfusion syndrome: etiology, severity and rational management. Curr Opin Obstet Gynecol 2001;13:193-206.

14. Sutcliffe AG, Sebire NJ, Pigott AJ, Taylor B, Edwards PR, Nicolaides KH. Outcome for children born after in utero laser ablation therapy for severe twin-to-twin transfusion syndrome. BJOG 2001; 108:1246-50.

15. Banek CS, Hecher K, Hackeloer BJ, Bartmann P. Long-term neurodevelopmental outcome after intrauterine laser treatment for severe twin-twin transfusion syndrome. Am J Obstet Gynecol 2003;188:876-80.

16. Cincotta RB, Gray PH, Phytian G, Rogers YM, Chan FY. Long term outcome of twin-twin transfusion syndrome. Arch Dis Child Fetal Neonatal Ed 2000;83:F171-6.

17. Lopriore E, Nagel HTC, Vandenbussche FPHA, Walther FJ. Long-term neurodevelopmental outcome in twin-to-twin transfusion syndrome. Am J Obstet Gynecol 2003;189:1314-9.

18. Fisk NM, Galea P. Twin-twin transfusion – As good as it gets? N Eng J Med 2004;351;2:182-4.

19. Middeldorp JM, Klumper FJ, Oepkes D, Lopriore E, Kanhai HH, Vandenbussche FP. The initial results of fetoscopic laser treatment for severe second trimester twin-to-twin transfusion syndrome in the Netherlands are comparable to international results. Ned Tijdschr Geneeskd 2004;148:1203-08.

20. Lopriore E, Sueters M, Middeldorp JM, Oepkes D, Vandenbussche FP, Walther FJ. Neonatal outcome in twin-to-twin transfusion syndrome treated with fetoscopic laser occlusion of vascular anastomoses. J Pediatr 2005;147:597-602.

21. Lopriore E, Wezel-Meijler G, Middeldorp JM, Sueters M, Vandenbussche FP, Walther FJ. Incidence, origin and character of cerebral injury in twin-to-twin transfusion syndrome treated with fetoscopic laser surgery. Am J Obstet Gynecol 2006;194:1215-20.

22. Luks FI, Carr SR, Plevyak M, Craigo SD, Athanassiou A, Ralston SJ, Tracy Jr. TF. Limited Prognostic Value of a Staging System for Twin-to-Twin Transfusion Syndrome. Fetal Diagn Ther 2004;19:301-4.

23. Adegbite AL, Castille S, Ward S, Bajoria R. Neuromorbidity in preterm twins in relation to chorionicity and discordant birth weight. Am J Obstet Gynecol. 2004:190;156-63.

Residual anastomoses after fetoscopic laser surgery in twin-to-twin transfusion syndrome: frequency, associated risks and outcome

Enrico Lopriore
Johanna M Middeldorp
Dick Oepkes
Frans J Klumper
Frans J Walther
Frank PHA Vandenbussche

4

(based on: Placenta 2007;28:204-8)

Abstract

Objective: To study the incidence and clinical implications of residual anastomoses in twin-to-twin transfusion syndrome treated with fetoscopic laser surgery

Methods: We examined all placentas treated with fetoscopic laser surgery and delivered at our centre between June 2002 and December 2005 with vascular injection using coloured dyes. Presence of residual anastomoses was studied in association with adverse outcome and inter-twin haemoglobin difference at birth. Adverse outcome was defined as fetal demise, neonatal death or severe cerebral injury. The relation between residual anastomoses and placental localization (anterior or posterior uterine wall) was evaluated.

Results: A total of 52 laser-treated placentas were studied. Residual anastomoses were detected in 33% (17/52) of placentas. Adverse outcome was similar in the groups with and without residual anastomoses, 18% (6/34) and 29% (20/70) respectively ($p = 0.23$). Large inter-twin haemoglobin differences (> 5 g/dL) were found in 65% (11/17) of cases with residual anastomoses and 20% (7/35) of cases without residual anastomoses ($p < 0.01$). Anterior placental localization was not associated with a more frequent presence of residual anastomoses.

Conclusions: Residual anastomoses at our institution are seen in one third of monochorionic placentas treated with fetoscopic laser surgery. Although residual anastomoses in our study were not associated with adverse outcome, they were often associated with neonatal haematological complications.

Introduction

Twin-to-twin transfusion syndrome (TTTS) presenting as oligo/polyhydramnios sequence is a major complication of monochorionic twin pregnancies and is due to inter-twin blood transfusion via placental vascular anastomoses. Fetoscopic laser coagulation of placental vascular anastomoses is nowadays considered to be the treatment of choice in severe second trimester TTTS. Fetoscopic laser surgery in TTTS is a causative treatment and is associated with significantly improved outcome compared to serial amniodrainage.[1]
The aim of laser coagulation of vascular anastomoses is to completely separate the inter-twin placental circulation. Careful examination of the placenta after birth through injection studies is required to determine whether all vascular connections have been adequately coagulated or whether residual anastomoses (RA) are still present.
Although the first report of fetoscopic laser surgery was published more than 15 years ago[2], only few studies have since reported on the placental findings and incidence of RA after laser surgery.[3-6] Most importantly, the results of these studies are highly discordant and the incidence or RA varied from 0% to 75%.[3-6]
The objective of our study was to determine the incidence and clinical implications of RA in a large series of placentas treated with fetoscopic laser surgery. We hypothesized that the presence of RA may lead to a higher incidence of adverse outcome and larger inter-twin haemoglobin difference at birth. Furthermore, we tested the hypothesis that RA may be found more frequently in anterior placentas due to the more complex approach in these cases.

Material and methods

All consecutive placentas of monochorionic twin pregnancies with TTTS treated with fetoscopic laser surgery and delivered at our centre between June 2002 and December 2005 were included in the study. The Leiden University Medical Centre is the national referral centre for laser treatment for TTTS in the Netherlands. TTTS was diagnosed using standard antenatal ultrasound criteria.[7] The fetoscopic laser surgery technique used was described in detail previously and is similar to the method reported by Hecher *et al* and Senat *et al.*[1;8;9]
After birth, presence of RA was studied by placental coloured dye injection. The umbilical vessels of both cords were injected with different-coloured dyes (blue or green for arteries and orange or yellow for veins). Injection was continued until dye was seen to flow through the distal end of the vascular tree and into the placental substance. Placentas were then photographed in a plane view, and the picture was saved in a computerized data base. Placentas were divided in two groups, a group with RA and a group without RA. Placentas of TTTS pregnancies with single or double intrauterine fetal demise were excluded when placental maceration prohibited accurate evaluation of RA.
Adverse outcome was defined as intrauterine fetal demise, neonatal death or severe cerebral injury on neonatal ultrasound examination. The criteria used for determining severe cerebral injury were published in a previous study.[10] Haemoglobin was measured at birth from cord blood. Anaemia and polycythemia at birth were defined as previously described.[11]
Results of categorical variables were compared using Chi-squared test. Continuous variables were analysed with the Independent Samples T- test. A p-value< 0.05 was considered to indicate a statistical significance. Statistical analysis was performed with SPSS version 11.0 (SPSS, Inc., Chicago, Illinois, USA).

Results

A total of 61 monochorionic placentas of TTTS pregnancies treated with laser were examined at our centre during the study period. Overall perinatal mortality was 21% (26/122: intrauterine fetal demise, n= 18; neonatal death, n = 8). The data required for this study could not be recorded completely for nine placentas due to maceration caused by single intrauterine fetal demise (n = 8) or placental fragmentation (n = 1). These nine cases were excluded from further analysis. Fifty-two placentas were thus included in the study. RA were found in 33% (17/52) of laser treated placentas. A total of 39 RA were detected, with an average of 2.3 (±1.7) RA per placenta. The type of RA detected were arterio-venous anastomoses from donor to recipient (n = 16), arterio-venous anastomoses from recipient to donor (n = 16), arterio-arterial anastomoses (n = 4) and veno-venous anastomoses (n = 3). Some placentas with RA (5/17) had multiple types of anastomoses. Twenty-five of the 39 (64%) RA were very small (< 1 mm diameter) (example shown in Figure 1 and 2). Superficial arterio-arterial or veno-venous anastomoses were found in 35% (6/17) of placentas with RA. Adverse outcome occurred in 8% (1/12) of infants with superficial RA compared to 23% (5/22) in infants with only deep arterio-venous RA (p = 0.39). Further details on placentas, vascular anastomoses and clinical outcomes in the RA group and no-RA group are presented in Table 1. The ten cases of intrauterine fetal demise in the no-RA group were all double demises: 4 pairs of twins died within 2 weeks of laser surgery and one pair of twins died 6 weeks after laser surgery.

In two of the 17 (12%) cases in the RA group, the presence of RA had already been predicted by the fetoscopic operator. In the first case a large arterio-arterial anastomosis was detected during fetoscopy but could not be coagulated due to its size. In the second case, surgery was complicated by intra-amniotic haemorrhage impeding further intervention due to blood-stained amniotic fluid. In two other cases (12%), presence of RA was suspected during the weeks following intervention because of fetal Doppler measurements (high middle cerebral artery peak systolic velocity (MCA-PSV) in one fetus). In the first case there was persistence of feto-fetal transfusion, in the second case there

Table 1 *Characteristics of TTTS pregnancies with and without residual anastomoses*

	RA[e] group (n = 17 twin pairs)	no-RA[e] group (n = 35 twin pairs)	p-value
Gestational age at laser surgery – weeks[a]	19.9 ± 4.1	20.6 ± 3.2	0.51
Anterior placenta[b]	5 (29%)	11 (31%)	0.83
Number of anastomoses coagulated per placenta[a]	7.2 ± 4.5	6.0 ± 2.6	0.23
Gestational age at birth – weeks[a]	31.8 ± 3.2	31.1 ± 5.2	0.61
Birth weight – g[a,c]	1718 ± 608	1633 ± 855	0.60
Inter-twin birth weight difference > 20%[b]	7 (41%)	11 (31%)	0.49
Intrauterine fetal demise[b,c]	0 (0%)	10 (14%)	0.02
Neonatal death[b,c]	1 (3%)	6 (9%)	0.28
Severe cerebral injury[b,c]	6 (18%)	7 (10%)	0.27
Adverse outcome[b,c,d]	6 (18%)	20 (29%)	0.23

[a] *Value given as mean ± SD*
[b] *Percentages are between brackets*
[c] *Refers to single infants instead of twin pair*
[d] *Adverse outcome was defined as intrauterine fetal demise, neonatal death or severe cerebral injury*
[e] *RA: residual anastomoses*

Table 2 *Haemoglobin values at birth in TTTS pregnancies with and without residual anastomoses*

	RA[c] group (n = 17 twin pairs)	no-RA[c] group (n = 35 twin pairs)	p-value
Haemoglobin – g/dL[a]	15.4 ± 5.6	16.0 ± 3.8	0.60
Anaemia in one twin[b]	9 (26%)	8 (11%)	0.06
Polycythaemia in one twin[b]	4 (12%)	2 (3%)	0.07
Inter-twin haemoglobin difference > 5 g/dL[b]	11 (65%)	7 (20%)	< 0.01
Twin pairs with anaemia or polycythaemia[b]	10 (59%)	8 (23%)	0.01

[a] *Value given as mean ± SD*
[b] *Percentages are between brackets*
[c] *RA: residual anastomoses*

was a reversal of feto-fetal transfusion. In the remaining 13 cases (76%), RA had not been suspected antenatally.

The results of haematological values at birth are presented in Table 2.

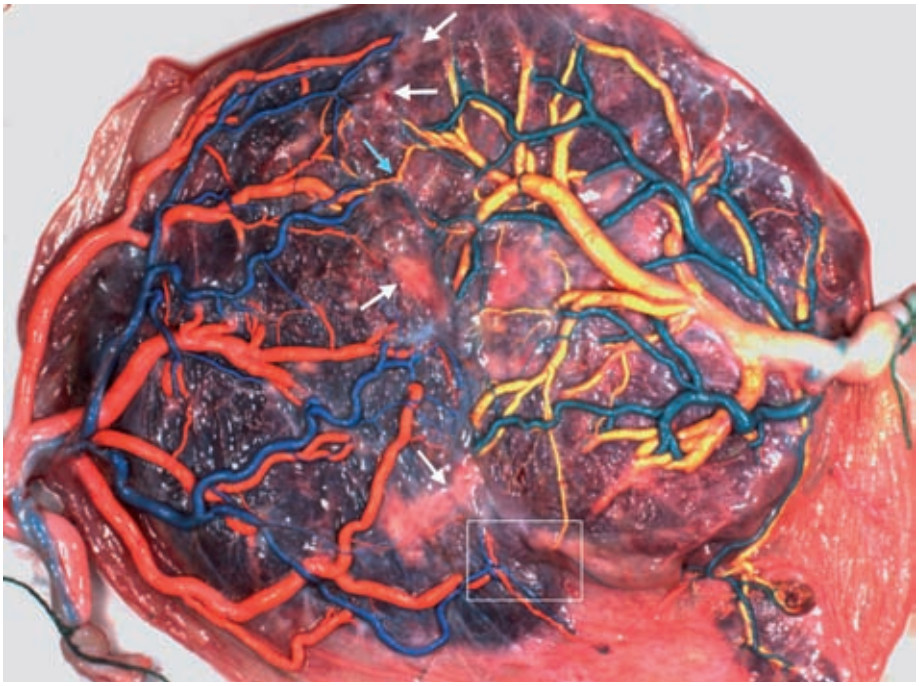

Figure 1*Placenta of TTTS-pregnancy treated with laser at 17 week's gestation, followed by spontaneous delivery of 2 healthy girls at 38 weeks. The placental share of the ex-donor (birth weight 3055 gr) is on the left-side of the picture (arteries are blue, veins are orange). The placental share of the ex-recipient (birth weight 2915 gr) is on the right-side (arteries are green, veins are yellow). Haemoglobin level in the ex-donor and ex-recipient were 13.2 g/dL and 19.2 g/dL respectively. The white arrows indicate the successfully coagulated anastomoses. The light blue arrow indicates a residual veno-venous anastomosis. A very small residual arterio-venous anastomosis from the ex-donor to the ex-recipient is in the white square that is enlarged in Figure 2.*

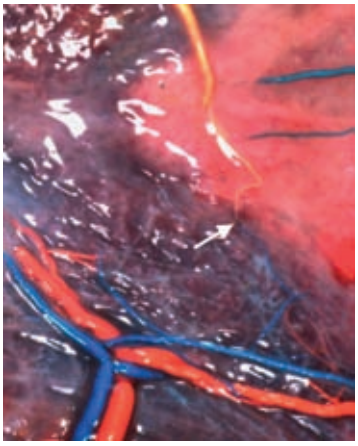

Figure 2 *Detail of the very small residual anastomosis (diameter < 1 mm) between an artery (blue) from the ex-donor and a vein (yellow) from the ex-recipient.*

Discussion

This study is the first large single centre study reporting on the frequency and clinical implications of RA after fetoscopic laser surgery. We found that RA are present in one third of laser treated placentas. In a small study, De Paepe *et al* found a much higher incidence of RA in laser treated placentas, namely 75%.[3] Quintero *et al*, on the other hand, described a much lower incidence of RA, ranging from 0% to 5%.[4-6] Such an extreme discrepancy between the various studies can be due to several factors, namely (1) number of placentas studied, (2) differences in laser technique and surgical results and (3) differences in placental injection techniques. Obviously, no reliable conclusions on incidence of RA can be drawn if the number of studied placentas is too small. De Paepe et al, for example, were able to study only 8 placentas.[3] The second factor, adequate identification and successful coagulation of vascular anastomosis, probably depends on the ability of each fetal surgeon. Hecher *et al* reported an association between improved outcome and growing experience in the laser technique, possibly attributable to an improved efficiency in laser surgery.[9] However, the relation between RA and inter-individual or inter-centre variation in fetoscopic laser surgery has not been studied. Nevertheless, we have

previously shown that the overall outcome after laser surgery in our centre is similar to that in other large centers.[8] Finally, the third factor, differences in placental injection technique, may influence the results on the incidence of RA. Discordant opinions on the sensitivity of various injection methods have recently resulted in a fierce debate in the literature.[12] Quintero *et al* performed placental injection studies with air and claimed that this method has similar sensitivity compared to other methods.[6;13] Most other authors, as well as our group, advocate placental injection with coloured dye.[3;14-19] Which of the two methods (air injection or coloured dye injection) is superior in detecting RA is not known. However, in our experience, the vast majority of RA are very small (with diameters < 1mm) and therefore difficult to detect without accurate injection with coloured dye.

Several reasons can be envisaged to explain the occurrence of RA, namely (1) anastomoses (particularly the minuscule ones) were not detected during fetoscopy, (2) anastomoses were not coagulated because surgery was too selective in order to spare cotyledons, (3) placental vessels of the donor were collapsed due to hypovolemia and vasoconstriction preventing adequate detection, (4) insufficient coagulation led to temporary anastomotic flow obstruction, but revascularization occurred later, and (5) anastomoses were detected during fetoscopy, but were considered too large to tackle. These reasonings may have consequences for the laser surgery technique. If (1), (2) or (3) are true, RA can be avoided using a technique of complete coagulation (with a 5 mm width) of the entire vascular equator. If (4) is true, then RA can be avoided by creating sufficient placental damage using a technique of deeper, longer-lasting and more frequent coagulation.

This study shows that, despite the fact that laser surgery in anterior placentas is technically more complex, anterior placentas are not associated with increased incidence of RA. Furthermore, the overall outcome of TTTS pregnancies with RA in our study was similar to those in TTTS pregnancies without RA. Both hypotheses, that RA could be associated with anterior placentas and adverse outcome, were thus not confirmed in our study. Lack of association between RA and adverse outcome may partly be due to the frequent presence (35%) of residual superficial anastomoses. Superficial arterio-

arterial anastomoses are known to protect against TTTS.[20]
An important (but inevitable) bias in our study may have been introduced by the exclusion of nine cases in which placental fragmentation or post-mortem placental changes prohibited the injection and demonstration of the vessels on the placental surface. Adverse outcome in the nine excluded pregnancies was 50% (9/18; intrauterine fetal demise: n = 8, severe cerebral injury: n =1). If adverse outcome in these pregnancies would have been caused by RA, then the incidence of adverse outcome in the RA group would have increased from 18% (6/34) to 29% (15/52). This is still similar to the incidence of adverse outcome in the no-RA group (29%) (p = 0.97). Therefore, it seems reasonable to deduce that RA in our study were not associated with adverse outcome.
We have shown in this study that large inter-twin haemoglobin differences (> 5 g/dL) were significantly more frequent in the presence of RA compared to the group without RA. Therefore, the hypothesis related to the association between RA and larger inter-twin haemoglobin difference seems legitimate. RA were also associated with a higher incidence of anaemia or polycythemia at birth. Overall, RA were associated with isolated haemoglobin discordance at birth or recurrent TTTS in 11 of the 52 (21%) TTTS pregnancies treated with laser surgery. Our findings are in agreement with recent reports suggesting that incomplete coagulation results in isolated haemoglobin discordance or recurrent TTTS in up to 27% of double survivors after laser surgery.[21-23] Routine serial ultrasound examination with MCA-PSV measurement after laser surgery proved invaluable in the early detection of severe fetal haematological disorders and is nowadays strongly recommended.[21-23] Similarly, we also strongly recommend routine placental injection study in TTTS treated with laser because it may give equally invaluable information to perinatologists to understand the etiology of severe haematological disorders. Finally, placental injection studies are an important feedback source to individual fetoscopic surgeons.
In conclusion, clinicians involved in the care for monochorionic twins should be aware that RA occur frequently after fetoscopic laser surgery in TTTS. Although RA are not clearly associated with adverse outcome, these anastomoses may be associated with severe haematological disorders in fetuses and neonates. Routine Doppler measurements after laser surgery and accurate placental

injection studies after birth can help in detecting and understanding fetal and neonatal haematological complications.

References

1. Senat MV, Deprest J, Boulvain M, Paupe A, Winer N, Ville Y. Endoscopic laser surgery versus serial amnioreduction for severe twin-to-twin transfusion syndrome. N Engl J Med 2004;351:136-44.

2. De Lia JE, Cruikshank DP, Keye WR, Jr. Fetoscopic neodymium:YAG laser occlusion of placental vessels in severe twin-twin transfusion syndrome. Obstet Gynecol 1990;75:1046-53.

3. De Paepe ME, Friedman RM, Poch M, Hansen K, Carr SR, Luks FI. Placental findings after laser ablation of communicating vessels in twin-to-twin transfusion syndrome. Pediatr Dev Pathol 2004;7:159-65.

4. Quintero RA, Bornick PW, Morales WJ, Allen MH. Selective photocoagulation of communicating vessels in the treatment of monochorionic twins with selective growth retardation. Am J Obstet Gynecol 2001;185:689-96.

5. Quintero RA, Comas C, Bornick PW, Allen MH, Kruger M. Selective versus non-selective laser photocoagulation of placental vessels in twin-to-twin transfusion syndrome. Ultrasound Obstet Gynecol 2000;16:230-36.

6. Quintero RA, Martinez JM, Lopez J, Bermudez C, Becerra C, Morales W et al. Individual placental territories after selective laser photocoagulation of communicating vessels in twin-twin transfusion syndrome. Am J Obstet Gynecol 2005;192:1112-18.

7. Wittmann BK, Baldwin VJ, Nichol B. Antenatal diagnosis of twin transfusion syndrome by ultrasound. Obstet Gynecol 1981;58:123-27.

8. Middeldorp JM, Klumper FJ, Oepkes D, Lopriore E, Kanhai HH, Vandenbussche FP. The initial results of fetoscopic laser treatment for severe second trimester twin-to-twin transfusion syndrome in the Netherlands are comparable to international results. Ned Tijdschr Geneeskd 2004;148:1203-08.

9. Hecher K, Diehl W, Zikulnig L, Vetter M, Hackeloer BJ. Endoscopic laser coagulation of placental anastomoses in 200 pregnancies with severe mid-trimester twin-to-twin transfusion syndrome. Eur J Obstet Gynecol Reprod Biol 2000;92:135-39.

10. Lopriore, E., Wezel-Meijler, G., Middeldorp, J. M., Sueters, M., Vandenbussche, F. P., and Walther, F. J. Incidence, origin and character of cerebral injury in twin-to-twin transfusion syndrome treated with fetoscopic laser surgery. Am.J.Obstet.Gynecol. 2006;194:1215-20.

11. Lopriore E, Sueters M, Middeldorp JM, Oepkes D, Vandenbussche FP, Walther FJ. Neonatal outcome in twin-to-twin transfusion syndrome treated with fetoscopic laser occlusion of vascular anastomoses. J Pediatr 2005;147:597-602.

12. Taylor MJ, Wee L, Fisk NM. Placental types and twin-twin transfusion syndrome. Am J Obstet Gynecol 2003;188:1119-20.

13. Bermudez C, Becerra CH, Bornick PW, Allen MH, Arroyo J, Quintero RA. Placental types and twin-twin transfusion syndrome. Am J Obstet Gynecol 2002;187:489-94.

14. De Paepe ME, Burke S, Luks FI, Pinar H, Singer DB. Demonstration of placental vascular anatomy in monochorionic twin gestations. Pediatr Dev Pathol 2002;5:37-44.

15. Denbow ML, Cox P, Taylor M, Hammal DM, Fisk NM. Placental angioarchitecture in monochorionic twin pregnancies: relationship to fetal growth, fetofetal transfusion syndrome, and pregnancy outcome. Am J Obstet Gynecol 2000;182:417-26.

16. Benirschke K. The placenta in twin gestation. Clin Obstet Gynecol 1990;33:18-31.

17. Nikkels PG, van Gemert MJ, Briet JW. Late onset of discordant growth in a monochorionic twin pregnancy: vascular anastomoses determine fetal growth pattern and not placental sharing. Fetal Diagn Ther 2001;16:23-25.

18. Arts NFT, Loizeau S. The vascular anatomy of monochorionic diamniotic twin placentas and the transfusion syndrome. Eur J Obstet Gynecol Reprod Biol 1971;3:85-93.

19. Machin G, Still K, Lalani T. Correlations of placental vascular anatomy and clinical outcomes in 69 monochorionic twin pregnancies. Am J Med Genet 1996;61:229-36.

20. Lopriore E, Middeldorp JM, Sueters M, Vandenbussche FP, Walther FJ. Twin-to-twin transfusion syndrome: from placental anastomoses to long-term neurodevelopmental outcome. Curr Pediatr Rev 2005;1:191-203.

21. Robyr, R., Lewi, L., Salomon, L. J., Yamamoto, M., Bernard, J. P., Deprest, J., and Ville, Y. Recurrence of twin-twin transfusion syndrome (TTTS) and feto-fetal hemorrhage: two complications of laser treatment with distinct ultrasound features. Ultrasound Obstet. Gynecol 2005;26:433-434. Ref Type: Abstract.

22. Yamamoto M, Ville Y. Twin-to-Twin Transfusion Syndrome: Management Options and Outcomes. Clin Obstet Gynecol 2005;48:973-80.

23. Robyr R, Lewi L, Salomon LJ, Yamamoto M, Bernard JP, Deprest J et al. Prevalence and management of late fetal complications following successful selective laser coagulation of chorionic plate anastomoses in twin-to-twin transfusion syndrome. Am J Obstet Gynecol 2006;194:796-803.

Laparoscopically guided uterine entry for fetoscopy in twin-to-twin transfusion syndrome with completely anterior placenta: a novel technique

Johanna M Middeldorp
Enrico Lopriore
Marieke Sueters
Frank W Jansen
Jan Ringers
Frans JCM Klumper
Dick Oepkes
Frank PHA Vandenbussche

5

(based on: Fetal Diagnosis and Therapy, in press)

Abstract

Objective: Laser coagulation of anastomotic vessels on the placental surface is the treatment of choice in severe second trimester twin-to-twin transfusion syndrome (TTTS). This procedure is associated with technical difficulties when the placenta is located on the anterior side of the uterus. We describe a novel technique for fetoscopy in TTTS with completely anterior placenta where laparoscopy is used to guide safe percutaneous insertion of the fetoscope through the lateral abdominal wall and the dorsal side of the uterus.

Methods: Prospective controlled series of 16 TTTS pregnancies with completely anterior placenta (study group) treated with this novel technique. Studied outcomes were technical result of the procedure and perinatal survival. Outcome in the study group was compared with outcome of 49 TTTS pregnancies treated with conventional percutaneous fetoscopic laser without laparoscopy, 9 of these with partially anterior placenta (control group A) and 40 with lateral or posterior placenta (control group B).

Results: In the study group, the procedure-related complication rate was 25% (4/16). In one case uterine entry of the fetoscope from the lateral abdominal wall was not possible due to complex bowel adhesions. In 3 patients, intraamniotic haemorrhage occurred after fetoscopic entry, preventing complete laser coagulation of anastomoses. One of these patients required two units of blood transfusion. The procedure-related complication rate in control group A and B was 22% (2/9) and 5% (2/40), respectively (intraamniotic haemorrhage n =3, severe leakage of amniotic fluid into the peritoneal cavity, n=1). Perinatal survival in the study group, control group A and control group B was 63% (20/32), 78% (14/18) and 70% (56/80), respectively.

Conclusions: Combined laparoscopy and fetoscopy is a novel technique that enables safe uterine entry and creates optimal visualisation for laser coagulation of intertwin anastomoses in TTTS pregnancies with completely

anterior placenta. Procedure-related complication rate and perinatal survival rate were similar compared to the conventional percutaneous technique. Procedure-related complications occur more often with partially or completely anterior placenta.

Introduction

Monochorionic twin pregnancies are at risk for developing twin-to-twin transfusion syndrome (TTTS) due to unbalanced intertwin blood-flow through placental vascular anastomoses. TTTS occurs in approximately 15% of monochorionic twin pregnancies during the second trimester.[1] The prognosis for untreated severe second trimester TTTS is poor.[2] Since 1980, serial amniodrainage has been used as a symptomatic therapy. A decade later, a cause-oriented approach for TTTS was developed: fetoscopic laser coagulation of placental vascular anastomoses.[3-5] In a recent randomised trial of severe second trimester TTTS, perinatal survival rates and neurological outcome at six months of age were significantly better after laser treatment compared to amniodrainage.[6]

In patients with placental localisation on the posterior wall of the uterus, percutaneous insertion of the fetoscope for laser coagulation gives perpendicular access to the chorionic plate and the vascular anastomoses on its surface, and is, in experienced hands, a straightforward procedure. An angle of approximately 90 degrees between chorionic plate and fetoscope and laser fibre provides maximal visualisation of the vascular equator and optimal laser effectiveness. An anterior placenta, however, presents a technical challenge, because perpendicular access is not possible. Several authors have claimed that the problem of anterior placentas could be solved either by open uterine access via mini-laparotomy, or by lateral percutaneous entry combined with the use of a curved shaft and flexible fetoscope, with the use of multiple ports, or with lateral view fetoscope and side firing laser.[7-11] These methods, however, still entail a higher risk of transplacental entry, maternal bowel or uterine vessel damage, increased risk of iatrogenic rupture of membranes, or incomplete placental visualisation and diminished laser effectiveness and thus of incomplete laser treatment. We report on a novel minimally invasive technique, developed to enable safe uterine entry and optimal placental visualisation in patients with completely anterior placenta by combining laparoscopy with fetoscopy. Laparoscopy with open entry technique has been shown before to

be a safe procedure in pregnant women.[12;13]
In this study, we describe this new technique and report on the procedure-related complications and on perinatal survival in the first 16 patients with completely anterior placenta treated with combined laparoscopy and fetoscopy. We compared procedure-related complications and perinatal survival in this study group with those of two control groups that underwent fetoscopy without laparoscopy for TTTS: control group A with partially anterior placenta and control group B with lateral or posterior placenta.

Patients

Our centre is the national referral centre for invasive fetal therapy in the Netherlands. In August 2000, we started our program of fetoscopic laser coagulation of anastomotic vessels for severe TTTS.[14] In September 2003, we performed our first combined open laparoscopy and fetoscopy for completely anterior placenta. Completely anterior placenta was defined as a placenta and stuck twin covering almost the entire ventral uterine wall, thereby excluding the avoidance of transplacental entry, or enhancing the risk of damaging maternal bowel or vessels, or excluding complete visualisation of the vascular equator with percutaneous fetoscopic entry. To evaluate this new technique, we compared the procedure-related complications and the perinatal survival with those of 49 routine laser procedures performed by our team during the same time period. Perinatal survival was assessed until 4 weeks after birth. Inclusion criteria for laser surgery were: monochorionic twin pregnancy, gestational age between 15 and 27 completed weeks, TTTS Quintero stage 1 with severe clinical symptoms of polyhydramnios, or TTTS Quintero stage ≥ 2. Patients in active labour or with a fetus with congenital malformations were excluded. Before fetoscopy, detailed sonographic evaluation was performed to exclude congenital anomalies, to confirm the diagnosis of TTTS, and to determine the Quintero stage. The sonographic investigation included: fetal anatomy and biometry, deepest vertical pocket of amniotic fluid of each fetus, bladder filling, arterial and venous Doppler studies, placental localisation, and localisation of umbilical

cord insertions. Based on the placental localisation, the position of both fetus and the insertion site of the umbilical cords, an estimation was made of the localisation of the vascular equator on the placenta.

Operative technique

Under general anaesthesia and with the patient in supine position, open laparoscopy was performed according to the technique first described by Hasson.[15] We modified the technique by introducing the Origin balloon trocar (Autosuture®, Tyco Healthcare, Gosport, UK) with blunt tip, after the abdomen had been opened, via a 2 to 3 cm median or paramedian incision. This incision was made 2 cm above the fundus of the uterus (figure 1a). Pneumoperitoneum was established under direct vision of the laparoscope. The intra-abdominal CO_2 insufflation pressure was automatically regulated and maintained at 12-14 mm Hg. After insertion of the laparoscope, the patient was turned to lateral tilt position and stabilised using a desufflatable beanbag. The fetoscopic insertion site was chosen near the mid-axillary line, between the lower ribs and the iliac crest (figure 1b). At this site, an 18-G needle was inserted into the abdominal cavity under laparoscopic vision, away from bowel. In some cases, in order to obtain better visualisation, a second trocar was inserted close to the needle insertion site and the laparoscope was then switched to the second trocar.

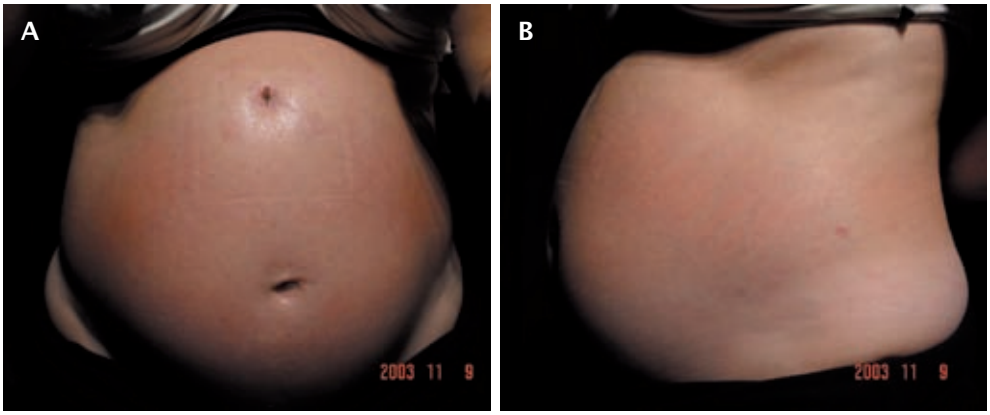

Figure 1a and 1b *Skin incisions made for open laparoscopy (a), and fetoscopic entry (b).*

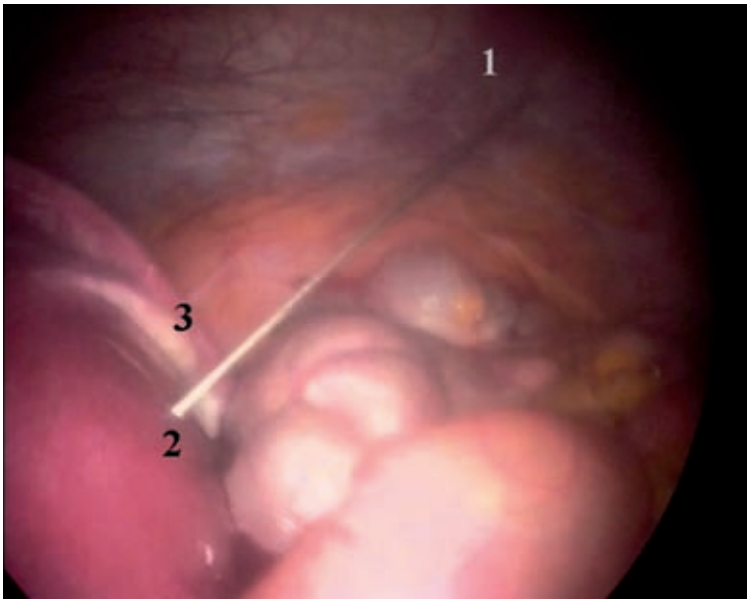

Figure 2
Laparoscopic view of the needle in the intraperitoneal cavity just after entering the dorsal uterine wall. Open laparoscopy was performed in the right upper quadrant, 3 cm under lower ribs.1 right dorsolateral abdominal wall, 2 needle insertion at posterior side of uterus, 3 right adnexa.

Under direct laparoscopic view, the 18-G needle was inserted safely into the posterior uterine wall, away from the large vessels on the lateral side of the uterus (figure 2). Simultaneously, ultrasound was used to guide the needle into the amniotic cavity of the recipient fetus. Then a Seldinger technique was used with a 0.085 inch soft J-tipped guide wire that was introduced through the needle, which was then removed.[7] A 10 F teflon cannula, loaded with a dilator, was advanced over the guide wire (Cook®). When the cannula had entered the amniotic cavity, the guide wire and dilator were removed and the shaft loaded with a 2 mm fetoscope (Storz, Vianen, the Netherlands) and laser fibre (400 µm) (Dornier Medizin Technik, Germering, Germany) was inserted. This procedure was also sonographically guided. For this purpose, the pneumoperitoneum had to be partly released. Figure 3 shows an ultrasound picture with the ultrasound probe at the maternal umbilicus and pushed against the uterus, and the fetoscope entered through the dorsal uterine wall. The fetoscopic laser coagulation then took place following the standard procedure, with the advantage of perpendicular access to and complete visualisation of the placenta.[14]

In the control group an 18-G needle that was inserted percutaneously in the uterine cavity under ultrasound guidance. The same procedure as described

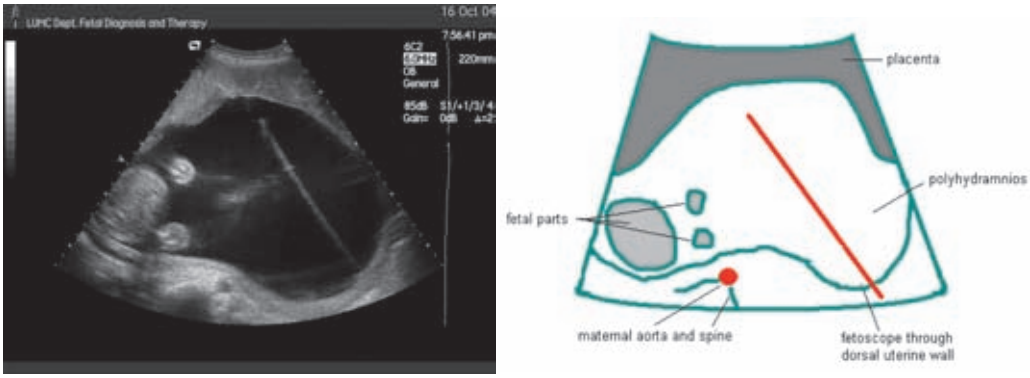

Figure 3 *Transverse sonographic view (transducer at maternal umbilicus) of the uterus with fetoscopic entry site in the dorsal uterine wall.*

above was then used for insertion of the fetoscopic shaft. Curved shafts up to 40 degrees and a semi rigid fetoscope were used when indicated. Patients underwent this conventional percutaneous entry procedure under local or loco-regional anaesthesia. In both groups, a prophylactic dose of tocolytics (indomethacin) and antibiotics (amoxycillin/clavulanate) was given routinely.

Statistics

Differences in gestational age between study and control groups were analysed with one-way analysis of variance. Categorical variables were analysed with Fisher exact test, chi square test, and linear by linear association for trend. A p-value < 0.05 was considered to indicate a statistical significance. Statistical analysis was performed with SPSS version 11.0 (SPSS, Inc., Chicago, Illinois, USA).

Results

Between September 2003 and December 2005, treatment with fetoscopic laser coagulation of anastomotic vessels was performed in 65 patients. Anterior placenta was detected in 38% (25/65) of patients. In 64% of these (16/25),

the placenta completely covered the anterior uterine wall. These 16 patients underwent the combined open laparoscopy and fetoscopy procedure. Of the 49 patients without completely anterior placenta, 9 (18%) patients had an anterior placenta that only partially covered the anterior uterine wall (control group A), and 40 (82%) patients had lateral or posterior placenta (control group B). Details of the 16 patients in the study group are listed in Table 1. In 2 of the 16 patients, the combined open laparoscopy and fetoscopy was the second procedure for the treatment of TTTS. One patient underwent a prior amniodrainage and in another patient a routine laser procedure had been attempted 9 days earlier, which had to be abandoned after the occurrence of significant intraamniotic haemorrhage at uterine entry. In 4 of the 16 patients, laser coagulation could not be performed. In one patient, uterine entry was not possible despite assistance of the laparoscope, because of complex bowel adhesions along the lateral side of the uterus. Instead, an amniodrainage procedure was performed. In three other patients, severe intraamniotic haemorrhage occurred. Because of impaired visualisation shortly after entry, the procedure was abandoned. One of these patients also suffered from an intraperitoneal bleeding from the uterine wall and received two units of blood transfusion.

In 4 of the 49 patients in the control groups, laser coagulation was not or incompletely achieved. In 3 of these 4 patients (2 in control group A and 1 in control group B) intraamniotic haemorrhage occurred. In the fourth patient (in control group B), no visualisation could be reached, due to rapid leakage of all of the amniotic fluid into the intraperitoneal cavity after a sudden movement of the patient. In two other cases in control group B, recurrence o f the syndrome and reversal of the syndrome were diagnosed, respectively. There was no significant difference in procedure-related complication rate between the laparoscopy (study) group and the conventional fetoscopy group (combination of control group A and B) ($p = 0.094$). When comparing the women with anterior placenta (combination of study group and control group A) with the women with posterior placenta (control group B), a significantly higher procedure-related complication rate was found in the anterior placenta group ($p = 0.047$). There was a significant linear-by-linear trend for higher procedure-

Table 1 *Characteristics of 16 cases of laparoscopically assisted fetoscopic intervention for twin-to-twin transfusion syndrome with completely anterior placenta*

case number	Quintero stage	GA at intervention	GA at delivery (completed	survivors 4 weeks after birth	procedure-related complications leading to incomplete treatment
1	II	15	31	2	
2	IV	21	33	2	
3	II	17	37	2	
4	III	20	33	2	
5†	I	24	37	2	
6	I	17	23	0	no intra-uterine access due to bowel adhesions, amniodrainage
7	III	19	29	0	
8	III	24	35	2	
9	II	18	19	0	
10‡	III	26	28	1	
11	III	20	29	1	intraamniotic haemorrhage, laser coagulation not achieved, amniodrainage + cord coagulation
12	III	20	29	2	
13	I	19	20	0	intraamniotic haemorrhage, laser coagulation not achieved, amniodrainage
14	III	15	28	2	intraamniotic haemorrhage, laser coagulation not achieved, intraperitoneal haemorrhage, amniodrainage
15	III	20	22	0	
16	III	16	31	2	

† *previous amniodrainage at 20 weeks*

‡ *previous attempt to percutaneous laser coagulation at 25 weeks*

related complication rate towards less favourable placenta localisation (p = 0.029).

No significant differences in 0, 1 and 2 survivors and perinatal survival were found between the three groups (p = 0.348). Further details on procedure-related complication rate and perinatal survival in study group and control groups are reported in table 2.

Table 2 *Perinatal outcome after laser coagulation of vascular anastomoses in the study group (laparoscopically assisted fetoscopic entry with completely anterior placenta), control group A (percutaneous fetoscopic entry with partial anterior placenta) and control group B (percutaneous fetoscopic entry with lateral or posterior placenta)*

	study group N=16	**Control group A Partial anterior placenta N=9**	**Control group B Lateral or posterior placenta N=40**
gestational age at intervention† -	20 (15-26)	18 (15-26)	20 (15-26)
procedure-related complication - no.(%)	4 (25%)	2 (22%)	2 (5%)
gestational age at birth† -	29 (19-37)	31 (15-36)	31 (16-38)
0 survivors‡ - no.(%)	5 (31%)	2 (22%)	7 (17%)
1 survivor‡ - no.(%)	2 (13%)	0 (0%)	10 (25%)
2 survivors‡ - no.(%)	9 (56%)	7 (78%)	23 (58%)
at least 1 survivor‡ - no.(%)	11 (69%)	7 (78%)	33 (83%)
neonatal death - no.(%)	1/32(3%)	0/18 (0%)	1/80 (1%)
perinatal survival‡ - no.(%)	20/32 (63%)	14/18 (78%)	56/80 (70%)

† *median (range) in completed weeks*

‡ *4 weeks after birth*

Discussion

We describe a novel minimally invasive technique for safe fetoscopic entry through the posterior uterine wall in patients where the placenta completely covers the anterior uterine wall. This safe entry was accomplished by laparoscopic guidance of the fetoscope, thus avoiding the risk of bowel damage at peritoneal entry and of vascular damage at uterine entry.
Our findings suggest that perinatal survival rate and procedure-related complications rate associated with this novel technique are similar compared to the conventional percutaneous laser technique without laparoscopy. However, procedure-related complication rate remained higher in the group with partly and completely anterior placenta compared to the group with posterior placenta.
Since the development of the technique of fetoscopic laser coagulation, patients with an anterior placenta have presented a technical challenge. In the first series of De Lia et al, patients with anterior placenta were excluded from fetoscopic laser surgery.4 In the second series of De Lia et al, 46% of patients had an anterior placenta and underwent midline laparotomy with the uterus exteriorised for optimal insertion of the fetoscope.16 Nowadays, De Lia is still using this operation technique in patients with a completely anterior placenta (personal communication). In the first series of Ville *et al*, 40% of the patients had an anterior placenta.[5] In this study, a rigid fetoscope was used and the same procedure was used for anterior placenta as for posterior placenta localisation. The author stated that adequate visualisation of the intertwin membrane and coagulation of the crossing vessels was more difficult to achieve in the patients with anterior placenta. In the second series of Ville *et al*, which included patients of their first series, 43% of the patients had an anterior placenta.[10] In this series of 57 patients, the percutaneous insertion site of the fetoscope was chosen as lateral as possible and sonographically guided by colour Doppler to avoid the uterine vessels. Nevertheless, in 9 of their patients the entry was transplacental. They state, however, that good visualisation of intertwin membrane and crossing vessels was achieved in all cases. Deprest *et al* also recognised the technical problems of an anterior placenta. They

described an alternative technique for fetoscopic access in patients with anterior placenta, using mini-laparotomy mainly in the region of the uterine fundus, Seldinger technique for uterine entry and a curved shaft with a semi-rigid fiberscope.[7] In the series of Zikulnig *et al*, 36% of the patients had an anterior placenta.[8] They mentioned that, when using the lateral percutaneous technique, the procedure succeeded in most cases, though more technical difficulties were encountered in achieving good visualisation and coagulation of vessels. Hecher *et al*, stated that, in most patients with anterior placenta, the lateral percutaneous fetoscopic access provided good visualisation of most vascular anastomoses, although detailed results were not reported.[9] Quintero *et al* described two techniques for the laser treatment in women with anterior placenta. The first technique entails the use of a flexible scope through a single port. The second technique is based on the use of a side-firing laser fibre through one port and a rigid angled-view endoscope through a second port. No significant differences in survival were found, but operating time was significantly increased for those with an anterior placenta.[11] Yamamoto *et al* reported on incidence and impact of perioperative complications in 175 fetoscopy-guided laser coagulation procedures.[17] Transplacental entry occurred in 27% of the cases and was 5 times more frequent when the placenta was anterior. Intraamniotic haemorrhage was 3 times more frequent with transplacental entry. However, position of the placenta and transplacental entry were not correlated with the outcome.
Although the majority of authors do not find significant differences in perinatal survival between cases with anterior and with posterior placenta, many authors mention the fact that anterior placenta presents a technical challenge because of impaired visualisation of the placental surface. All but one published series of fetoscopic laser coagulation of vascular anastomoses were non-randomised prospective studies. Possibly, some of the patients with a completely anterior placenta would not have been included in these series, because of the anticipation on technical problems of percutaneous fetoscopic laser coagulation.

Our technique is an alternative to the existing techniques aimed on being

minimally invasive and providing a close to 90 degrees perpendicular intra-uterine access for optimal visualisation and laser effectiveness, with simultaneous avoidance of the maternal intraperitoneal structures. We agree with other authors that in a substantial number of patients with an anterior placenta, lateral percutaneous fetoscopic access provides acceptable conditions for laser surgery. During the study period, 9 of 25 patients with an anterior placenta underwent fetoscopic laser coagulation using the conventional percutaneous fetoscopic entry. However, in patients with completely anterior placenta, this procedure still entails a risk of transplacental entry or incomplete laser surgery.[17] Procedure-related complication rates in completely anterior placenta have not yet been reported. We found that 2 of 4 procedure-related complications in the control groups occurred in the control group with partially anterior placenta, confirming the suggestion that fetoscopic procedures carry more risks in patients with an anterior placenta. Procedure-related complications also occurred in the study group in which we performed the laparoscopic procedure. However, this group of patients was a highly selective group where the placenta covered the complete anterior uterine wall and no placenta-free site could be identified for safe lateral percutaneous fetoscopic entry. This may explain the higher number of procedure-related complications towards less favourable placental localisation.

Laparoscopically guided fetoscopy also has some limitations. Firstly, abdominal adhesions may hamper application of this technique. Secondly, we found an 18% risk of intraamniotic bleeding in our study group. This may be by coincidence, as the incidence of intraamniotic bleeding did not differ significantly between the study group and the two control groups, and as the overall incidence, 6/65 (9.2%), of intraamniotic bleeding in both study and control groups was very similar to the 8.6% found by Yamamoto *et al.*[17] However, the high risk of intraamniotic bleeding in the study group may also be explained by the limited value of colour Doppler for identification and avoidance of vasculature when the uterine entry site is posterior. Also, the use of general anaesthesia for laparoscopy may promote uterine relaxation and thus the risk of bleeding at perforation.

Conclusions

Laparoscopically assisted fetoscopic uterine access through the dorsal uterine wall for laser coagulation of vascular anastomoses in patients with severe TTTS is a novel technique. This technique enables safe uterine entry in a selected group of patients with an anterior placenta covering the complete anterior uterine wall. There were no significant differences in perinatal survival between the laparoscopically guided and the conventional percutaneous fetoscopic entry technique. However, procedure-related complication rate remained higher in women with anterior than in women with posterior placental localisation. Further comparison between laparoscopically guided fetoscopy and alternative approaches may form the subject of prospective controlled trials.

References

1. Sebire NJ, Souka A, Skentou H, Geerts L, Nicolaides KH: Early prediction of severe twin-to-twin transfusion syndrome. Hum Reprod 2000; 15:2008-10.

2. Gemert JC van, Umur A, Tijssen JGP, Ross MG: Twin-twin transfusion syndrome: etiology, severity and rational management. Curr Opin Obstet Gynecol 2001;13:193-206.

3. De Lia JE, Cruikshank DP, Keye WR Jr: Fetoscopic neodymium:YAG laser occlusion of placental vessels in severe twin-twin transfusion syndrome. Obstet Gynecol 1990;75:1046-53.

4. De Lia JE, Kuhlman RS, Harstad TW, Cruikshank DP: Fetoscopic laser ablation of placental vessels in severe previable twin-twin transfusion syndrome. Am J Obstet Gynecol 1995;172:1202-11.

5. Ville Y, Hyett J, Hecher K, Nicolaides K: Preliminary experience with endoscopic laser surgery for severe twin-twin transfusion syndrome. N Engl J Med 1995;332:224-7.

6. Senat MV, Deprest J, Boulvain M, Paupe A, Winer N, Ville Y: Endoscopic laser surgery versus serial amnioreduction for severe twin-to-twin transfusion syndrome. N Engl J Med 2004;351:136-44.

7. Deprest JA, Van Schoubroeck D, Van Ballaer PP, Flageole H, Van Assche FA, Vandenberghe K: Alternative technique for Nd: YAG laser coagulation in twin-to-twin transfusion syndrome with anterior placenta. Ultrasound Obstet Gynecol 1998;11:347-52.

8. Zikulnig L, Hecher K, Bregenzer T, Baz E, Hackeloer BJ: Prognostic factors in severe twin-twin transfusion syndrome treated by endoscopic laser surgery. Ultrasound Obstet Gynecol 1999;14:380-7.

9. Hecher K, Diehl W, Zikulnig L, Vetter M, Hackeloer BJ: Endoscopic laser coagulation of placental anastomoses in 200 pregnancies with severe mid-trimester twin-to-twin transfusion syndrome. Eur J Obstet Gynecol Reprod Biol 2000;92:135-9.

10. Ville Y, Hecher K, Gagnon A, Sebire N, Hyett J, Nicolaides K: Endoscopic laser coagulation in the management of severe twin-to-twin transfusion syndrome. Br J Obstet Gynaecol 1998;105:446-53.

11. Quintero RA, Bornick PW, Allen MH, Johnson PK: Selective laser photocoagulation of communicating vessels in severe twin-twin transfusion syndrome in women with an anterior placenta. Obstet Gynecol 2001;97:477-81.

12. Kolkman W, Scherjon SA, Gaarenstroom KN, Jansen FW: Laparascopic management of adnexal masses with the open entry technique in second-trimester pregnancy. Gynecol Surg 2004;1:21-5.

13. SAGES (Society of American Gastrointestinal Endoscopic Surgeons): Guidelines for laparoscopic surgery during pregnancy. Surg Endosc 1998;12:189-90.

14. Middeldorp JM, Sueters M, Lopriore E, Klumper FJ, Oepkes D, Devlieger R, Kanhai HH, Vandenbussche FP: Fetoscopic surgery in 100 pregnancies with severe twin-to-twin transfusion syndrome in the Netherlands. Fetal Diagn Ther 2007;22:190-194.

15. Hasson HM: A modified instrument and method for laparosocopy. Am J Obstet Gynecol 1971;110:886-7.

16. De Lia JE, Kuhlmann RS, Lopez KP: Treating previable twin-twin transfusion syndrome with fetoscopic laser surgery: Outcomes following the learning curve. J Perinat Med 1999;27:61-7.

17. Yamamoto M, El Murr L, Robyr R, Leleu F, Takahashi Y, Ville Y: Incidence and impact of perioperative complications in 175 fetoscopy-guided laser coagulations of chorionic plate anastomoses in fetofetal transfusion syndrome before 26 weeks of gestation. Am J Obstet Gynecol 2005;193:1110-6.

Long-term neurodevelopmental outcome in twin-to-twin transfusion syndrome treated with fetoscopic laser surgery

Enrico Lopriore
Johanna M Middeldorp
Marieke Sueters
Dick Oepkes
Frank PHA Vandenbussche
Frans J Walther

(based on: American Journal of Obstetrics and Gynecology, in press)

6

Abstract

Objective: To determine the long-term neurodevelopmental outcome in twin-to-twin transfusion syndrome (TTTS) treated with fetoscopic laser surgery.

Methods: All TTTS-cases treated at our centre with laser between August 2000 and December 2003 were included in the study. Neurological, mental and psychomotor development at 2 years of age corrected for prematurity was assessed in all TTTS-survivors. Neurodevelopmental impairment was defined as any of the following: cerebral palsy, deafness, blindness, mental or psychomotor development index of the Bayley Scales of Infant Development II < 2 SD.

Results: A total of 82 TTTS pregnancies were treated with fetoscopic laser surgery during the study period. Perinatal survival was 70% (115/164). The incidence of neurodevelopmental impairment was 17% (19/115) and was due to cerebral palsy (n = 8), mental developmental delay (n = 9), psychomotor developmental delay (n = 12) and deafness (n = 1).

Conclusions: The incidence of neurodevelopmental impairment in TTTS-survivors treated with laser is high and warrants long-term follow-up.

Introduction

Monochorionic twinning predisposes to cerebral damage due to complications caused by twin-to-twin transfusion (TTTS). TTTS occurs in approximately 15% of monochorionic pregnancies and results from shunting of blood from one twin, the donor, to the other twin, the recipient, through placental vascular anastomoses. Untreated, TTTS is associated with high perinatal mortality and morbidity.[1] The two current treatment options in TTTS are serial amnioreduction and fetoscopic laser occlusion of vascular anastomoses.[1-4] In a recent randomized trial comparing serial amnioreduction and laser treatment, perinatal survival and neurological outcome at six months of age was significantly better in the group treated with laser.[5] Although fetoscopic laser occlusion of vascular anastomoses is increasingly being advocated as the preferred treatment for TTTS, only a few studies have been published on the long-term neurodevelopmental outcome following such treatment. The incidence of major neurological abnormalities in these reports varied from 6% to 11%.[6-8]

The main objective of our study was to evaluate long-term neurodevelopmental outcome in a large group of TTTS-survivors after treatment with fetoscopic laser surgery.

Patients and methods

All survivors of consecutive TTTS-cases treated with fetoscopic laser surgery between August 1, 2000 and December 31, 2003 at the Leiden University Medical Centre were included in the study. The Leiden University Medical Centre serves as the national referral centre for intrauterine laser treatment in TTTS pregnancies in the Netherlands. TTTS was diagnosed using standard prenatal ultrasound criteria, and staged according to the criteria of Quintero.[9;10] The following perinatal data were recorded: gestational age at the time of laser treatment, stage of TTTS, gestational age at delivery, mode of delivery and birth weight.

The follow-up visit was assessed at 2 years of age (corrected for prematurity) and included a physical and neurological examination and an assessment of cognitive and neuromotor development using the Dutch version of the Bayley Scales of Infant Development, 2nd edition (BSID-II) (both by certified examiners). Bayley scale scores provide mental developmental indexes (MDI) and psychomotor development indexes (PDI). Each of these indexes has a mean score of 100. When each separate index score was below 70 (i.e. > 2 SD below the mean score), this was indicative of a severe delay in either mental development or psychomotor development. Infants with very low MDI or PDI scores (< 50) were assigned a score of 49 in the database. Cerebral palsy (CP) was defined according to the European CP Network and classified as diplegia, hemiplegia, quadriplegia, dyskinetic or mixed.[11]
A composite outcome, termed neurodevelopmental impairment, was defined as any of the following: CP, MDI score of less than 70, PDI score of less than 70, bilateral blindness, or bilateral deafness requiring amplification. Outcome was compared between donor and recipient twins.
The institutional review board of the Leiden University Medical Centre approved the study and all parents gave written informed consent for their children.

Statistics

Results of categorical variables were compared using Fisher's exact test or Chi-square test, as appropriate. Unpaired Student's *t* test was used to compare normally distributed values between two groups. For comparisons between donors and recipients, the paired Student t test was used for normally distributed continuous variables and the Mc Nemar test for analysis of paired nominal variables. Multiple logistic regression analysis with "random twin effect" was used to measure the independent effects of potential prognostic factors on outcome. A model with "random twin effect" was applied to adjust for possible correlated effects within twins. The results of the logistic models were expressed as an odds ratio (OR) and 95% confidence intervals (CI). Chi-square test for trend was used in order to evaluate the relationship between

stage of TTTS and outcome. A p-value <0.05 was considered to indicate statistical significance. Analysis was performed using SPSS version 11 (SPSS Inc., Chicago, IL, USA). Multiple logistic regression analysis was performed with EGRET version 2.0.1 for Windows (Cytel Software Corporation, Cambridge, Massachusetts, USA).

Results

During the study period, 82 TTTS pregnancies were treated with fetoscopic laser surgery at our centre. Quintero stage was I in 9 cases, II in 35 cases, III in 32 cases and IV in 6 cases. Laser surgery treatment for Quintero stage I was only performed when symptomatic polyhydramnios warranted intervention. Mean gestational age at laser surgery was 20.0 weeks (range 15 to 28 weeks; 2 TTTS pregnancies were treated after 26 weeks' gestation). Intrauterine fetal demise occurred in 41 fetuses (single intrauterine fetal demise, n = 15; double intrauterine fetal demise, n = 26). Mean gestational age at birth of the surviving infants was 33.9 ± 3.1 weeks (range: 27 to 40 weeks). Neonatal death occurred in 8 neonates. Overall perinatal survival was 70% (115/164). We were able to follow-up all 115 surviving twins. Four families refused to travel to our centre for follow-up visit due to the long travel distance, but agreed to allow the complete follow-up examination (including BSID-II test) at their own home. Baseline characteristics of the TTTS survivors are presented in Table 1.
The incidence of neurodevelopmental impairment was 17% (19/115) and was due to cerebral palsy (n = 8), severe mental developmental delay (n = 9), severe psychomotor developmental delay (n = 12) and deafness (n = 1). Cerebral palsy was classified as quadriplegia (n=4), diplegia (n= 2) and hemiplegia (n= 2). Details on the combinations of abnormal findings detected in the infants with adverse outcome are presented in Table 2. Characteristics and outcome in surviving donor and recipient twins at 2 years of age are presented in Table 3. Donor twins were smaller at birth than recipient twins, and remained significantly smaller at 2 years of age (p < 0.001). We found no difference in neurodevelopmental outcome between donor and recipient twins.

Table 1 *Baseline characteristics in the 115 TTTS long-term survivors*

	Long-term survivors (n = 115 infants)
Gestational age at laser surgery - wk[a]	20.2 ± 3.0
Median Quintero stage (range)	2 (1-4)
Gestational age at birth - wk[a]	33.9 ± 3.1
Female - no. (%)	55 (48%)
Vaginal delivery - no. (%)	80 (70%)
Birth weight - g[a]	2015 ± 678

[a] *Value given as mean ± SD*

Table 2 *Combinations of abnormal findings in the 19 TTTS survivors with neurodevelopmental impairment*

	Infants with neurodevelopmental impairment (n = 19)
MDI < 2 SD	6 (32%)
PDI < 2 SD and CP - no. (%)	5 (26%)
PDI < 2 SD - no. (%)	4 (21%)
MDI < 2 SD, PDI < 2 SD and CP - no. (%)	2 (11%)
MDI < 2 SD, PDI < 2 SD and bilateral deafness - no. (%)	1 (5%)
CP - no. (%)	1 (5%)

MDI: mental development index; PDI: psychomotor development index; CP: cerebral palsy.

Table 3 *Characteristics and outcome in donor and recipient twins*

	Donors (n = 61)	Recipients (n = 54)	p-value
Birth weight - g[a]	1773 ± 608	2076 ± 567	< 0.001
Weight at 2 years of age - kg[a]	11.7 ± 1.3	12.3 ± 1.3	< 0.001
Length at 2 years of age - cm[a]	86.8 ± 4.1	87.6 ± 3.8	0.005
Head circumference at 2 years of age - cm[a]	48.5 ± 1.4	48.9 ± 1.4	0.006
Cerebral palsy - no. (%)	3 (5%)	5 (9%)	0.25
Mental development index[a]	96 ± 16	96 ± 18	0.90
Psychomotor development index[a]	91 ± 13	89 ± 18	0.52
Neurodevelopmental impairment[b] - no. (%)	10 (16%)	9 (17%)	1.0

[a] *Value given as mean ± SD*

[b] *Neurodevelopmental impairment is defined as any of the following: cerebral palsy, mental development index < 2 SD, psychomotor development index < 2 SD, bilateral deafness or blindness.*

Table 4 *Mortality rate and adverse outcome (neurodevelopmental impairment or death) by Quintero stage of TTTS*

TTTS stage	Death[a]	Adverse outcome[b,c]
I	6% (1/18)	6% (1/18)
II	29% (20/70)	40% (28/70)
III	36% (23/64)	52% (33/64)
IV	42% (5/12)	50% (6/12)

[a] *Chi-square test for trend = 5.8, df = 1, p = 0.016*

[b] *Chi-square test for trend = 9.2, df = 1, p = 0.002*

[c] *Adverse outcome = Intrauterine fetal demise, neonatal death or neurodevelopmental impairment.*

Multiple logistic regression was carried out to measure the independent associations between neurodevelopmental impairment and various clinical parameters (gestational age at laser, gestational age at birth, birth weight, Quintero stage and donor versus recipient status). We found a trend towards an independent association between higher Quintero stages and neurodevelopmental impairment (OR 6.6 for each stage, 95% CI 0.7 – 66.0, p = 0.08) and lower gestational age at birth and neurodevelopmental impairment (OR 1.6 for each week, 95% CI 0.8 – 3.0, p = 0.08) (table 4).

Comment

The main objective of our study was to evaluate the long-term neurodevelopmental outcome in TTTS-survivors treated with fetoscopic laser surgery. We were able to follow-up all (100%) TTTS survivors and report a high incidence (17%) of neurodevelopmental impairment. The long-term neurolodevelopmental outcome found in this study is in agreement with the short-term neurological outcome reported previously by our research group, in which we found a similar incidence (14%) of severe cerebral lesions in TTTS-survivors after laser treatment.[12]
Four studies from three different research groups have reported on long-term outcome in TTTS after laser surgery. The incidence of neurodevelopmental impairment found in this study is somewhat higher than in these other reports. However, special care must be taken when comparing results from various studies, as discrepant results may partly be due to different methodology, selection criteria and definitions of neurodevelopmental impairment. De Lia *et al* report a 6% (6/93) incidence of severe handicaps in TTTS survivors after laser surgery.[13] Mean age at follow-up was 14 months (range 1 to 34 months), which may be too soon for accurate assessment of CP or major developmental delay. Most importantly, the methods used to determine neurodevelopmental outcome were not specified, suggesting that accurate assessment of mental and psychomotor development was not performed. Sutcliffe *et al* found a 9% (6/66) incidence of CP in a cohort of TTTS survivors treated with laser.[6] Follow-

up was however incomplete (81%) and in 47% (31/66) of patients neurological outcome was assessed using information from the general practitioner. In the group assessed by a paediatrician, 14% (5/36) had CP. Children assessed by paediatricians were also tested with a standardized developmental test (Griffiths' Developmental Test Scales). However, details on the number of infants with severe developmental delay (defined as a score < 2 SD) were not reported or scored as primary outcome, as opposed to the definition used in this study. The two largest follow-up cohorts have been reported by a research group from Germany. Using standardized developmental test and neurological examination, Banek *et al* and Graef *et al* report an incidence of major neurological deficiencies of 11% (10/89) and 6% (10/167) respectively.[7;8] In both studies, the definition of major neurological deficiencies did not include severe developmental delay. Therefore, as opposed to this study, infants with severe developmental delay but without CP were not included in the group with major abnormalities. Also, developmental outcome in the majority of children (112/167) in the study from Graef *et al* was only assessed by the Snijders-Oomen Non-Verbal-Intelligence Test and therefore motor abilities were not tested. The incidence of CP in the studies from Banek *et al* and Graef *et al*, respectively 11% and 6%, was nevertheless similar to the 7% incidence of CP found in this study.

After treatment of TTTS with amniodrainage, most studies on long-term outcome report a high incidence of neurodevelopmental impairment, ranging from 22 to 26%.[14-17] Only one study in TTTS treated with amniodrainage reported a lower incidence of CP or multicystic encephalomalacia of 7% (3/42), without assessment of neurodevelopmental delay.[18] Overall, the reported incidence of neurodevelopmental impairment appears to be higher in TTTS survivors treated with serial amniodrainage than with laser surgery. However, different methodology may also explain the discrepancy in results between various follow-up studies. To assess the true difference in neurodevelopmental impairment in TTTS survivors treated with either laser surgery or serial amnioreduction, results of the long-term follow-up in the first randomized control trial comparing both treatments must be awaited.[5]

Absence of a control group is an important limitation of this study. A case-

control study comparing the long-term outcome in monochorionic twins with TTTS treated with laser and monochorionic twins without TTTS is currently being performed at our institution.[19]

We found no difference in neurodevelopmental impairment between donor and recipient twins, suggesting that both are equally at risk for adverse neurodevelopmental outcome. These results are in agreement with previous studies.[7;8;14] Donor twins are significantly smaller at birth than recipient twins, and remain smaller and shorter at 2 years of age. These findings are in agreement with previous reports.[14] According to the 'fetal origins of adult disease' or 'Barker hypothesis', lower birth weight is associated with an increased risk for coronary heart disease, diabetes, hypertension and stroke in adulthood.[20] Whether reduced birth weight in donor twins in TTTS may also lead to increased incidence of adult diseases is not known yet.

Multivariate analysis showed a trend towards an independent association between neurodevelopmental impairment and lower gestational age at birth as well as higher Quintero stages. Prematurity is a well recognized risk factor for adverse neurodevelopmental outcome in twins as well as in singletons.[21;22] Although the prognostic value of Quintero stages is subject of debate, our results also suggest an important prognostic value of Quintero staging.[4;23]

The objective of fetal therapy should be to reach a high percentage of intact-survival. Even though fetoscopic laser surgery appears to be the best available treatment option for TTTS, the idealistic goal of high intact-survival rate has not yet been reached. Timing of cerebral injury leading to neurodevelopmental impairment in TTTS treated with fetoscopic laser surgery is not clear. Cerebral Injury may occur before, during or after laser surgery. Therefore, whether cerebral injury and subsequent neurodevelopmental impairment could be prevented by advances in laser surgery techniques such as more selective or more complete coagulation of anastomoses, or by adaptation of inclusion criteria for laser surgery is not known. Considering the high incidence of adverse neurodevelopmental outcome in TTTS, we recommend that all surviving twins be thoroughly followed up.

References

1. van Gemert MJ, Umur A, Tijssen JG, Ross MG. Twin-twin transfusion syndrome: etiology, severity and rational management. Curr Opin Obstet Gynecol 2001;13:193-206.

2. Mari G, Roberts A, Detti L, Kovanci E, Stefos T, Bahado-Singh RO *et al.* Perinatal morbidity and mortality rates in severe twin-twin transfusion syndrome: results of the International Amnioreduction Registry. Am J Obstet Gynecol 2001;185:708-15.

3. Huber A, Hecher K. How can we diagnose and manage twin-twin transfusion syndrome? Best Pract Res Clin Obstet Gynaecol 2004;18:543-56.

4. Jain V, Fisk NM. The twin-twin transfusion syndrome. Clin Obstet Gynecol 2004;47:181-202.

5. Senat MV, Deprest J, Boulvain M, Paupe A, Winer N, Ville Y. Endoscopic laser surgery versus serial amnioreduction for severe twin-to-twin transfusion syndrome. N Engl J Med 2004;351:136-44.

6. Sutcliffe AG, Sebire NJ, Pigott AJ, Taylor B, Edwards PR, Nicolaides KH. Outcome for children born after in utero laser ablation therapy for severe twin-to-twin transfusion syndrome. BJOG 2001;108:1246-50.

7. Banek CS, Hecher K, Hackeloer BJ, Bartmann P. Long-term neurodevelopmental outcome after intrauterine laser treatment for severe twin-twin transfusion syndrome. Am J Obstet Gynecol 2003;188:876-80.

8. Graef C, Ellenrieder B, Hecher K, Hackeloer BJ, Huber A, Bartmann P. Long-term neurodevelopmental outcome of 167 children after intrauterine laser treatment for severe twin-twin transfusion syndrome. Am J Obstet Gynecol 2006;194:303-08.

9. Wittmann BK, Baldwin VJ, Nichol B. Antenatal diagnosis of twin transfusion syndrome by ultrasound. Obstet Gynecol 1981;58:123-27.

10. Quintero RA, Morales WJ, Allen MH, Bornick PW, Johnson PK, Kruger M. Staging of twin-twin transfusion syndrome. J Perinatol 1999;19:550-55.

11. Surveillance of cerebral palsy in Europe: a collaboration of cerebral palsy surveys and registers. Surveillance of Cerebral Palsy in Europe (SCPE). Dev Med Child Neurol 2000;42:816-24.

12. Lopriore E, Wezel-Meijler G, Middeldorp JM, Sueters M, Vandenbussche FP, Walther FJ. Incidence, origin, and character of cerebral injury in twin-to-twin transfusion syndrome treated with fetoscopic laser surgery. Am J Obstet Gynecol 2006;194:1215-20.

13. De Lia JE, Kuhlmann RS, Lopez KP. Treating previable twin-twin transfusion syndrome with fetoscopic laser surgery: outcomes following the learning curve. J Perinat Med 1999;27:61-67.

14. Lopriore E, Nagel HT, Vandenbussche FP, Walther FJ. Long-term neurodevelopmental outcome in twin-to-twin transfusion syndrome. Am J Obstet Gynecol 2003;189:1314-19.

15. Haverkamp F, Lex C, Hanisch C, Fahnenstich H, Zerres K. Neurodevelopmental risks in twin-to-twin transfusion syndrome: preliminary findings. Eur J Paediatr Neurol 2001;5:21-27.

16. Cincotta RB, Gray PH, Phythian G, Rogers YM, Chan FY. Long term outcome of twin-twin transfusion syndrome. Arch Dis Child Fetal Neonatal Ed 2000;83:F171-F176.

17. Frusca T, Soregaroli M, Fichera A, Taddei F, Villani P, Accorsi P, Martelli P. Pregnancies complicated by Twin-Twin transfusion syndrome: outcome and long-term neurological follow-up. Eur J Obstet Gynecol Reprod Biol 2003;107:145-50.

18. Mari G, Detti L, Oz U, Abuhamad AZ. Long-term outcome in twin-twin transfusion syndrome treated with serial aggressive amnioreduction. Am J Obstet Gynecol 2000;183:211-17.

19. Lopriore, E, Sueters, M, Middeldorp, JM, Vandenbussche, FPHA, Walther, FJ. Neurological and cardiovascular morbidity in severe twin-to-twin transfusion syndrome treated with endoscopic laser surgery. LETTS' study (Leiden TTS study). http://www.lumc.nl/3050/research/research.letts%20study.html. 1-12-2004 (Electronic Citation).

20. Barker DJ. In utero programming of chronic disease. Clin Sci (Lond) 1998;95:115-28.

21. Dickinson JE, Duncombe GJ, Evans SF, French NP, Hagan R. The long term neurologic outcome of children from pregnancies complicated by twin-to-twin transfusion syndrome. BJOG 2005;112:63-68.

22. Hack M, Fanaroff AA. Outcomes of children of extremely low birthweight and gestational age in the 1990's. Early Hum Dev 1999;53:193-218.

23. Taylor MJ, Govender L, Jolly M, Wee L, Fisk NM. Validation of the Quintero staging system for twin-twin transfusion syndrome. Obstet Gynecol 2002;100:1257-65.

Selective feticide in monoamniotic twin pregnancies by umbilical cord occlusion and transection

Johanna M Middeldorp
Frans J Klumper
Dick Oepkes
Humphrey HH Kanhai
Frank PHA Vandenbussche

(based on: Fetal Diagnosis and Therapy, accepted for publication)

7

Abstract

Objective: In monoamniotic twin pregnancies discordant for fetal anomaly, parents may opt for selective feticide. However, the normal co-twin remains at risk of sudden demise from cord entanglement. We report on three cases of successful selective feticide by cord occlusion combined with cord transection.

Methods: We describe technical details and outcome of three monoamniotic twin pregnancies, discordant for fetal anomaly (two cases of anencephaly and one case of congenital heart block), in which cord occlusion was followed by transection of the cord, using contact laser.

Results: The fetoscopic cord occlusion and transection, using laser, was successfully performed at 15, 16 and 19 weeks' gestation, respectively. In one case, amniotic fluid leakage occurred after fetoscopy. The surviving co-twins were born healthy, two out three vaginally, at 36, 38 and 36 weeks' gestation, respectively.

Conclusion: In monoamniotic twins, selective feticide using laser occlusion and transection of the umbilical cord is technically feasible and can lead to near-term vaginal birth of healthy co-twins.

Introduction

Monoamniotic twins occur in approximately 1% of monozygotic twin pregnancies. Monoamniotic twins are at increased risk of fetal anomalies, twin-to-twin transfusion syndrome (TTTS), fetal death and premature delivery. Perinatal mortality rates of 10-70% have been reported.[1;2] Entanglement and knots of the umbilical cords are the major cause of fetal death in monoamniotic twins.[3] Cord entanglement is present in over 70% of monoamniotic twins, and is already seen in the first trimester.[3;4] It is speculated that the occurrence and the fastening of knots occurs more easily when there is more amniotic fluid in relation to the fetal body masses. Several methods have been described that aim at lowering perinatal mortality from cord entanglement: reduction of amniotic fluid by amniodrainage, or administration of sulindac.[5;6] Also, intensive inpatient fetal monitoring with elective preterm delivery has been described.[6;7] Furthermore, congenital anomalies are found in 15-20% of monozygotic twin pregnancies, and may or may not be concordant.[8] In case of congenital anomalies in one fetus of a monochorionic twin pair, the otherwise normal co-twin is at risk for in utero demise due to acute perimortem blood loss into the dying co-twin.[9] In addition, obstetric complications, due to the anomaly, for example polyhydramnios in pregnancies complicated by anencephaly, can present a threat to the normal co-twin. In twin pregnancies with one anomalous fetus, selective feticide can be indicated for two reasons, either to prevent the birth of a severely handicapped child, or to protect the normal co-twin against the described complications. Both in monochorionic and monoamniotic twin pregnancies, selective feticide should not be performed using fetal drug injection because of the presence of vascular anastomoses on the placental surface and the risk of acute hypovolaemia in the normal co-twin during demise of the anomalous twin. Therefore, umbilical cord occlusion is the method of choice. However, after cord occlusion in monoamniotic twins, the incidence of cord accidents from entanglement and strangulation is still a serious threat, and reported to be as high as 36%.[10] Therefore, transection of the occluded cord may be life saving for the normal co-twin.

We report our experience with selective feticide using laser energy for occlusion and transection of the umbilical cord, in three cases of monoamniotic twins discordant for congenital anomalies.

Case 1

A 32-year-old woman was referred to our centre, which is the national referral centre for invasive fetal treatment in the Netherlands, at 14+1 weeks' gestation, with a monoamniotic twin pregnancy complicated by one fetus with anencephaly. On ultrasound examination, the presence of anencephaly in one fetus was confirmed, the other fetus showed no signs of structural anomalies. Colour Doppler showed signs of cord entanglement. During counselling, consideration was given to the risk for the normal co-twin on the basis of cord entanglement, the risk of polyhydramnios with anencephaly and other known risks of monochorionic monoamniotic twinning. The couple opted for selective feticide of the anencephalic fetus. The procedure was performed at 15+4 weeks' gestation under general anaesthesia. A prophylactic dose of tocolytics (indomethacin) and antibiotics (amoxycillin/clavulanate) was given. An 18-G needle was entered into the amniotic cavity under ultrasound guidance, followed by introduction of a 0.085-inch soft J-tipped guide wire (Cook®) through the needle using the Seldinger technique. A 10 F teflon cannula, loaded with a dilator, was advanced over the guide wire. When the cannula had entered the amniotic cavity, the quide wire and dilator were removed and the shaft loaded with the fetoscope (2 mm diameter) and laser fibre (400µm) was inserted. This procedure was also sonographically guided.
Amniotic fluid was blood stained, as is often the case in the presence of an anencephalic fetus. Amnioexchange with warm Ringers lactate was performed until a clear fluid compartment was reached. The umbilical cord of the abnormal fetus was identified and cord knots were present (*Figure 1*).
Under fetoscopic sight and ultrasound guidance, the umbilical cord of the anencephalic fetus was coagulated by laser energy (Nd:YAG laser, Dornier Medizin Technik, Germering, Germany), close to the abdominal insertion of the umbilical cord, over a distance of 15 mm, using short bursts of 5-10

seconds, with a maximum power of 50 Watts. We aimed at whitening and shrinking the cord over a distance of 15 mm, as can be observed by direct visualisation, using the laser fibre (diameter 0.4 mm) as a reference, and also by sonographic measurement. Vascular occlusion was confirmed with colour Doppler ultrasound. Hereafter, the occluded cord was transected with the same laser fibre, set in the cutting mode (50 Watts). The procedure had an uneventful course. During the procedure, the normal fetus showed no changes in heart rate. Several weeks after the procedure, some leakage of amniotic fluid occurred. This leakage continued during pregnancy and resulted in oligohydramnios. Despite fluid leakage, the pregnancy continued uneventfully until the near term period. At 36+3 weeks' gestation the woman went into labour and gave birth vaginally to a healthy boy weighing 3160 gram and a 5-min Apgar score of 9. The neonatal course was uneventful.

Case 2

A 32-year-old woman, known with insulin-dependent diabetes mellitus, was referred to our hospital at 16+3 weeks' gestation, with a monoamniotic twin pregnancy complicated by one fetus with anencephaly. On ultrasound examination the diagnosis of anencephaly was confirmed. On colour Doppler, signs of cord entanglement were present. The other fetus showed no structural anomalies. After counselling, the couple opted for selective feticide of the fetus with anencephaly. The procedure was performed at 16+4 weeks' gestation under general anaesthesia. A prophylactic dose of tocolytics (indomethacin) and antibiotics (amoxycillin/clavulanate) were given. The placenta covered the anterior uterine wall completely and, although very unusual even in anterior placenta, no placenta-free area could be identified for safe fetoscopic entry. Therefore, a midline laparotomy was performed. The uterus was gently exteriorised and an embryoscope (1 mm diameter) and laser fibre (400μm) were introduced through the posterior uterine wall into the amniotic cavity under ultrasound guidance. Amniotic fluid was clear. The umbilical cord of the abnormal fetus was identified. The presence of multiple complex cord knots was confirmed. Under embryoscopic sight

and ultrasound guidance, the umbilical cord of the anencephalic fetus was coagulated by laser energy, close to the abdominal insertion of the umbilical cord, over a distance of 15 mm, using short bursts of 5-10 seconds, with a maximum power of 30 Watts. Occlusion was confirmed with colour Doppler ultrasound. Hereafter, the occluded cord was transected with the laser fibre (400µm), set in the cutting mode (30 Watts). The procedure had an uneventful course. During the procedure, the normal fetus showed no changes in heart rate. Postoperative course was uneventful. At 37 weeks' gestation the patient developed hypertension and episodes of hypoglycaemia. She was admitted to the referring hospital and ultrasound investigation showed macrosomia of the fetus. Labour was induced at 38 weeks' gestation and a caesarean section was performed because of failure to progress. A healthy girl weighing 4044 gram was born.

Case 3

A 33-year-old woman was referred to our hospital at 18+0 weeks' gestation with a monoamniotic twin pregnancy complicated by one fetus with severe ventricular bradycardia of 47 beats per minute, due to a congenital heart block. Maternal serum tested negative for anti-SSA and anti-SSB antibodies. Diagnosis of congenital heart block was confirmed by fetal echocardiography. Cord entanglement with a complex knot was visible on ultrasound. The other fetus showed no anomalies. After extensive counselling, considering the risk of cardiac failure and death in the fetus with bradycardia and the subsequent risk for the other fetus, the couple opted for selective feticide of the fetus with the heart block. The procedure was performed at 18+6 weeks' gestation under general anesthesia. The placenta was anterior, with a placenta-free window allowing safe percutaneous access. The same procedure as described in case 1 was followed. The amniotic fluid was clear. Once the umbilical cord insertion at the abdominal site of the fetus with the heart block was identified, it became clear that the entangled cords were too close to the abdominal wall of the fetus, making laser coagulation at this site unsafe. At the placental insertion site, the umbilical cords, with insertion close to each other, were free

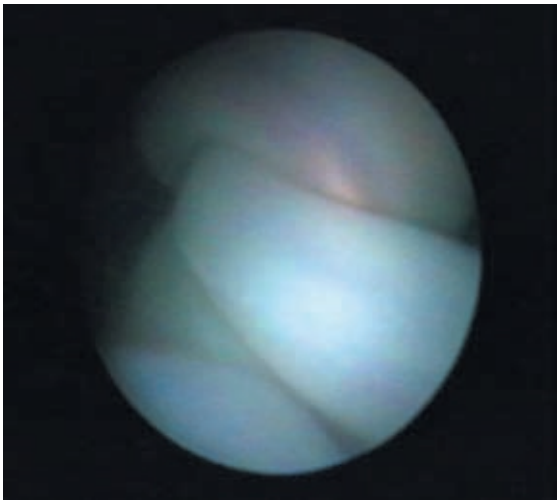

Figure 1 *Fetoscopic view of cord entanglement in a monoamniotic twin pregnancy.*

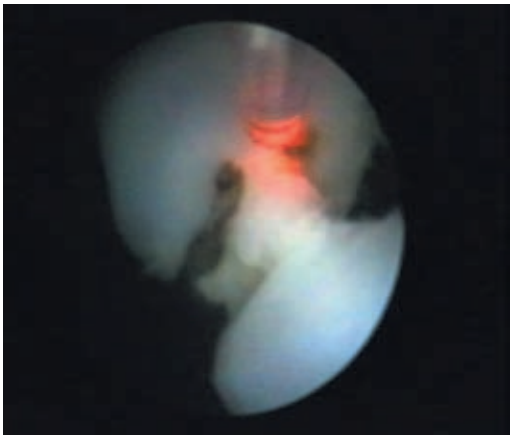

Figure 2 *Fetoscopic view of the occluded umbilical cord being transected using Nd:YAG laser energy through a 400 µm fibre in the cutting mode.*

Figure 3 *Fetoscopic view of the umbilical cord at the placental insertion after transection.*

of knots over a short distance of circa 5 cm. Using Doppler, the umbilical cord of the fetus with bradycardia could easily be identified, and was subsequently coagulated with laser energy and transected as described above (*Figure 2*). Figure 3 shows the cord insertion at the end of the operation. During the procedure, the normal fetus showed no changes in heart rate. The pregnancy proceeded uneventfully. At 35+6 weeks' gestation, the patient was admitted to the referring hospital with premature rupture of membranes and contractions. A healthy girl was born vaginally, with a birth weight of 3100 gram and a 5-min Apgar score of 9.

Discussion

Selective termination in twin pregnancies is to be considered as a management option in the presence of an anomaly in one fetus, severe enough either to lead to the birth of a severely handicapped child, or when it presents a threat to the normal co-twin e.g. by the development of polyhydramnios with risk of preterm birth. In monochorionic twin pregnancies, the placental anastomoses present a serious threat when one of the twins is critically ill or dying, because of acute perimortem TTTS.[9] In case of a monoamniotic twin pregnancy, the risk of cord

entanglement and cord knots adds another major risk, even after the death of one fetus.[10]

Selective feticide by cord occlusion has been widely accepted as a treatment option for monochorionic diamniotic twin pregnancies in case of discordant congenital anomaly, twin reversed arterial perfusion (TRAP) or severe TTTS with a critically ill fetus.[11] In monoamniotic and pseudo monoamniotic twins, additional transection of the umbilical cord has been proposed, to avoid the complications of cord entanglement later in pregnancy.[3;12-16]

Several techniques have been described to interrupt the blood flow in the umbilical cord. Percutaneous ultrasound-guided injection of thrombogenic material in the umbilical cord of an acardiac twin has been performed in various ways, e.g. trombogenic coils, fibrin superglue, or alcohol embedded suture.[17-22] Unfortunately, this procedure has been associated with death of both twins in approximately half of the cases.[18;19] The first described minimally invasive procedure using two 2-3 mm ports was umbilical cord ligation with a 3-0 Vicryl suture.[23] Endoscopically guided photocoagulation of the cord using Nd:YAG laser through a single port was first described by Hecher *et al.*[24] Ultrasound guided bipolar electro coagulation using a bipolar forceps through a 3 mm port was the next technique used for umbilical cord occlusion.[14] In TRAP sequence, the treatment modality of choice is the so-called intrafetal approach.[25]

For transection of the occluded cord, some have proposed the use of scissors, others suggested using a harmonic scalpel via a single 5-mm port technique, or coaxial bipolar electrode (Versapoint®) via a two port technique (diameters 3.8-mm and 2.2mm).[12;13;15] In our three cases, a single port technique with a shaft containing a 2 mm fetoscope or 1 mm embryoscope with a 400 µm laser fibre was used. Under direct and continuous vision, coagulation was performed in the non-contact mode and the cord was transected in the contact mode. Laser occlusion of the umbilical cord has been described to be successful up to 20 weeks' gestation.[26] After 20 weeks, the thickness of the cord and the quantity of Wharton's jelly content limit the effects of laser, and in these cases bipolar coagulation (followed by laser transection) is probably more successful.[27] In monoamniotic twins with cord entanglement

and knots, the optimal identification site of the cord of the affected twin is at the abdominal insertion. Thus, the risk of coagulating the cord of the normal co-twin is small. Another advantage of coagulating the cord close to its abdominal insertion is the lack of mobility of the cord when touching it for the cutting session. In our three cases, the cord was easily transected and no technical complications occurred. In one case, ongoing amniotic fluid leakage occurred, a well-known complication of invasive fetal procedures. Because the risks associated with cord entanglement were ruled out by transecting the cord, near term vaginal birth was made possible.

Conclusion

Laser coagulation and transection of the umbilical cord under direct vision is a minimally invasive single-port-technique that can be safely used for selective feticide in monoamniotic twin pregnancies with discordant congenital anomaly.

References

1. Beasly E, Megerian G, Gerson A, Roberts N: Monoamniotic twins: case series and proposal for antenatal management. Obstet Gynecol 1999;93:130-4.

2. Allen VM, Windrim R, Barrett J, Ohlsson A: Management of monoamniotic twin pregnancies: a case series and systematic review of the literature. BJOG 2001;108:931-6.

3. Aisenbrey GA, Catanzarite VA: Monoamniotic and pseudomonoamniotic twins: sonographic diagnosis, detection of cord entanglement and obstetric management. Obstet Gynecol 1995;86:218-22.

4. Sebire NJ, Souka A, Skentou H, Geerts L, Nicolaides KH: First trimester diagnosis of monoamniotic twin pregnancies. Ultrasound Obstet Gynecol. 2000 Sep;16:223-5.

5. Shveiky D, Ezra Y, Schenker JG, Rojansky N: Monoamniotic twins: an update on antenatal diagnosis and treatment. J Matern Fetal Neonat Med 2004;16:180-6.

6. Pasquini L, Wimalasundera RC, Fichera A, Barigye O, Chappell L, Fisk NM: High perinatal survival in monoamniotic twins managed by prophylactic sulindac, intensive ultrasound surveillance, and Cesarean delivery at 32 weeks' gestation. Ultrasound Obstet Gynecol. 2006;28:681-7.

7. Ezra Y, Shveiky D, Ophir E, Nadjari M, Eisenberg VH, Samueloff A, Rojansky N: Intensive management and early delivery reduce antenatal mortality in monoamniotic twin pregnancies. Acta Obstet Gynecol Scand. 2005;84:432-5.

8. Baldwin VJ: The pathology of monochorionic monozygosity. In Pathology of Multiple Pregnancy. New York, Springer-Verlag, 1994;199-214.

9. Fusi L, McParland P, Fisk N, Nicolini U, Wigglesworth J: Acute twin-twin transfusion: a possible mechanism for brain-damaged survivors after intrauterine death of a monochorionic twin. Obstet Gynecol 1991;78:517-20.

10. Quintero R, Morales W: Percutaneous fetal intervention; in Harrison M (ed): The Unborn Patient. Philadelphia, Saunders, 1999;3:100-5.

11. Ville Y: Selective feticide in monochorionic pregnancies: toys for the boys or standard care? Ultrasound Obstet Gynecol 2003;22:448-50.

12. Quintero R, Lanouette J, Carreno C: Percutaneous ligation and transection of the umbilical cord in complicated monoamniotic twin gestations via operative fetoscopy (abstract). Am J Obstet Gynecol 1997;176:S19.

13. Lopoo JB, Paek BW, Maichin GA, Lipshutz GS, Jennings RW, Farmer DL, Sandberg PL, Feldstein VA, Filly RA, Farrell JA, Harrison MR, Albanese CT: Cord ultrasonic transection procedure for selective termination of a monochorionic twin. Fetal Diagn Ther 2000;15:177-9.

14. Quintero R: Discordant anomalous monochorionic twins. In Diagnostic and operative Fetosopy, Quintero R (ed.). Parthenon Publishing: New York 2002;61-63.

15. Bermudez C, Tejada P, Gonzalez F, Perez-Wulff J, Araujo L, Azpurua H, Cadenas LF, Quintero RA: Umbilical cord transection in twin-reverse arterial perfusion syndrome with the use of a coaxial bipolar electrode (Versapoint). J Matern Fetal Neonatal Med. 2003;14:277-8.

16. Vandenbussche FPHA, Deprest JA, Klumper FJCM, Vandenbroucke WVA, Sollie KM, Kanhai HHH: Minimally-invasive intrauterine treatment in four monochorionic twin pregnancies complicated by an acardiac. Ned Tijdschr Geneesk 2003;147:931-6.

17. Hamada H, Okane M, Koresawa M, Kubo T, Iwasaki H: Fetal therapy in utero by blockage of the umbilical blood flow of acardiac monster in twin pregnancy. Nippon Sanka Fujinka Gakkai Zasshi 1989;41:1803-9.

18. Grab D, Schneider V, Keckstein J: Twin, acardiac, outcome. Fetus 1992;2:11-3.

19. Porreco RP, Barton SM, Haverkamp AD: Occlusion of umbilical artery in acardiac, acephalic twin. Lancet 1991;337:326-7.

20. Roberts R, Shah D, Jeanty P, Beattie J: Twin, acardiac, ultrasound-guided embolization. Fetus 1991;1:5-10.

21. Holzgreve W, Tercanli S, Krings W, Schuierer G: A simpler technique for umbilical-cord blockade of an acardiac twin. N Engl J Med 1994;331:56-7.

22. Sepulveda W, Bower S, Hassan J, Fisk NM: Ablation of acardiac twin by alcohol injection into the intra-abdominal umbilical artery. Obstet Gynecol 1995;86:680-1.

23. Quintero RA, Reich H, Puder KS, Bardicef M, Evans MI, Cotton DB, Romero R: Brief report: umbilical-cord ligation of an acardiac twin by fetoscopy at 19 weeks of gestation. N Engl J Med 1994;330:469-71.

24. Hecher K, Reinhold U, Gbur K, Hackeloer BJ: Interruption of umbilical blood flow in an acardiac twin by endoscopic laser coagulation. Geburtshilfe Frauenheilkd 1996;56:97-100.

25. Tan TYT, Sepulveda W: Acardiac twin: a systematic review of minimally invasive treatment modalities. Ultrasound Obstet Gynecol 2003;22:409-19.

26. Ville Y, Hyett JA, Vandenbussche FP, Nicolaides KH: Endoscopic laser coagulation of umbilical cord vessels in twin reversed arterial perfusion sequence. Ultrasound Obstet Gynecol 1994;4:396-8.

27. Challis D, Gratacos E, Deprest JA: Cord occlusion techniques for selective termination in monochorionic twins. J Perinat Med. 1999;27:327-38.

TTTS after 26 weeks gestation: is there a role for fetoscopic laser surgery?

Johanna M Middeldorp
Enrico Lopriore
Marieke Sueters
Frans J Klumper
Frank PHA Vandenbussche
Dick Oepkes

(based on: British Journal of Obstetrics and Gynecology, accepted for publication)

8

Abstract

Objective: To compare fetoscopic laser surgery with amniodrainage in the treatment of twin-to-twin transfusion syndrome (TTTS) diagnosed after 26 weeks' gestation.

Methods: Treatment of TTTS consisted of either amniodrainage or fetoscopic laser coagulation of vascular anastomoses. Primary outcome was adverse outcome (intrauterine or neonatal death, major neonatal morbidity and/or severe cerebral injury). Secondary outcome was gestational age at birth.

Results: Eleven TTTS cases were treated with amniodrainage and ten with laser surgery. Median gestational age at birth in the amniodrainage group and laser surgery group was 29 and 31 weeks respectively ($p = 0.17$) All infants were born alive. Major neonatal morbidity occurred more often in the amniodrainage group than in the laser surgery group, 27% (6/22) and 0% (0/20) respectively ($p = 0.02$). Severe cerebral injury in the amniodrainage group and laser surgery group occurred in 23% (5/22) and 15% (3/20) respectively ($p = 0.70$). Neonatal mortality in the amniodrainage group and laser surgery group was 14% (3/22) and 0% (0/20) respectively ($p = 0.23$). Overall adverse outcome was 36% (8/22) in the amniodrainage group and 15% (3/20) in the laser surgery group ($p = 0.17$).

Conclusions: In TTTS diagnosed after 26 weeks' gestation, amniodrainage and laser surgery both result in 100% survival. However, infants born after laser surgery have less major neonatal morbidity.

Introduction

Monochorionic twin pregnancies are at risk for developing chronic twin-to-twin transfusion syndrome (TTTS) due to unbalanced inter-twin blood-flow through placental vascular anastomoses. TTTS may occur in 10-15% of monochorionic twin pregnancies, mostly in the second trimester of pregnancy.[1]
The first sonographic signs of TTTS are oliguria in the donor, resulting in oligohydramnios in the donor sac, and polyuria in the recipient, resulting in polyhydramnios and associated risks for preterm birth. Hereafter, more severe signs may occur such as anhydramnios in the donor twin, hydrops fetalis in the recipient twin, and eventually fetal demise.
Serial amnioreduction has been the symptomatic treatment for TTTS for more than two decades. More recently, a cause-oriented approach for TTTS, fetoscopic laser coagulation of vascular anastomoses on the placental surface, was shown to result in significantly higher perinatal survival and improved neurological outcome.[2] However, this randomised controlled trial and most other published studies on the treatment of TTTS with laser surgery were limited to pregnancies treated before 26 weeks' gestation.[2-4]
In monochorionic twin pregnancies, complicated by TTTS diagnosed after 26 weeks' gestation, apart from expectant management or amniodrainage, therapeutic delivery is a management option. In otherwise healthy fetuses, premature birth can lead to major handicaps, such as cerebral palsy, severe cognitive deficits and severe visual or hearing impairments. Neonates that have suffered from chronic TTTS in utero are known to have an additional risk on neurological morbidity, and other characteristic morbidities in TTTS, such as cardiovascular and renal morbidity.[5-7]
The aim of this study was to evaluate the pregnancy and neonatal outcome in TTTS diagnosed after 26 weeks' gestation in relation to treatment with either laser surgery or amniodrainage.

Methods

All consecutive cases of monochorionic twins with chronic TTTS, diagnosed and treated after 26 weeks' gestation at our centre between January 1991 and February 2006 were included in the study. The Leiden University Medical Centre is the national referral centre for fetal therapy. During the study period, indications for treatment for TTTS were as follows: before August 2000, women with TTTS were routinely treated with amniodrainage. Amniodrainage was performed when chronic TTTS was diagnosed using standard prenatal ultrasound criteria: oligohydramnios (deepest vertical pocket ≤ 2cm) in the twin sac of one fetus and polyhydramnios (deepest vertical pocket ≥ 8cm before 20 weeks of gestation or ≥ 10cm after 20 weeks of gestation) in the twin sac of the other fetus.[8] In August 2000 a fetoscopic laser surgery program for TTTS was started at our centre. Since then, women presenting between 16 and 26 weeks' gestation with TTTS Quintero stage 1 and symptomatic polyhydramnios, or Quintero stages ≥ 2, were treated with laser surgery. After August 2000, amniodrainage and laser surgery, when technically feasible, were both discussed as options in case of TTTS Quintero ≥ 2. In Quintero stage 1, or Quintero stage ≥ 2 with a completely anterior placenta, amniodrainage was performed. All procedures were sonographically guided. The fetoscopic laser surgery technique used was described in detail previously and is similar to the method reported by Hecher *et al* and Senat *et al*.[2;4;9] To coagulate the anastomoses a Nd:YAG laser was used (Dornier Medizin Technik, Germering, Germany). The majority of fetoscopic procedures were performed under regional anaesthesia. A prophylactic dose of tocolytics (indomethacin) and antibiotics (amoxycillin/clavulanate) was given routinely. Amniodrainage was performed under continuous ultrasound guidance, using an 18 or 20 Gauge needle. Amniotic fluid was removed until deepest pocket was 6 cm. The procedure was repeated when clinical signs of maternal discomfort recurred. A prophylactic dose of tocolytics (indomethacin) was given routinely.
The following data were extracted from the medical records: gestational age at the time of diagnosis and treatment, Quintero stage prior to treatment, intrauterine fetal death, gestational age at delivery, and mode of delivery.

In the amnioreduction group we recorded the number of therapeutic amnioreductions and total volume of amniotic fluid removed. In the laser surgery group we recorded the total volume of amniotic fluid drained at the end of the laser procedure. In TTTS pregnancies treated after 1999, Quintero stage was assessed routinely prior to treatment.[10] In pregnancies treated before 1999, Quintero stage was determined retrospectively for the purpose of this study. The following neonatal data were recorded: neonatal cranial ultrasound findings, chronic lung disease, symptomatic patent ductus arteriosus, necrotising enterocolitis, renal failure, hydrops fetalis, retinopathy of prematurity, anaemia at birth, polycythaemia-hyperviscosity syndrome requiring partial exchange transfusion and major congenital malformations. Haemoglobin levels were measured from umbilical cord blood. Anaemia at birth was defined as haemoglobin level below the 3rd percentile for gestational age requiring a blood transfusion during the first day of life. Cerebral ultrasound scans were performed in all neonates on the first day of life and thereafter according to our unit protocol. The cranial ultrasound protocol at our neonatal intensive care unit requires a minimum of 3 scans during the first week of life (day 1, 3 and 7), followed by at least 1 scan weekly until discharge. In term infants, repeat cranial ultrasound scans are not performed if scans are normal at birth. Severe cerebral injury on cranial ultrasound scans was defined as the presence of at least one of the following findings: intraventricular haemorrhage grade III, intraventricular haemorrhage with parenchymal involvement, cystic periventricular leucomalacia ≥ grade II, ventriculomegaly, porencephalic or parenchymal cysts or other major cerebral abnormalities associated with adverse neurological outcome, as previously described.[11] Major neonatal morbidity was defined as any of the following: chronic lung disease, necrotising enterocolitis ≥ grade II, retinopathy of prematurity ≥ stage III, major cardiac morbidity requiring surgery or major ischemic limb injury, as previously described.[12]

The primary outcome was a composite outcome, adverse outcome, defined as intrauterine fetal demise, neonatal death, major neonatal morbidity or severe cerebral injury. Gestational age at birth was considered a secondary outcome. Outcome was compared between the amniodrainage and the laser surgery

group. Statistics: Results of categorical variables were compared using Fisher's exact test. Unpaired Student's *t* test was used to compare normally distributed values between two groups. Differences in Quintero stage, in gestational age at treatment and at birth, and in haemoglobin difference at birth were tested by Wilcoxon. A P-value of < 0 .05 was considered statistically significant. Statistical analysis was performed with SPSS version 11.0 (SPSS, Inc., Chicago, Illinois, USA).

Results

During the study period, 21 TTTS cases were diagnosed and treated after 26 weeks' gestation. Before August 2000, 4 TTTS cases were treated with amniodrainage after 26 weeks' gestation. Between August 2000, when the laser program was started, and February 2006, 153 fetoscopic procedures for laser coagulation of vascular anastomoses for TTTS were performed. During this period, another 7 TTTS cases were treated with amniodrainage and 10 TTTS cases underwent laser surgery after 26 weeks' gestation.

In the amniodrainage group, Quintero stage 1, 2, 3 and 4 occurred in 4, 2, 4 and 1 case, respectively. The median gestational age treatment was 27 (range 26-29) weeks' gestation. A mean of 1.6 (range 1-3) amniodrainage procedures was performed, 45% (5/11) of the women underwent more than 1 amniodrainage procedure. Per amniodrainage procedure, a median amniotic fluid volume of 2000 ml (range 500-3500 ml) was removed.

In the laser group, 2 cases had TTTS Quintero stage 2 and 8 cases had TTTS Quintero stage 3. The median gestational age treatment was 27 (range 26-28) weeks' gestation. A median of 5 (range 2-10) anastomoses was coagulated. The maximum power used for coagulation was 70 Watts. At the end of the procedure, a median amniotic fluid volume of 1800 ml (range 0-4200 ml) was removed. The quality of chorionic plate exposure was good in all but one case, there were no difficulties with turbidity of amniotic fluid, and there was no need for amniotic fluid exchange to improve visualisation. Neither placental bleeding nor uterine bleeding occurred. In one case in the laser surgery group,

one amniodrainage procedure was performed three days before laser surgery. In another case in the laser surgery group, the procedure had to be abandoned because of poor visualisation, due to rapid leakage of amniotic fluid into the intraperitoneal cavity after severe vomiting of the patient. In a third case in the laser surgery group, after normalisation of the amniotic fluid in both sacs, the ex-recipient became severely anaemic and was treated with an intrauterine blood transfusion two weeks after laser surgery. Within 48 hours after the intrauterine transfusion, MCA-PSV Doppler studies showed again signs of severe fetal anaemia, cardiotocography demonstrated a sinusoidal pattern and a caesarean section was performed. This case has been described in detail, previously.[13]

Median gestational age at birth in the amniodrainage and laser surgery group was 29 and 31 weeks, respectively (p = 0.17). Median treatment-to-delivery interval in the amniodrainage and laser group was 9 and 31 days, respectively (p = 0.07). In the amniodrainage group, 9/11(82%) patients needed additional tocolysis for which a variety of drugs were used due to changing protocols including ritodrin, atosiban, indomethacin or nifedipin, versus 2/10(20%) in the laser surgery group (nifedipin) (p = 0.009). Steroids for fetal lung maturation were administered in 8/9(89%) and in 6/7(86%) of cases with premature birth < 34 weeks, in the amniodrainage and in the laser surgery group, respectively (p = 1.0) Premature prelabour rupture of membranes (PPROM) < 2 weeks after the intervention occurred in 1/11 (9%) of the cases in the amniodrainage group and in none of the cases in the laser surgery group (p = 1.0). There were no intra-uterine deaths, neither in the amniodrainage group, nor in the laser surgery group.

More then 25% birth weight discordance occurred in 2/11 (18%) of the amniodrainage group and in 2/10 (20%) of the laser surgery group. Major neonatal morbidity occurred only in the amniodrainage group (necrotising enterocolitis grade III, n =3, chronic lung disease, n = 2, terminal renal failure, n=1). Severe cerebral injury was diagnosed in 5 infants in the amniodrainage group (cystic periventricular leucomalacia ≥ grade II, n = 2, bilateral intraventricular haemorrhage grade III, n = 1, bilateral intraventricular haemorrhage with parenchymal involvement and post-haemorrhagic

ventricular dilatation, n =1, ventriculomegaly, n = 1) and in 3 infants in the laser group (ventriculomegaly, n = 1, porencephalic cyst, n = 1, middle cerebral artery infarction, n = 1). Neonatal death occurred in three infants in the amniodrainage group and was caused by terminal renal failure (n =1), bilateral intraventricular haemorrhage with parenchymal involvement and post-hemorrhagic ventricular dilatation (n = 1), and necrotising enterocolitis grade III (n = 1). Overall, adverse outcome in amniodrainage group and laser surgery group was 36% (8/22) and 15% (3/20), respectively (p = 0.17). Details on pregnancy outcome and neonatal outcome in the amniodrainage group and laser surgery group are reported in table 1.

Table 1 *Pregnancy outcome and neonatal outcome in the serial amniodrainage group and laser surgery group*

	Amniodrainage group n = 11/22	**Laser surgery group n = 10/20**	**P-value**
Treatment to delivery interval – days[a]	9 (0-65)	31 (5-75)	0.07
PPROM < 2 weeks after intervention – n (%)	1 (9)	0 (0)	1.0
Gestational age at birth – weeks[a]	29 (27-36)	31 (28-37)	0.17
Birth weight – gr[b]	1472 ± 634	1615± 516	0.43
Haemoglobin difference at birth - g/d[a]	4.0 (0.8-12.2)	1.2 (.0-16.6)	0.37
Anaemia at birth - n (%)	2 (9)	4 (20)	0.40
Polycythaemia at birth - n (%)	3 (14)	1 (5)	0.61
Major neonatal morbidity - n (%)	6 (27)	0 (0)	0.02
Severe cerebral injury - n (%)	5 (23)	3 (15)	0.70
Neonatal death - n (%)	3 (14)	0 (0)	0.23
Adverse outcome[c] - n (%) (%)	8 (36)	3 (15)	0.17

[a] *values given as median (range)*
[b] *values given as mean ±SD*
[c] *intrauterine fetal demise, neonatal death, major neonatal morbidity or severe cerebral injury*

Discussion

In this study we found that in TTTS diagnosed after 26 weeks' gestation, treatment with laser surgery was associated with a trend towards higher gestational age at birth and a longer treatment-to-delivery interval, and with significantly less major neonatal morbidity than in TTTS treated with amnioreduction. Neonatal morbidity such as necrotising enterocolitis and chronic lung disease are known to be directly related to prematurity, suggesting a direct relationship between the lower gestational age at birth in the amnioreduction group and the higher rate of major neonatal morbidity. Severe cerebral injury was similar in the laser group and amnioreduction group. As previously reported, the majority of cerebral injury in TTTS is of antenatal origin.[11;14-16] This may explain why TTTS survivors treated with laser surgery in this study do not have a lower incidence of severe cerebral injury despite the more advanced gestational age at birth. Overall, we found a trend towards less adverse outcome in TTTS treated with laser as compared with amnioreduction, but numbers were probably too small to reach significance. For a randomised controlled trial comparing amnioreduction with laser after 26 weeks' gestation with a power of 0.80, a total of 126 patients, 63 in each arm would be needed to show that the expected reduction in adverse outcome from 36% to 15% is statistically significant.

In severe second trimester TTTS, because of the poor survival rates with conservative management, there is general consensus that therapy should be offered. Fetoscopic laser coagulation of vascular anastomoses on the placental surface is associated with significantly higher perinatal survival and improved neurological outcome as compared with serial amioreduction[2]. However, most published series of TTTS cases treated with laser surgery are limited to gestational ages under 26 weeks.[2;4;17;18] Only one case series included patients until 28 weeks' gestation.[19] To our knowledge, no specific details on neonatal outcome after laser surgery or amniodrainage for TTTS performed after 26 weeks' gestation have yet been reported.

When TTTS occurs after 26 weeks' gestation, common advice for management is either to perform one or more amniodrainages or, in selected cases of severe

TTTS, preterm delivery. Both options are associated with a significant risk of neonatal death or major neurological sequelae, either due to problems related to the invasive nature of the procedure with inherent risks of premature birth, or to TTTS itself.[20-22] Laser surgery is usually not advocated as the treatment of choice in early third trimester TTTS, possibly because of the expected higher rate of complications such as premature rupture of membranes as compared with amniodrainage. Our preliminary data show that new consideration should be given to laser surgery as a valid alternative to amniodrainage in early third trimester TTTS.

Performing a successful uncomplicated laser procedure allows the fetuses to recover from TTTS in utero and results in more advanced gestational age at birth. Selection of the cases at minimal risk of complications is an important, but difficult issue. Placental localisation, and in particular anterior placental localisation, is an important issue in fetoscopic laser surgery. In this non-randomised descriptive study, placental localisation was mainly posterior (7 cases), or anterior with a placenta free window for lateral percutaneous access (3 cases). In this selected group of cases laser surgery was feasible. Obviously, due to the retrospective character of this study, our results are subjected to a selection bias. Another important, but inevitable limitation of this study is the small number of cases. In order to determine the best management of early third trimester TTTS, further studies are urgently needed. Considering the low incidence of TTTS presenting after 26 weeks' gestation, the ideal setting of such a study would be a sufficiently large multi-centre randomised study.

Conclusion

In this study, less major neonatal morbidity occurred in TTTS cases, diagnosed and treated after 26 weeks' gestation as compared with amniodrainage.
This finding suggests that fetoscopic laser surgery is a valid alternative to amniodrainage in the treatment of TTTS after 26 weeks.

References

1. Sebire NJ, Souka A, Skentou H, Geerts L, Nicolaides H. Early prediction of severe twin-to-twin transfusion syndrome. Hum Reprod 1997;15:2008-10.

2. Senat MV, Deprest J, Boulvain M, Paupe A, Winer N, Ville Y. Endoscopic laser surgery versus serial amnioreduction for severe twin-to-twin transfusion syndrome. N Engl J Med 2004;351:136-44.

3. De Lia JE, Kuhlmann RS, Lopez KP. Treating previable twin-twin transfusion syndrome with fetoscopic laser surgery: Outcomes following the learning curve. J Perinat Med 1999;27:61-7.

4. Hecher K, Diehl W, Zikulnig L, Vetter M, Hackeloer BJ. Endoscopic laser coagulation of placental anastomoses in 200 pregnancies with severe mid-trimester twin-to-twin transfusion syndrome. Eur J Obstet Gynecol Reprod Biol 2000;92:135-39.

5. Karatza AA, Wolfenden JL, Taylor MJ, Wee L, Fisk NM, Gardiner HM. Influence of twin-twin transfusion syndrome on fetal cardiovascular structure and function: prospective case-control study of 136 monochorionic twin pregnancies. Heart 2002;88:271-7.

6. Christensen AM, Daouk GH, Norling LL, Catlin EA, Ingelfinger JR. Postnatal transient renal insufficiency in the feto-fetal transfusion syndrome. Pediatr Nephrol 1999;13:117-20.

7. De Paepe ME, Stopa E, Huang C, Hansen K, Luks FI. Renal tubular apoptosis in twin-to-twin transfusion syndrome. Pediatr Dev Pathol 2003;6:215-25.

8. Wittmann BK, Baldwin VJ, Nichol B. Antenatal diagnosis of twin transfusion syndrome by ultrasound. Obstet Gynecol 1981;58:123-27.

9. Middeldorp JM, Sueters M, Lopriore E, Klumper FJCM , Oepkes D, Devlieger R, Kanhai HHH, Vandenbussche FPHA. Fetoscopic laser surgery in 100 pregnancies with severe twin-to-twin transfusion syndrome in the Netherlands. Fetal Diagn Ther 2007;22:190–194.

10. Quintero RA, Morales WJ, Allen MH, Bornick PW, Johnson PK, Kruger M. Staging of twin-twin transfusion syndrome. J Perinatol 1999;19:550-5.

11. Lopriore E, Wezel van-Meijler G, Middeldorp JM, Sueters M, Vandenbussche FP, Walther FJ. Incidence, origin and character of cerebral injury in twin-to-twin transfusion syndrome treated with fetoscopic laser surgery. Am J Obstet Gynecol 2006;194:1215-20.

12. Lopriore E, Sueters M, Middeldorp JM, Oepkes D, Vandenbussche FP, Walther FJ. Neonatal outcome in twin-to-twin transfusion syndrome treated with fetoscopic laser occlusion of vascular anastomoses. J Pediatr 2005;147:597-602.

13. Lopriore E, Middeldorp JM, Oepkes D, Kanhai HH, Walther FJ, Vandenbussche FP. Twin anemia-polycythemia sequence in two monochorionic twin pairs without oligo-polyhydramnios sequence. Placenta 2007;28:47-51.

14. Bejar R, Vigliocco G, Gramajo H, Solana C, Benirschke K, Berry C *et al*. Antenatal origin of neurologic damage in newborn infants. II. Multiple gestations. Am J Obstet Gynecol 1990;162:1230-36.

15. Denbow ML, Battin MR, Cowan F, Azzopardi D, Edwards AD, Fisk NM. Neonatal cranial ultrasonographic findings in preterm twins complicated by severe fetofetal transfusion syndrome. Am J Obstet Gynecol 1998;178:479-83.

16. Banek CS, Hecher K, Hackeloer BJ, Bartmann P. Long-term neurodevelopmental outcome after intrauterine laser treatment for severe twin-twin transfusion syndrome. Am J Obstet Gynecol 2003;188:876-80.

17. De Lia JE, Kuhlman RS, Harstad TW, Cruikshank DP. Fetoscopic laser ablation of placental vessels in severe previable twin-twin transfusion syndrome. Am J Obstet Gynecol 1995;172:1202-11.

18. Quintero RA, Bornick PW, Allen MH, Johnson PK. Selective laser photocoagulation of communicating vessels in severe twin-twin transfusion syndrome in women with an anterior placenta. Obstet Gynecol 2001;97:477-81.

19. Ville Y, Hecher K, Gagnon A, Sebire N, Hyett J, Nicolaides K. Endoscopic laser coagulation in the management of severe twin-to-twin transfusion syndrome. Br J Obstet Gynecol 1998;105:446-53.

20. Lopriore E, Nagel HTC, Vandenbussche FPHA, Walther FJ. Long-term neurodevelopmental outcome in twin-to-twin transfusion syndrome. Am J Obstet Gynecol 2003;189:1314-9.

21. Gemert JC van, Umur A, Tijssen JGP, Ross M. Twin-twin transfusion syndrome: etiology, severity and rational management. Curr Opin Obstet Gynecol 2001;13:193-206.

22. Dickinson JE, Evans SF. Obstetric and perinatal outcomes from the Australian and New Zealand twin-twin transfusion syndrome registry. Am J Obstet Gynecol. 2000;182:706-12.

General discussion and future perspectives

9

General discussion and future perspectives

In monochorionic twin pregnancies, the fetuses share a common placenta with vascular anastomoses between both circulations and have a significantly higher risk of adverse outcome than dichorionic twins and singletons. Complications in monochorionic twin gestation include twin-to-twin transfusion syndrome (TTTS), severe intrauterine growth retardation (IUGR), twin reversed arterial perfusion (TRAP), increased rate of fetal anomalies, and death of the co-twin. In the case of single intrauterine fetal demise in monochorionic twin pregnancies, the vascular anastomoses allow the transfer of blood from the surviving twin to the dead twin, the so-called acute perimortem intertwin transfusion, which can lead to periods of hypoperfusion, hypotension, acute fetal anaemia, eventually resulting in co-twin demise and neurologic abnormality in the surviving co-twin.

In the last decades, important advances have been made in fetoscopic treatment. However, few of these interventions are evidence-based, and many questions remain to be answered. These questions pertain to type and timing of treatment in TTTS and severe discordant IUGR, and to the prevention of PROM after fetoscopic interventions.

TTTS

Today, laser surgery is considered to be the first choice of treatment for severe TTTS between 16 and 26 weeks' gestation.[1] There is still debate, however, on whether and how to treat TTTS Quintero stage 1. In contrast to Quintero *et al,* who reported that stage is not an important prognostic factor when laser therapy is involved, we found that the earlier the Quintero stage at the time of treatment, the better the outcome (Chapter 3).[2] Our findings are in accordance with the results of a randomised study reporting significantly better perinatal outcome of fetoscopic laser surgery in Quintero stages 1 and 2 as compared to stages 3 and 4; our findings also agreed with the results published by Huber *et al*, who reported a significant trend toward reduced survival rates

after treatment with laser surgery for fetuses at later Quintero stages.[1;3] These findings support the hypothesis that laser surgery should be the first choice of treatment, even in early Quintero stages.

There is controversy about the best way to manage TTTS diagnosed early in the 3rd trimester. Apart from expectant management or amniodrainage, elective delivery is an option. In otherwise healthy fetuses, premature birth can lead to major handicaps, such as cerebral palsy, severe cognitive deficits, and severe visual or hearing impairments. Neonates that have suffered from chronic TTTS in utero are known to have an additional risk of neurological morbidity, and other characteristic morbidities in TTTS, such as cardiovascular and renal morbidity.[5-7] Laser surgery is usually not advocated as the treatment of choice in early third trimester TTTS, possibly because of the expected higher rate of complications compared with amniodrainage, including premature rupture of membranes. The preliminary data described in this thesis (Chapter 8), comparing amniodrainage and laser surgery for treatment of TTTS diagnosed after 26 weeks' gestation, shows that laser surgery should be considered as a valid alternative to amniodrainage in early third trimester TTTS. In order to determine the best way to manage early third trimester TTTS, further studies are urgently needed. Considering the low incidence of TTTS appearing after 26 weeks' gestation, the ideal setting of such a study would be a sufficiently large, multi-centre randomised study.

Incomplete laser surgery and residual anastomoses do not necessarily result in recurrence or reversal of TTTS (see Chapter 4). Recently, an atypical form of chronic TTTS has been described, the so-called twin anaemia-polycythaemia sequence.[7] This phenomenon occurs in the absence of a twin oligo-polyhydramnios sequence (TOPS) and therefore does not fulfill the criteria of TTTS. In the reported cases, placental injection studies revealed the presence of very small (<1 mm) uni-directional arterio-venous anastomoses. Robyr *et al* also reported that TAPS developed after incomplete laser surgery, in 13 of 101 TTTS cases, and Lewi *et al* reported it in 4 of 43 TTTS cases with double survivors at birth.[8;9] Usually, it was the former recipient who became anaemic,

whereas the former donor became polycythaemic. Treatment options include expectant management, re-intervention with laser coagulation of the residual vascular anastomoses, feticide by cord coagulation, intrauterine transfusion, and elective delivery when appropriate. Expectant management carries the risk of the anaemic fetus developing hydrops, followed by intra-uterine death. Re-intervention incurs both procedure-related risks and the risk of operative failure as a result of the inability to identify the residual anastomoses due to their small diameter. Because of ongoing fetofetal transfusion, intra-uterine transfusion only gives a temporary rise of the anaemic fetus' hemoglobine count, and it exposes the polycythaemic fetus to the risk that polycythaemia-hyperviscosity syndrome will be aggravated, which is known to be a risk factor for necrotic tissue injury and gangrene.[10;11] However, since it is not certain whether TAPS is associated with increased morbidity or mortality, the question whether and how to treat it still needs to be clarified.

Severe discordant IUGR

The distinction between TTTS and IUGR is based on the absence of polyhydramnios in the sac of the appropriately grown fetus in discordant IUGR. Birth weight discordance carries a greater risk of complications in monochorionic twin pregnancies than in dichorionic ones because of the vascular anastomoses on the placental surface.
Several studies have reported on perinatal outcome of monochorionic pregnancies complicated by discordant growth retardation. Gratacos *et al* reported that the presence of intermittently absent or reversed end diastolic flow in the umbilical artery in monochorionic twins with selective IUGR, identifies a subgroup with an elevated risk of intrauterine demise of the smaller twin and neurological damage in the larger twin, the latter even in the case where the smaller co-twin survives.[12] Another study showed that monochorionic infants had a seven-fold higher incidence of cerebral white matter lesions than dichorionic infants.[13] Discordant birth weight, TTTS, and being a survivor after co-twin demise were independent risk factors

for cerebral white matter lesions. Huber *et al* concluded that amniotic fluid discordance in monochorionic diamniotic twin pregnancies in combination with IUGR and absent or reversed end diastolic flow in the umbilical artery in one fetus represents an extremely high-risk constellation for adverse pregnancy outcome.[14] This raises the question whether an intervention could optimise outcome. Treatment options are expectant management, fetoscopic laser coagulation of vascular anastomoses, umbilical cord ligation of the growth-retarded fetus, or elective delivery when appropriate. The risks of expectant management have been described above. Fetoscopic laser surgery aims to "bichorionise" the monochorionic twin pair, after which nature can follow its course without risk of adverse effects on the normal co-twin in case the condition of the growth-retarded fetus deteriorates. However, in the absence of severe oligo-polyhydramnios sequence, fetoscopic laser surgery is a technical challenge, with the potential risk of impaired visualisation and inability to identify and coagulate all anastomoses, as well as possibly requiring excessive amnion infusion. When performing umbilical cord ligation of the growth-retarded fetus, fetoscopic entry is preferably via the sac of this fetus without perforating the intertwin membrane, but severe oligohydramnios may prevent optimal fetoscopic entry. Moreover, the decision to perform umbilical cord ligation puts the parents in the difficult emotional situation, where they have to choose to give up on one child in order to save the other. Quintero *et al* suggested that a trial of laser surgery versus expectant management is indicated in monochorionic twins with highly discordant intrauterine growth restriction, and such a randomised trial is currently being conducted in the United States.[15]

Rupture of the fetal membranes after fetoscopic interventions

One of the major problems associated with invasive procedures is the risk of "iatrogenic" preterm prelabour rupture of membranes (iPPROM). Subclinical amniotic fluid leakage in the immediate postoperative period probably occurs more often than previously thought, but when it persists and becomes clinically

relevant it is called iPPROM.[16;17] Within 1 week of intervention, 7% of fetoscopic laser procedures for TTTS are complicated by iPPROM.[18] For more complex fetoscopic procedures, the risk can be up to 30%.[19] Since most invasive procedures are performed in the second trimester of pregnancy, iPPROM usually occurs at an early gestational age, with important fetal consequences (perinatal mortality and morbidity) and maternal ones (chorioamnionitis). This, of course, limits the clinical use of the fetoscopic technique and is a major obstacle for further development. It is important to develop strategies to seal the membrane defect or stimulate the repair mechanisms of fetal membranes at the time of the procedure. In the last six years, several (case) reports have been published on fetal membrane sealing strategies after iPPROM. In a series of 22 cases, Quintero *et al* describe 8 cases with iPPROM and 14 cases with amnion-chorion dissociation after amniocentesis or fetoscopy between 16 and 24 weeks' gestation.[20] As an experimental treatment, the uterine cavity was punctured with a 22 Gauge needle, and various volumes of platelets and cryoprecipitate were injected intra-amniotically. Using this "amnion-patch" technique, the amniotic fluid leakage stopped in 9 cases, and 18 of 32 fetuses survived (56%). However, 2 cases were complicated by sudden intrauterine fetal death, possibly as a result of severe haemodynamic changes induced by platelet activation. These serious complications stress the need for further research to develop strategies and regimens to heal defects in the fetal membranes after iPPROM.[21] In the meantime, every indication for fetoscopic surgery should be carefully weighed by an experienced team. During fetoscopic procedures, the best means of preventing iPPROM is by reducing the size and number of uterine entry ports.

Important advances have been made in the field of fetoscopic fetal therapy during the past decade. However, untimely treatment and pregnancy and neonatal complications still occur frequently. More research and new developments are required to further improve fetoscopic techniques and to further reduce complications.

References

1. Senat MV, Deprest J, Boulvain M, Paupe A, Winer N, Ville Y. Endoscopic laser surgery versus serial amnioreduction for severe twin-to-twin transfusion syndrome. N Engl J Med 2004;351:136-44.

2. Quintero RA, Dickinson JE, Morales WJ, Bornick PW, Bermudez C, Cincotta R et al. Stage-based treatment of twin-twin transfusion syndrome. Am J Obstet Gynecol 2003;188:1333-40.

3. Huber A, Diehl W, Bregenzer T, Hackeloer BJ, Hecher K. Stage-related outcome in twin-twin transfusion syndrome treated by fetoscopic laser coagulation. Obstet Gynecol 2006;108:333-7.

4. Karatza AA, Wolfenden JL, Taylor MJ, Wee L, Fisk NM, Gardiner HM. Influence of twin-twin transfusion syndrome on fetal cardiovascular structure and function: prospective case-control study of 136 monochorionic twin pregnancies. Heart 2002;88:271-7.

5. Christensen AM, Daouk GH, Norling LL, Catlin EA, Ingelfinger JR. Postnatal transient renal insufficiency in the feto-fetal transfusion syndrome. Pediatr Nephrol 1999;13:117-20.

6. De Paepe ME, Stopa E, Huang C, Hansen K, Luks FI. Renal tubular apoptosis in twin-to-twin transfusion syndrome. Pediatr Dev Pathol 2003;6:215-25.

7. Lopriore E, Middeldorp JM, Oepkes D, Kanhai HH, Walther FJ, Vandenbussche FP. Twin anemia-polycythemia sequence in two monochorionic twin pairs without oligo-polyhydramnios sequence. Placenta 2007;28:47-51.

8. Robyr R, Lewi L, Salomon LJ, Yamamoto M, Bernard JP, Deprest J, Ville Y. Prevalence and management of late fetal complications following successful selective laser coagulation of chorionic plate anastomoses in twin-to-twin transfusion syndrome. Am J Obstet Gynecol 2006;194:796-803.

9. Lewi L, Jani J, Cannie M, Robyr R, Ville Y, Hecher K, Gratacos E, Vandecruys H, Vandecaveye V, Dymarkowski S, Deprest J.Intertwin anastomoses in monochorionic placentas after fetoscopic laser coagulation for twin-to-twin transfusion syndrome: is there more than meets the eye? Am J Obstet Gynecol. 2006;194:790-5.

10. Carr SR, Luks F, Tracy T, Plevyak M. Antenatal necrotic injury in severe twin-to-twin transfusionsyndrome. A case and review. Fetal Diagn Ther 2004;19:370-2.

11. Scott F, Evans N. Distal gangrene in a polycythemic recipient fetus in twin-twin transfusion. Obstet Gynecol 1995;86:677-9.

12. Gratacos E, Carreras E, Becker J, Lewi L, Enriquez G, Perapoch J, Higueras T, Cabero L, Deprest J. Prevalence of neurological damage in monochorionic twins with selective intrauterine growth restriction and intermittent absent or reversed end-diastolic umbilical artery flow. Ultrasound Obstet Gynecol. 2004;24:159-63.

13. Adegbite AL, Castille S, Ward S, Bajoria R. Prevalence of cranial scan abnormalities in preterm twins in relation to chorionicity and discordant birth weight. Eur J Obstet Gynecol Reprod Biol. 2005;119:47-55.

14. Huber A, Diehl W, Zikulnig L, Bregenzer T, Hackeloer BJ, Hecher K.Perinatal outcome in monochorionic twin pregnancies complicated by amniotic fluid discordance without severe twin-twin transfusion syndrome. Ultrasound Obstet Gynecol. 2006;27:48-52.

15. Quintero RA, Bornick PW, Morales WJ, Allen MH. Selective photocoagulation of communicating vessels in the treatment of monochorionic twins with selective growth retardation. Am J Obstet Gynecol 2001;185:689-96.

16. Devlieger R, Cadron I, Van Schoubroeck D, Witters I, Timmerman D, Deprest JA. Amniotic fluid leakage after amniocentesis: biochemical detection, incidence and consequences. J Perinat Med 2001;29:22–3.

17. Papadopulos NA, Van Ballaer PP, Ordonez JL, Laermans IJ, Vandenberghe K, Lerut TE, Deprest JA. Fetal membrane closure techniques after hysteroamniotomy in the midgestational rabbit model.Am J Obstet Gynecol 1998;178:938–42.

18. Yamamoto M, El Murr L, Robyr R, Leleu F, Takahashi Y, Ville Y. Incidence and impact of perioperative complications in 175 fetoscopy-guided laser coagulations of chorionic plate anastomoses in fetofetal transfusion syndrome before 26 weeks of gestation. Am J Obstet Gynecol 2005;193:1110-6.

19. Harrison MR. Surgically correctable fetal disease. Am J Surg 2000;180:335-42.

20. Quintero RA. New horizons in the treatment of preterm premature rupture of membranes. Clin Perinatol 2001;28:861-75.

21. Devlieger R, Millar LK, Bryant-Greenwood G, Lewi L, Deprest JA.Fetal membrane healing after spontaneous and iatrogenic membrane rupture: a review of current evidence. Am J Obstet Gynecol 2006;19:1512-20.

Summary

10

Leiden University Medical Centre (LUMC) is a tertiary medical centre in the Netherlands and serves as the national referral centre for fetal therapy. Since august 2000, when the fetoscopic surgery program was started, several study projects on endoscopic fetal surgery were initiated in close collaboration with the neonatology division of the paediatrics department at LUMC. In this thesis, studies on fetoscopic interventions in complicated monochorionic twin pregnancies are presented.

Chapter 1 is a brief introduction concerning the characteristics of monochorionic twin pregnancies. The major complications of monochorionic twin gestation, twin-to-twin transfusion syndrome (TTTS), severe intrauterine growth retardation (IUGR), increased rate of fetal anomalies, death of the co-twin, and the various therapeutic options are discussed.

In ***Chapter 2*** we assessed the value of serial ultrasound examinations in combination with patient instructions, to report the onset of symptoms, for timely detection of TTTS in a cohort of monochorionic diamniotic twin pregnancies. Timely detection of TTTS was defined as diagnosis before severe complications of TTTS, such as preterm prelabour rupture of membranes, very preterm delivery (24-32 weeks of pregnancy), fetal hydrops, or intrauterine fetal death occurred. Ultrasound and Doppler measurements (nuchal translucency thickness, presence of membrane folding, estimated fetal weight, deepest vertical pocket, bladder filling, and Doppler waveforms of the umbilical artery, ductus venosus, and umbilical vein) were performed at least every 2 weeks. A prospective series of 23 monochorionic twin pregnancies was monitored from the first trimester until delivery. Measurements of TTTS cases were compared with those of non-TTTS cases matched for gestational age. Furthermore, patients were informed about the symptoms caused by TTTS, and instructed to consult us immediately in case of rapidly increasing abdominal size or premature contractions. During the study period, 4 cases of TTTS were diagnosed. In all these cases, the diagnosis was timely (one case was at Quintero Stage 1, two at Quintero Stage 2, and one at Quintero Stage 3).Two of the TTTS cases became apparent after the patients' feeling of rapidly increasing

girth. The identification of TTTS predictors was successful with respect to one parameter: isolated polyhydramnios in one sac, without oligohydramnios in the other, preceded the ultimate diagnosis of TTTS in two of the four TTTS cases. All other ultrasound measurements of TTTS cases, prior to the diagnosis of TTTS, were within the range of measurements of non-TTTS cases. We concluded that biweekly ultrasound examinations, with special attention to amniotic fluid compartments of both fetuses, combined with detailed patient instructions to report the onset of symptoms resulted in timely diagnosis of all TTTS cases and appears to be a safe program for monitoring monochorionic twin pregnancies.

Since August 2000, in the LUMC, fetoscopic laser surgery has been the preferred treatment modality for TTTS. In ***Chapter 3*** we evaluated the results of the first 100 consecutive pregnancies with severe second trimester TTTS treated with selective fetoscopic laser coagulation of vascular anastomoses on the placental surface at our centre. Perinatal survival was analysed in relation to Quintero stage at the time of treatment.
The median gestational age at fetoscopy was 20 weeks (range 16-26), and the median gestation age at delivery was 33 weeks (range 18-40). Perinatal survival rate was 70% (139/200). The treatment resulted in at least one survivor at the age of 4 weeks in 81% of pregnancies. Perinatal survival was significantly higher when treatment was performed in the early Quintero stages (95% in stage 1, 76% in stage 2, 70% in stage 3, 50% in stage 4) ($p=0.02$). We concluded that the initial results of fetoscopic laser surgery for TTTS in our centre were similar to those in specialised centres in other countries. Diagnosis and treatment in the early Quintero stages resulted in significantly higher perinatal survival.

In ***Chapter 4*** the frequency of residual placental vascular anastomoses after fetoscopic laser surgery for TTTS was studied. Presence of residual anastomoses was studied in association with adverse outcome and inter-twin hemoglobin difference at birth. Adverse outcome (fetal demise, neonatal death

or severe cerebral injury) was similar in the groups with and without residual anastomoses, 18% (6/34) and 29% (20/70) respectively (p = 0.23). Large inter-twin hemoglobin differences (> 5 g/dL) were found in 65% (11/17) of cases with residual anastomoses and 20% (7/35) of cases without residual anastomoses (p < 0.01). Anterior placental localization was not associated with a more frequent presence of residual anastomoses. The first conclusion of this study is that laser treatment needs to be improved, as only 2/3 of monochorionic placentas are functionally ”bichorionised”. The second conclusion is that residual anastomoses in this study are not associated with adverse outcome. Lack of association between residual anastomoses and adverse outcome may be partly due to the small size of most residual anastomoses (<1mm diameter in 64% of the cases) and the presence of “protective” residual superficial anastomoses in 35% of the cases. Finally, we conclude that residual anastomoses are often associated with haematological complications in the neonatal period.

In patients with placental localisation on the posterior wall of the uterus, percutaneous insertion of the fetoscope for laser coagulation gives perpendicular access to the chorionic plate and the vascular anastomoses on its surface, and is, in experienced hands, a straightforward procedure. An angle of approximately 90 degrees between chorionic plate and fetoscope and laser fibre provides maximal visualisation of the vascular equator and optimal laser effectiveness. An anterior placenta, however, presents a technical challenge, because perpendicular access is not possible. In ***Chapter 5*** we describe a novel technique for fetoscopy in TTTS with completely anterior placenta where laparoscopy is used to guide safe percutaneous insertion of the fetoscope through the lateral abdominal wall and the dorsal side of the uterus. We compared 16 TTTS pregnancies with completely anterior placenta (study group) treated with this novel technique with 49 TTTS pregnancies treated with conventional percutaneous fetoscopic laser without laparoscopy: 9 of these with partially anterior placenta (control group A) and 40 with lateral or posterior placenta (control group B). In the study group, the procedure-related complication rate was 25% (4/16). In one case uterine entry of the fetoscope from the lateral abdominal wall was not possible due to complex bowel

adhesions. In 3 patients, intraamniotic haemorrhage occurred after fetoscopic entry, preventing complete laser coagulation of anastomoses. One of these patients required two units of blood transfusion. The procedure-related complication rate in control group A and B was 22% (2/9) and 5% (2/40), respectively (intraamniotic haemorrhage n =3, severe leakage of amniotic fluid into the peritoneal cavity, n=1). Perinatal survival in the study group, control group A and control group B was 63% (20/32), 78% (14/18) and 70% (56/80), respectively. We concluded that combined laparoscopy and fetoscopy is a novel technique that enables safe uterine entry and creates optimal visualisation for laser coagulation of inter-twin anastomoses in TTTS pregnancies with completely anterior placenta. Procedure-related complication rate and perinatal survival rate were similar compared to the conventional percutaneous technique. Procedure-related complications occur more often with partially or completely anterior placenta.

Chapter 6 describes the long-term neurodevelopmental outcome in TTTS treated with fetoscopic laser surgery. All TTTS cases treated consecutively at our centre between August 2000 and December 2003 were included in the study. Perinatal mortality was 30% (49/164). Neurological, mental and psychomotor development at 2 years for age was assessed in all TTTS survivors (n = 115). Overall, the incidence of neurodevelopmental impairment was 17% (19/115) and was due to cerebral palsy (n = 8), severe mental developmental delay (n = 9), severe psychomotor developmental delay (n = 12) and deafness (n = 1). From this long-term follow-up study, we concluded that the incidence of neurodevelopmental impairment in TTTS survivors, treated with fetoscopic laser surgery, is high and warrants long-term follow-up.

In monoamniotic twin pregnancies discordant for fetal anomaly, parents may opt for selective feticide by umbilical cord coagulation. However, the normal co-twin remains at risk of sudden demise from cord entanglement. In ***Chapter 7*** we report on three cases of successful selective feticide by cord occlusion combined with cord transection to prevent complications caused by entanglement. We describe technical details and outcome of three

monoamniotic twin pregnancies, discordant for fetal anomaly (two cases of anencephaly and one case of congenital heart block), in which cord occlusion was followed by transection of the cord, using contact laser. The fetoscopic cord occlusion and transection, using laser, was successfully performed at 15, 16 and 19 weeks' gestation, respectively. In one case, amniotic fluid leakage occurred after fetoscopy. The surviving co-twins were born healthy, two out three vaginally, at 36, 38 and 36 weeks' gestation, respectively. We concluded that in monoamniotic twins, selective feticide using laser occlusion and transection of the umbilical cord is technically feasible and can lead to near-term vaginal birth of healthy co-twins.

In monochorionic twin pregnancies, complicated by TTTS diagnosed after 26 weeks' gestation, apart from expectant management or amniodrainage, therapeutic delivery is a management option. In otherwise healthy fetuses, however, premature birth can lead to major handicaps, such as cerebral palsy, severe cognitive deficits and severe visual or hearing impairments. Neonates that have suffered from chronic TTTS in utero are known to have an additional risk of neurological morbidity, and other characteristic morbidities in TTTS, such as cardiovascular and renal morbidity. In ***Chapter 8*** we retrospectively studied 21 TTTS cases, diagnosed after 26 weeks' gestation, and treated in the Leiden University Medical Centre between January 1991 and February 2006 with either amniodrainage or fetoscopic laser surgery. Main outcome measures were adverse outcome (intrauterine or neonatal death, major neonatal morbidity and/or severe cerebral injury) and gestational age at birth. Eleven TTTS cases were treated with amniodrainage and ten with laser surgery. Median gestational age at birth in the amniodrainage group and laser surgery group was 29 and 31 weeks respectively ($p = 0.17$) All infants were born alive. Major neonatal morbidity occurred more often in the amniodrainage group than in the laser surgery group, 27% (6/22) and 0% (0/20) respectively ($p = 0.02$). Severe cerebral injury in the amniodrainage group and laser surgery group occurred in 23% (5/22) and 15% (3/20) respectively ($p = 0.70$). Neonatal mortality in the amniodrainage group and laser surgery group was 14% (3/22) and 0% (0/20) respectively ($p = 0.23$). Overall adverse outcome was 36% (8/22) in the

amniodrainage group and 15% (3/20) in the laser surgery group (p = 0.17). We concluded, that in TTTS diagnosed after 26 weeks' gestation, amniodrainage and laser surgery both result in 100% survival. However, the incidence of major neonatal morbidity in infants born after laser surgery was lower. Our findings suggest that even in TTTS diagnosed after 26 weeks' gestation laser surgery should be considered.

In conclusion, although important advances have been made in the field of fetoscopic fetal therapy during the past decade, untimely treatment and severe perinatal complications still do occur very frequently. More research and new developments are required to further improve fetoscopic techniques and to further reduce complications.

Samenvatting

Hoofdstuk 1 bevat een korte inleiding over eeneiige tweelingzwangerschappen en de daarbij voorkomende problemen. Ongeveer 1-2% van alle zwangerschappen zijn tweelingzwangerschappen. Er zijn twee soorten tweelingen: eeneiige en twee-eiige. Ongeveer tweederde van de tweelingen is twee-eiig en ongeveer eenderde is eeneiig. Alle twee-eiige tweelingen hebben een eigen placenta (dichoriaal). Van de eeneiige tweelingen heeft ongeveer 30% ieder een eigen placenta, maar 70% deelt samen één placenta (monochoriaal). Wanneer de tweeling wel de placenta deelt, maar de kinderen ieder in een eigen vruchtzak zitten, noemen we dit een monochoriale diamniotische tweelingzwangerschap. In zeldzame gevallen, namelijk in 1-2% van de monochoriale tweelingzwangerschappen, bevinden de twee kinderen zich samen in één vruchtzak en spreken we van een monochoriale monoamniotische tweelingzwangerschap. In tegenstelling tot bij dichoriale placenta's zijn op monochoriale placenta's vrijwel altijd vaatverbindingen, vasculaire anastomosen, aanwezig. Via deze anastomosen staat de bloedsomloop (circulatie) van het ene kind in verbinding met de circulatie van het andere kind. De vasculaire anastomosen zijn een belangrijke oorzaak van ziekte en sterfte (morbiditeit en mortaliteit), in de zwangerschap of rondom de geboorte, bij monochoriale tweelingzwangerschappen. De belangrijkste problemen van monochoriale tweelingzwangerschappen zijn het tweeling-transfusie syndroom (TTS), intra-uteriene groeivertraging (IUGR) en aangeboren afwijkingen bij één van beide kinderen. Wanneer als gevolg van een dergelijke complicatie één van beide kinderen in de baarmoeder overlijdt, ontstaat een levensbedreigende situatie voor het andere kind. Als gevolg van het wegvallen van de bloeddruk bij het overleden kind, kan het overlevende kind via de anastomosen veel bloed verliezen in de circulatie van het overleden kind en als gevolg daarvan zelf komen te overlijden of hersenschade oplopen.
TTS treedt op in 15% van de monochoriale zwangerschappen, meestal tussen een zwangerschapsduur van 16 en 26 weken. Hierbij krijgt één kind te veel bloed (de recipiënt) terwijl de andere te weinig krijgt (de donor). De recipiënt gaat veel plassen, waardoor de hoeveelheid vruchtwater enorm toeneemt (polyhydramnion), terwijl de donor steeds minder gaat plassen en steeds minder vruchtwater overhoudt (oligohydramnion). Het polyhydramnion kan

de oorzaak zijn van vroegtijdige weeën en vroeggeboorte met een zeer hoog risico op morbiditeit en mortaliteit. Aanvankelijk werd TTS behandeld door herhaaldelijk de overmaat aan vruchtwater bij de recipiënt af te tappen om zo de vroeggeboorte te voorkomen (amniodrainage). De oorzaak van het ziektebeeld werd hierbij echter niet behandeld. Begin jaren '90 werd in de Verenigde Staten een oorzakelijke behandeling voor TTS uitgevonden: de foetoscopische laserbehandeling. Hierbij wordt een kijkbuisje in de baarmoederholte gebracht en worden de anastomosen op de placenta opgespoord. Vervolgens worden deze anastomosen met behulp van laserlicht dichtgeschroeid (gecoaguleerd). Op deze manier worden de circulaties van de kinderen van elkaar gescheiden en kunnen de kinderen zich herstellen van het tweeling-transfusie syndroom, omdat de oorzaak van TTS hiermee is weggenomen.

Bij ernstige IUGR of aangeboren afwijkingen van één van beide kinderen bestaat kans op sterfte van het te kleine of afwijkende kind. Om het gezonde kind te beschermen tegen de nadelige gevolgen van het overlijden van het zieke kind, kan overwogen worden ook in deze gevallen de bloedsomlopen van elkaar te scheiden. Dit kan door dezelfde foetoscopische laserbehandeling; immers door het dichtmaken van de anastomosen zijn de foetale circulaties gescheiden en kan het gezonde kind geen nadelige gevolgen meer ondervinden in geval van overlijden van het zieke kind. Een andere manier om de circulaties van elkaar te scheiden is het dichtmaken van de bloedvaten in de navelstreng (navelstrengcoagulatie). Wanneer één kind van een monochoriale tweeling ernstige aangeboren afwijkingen heeft met een zeer slechte prognose, kan besloten worden tot een navelstrengcoagulatie van dit kind. Als gevolg hiervan zal het zieke kind direct overlijden, maar dit brengt dan geen gevaren met zich mee voor het overlevende kind. In geval van ernstige IUGR van één van beide kinderen is nog onbekend welk beleid het beste is, afwachten of laserbehandeling/navelstrengcoagulatie.

Het Leids Universitair Medisch Centrum (LUMC) is een centrum voor derdelijns obstetrische pathologie en is het nationale verwijzingscentrum voor behandelingen van een ziek kind (of zieke kinderen) in de baarmoeder (intra-uteriene foetale behandeling). Sinds augustus 2000 wordt in het

LUMC de foetoscopische laser behandeling in gecompliceerde eeneiige tweelingzwangerschappen toegepast. Sindsdien werden bijna 250 foetoscopische ingrepen verricht. In dit proefschrift wordt het resultaat van een aantal studieprojecten beschreven, die werden uitgevoerd in een nauw samenwerkingsverband tussen de afdeling verloskunde en de afdeling neonatologie van het LUMC.

In ***Hoofdstuk 2*** hebben wij onderzocht wat de waarde is van tweewekelijks echo-onderzoek, samen met het geven van instructies aan de patiënt om vroege symptomen direct te rapporteren, ten aanzien van het tijdig stellen van de diagnose TTS in een cohort monochoriale tweelingzwangerschappen. Tevens evalueerden we welke echografische bevindingen voorspellend waren voor het optreden van TTS. Tijdig stellen van de diagnose TTS werd gedefinieerd als het stellen van de diagnose voordat ernstige complicaties van TTS optraden, zoals voortijdig breken van de vliezen, ernstige vroeggeboorte (24-32 weken zwangerschapsduur), hydrops foetalis, of intra-uteriene vruchtdood. Echo-onderzoek werd minstens eens per twee weken verricht (nekplooimeting, aanwezigheid van “membrane folding”, geschat foetaal gewicht, diepste verticale vruchtwater pocket, blaasvulling, en Doppler flow metingen van de arteria umbilicalis, ductus venosus en vena umbilicalis). 23 eeneiige tweelingzwangerschappen werden gevolgd vanaf het eerste trimester van de zwangerschap tot aan de geboorte. Metingen van TTS en geen-TTS zwangerschappen werden met elkaar vergeleken, rekening houdend met de zwangerschapsduur. Alle patiënten werden geïnformeerd over de symptomen die kunnen optreden bij TTS, en werden geïnstrueerd om in het geval van snelle groei van de buik of premature contracties direct kontakt met ons op te nemen. In vier zwangerschappen ontwikkelde zich een TTS en in alle gevallen werd de diagnose tijdig gesteld. Ten tijde van de diagnose, was er éénmaal sprake van Quintero stadium 1, tweemaal Quintero stadium 2, en éénmaal Quintero stadium 3. Tweemaal werd de diagnose gesteld naar aanleiding van het feit dat de patiënte aangaf dat haar buik extreem snel gegroeid was. Bij echografisch onderzoek bleek één parameter voorspellend ten aanzien van het ontwikkelen van TTS: geïsoleerd polyhydramnion in één vruchtzak, zonder

oligohydramnion in de andere vruchtzak. Deze echobevinding was aanwezig in twee van de vier zwangerschappen voorafgaand aan het ontwikkelen van TTS. Alle andere echobevindingen voorafgaand aan de diagnose TTS waren niet verschillend van die in de groep waarin zich geen TTS ontwikkelde. Tweewekelijks echo-onderzoek, met speciale aandacht voor de beoordeling van de vruchtwatercompartimenten van beide kinderen, in combinatie met het geven van patiëntinstructies met betrekking tot het melden van symptomen die kunnen optreden bij TTS, resulteerde in het tijdig stellen van de diagnose in alle zwangerschappen waar zich TTS ontwikkelde en lijkt een veilig controlebeleid van monochoriale tweelingzwangerschappen.

In ***Hoofdstuk 3*** worden de resultaten beschreven van de eerste 100 TTS zwangerschappen die tussen augustus 2000 en november 2004 in het LUMC werden behandeld door middel van foetoscopische laser coagulatie van de vasculaire anastomosen. De mediane zwangerschapsduur bij behandeling was 20 weken en bij geboorte 33 weken. De perinatale overleving was 70% (139/200). Behandeling resulteerde in 81% van de zwangerschappen in tenminste 1 overlevend kind op de leeftijd van 4 weken. De perinatale overleving was significant beter wanneer behandeling plaatsvond in de vroege Quintero stadia (95% in stadium 1, 76% in stadium 2, 70% in stadium 3 en 50% in stadium 4). Onze behandelingsresultaten waren vergelijkbaar met die van gespecialiseerde centra in het buitenland. Onze bevindingen suggereren dat diagnose en behandeling van TTS in de vroege Quintero stadia tot betere perinatale overleving leidt.

In ***Hoofstuk 4*** hebben wij onderzocht hoe vaak er in TTS placenta's die met laser behandeld waren, nog sprake was van rest-anastomosen. Tevens bekeken wij de klinische gevolgen van deze rest-anastomosen. Wij vonden in 33% (17/52) van de met laser behandelde placenta's rest-anastomosen. De meeste rest-anastomosen (64%) waren extreem klein (diameter < 1mm). De aanwezigheid van rest-anastomosen was niet geassocieerd met een slechtere uitkomst (gedefinieerd als intrauteriene of neonatale sterfte, of ernstige hersenschade). Rest-anastomosen waren echter wel duidelijk geassocieerd met

grotere hemoglobine verschillen (> 5 g/dL) tussen de beide kinderen. Grote hemoglobine verschillen werden gedetecteerd in 65% (11/17) van de gevallen met rest-anastomosen vergeleken met 20% (7/35) van de gevallen zonder rest-anastomosen ($p < 0.01$). Aldus hebben wij aangetoond dat 1/3 van de door ons met laser behandelde TTS placenta's nog rest-anastomosen bevatten en dat deze rest-anastomosen vooral kunnen leiden tot hematologische complicaties.

Om de placenta en de daarop gelegen anastomosen optimaal in beeld te brengen, is het wenselijk om de foetoscoop onder een hoek van 90 graden ten opzichte van de placenta in de baarmoederholte in te brengen. Bij patiënten met een placenta op de achterwand van de baarmoeder is dit een relatief gemakkelijk te bereiken doel. Wanneer echter de placenta op de voorwand van de baarmoeder gelegen is, wordt het verkrijgen van optimale foetoscopische toegang technisch lastiger. In ***Hoofdstuk 5*** beschrijven wij een nieuwe techniek voor foetoscopische entree bij patiënten met een placenta die de gehele voorwand van de baarmoeder bedekt. Onder laparoscopisch zicht, om schade aan de moederlijke darmen en bloedvaten in de buik te vermijden, wordt de foetoscoop door de laterale buikwand en vervolgens door de baarmoederachterwand in de baarmoederholte ingebracht. Op deze manier wordt onder optimale omstandigheden een hoek van bij benadering 90 graden ten opzichte van de placenta verkregen. We vergeleken 16 TTS zwangerschappen met een complete voorwandplacenta, die behandeld werden volgens deze nieuwe operatietechniek (studiegroep) met 49 TTS zwangerschappen, die in dezelfde periode volgens de conventionele methode werden behandeld. In deze 49 zwangerschappen was 9 maal sprake van partiële voorwand placenta (controlegroep A) en 40 maal was er sprake van een laterale of achterwandplacenta (controlegroep B). We evalueerden het technisch resultaat van deze nieuwe procedure en de perinatale overleving. In de studiegroep kwam een procedure-gerelateerde complicatie in 25% (4/16) van de gevallen voor. Eenmaal bleek het onmogelijk de foetoscoop in de baarmoederholte in te brengen vanwege complexe intra-abdominale verklevingen. Driemaal ontstond na het inbrengen van de foetoscoop in de baarmoederholte een bloeding in het vruchtwatercompartiment (intra-

amniotische bloeding), die het zicht op de placenta belemmerde waardoor geen complete laserbehandeling mogelijk was. Eén van deze patiënten moest een bloedtransfusie toegediend krijgen. De kans op procedure-gerelateerde complicaties in controlegroep A en B was respectievelijk 22% (2/9) en 5% (2/40). Deze complicaties bestonden uit: 3 maal een intra-amniotische bloeding en 1 maal ernstig vruchtwaterverlies in de moederlijke buikholte. De perinatale overleving in de studiegroep, controlegroep A and controlegroep B was respectievelijk 63% (20/32), 78% (14/18) and 70% (56/80). Laparoscopisch geleide foetoscopie is een nieuwe techniek die, bij TTS patiënten met een complete voorwandplacenta, veilige foetoscopische toegang tot de baarmoederholte en optimale visualisatie en coagulatie van de placentaire anastomosen mogelijk maakt. Het optreden van procedure-gerelateerde complicaties en perinatale overleving waren vergelijkbaar met de conventionele techniek. Procedure-gerelateerde complicaties komen wel vaker voor in geval van een placenta die geheel of deels over de voorwand van de baarmoeder ligt dan bij placenta lokalisatie op de laterale of achterwand van de baarmoeder.

In ***Hoofdstuk 6*** beschrijven wij de lange termijn uitkomst bij TTS na laser behandeling. Alle kinderen met TTS die tussen 2000 en 2003 in het LUMC met laser behandeld zijn, werden geïncludeerd in deze studie. De perinatale mortaliteit betrof 70% (49/164). De neurologische status en de psychomotore ontwikkeling werden bepaald op de leeftijd van 2 jaar, gecorrigeerd voor de prematuriteit. Een abnormale psychomotore ontwikkeling werd gedefinieerd als één of meerdere van de volgende factoren: spasticiteit, doofheid, blindheid of een mentale of motorische ontwikkelingsindex van minder dan 70 (meer dan 2 standaarddeviaties onder het gemiddelde). De incidentie van een abnormale psychomotore ontwikkeling was 17% (19/115) en was gebaseerd op spasticiteit (n = 8), doofheid (n= 1), achterstand in mentale ontwikkeling (n = 9) en achterstand in motorische ontwikkeling (n = 12). Wij concluderen dat kinderen met TTS ook na laser behandeling een hoge kans hebben op spasticiteit en ontwikkelingsachterstand en langdurige follow-up behoeven.

In geval van een monochoriale monoamniotische zwangerschap (twee

kinderen samen in één vruchtzak), waarbij één van beide kinderen ernstige aangeboren afwijkingen heeft, kan gekozen worden voor selectieve foeticide middels navelstrengcoagulatie. In dit geval blijft er voor het overlevende kind echter een risico bestaan op intrauterien overlijden als gevolg van navelstrengverstrengeling. In ***Hoofdstuk 7*** beschrijven we 3 monoamniotische tweelingzwangerschappen, waarin sprake was van een ernstige aangeboren afwijking van één van beide kinderen (twee maal anencefalie en een maal een aangeboren hart blok). Op succesvolle wijze werd selectieve foeticide verricht middels foetosopisch dichtschroeien van de navelstreng (occlusie) met behulp van laser, gevolgd door doorsnijden (transsectie) van de navelstreng met behulp van kontakt laser. We beschrijven de technische details van de ingreep en de uitkomst van de drie zwangerschappen. De ingreep werd verricht bij een zwangerschapsduur van respectievelijk 15, 16 en 19 weken. In 1 casus ontstond vruchtwaterlekkage in aansluiting op de ingreeep. De overlevende kinderen werden geboren bij een zwangerschapsduur van respectievelijk 36, 38 en 36 weken en waren gezond. In monoamniotische tweelingzwangerschappen, die gecompliceerd worden door één kind met een ernstige aangeboren afwijkingen, is selectieve foeticide middels laser occlusie en laser transsectie van de navelstreng een technisch haalbare ingreep, die kan leiden tot de bijna a terme geboorte van het gezonde kind.

In ***Hoofdstuk 8*** vergeleken we retrospectief de uitkomsten van 21 TTS zwangerschappen, waarin de diagnose TTTS gesteld werd na een zwangerschapsduur van 26 weken, die behandeld werden in het LUMC tussen januari 1991 en februari 2006 middels ofwel amniodrainage ofwel laserbehandeling. Onderzocht werd de incidentie van slechte uitkomst (gedefinieerd als intrauteriene of neonatale sterfte, ernstige neonatale morbiditeit en/of ernstige cerebrale schade) en zwangerschapsduur bij de geboorte. Elf TTS zwangerschappen werden behandeld met amniodrainage en tien met laser. De mediane zwangerschapsduur bij de geboorte was 29 weken in de amniodrainage groep en 31 weken in de laser groep . Alle kinderen werden levend geboren. Er was geen significant verschil tussen beide groepen in ernstige cerebrale schade, neonatale sterfte of gecombineerde slechte

uitkomst. Ernstige neonatale morbiditeit kwam echter significant vaker voor in de amniodrainage groep dan in de laser groep, respectievelijk in 27% (6/22) en 0% (0/20). Wij concluderen dat wanneer de diagnose TTS na 26 weken wordt gesteld, zowel amniodrainage als laser resulteerde in 100% overleving bij de geboorte. Echter, bij TTS kinderen behandeld met laser kwam minder ernstige neonatale morbiditeit voor. Onze bevindingen suggereren dat er een rol is voor laser behandeling, ook bij TTS gediagnostiseerd na 26 weken.

Samenvattend kunnen we stellen dat, hoewel er in het laatste decennium belangrijke vooruitgang is geboekt op het gebied van de foetoscopische foetale behandeling, te late verwijzing voor behandeling en perinatale complicaties nog frekwent voorkomen. Verder onderzoek op dit gebied ter verbetering van de foetoscopische operatietechnieken en ter reductie van complicaties is daarom onontbeerlijk.

List of abbreviations

List of abbreviations

AA	arterioarterial
AV	arteriovenous
BSID	Bayley scales of infant development
CP	cerebral palsy
DV	ductus venosus
DVP	deepest vertical pocket
EDF	end-diastolic flow
EFW	estimated fetal weight
Hb	haemoglobin
IUGR	intrauterine growth restriction
LUMC	Leiden University Medical Centre
MCA-PSV	middle cerebral artery peak systolic velocity
MDI	mental development index
NDI	neurodevelopmental impairment
NND	neonatal death
PDI	psychomotor development index
PVI	periventricular leucomalacia
RA	residual anatomoses
TAPS	twin anaemia-polycythaemia sequence
TOPS	twin oligo-polyhydramnios sequence
TRAP	twin reversed arterial perfusion
TTTS	twin-to-twin transfusion syndrome
UA	umbilical artery
UV	umbilical vein
VV	venovenous

Authors and affiliations

Authors and affiliations

From the Division of Fetal medicine, Department of Obstetrics, Leiden University Medical Centre, Leiden:
Annemieke Middeldorp, Marieke Sueters, Dick Oepkes, Frans Klumper, Frank Vandenbussche, Humphrey Kanhai

From the Division of Neonatology, Department of Paediatrics, Leiden University Medical Centre, Leiden:
Enrico Lopriore, Frans Walther

From the Department of Gynaecology, Leiden University Medical Centre, Leiden:
Frank Willem Jansen

From the Department of Surgery, Leiden University Medical Centre, Leiden:
Jan Ringers

From the Department of Obstetrics and Gynaecology, University Hospitals Leuven, Belgium:
Roland Devlieger

Publications

Publications

Lopriore E, *Middeldorp JM,* Sueters M, Oepkes D, Vandenbussche FP, Walther FJ. Long-term neurodevelopmental outcome in twin-to-twin transfusion syndrome treated with fetoscopic laser surgery. American Journal of Obstetrics and Gynecology 2007; in press.

Middeldorp JM, Lopriore E, Sueters M, Jansen FW, Ringers J, Klumper FJ, Oepkes D, Vandenbussche FP. Laparoscopically guided uterine entry for fetoscopy in twin-to-twin transfusion syndrome with completely anterior placenta: a novel technique. Fetal Diagnosis and Therapy 2007; in press.

Lopriore E, *Middeldorp JM*, Oepkes D, Klumper FJ, Walther FJ, Vandenbussche FP. Residual anastomoses after fetoscopic laser surgery in twin-to-twin transfusion syndrome: frequency, associated risks and outcome. Placenta 2007;28:204-8.

Middeldorp JM, Sueters M, Lopriore E, Klumper FJ, Oepkes D, Devlieger R, Kanhai HH, Vandenbussche FP. Fetoscopic laser surgery in 100 pregnancies with severe twin-to-twin transfusion syndrome in the Netherlands. Fetal Diagnosis and Therapy 2007;22:190-194.

Lopriore E, *Middeldorp JM*, Oepkes D, Kanhai HH, Walther FJ, Vandenbussche FP. Twin anemia-polycythemia sequence in two monochorionic twin pairs without oligo-polyhydramnios sequence. Placenta 2007;28:47-51.

Lopriore E, van den Wijngaard JP, *Middeldorp JM*, Oepkes D, Walther FJ, van Gemert MJ, Vandenbussche FP. Assessment of feto-fetal transfusion flow through placental arterio-venous anastomoses in a unique case of twin-to-twin transfusion syndrome. Placenta 2007;28:209-11.

van den Wijngaard JP, Lewi L, Lopriore E, Robyr R, *Middeldorp JM*, Vandenbussche FP, Devlieger R, Deprest J, Ville Y, van Gemert MJ. Modeling severely discordant hematocrits and normal amniotic fluids after incomplete laser therapy in twin-to-twin transfusion syndrome. Placenta 2006;[Epub ahead of print]

Sueters M, *Middeldorp JM*, Lopriore E, Oepkes D, Kanhai HH, Vandenbussche FP. Timely diagnosis of twin-to-twin transfusion syndrome in monochorionic twin pregnancies by biweekly sonography combined with patient instruction to report onset of symptoms. Ultrasound in Obstetrics and Gynecology 2006;28:659-64.

Adama van Scheltema PN, Feitsma AH, *Middeldorp JM*, Vandenbussche FP, Oepkes D. Amnioinfusion to facilitate external cephalic version after initial failure. Obstetrics and Gynecology 2006;108:591-2.

Lopriore E, van Wezel-Meijler G, *Middeldorp JM*, Sueters M, Vandenbussche FP, Walther FJ. Neurodevelopmental outcome after laser therapy for twin-twin transfusion syndrome. American Journal of Obstetrics and Gynecology 2006;[Epub ahead of print]

Lopriore E, van Wezel-Meijler G, *Middeldorp JM*, Sueters M, Vandenbussche FP, Walther FJ. Incidence, origin, and character of cerebral injury in twin-to-twin transfusion syndrome treated with fetoscopic laser surgery. American Journal of Obstetrics and Gynecology 2006;194:1215-20.

Lopriore E, Sueters M, *Middeldorp JM*, Klumper F, Oepkes D, Vandenbussche FP. Twin pregnancies with two separate placental masses can still be monochorionic and have vascular anastomoses. American Journal of Obstetrics and Gynecology 2006;194:804-8.

Middeldorp JM. Obesitas en zwangerschap. In: Kanhai HHH, Hoornweg J eds. Verloskundige zorg in de eerste lijn. Boerhaave commissie PAOG. Leiden 2005;107-13. ISBN 90-6767-584-9.

Lopriore E, Sueters M, *Middeldorp JM*, Oepkes D, Vandenbussche FP, Walther FJ. Neonatal outcome in twin-to-twin transfusion syndrome treated with fetoscopic laser occlusion of vascular anastomoses. Journal of Pediatrics 2005;147:597-602.

Sueters M, *Middeldorp JM*, Oepkes D, Lopriore E, Vandenbussche FP. Twin-to-twin transfusion syndrome at 11 weeks of gestation. Am J Obstet Gynecol 2005;193:887-8.

Lopriore E, Sueters M, *Middeldorp JM*, Vandenbussche FP, Walther FJ. Haemoglobin differences at birth in monochorionic twins without chronic twin-to-twin transfusion syndrome. Prenatal Diagnosis 2005;25:844-50.

Middeldorp JM, Lopriore E, Vandenbussche FP. Foetoscopische lasercoagulatie van placentaire anastomosen als behandeling van het tweelingtransfusie syndroom. Nederlands Tijschrift voor Kindergeneeskunde 2005;73:125-31.

Middeldorp JM, Sueters M, Klumper FJ, Oepkes D, Lopriore E, Kanhai HH, Vandenbussche FP. Foeoscopische laserbehandeling in Nederland. In: Vandenbussche FPHA, Kanhai HHH, Walther FJ eds. Vorderingen in de foetale geneeskunde. Boerhaave commissie PAOG. Leiden 2005;95-9. ISBN 90-6767-571-7.

Witsenburg CP, Rosendaal FR, *Middeldorp JM*, Van der Meer FJ, Scherjon SA. Factor VIII levels and the risk of pre-eclampsia, HELLP syndrome, pregnancy related hypertension and severe intrauterine growth retardation.Thrombosis Research 2005;115:387-92.

Lopriore E, *Middeldorp JM*, Sueters M, Vandenbussche FP, Walther FJ. Twin-to-twin transfusion syndrome: from placental anastomoses to long-term neurodevelopmental outcome. Current Pediatric Reviews 2005;3:191-203.

Middeldorp JM, Klumper FJ, Oepkes D, Lopriore E, Kanhai HH, Vandenbussche FP. Eerste resultaten in Nederland van foetoscopische laserbehandeling bij tweelingtransfusiesyndroom in het tweede trimester van de zwangerschap vergelijkbaar met internationale resultaten. Nederlands Tijdschrift voor Geneeskunde 2004;148:1203-8.

Feitsma AH, *Middeldorp JM*. Haemorrhagia post partum: ballonnetje opblazen of oplaten. Nederlands Tijdschrift voor Obstetrie en Gynaecologie 2004;117:129-130.

Oepkes D, *Middeldorp JM*, Nijhuis JG, Knahai HH, Creemers JWT. Managing obstetric emergencies and trauma (MOET): een nieuwe cursus voor gynaecologen. Nederlands Tijdschrift voor Obstetrie en Gynaecologie 2004;117:62-4.

Middeldorp JM, Klumper F, Vandenbussche FP. Tweede trimester tweelingtransfusie syndroom. Tijdschrift voor Verloskundigen 2003;3:126-9.

Middeldorp JM. Kraamvrouwenkoorts. In: Springer MP ed. Verloskunde voor de huisarts. Boerhaave commissie PAOG. Leiden 2001;91-6. ISBN 90-6767-491-5.

Middeldorp JM. Bloedverlies in de zwangerschap. Modern Medicin 2000;24:826-30.

Bax A, *Middeldorp AM*, Harinck B, Holleboom C, van Roosmalen J. Unilateral pulmonary edema as a life-threatening complication of ritodrine. Acta Obstetricia et Gynecologica Scandinavica 1999;78:915-6.

Middeldorp JM. Totaalruptuur en bekkenbodemschade: prevalentie en preventie. In: Springer MP ed. Verloskunde voor de huisarts. Boerhaave commissie PAOG. Leiden 1997;115-18. ISBN 90-6767-369-2.

Dankwoord

Dankwoord

Bij de totstandkoming van dit proefschrift zijn vele personen betrokken die ik dank verschuldigd ben, waarvan echter een aantal ongenoemd dient te blijven. De goede verstaanders hebben hopelijk slechts een half woord nodig.....

Graag wil ik stilstaan bij de patiënten en hun partners die in hun moeilijke tweelingzwangerschap met onzekere vooruitzichten een ingreep ondergingen, vol hoop op een goede afloop. De manier waarop zij omgingen met hun blijdschap, verdriet en met de combinatie van deze emoties, was indrukwekkend.

Onze “TTS-club”, Frank, Frans, Dick, Enrico, Marieke, Roland, ondersteund door Robert Jan, Katinka, Suzanne, Sander, Phebe, Jennie en Annemarie, was vanaf het allereerste begin (bij God in Tampa) een stimulerende groep mensen met zo veel enthousiasme dat ik niet anders kon dan be/geloven dat dit proefschrift er zou komen.

Werkzaam zijn in de leukste academische verloskunde staf van Nederland blijft een groot voorrecht. Lieve collega’s, dank voor jullie steun en vertrouwen!

Laura en Ivanka, al jaren zorgen jullie voor optimale omstandigheden om alle facetten van mijn werk te kunnen doen. Lau, jouw digitale hulp en enthousiasme bij het promotietraject waren onbetaalbaar.

Mijn vriendinnen van de F2-loge, Marjolein, Co’tje, Anca, Annette en Joanne, hebben ook mij op het cruciale moment het juiste pad op geduwd. Moge er nog vele mijlpalen door de leden van ons illustere gezelschap bereikt worden.

Dames van de Jacobsgracht, Marjan, Mirella en Sonja, jullie bijdrage was van een heel andere orde en had niets van doen met medisch inhoudelijke zaken, maar was daarom juist onmisbaar.

Nicolette, als assistent samen visite gelopen met de baas, allebei een beetje blond (de één wat blonder dan de ander), dan uiteindelijk ook maar allebei promoveren (de één wat eerder dan de ander). Dank voor het goede voorbeeld.

Mariska, al 27 jaar maatjes, dank voor je grenzeloze vriendschap.

Joke, Tineke, Arja en Elise, jullie zorgen dat thuis alles reilt en zeilt in ons drukke “twee-dokters” gezin. Zonder jullie hulp was dit allemaal nooit mogelijk geweest.

Lieve Marleen en Juul, mijn twee grote verstandige vrolijke meiden, thuiskomen bij jullie is elke dag een feest. Laten we vooral heel veel plezier blijven maken.

Allerliefste Martien, als er iemand was die nooit getwijfeld heeft dat ik dit tot een goed einde kon brengen, was jij het wel. Dank voor alles en nog veel meer.

Curriculum Vitae

Curriculum Vitae

Annemieke Middeldorp werd geboren op 2 april 1962 in Den Haag. Zij voltooide het VWO aan het Edith Stein College te Den Haag. Van 1980 tot 1988 studeerde zij Geneeskunde aan de Rijksuniversiteit Leiden. Na het behalen van het artsexamen in 1988 werkte zij 1 jaar als AGNIO op de afdeling Obstetrie en Gynaecologie van het Diaconessenhuis Bronovo te Den Haag. In juni 1989 begon zij haar opleiding tot gynaecoloog in het Leidse opleidingscluster; de eerste 6 maanden en de laatste 2 jaar in het Ziekenhuis Leyenburg te Den Haag (opleider Dr. J.P. Holm), de tussenliggende 3 ½ jaar in het Leids Universitair Medisch Centrum (opleider Prof. Dr. E.V. van Hall). In 1995 rondde zij haar opleiding tot gynaecoloog af. Hierna was zij gedurende bijna 2 jaar als chef de clinique werkzaam in het Ziekenhuis Leyenburg te Den Haag. Vanaf februari 1997 maakt zij deel uit van de staf Obstetrie van het Leids Universitair Medisch Centrum (afdelingshoofd Prof. Dr. H.H.H. Kanhai). Vanaf eind 2000 is zij betrokken bij de foetoscopische behandeling van gecompliceerde monochoriale tweeling zwangerschappen en het daaraan gerelateerde, in dit proefschrift beschreven, klinisch onderzoek.