



**Universiteit  
Leiden**  
The Netherlands

## **Genetic and molecular markers of proteinuria and glomerulosclerosis**

Ijpelaar, D.H.T.

### **Citation**

Ijpelaar, D. H. T. (2009, September 16). *Genetic and molecular markers of proteinuria and glomerulosclerosis*. Retrieved from <https://hdl.handle.net/1887/13997>

Version: Corrected Publisher's Version

License: [Licence agreement concerning inclusion of doctoral thesis in the Institutional Repository of the University of Leiden](#)

Downloaded from: <https://hdl.handle.net/1887/13997>

**Note:** To cite this publication please use the final published version (if applicable).

# **Glomerular hypertrophy precedes albuminuria and segmental loss of podoplanin in podocytes in Munich Wistar Frömter rats**

D.H.T. IJpelaar<sup>1</sup>, A. Schulz<sup>2</sup>, K. Koop<sup>1</sup>, M. Schlesener<sup>2</sup>, J.A. Bruijn<sup>1</sup>, D. Kerjaschki<sup>3</sup>, R. Kreuz<sup>2</sup> and E. De Heer<sup>1</sup>.

<sup>1</sup>Pathology, Leiden University Medical Center, Leiden, The Netherlands; <sup>2</sup>Clinical Pharmacology and Toxicology, Charité Universitätsmedizin Berlin, Berlin, Germany; <sup>3</sup>Department of Clinical Pathology, University of Vienna, Vienna, Austria.

*Am J Physiol Renal Physiol.* 2008 Apr;294(4):F758-67

## **Abstract**

Focal and segmental glomerulosclerosis (FSGS) is a common cause of end-stage renal disease. Albuminuria is a risk factor for FSGS and is influenced by environmental, genetic and gender-specific factors. Podocytes play a central role in the development of albuminuria, but the precise relationship between early glomerular and podocyte-associated damage and albuminuria is unclear. Furthermore, experimental findings demonstrate a sex difference in development of albuminuria and FSGS. We investigated the early glomerular changes in male Munich-Wistar-Frömter (MWF) rats, which spontaneously develop albuminuria, and male albuminuria-resistant spontaneously hypertensive rats (SHR). In addition, since female MWF rats are protected from overt proteinuria and progressive renal disease, we compared the phenotypic changes in podocytes during early development of albuminuria in male and female MWF rats. In male MWF rats, glomerular hypertrophy preceded the onset of albuminuria and was greater than in male SHR rats. Albuminuria developed starting at 6 weeks of age and coincided with focal and segmental loss of podoplanin, increased expression of desmin, entrapment of albumin in affected podocytes, and focal and segmental foot process effacement at the ultrastructural level. Other podocyte-associated molecules such as nephrin and zonula occludens 1 were unaffected. Early glomerular hypertrophy and podocyte damage did not differ between male and female MWF rats. Our data show for the first time that albuminuria in male and female MWF rats is preceded by glomerular hypertrophy and accompanied by focal and segmental loss of podoplanin when FSGS was not present yet.

## Introduction

Focal and segmental glomerulosclerosis (FSGS) is one of the most frequent causes of end-stage renal disease (ESRD).<sup>1</sup> It is clinically characterized by proteinuria, usually in the nephrotic range, and development of glomerulosclerosis.<sup>2</sup> The severity of proteinuria and the rate of progression to ESRD are influenced by gender, environmental, and genetic factors.<sup>3-6</sup> FSGS can be divided into 2 etiologic categories: idiopathic (or primary) and secondary. The causes of idiopathic FSGS are not known and are outside the scope of this study. Secondary FSGS has multiple causes, including genetic mutations in glomerular epithelial cells, metabolic disease, glomerular immunologic injury, and hemodynamic factors.<sup>7,8</sup> Irrespective of the root cause, secondary FSGS is thought to result from nephron loss and subsequent hyperperfusion.<sup>9</sup>

In recent years, podocyte damage has been demonstrated to play a central role in the development of secondary FSGS.<sup>10,11</sup> However, the exact relationship between damage to the podocyte and development of FSGS is unclear. It is well established that podocyte damage contributes to the development of albuminuria in human renal disease and animal models.<sup>12,13</sup> Albuminuria is typically accompanied by podocyte damage, loss or reorganization of podocyte-associated molecules, and flattening of the foot processes at the ultrastructural level.<sup>14</sup> Also, damaged podocytes may detach from the glomerular basement membrane and a reduction in the podocyte number has been linked to progression of renal disease.<sup>11,15,16</sup>

Albuminuria itself is an independent predictor of the development of ESRD, and, in the microalbuminuric and even high normal normoalbuminuric range, it is an independent risk factor for cardiovascular events.<sup>17-19</sup> Greater insight into the molecular events occurring during the early stages of microalbuminuria may lead to better understanding of the pathogenesis of proteinuria and progressive glomerulosclerosis, and eventually improved therapeutic options.

However, the sequence of events in the development of microalbuminuria, podocyte-associated changes, overt proteinuria, and glomerulosclerosis is difficult to investigate in humans due to a lack of repetitive biopsies and human genetic heterogeneity. An ideal tool for investigating the time course of early changes in development of albuminuria and FSGS is the Munich-Wistar-Frömter (MWF) rat.<sup>20,21</sup> Male MWF rats have an inherited deficit in the number of nephrons and spontaneously develop albuminuria and mild hypertension followed at an older age by overt proteinuria, FSGS, and renal failure.<sup>20,22</sup> In contrast, although female MWF rats demonstrate a similar reduction in the total number of nephrons<sup>22</sup>, they do not develop overt proteinuria or FSGS, although they exhibit mild albuminuria and

mild hypertension.<sup>20;23</sup> Consistent with this finding, gender is known to influence the severity of proteinuria and the development of FSGS in humans and experimental models.<sup>5</sup>

Previous studies have demonstrated a depletion of podocytes, and changes in the podocyte-associated molecules zonula occludens 1 (ZO-1) and nephrin in male MWF rats with overt albuminuria and when obvious light microscopic changes are present; these studies have suggested that podocyte damage is a consequence of albuminuria and may lead to FSGS in this rat model.<sup>24;25</sup> In this study, we investigated the early glomerular changes that precede the development of microalbuminuria and light microscopic changes in MWF rats. In particular, we examined whether these glomerular changes involve podocyte-associated molecular changes. In addition, we compared early glomerular molecular changes between male and female MWF rats.

## **Materials and methods**

### ***Animals and study design***

Fifteen female MWF rats, 15 male MWF rats, and 15 male SHR rats were obtained from the colony at the Charite-Universitätsmedizin, Campus Benjamin Franklin (Berlin, Germany). All rats were fed a normal pellet diet and had free access to food and water.

Each strain was divided into 3 groups ( $n = 5$ ) and was studied at 4, 6, and 8 weeks of age. For the determination of urinary albumin excretion, rats were placed in metabolic cages for 2 days, and urine was collected over the last 24-hour period. Urinary albumin excretion was determined using a sensitive and rat-specific ELISA.<sup>23</sup>

Subsequently, rats were anesthetized by intraperitoneal injection of ketamine and xylazine. Kidneys were perfused with PBS and removed. Small pieces of the cortex were fixed in 1.5% glutaraldehyde and 1% paraformaldehyde for 24 hours and stored in cacodylate buffer for electron microscopy. One kidney was snap-frozen and stored at -80 °C. The other was fixed in formalin for 24 hours, transferred to 70% ethanol, and embedded in paraffin for histology and immunohistochemistry.

### ***Immunohistochemistry***

Periodic acid Schiff staining was performed on 4- $\mu$ m sections of paraffin-embedded samples to determine changes in morphology.

In addition to staining for 11 podocyte-associated molecules (Table 1), expression of albumin and Jg12 proteins was assessed. Jg12 is a bradykinin-degrading membrane peptidase that is expressed on glomerular and tubulointerstitial endothelial cells.<sup>26</sup>

Epitope	Fixation or antigen retrieval	Primary antibody dilution	Source	Secondary antibody *	Reference
<i>Frozen sections</i>					
Nephrin, extracellular domain	Acetone 1 minute	Mouse mAb 5-1-6, 1:200	Dr. Kawachi, Nigata University School of Medicine, Japan	Anti-mouse Envision	(56)
$\alpha$ -actinin-4	-	Rabbit pAb 6A3, 1:4000	Dr. Beggs, Harvard University, Boston, MA	Anti-rabbit Envision	(57)
<i>Paraffin sections</i>					
$\alpha$ -dystroglycan	<sup>†</sup> Citrate	Mouse mAb VIA4-1, 1:300	Upstate Biotechnology, Lake Placid, NY; catalog # 05-298	Anti-mouse Envision	
Desmin	<sup>*†</sup> Tris/EDTA	Mouse mAb, clone 33, 1:750	Sambio-Monosan, Uden, The Netherlands	Anti-mouse Envision	
Ezrin	Tris/EDTA	Mouse mAb 3C12, 1:200	Neomarkers, Fremont, CA; catalog # MS-661-P1	Anti-mouse Envision	
Podocalyxin	<sup>§</sup> Proteinase K	Mouse mAb 5A, 1:600	Dr. Miettinen, University of Helsinki, Finland	Anti-mouse Envision	(58)
Podocin, C-terminal portion	Proteinase K	Rabbit pAb P35, 1:1000	Dr. Antignac, Hôpital Necker, Paris, France	Anti-rabbit Envision	(59)
Podoplanin	Proteinase K	Rabbit pAb, 1:1000	Prof. Kerjaszski, University of Vienna, Austria	Anti-rabbit Envision	
Synaptopodin	Citrate	Mouse mAb G1D4, 1:10	Progen Biotechnik GmbH, Heidelberg, Germany; catalog # 65194	Anti-mouse Envision	
WT-1	Tris/EDTA	Rabbit pAb C19, 1:1000	Santa Cruz Biotechnology, Santa Cruz, CA; Sc-192	Anti-rabbit Envision	
ZO-1	Proteinase K	Rabbit pAb ZO-1:1:100	Zymed, San Francisco, CA; catalog # 61-7300	Anti-rabbit Envision	(24)
Jg12	Citrate	Mouse mAb, 1:600	Prof. Kerjaszski, University of Vienna, Austria	Anti-mouse Envision	(26)
Albumin	Tris/EDTA	Rabbit pAb, 1:15000	Nordic Immunology, Tilburg, The Netherlands; catalog # RARa/Alb/7S	Anti-rabbit Envision	

<sup>†</sup>DakoCytomation, Glostrup, Denmark; catalog # K4001 (anti-mouse Envision HRP) and K4003 (anti-rabbit Envision HRP). Citrate: 0.1 M citrate buffer, pH 6.0. <sup>\*</sup>Tris/EDTA: 0.1M Tris/EDTA, pH9.0. <sup>§</sup>Proteinase K: DakoCytomation, Glostrup Denmark; catalog # S3020. mAb, monoclonal antibody; pAb, polyclonal antibody; ZO-1, zonula occludens 1; WT-1, Wilms tumor 1.

**Table 1.** Antibodies and protocol immunohistochemistry.

Four-micrometer paraffin sections were dewaxed, and endogenous peroxidase was blocked by incubation with 0.12% H<sub>2</sub>O<sub>2</sub> in PBS for 20 minutes. Sections stained for Wilms tumor 1 (WT-1) and Jg12 were additionally blocked with normal goat serum for 1 hour. Sections were then incubated with primary antibodies diluted in 1% BSA in PBS for 2 hours. Binding was detected by incubation with peroxidase-labeled secondary antibodies. Peroxidase activity was visualized using 3,3'-diaminobenzidine tetrahydrochloride (DakoCytomation, Glostrup, Denmark), and sections were counterstained with hematoxylin and mounted. Staining for nephrin and  $\alpha$ -actinin 4 were performed on 3- $\mu$ m-thick frozen sections (Table 1). The specificity of the anti-podoplanin antibody has been described before.<sup>27;28</sup>

### ***Quantification***

Staining for desmin and podoplanin was analyzed by counting the percentage of glomeruli with loss of podocyte staining for podoplanin or desmin. At least 30 glomeruli per section were scored.

Slides stained for WT-1 were used for morphometric analysis of the size of the glomerulus and the number of podocytes. WT-1 is a podocyte-specific transcription factor previously used to identify and count podocytes in tissue sections.<sup>29</sup> The number of WT-1-positive nuclei per glomerular cross-section (4  $\mu$ m) was counted. Ten randomly chosen regions of the outer glomerular cortex were photographed at 200x magnification with a Zeiss Axioplan microscope equipped with a Sony DXC-950P 3CCD color camera (Sony Corporation, Tokyo, Japan). The surface area of all glomeruli in the photographs was measured using ImageJ 1.34 software (National Institutes of Health, <http://rsb.info.nih.gov/ij>). From these measurements, the mean glomerular volume, the number of podocytes per glomerulus, and the glomerular volume per podocyte were calculated, as described previously.<sup>30</sup>

### ***Electron microscopy***

Small pieces of cortex were fixed in 1.5% glutaraldehyde and 1% paraformaldehyde for 24 hours and stored in 0.1 M cacodylate buffer with 6% sucrose. After postfixation in 1% reduced osmium in 0.1 M cacodylate buffer, pieces were dehydrated and embedded in Epon. Ultrathin sections were cut using a Leica Ultracut microtome and mounted on uncoated copper grids. Sections were contrasted with uranyl acetate and lead citrate and evaluated with a JEOL JEM-1011 electron microscope equipped with a digital camera.

### ***Statistical analysis***

Results are expressed as the means  $\pm$  SD. ANOVA with Least Significant Difference

post hoc correction was used to test for differences between groups. Correlation coefficients were calculated using the Pearson correlation test. Statistical significance was set at  $P < 0.05$ .

## Results

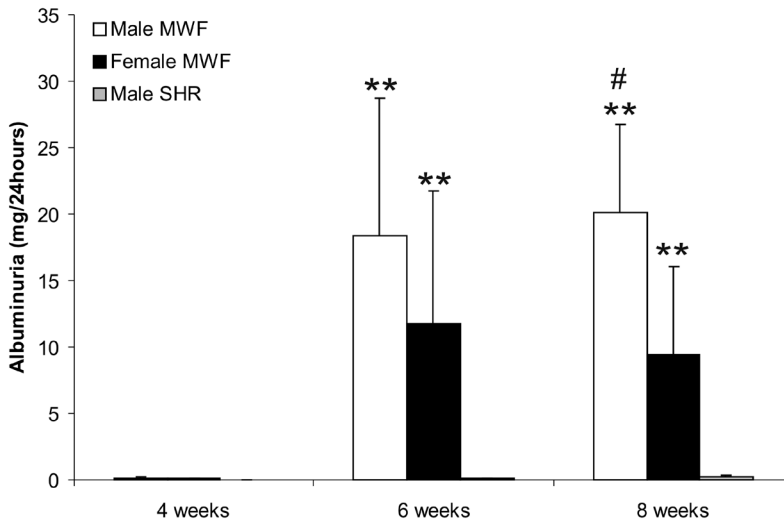
### *Time course analysis in male MWF rats versus male spontaneously hypertensive rats*

#### *Albuminuria*

At 4 weeks of age, no appreciable amounts of albumin were detected in the urine of MWF or spontaneously hypertensive rats (SHR) rats. Starting at 6 weeks of age, MWF rats, but not SHR rats, developed increased albuminuria (Figure 1,  $P < 0.05$ ).

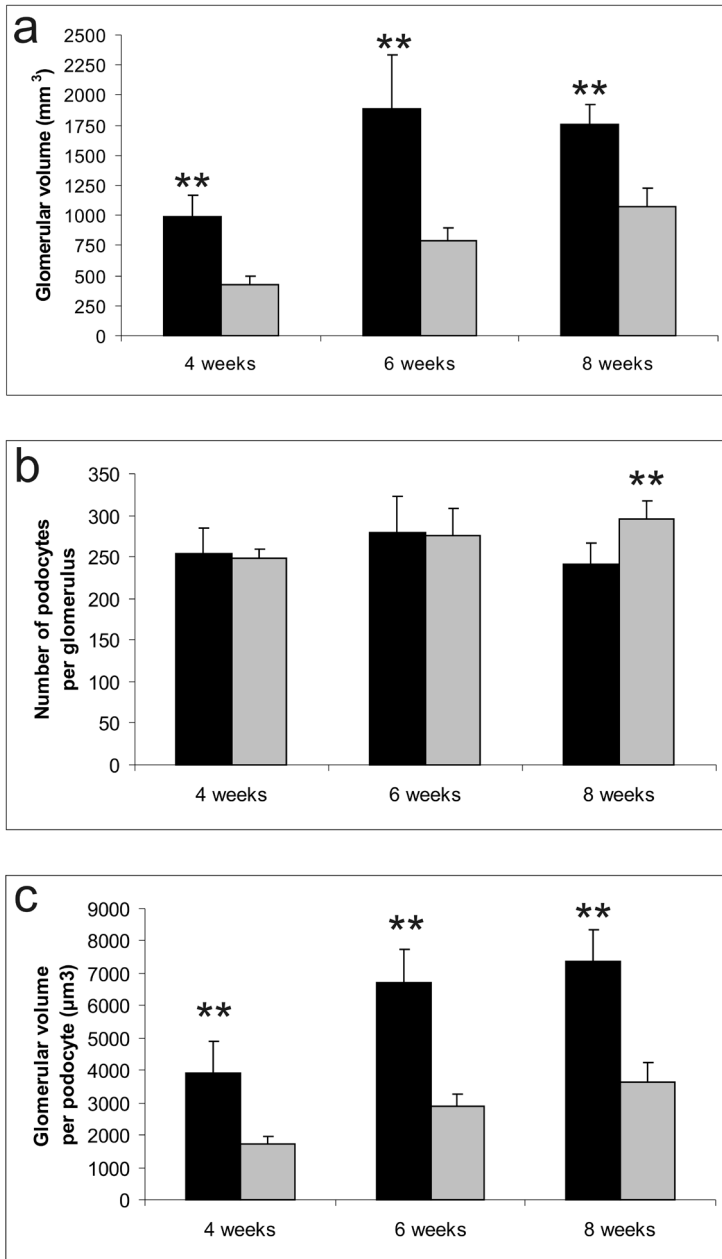
#### *Glomerular volume and number of podocytes*

The mean volume per glomerulus increased with age in both MWF and SHR rats (Figure 2a). However, the glomerular volume was significantly higher in MWF versus SHR rats at all time points ( $P = 0.001$ ). Glomerular hypertrophy was already present at 4 weeks of age in male MWF rats and preceded the development of albuminuria.

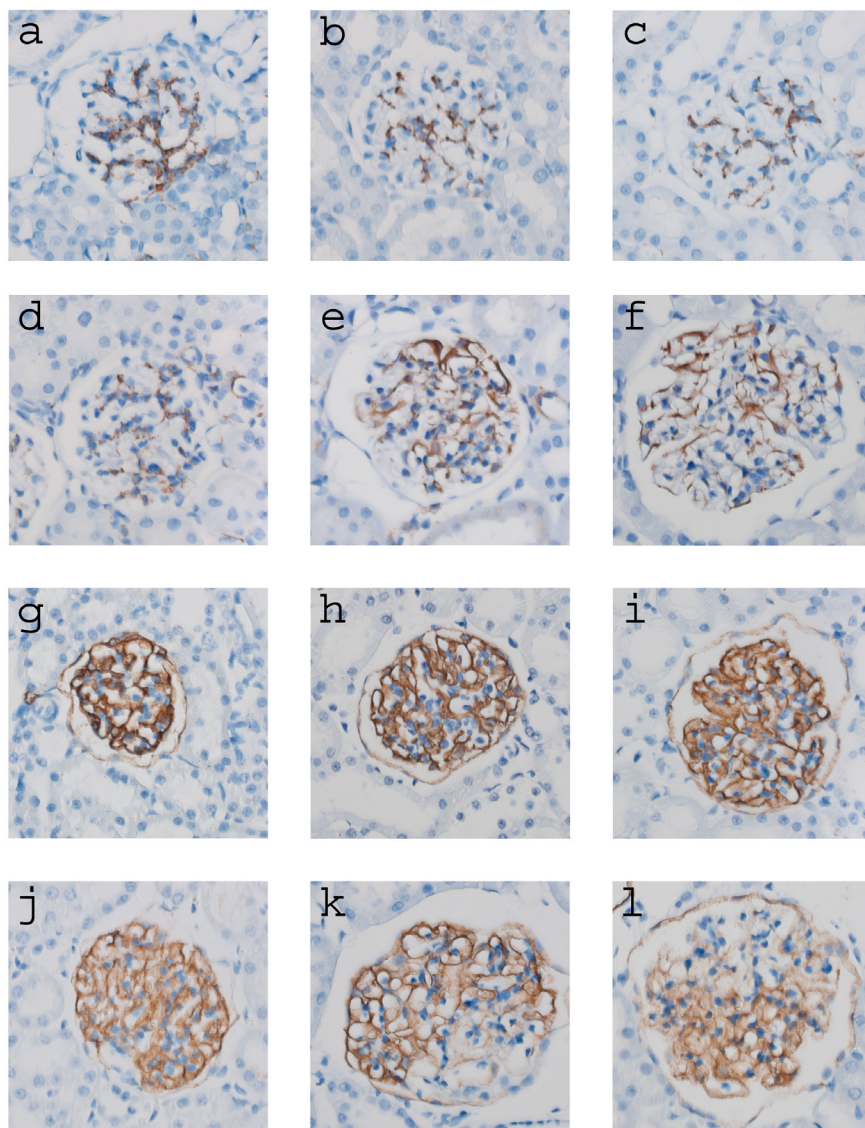


**Figure 1.** Urinary albumin excretion (mg/24 hours) in male Munich-Wistar-Frömter (MWF), female MWF, and male spontaneously hypertensive rats (SHR). Male and female MWF rats, but not SHR, developed albuminuria at 6 and 8 weeks of age. At 8 weeks of age, albuminuria was significantly greater in male versus female MWF rats. \*\* $P < 0.01$  vs. SHR at same age, # $P < 0.05$  vs. other sex of MWF rats at same age.





**Figure 2.** Quantification of glomerular volume (a), number of podocytes (b), and glomerular volume per podocyte (c) in male MWF rats (solid bars) and male SHR rats (shaded bars) at 4, 6, and 8 weeks of age. (A) At all time points, glomerular volume was significantly greater in MWF versus SHR rats. (B) At 8 weeks, there were fewer Wilms tumor 1(WT-1)-positive podocytes in MWF versus SHR rats. (C) At all time points, the glomerular volume per podocyte was significantly greater in MWF versus SHR rats. \*\*P < 0.01 vs. SHR at same age.



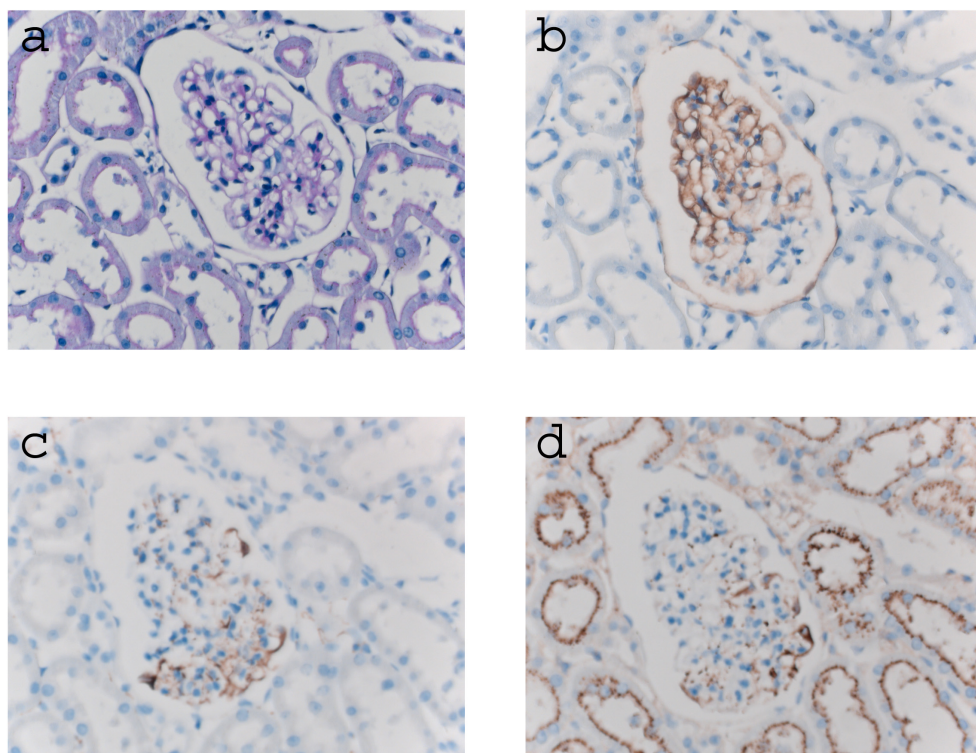
**Figure 3.** Expression of desmin and podoplanin proteins in male MWF and male SHR. Representative photographs are of desmin staining in SHR (a-c) and MWF rats (d-f) at 4 weeks (a and d), 6 weeks (b and e), and 8 weeks (c and f) of age. At 6 and 8 weeks of age, MWF rats exhibited focal and segmental expression of desmin protein in podocytes. Protein expression in SHR did not change. Representative photographs of podoplanin staining in SHR (g-i) and MWF rats (j-l) at 4 weeks (g and j), 6 weeks (h and k), and 8 weeks (i and l) of age. At 6 and 8 weeks of age, MWF rats exhibited focal and segmental loss of podoplanin protein expression in podocytes. Protein expression in SHR did not change.

The number of WT-1-positive podocytes did not differ between MWF and SHR rats at 4 and 6 weeks of age (Figure 2b). However, at 8 weeks, glomeruli from male MWF rats contained significantly fewer podocytes than did glomeruli from male SHR rats ( $P = 0.008$ ). The glomerular volume per podocyte (Figure 2c) was significantly greater in male MWF rats compared to male SHR at 4, 6, and 8 weeks of age ( $P < 0.001$ ).

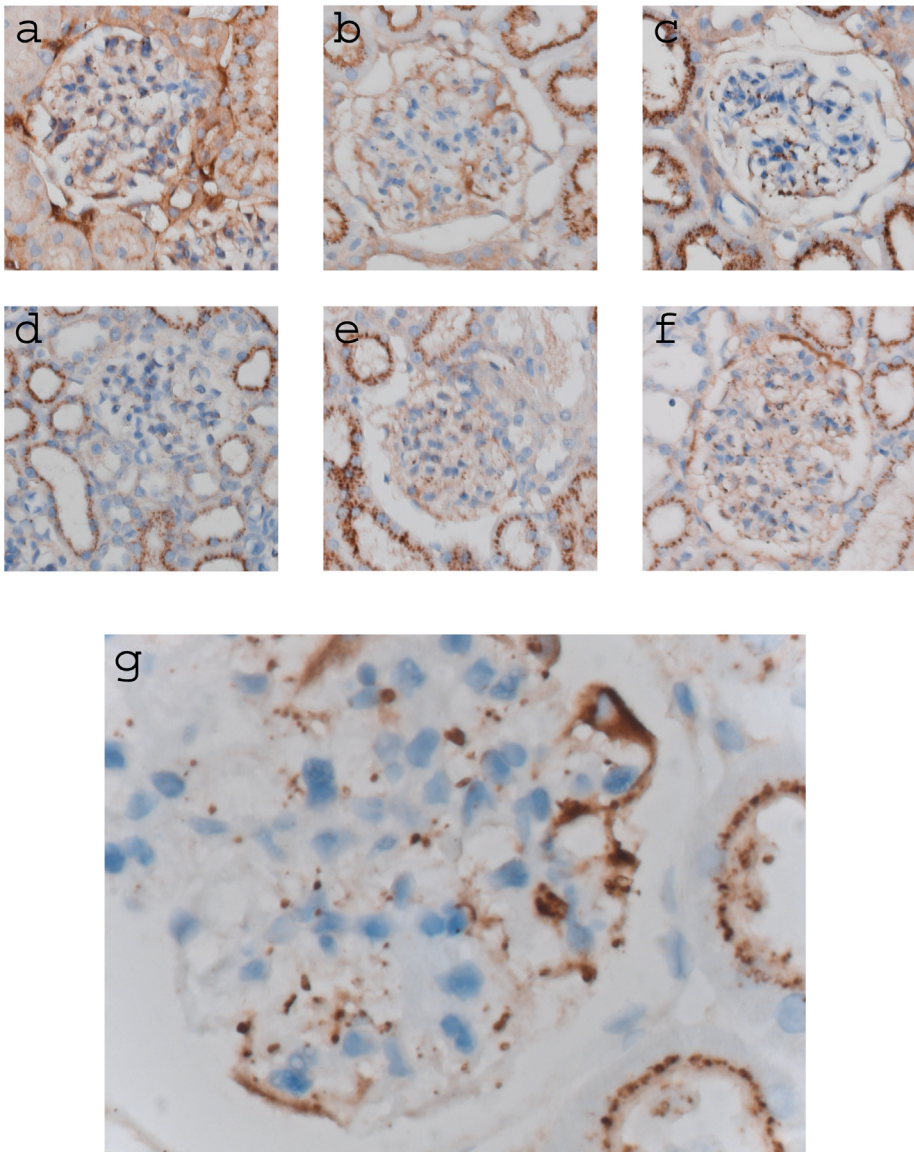
#### *Glomerular morphology and protein expression*

Evaluation of periodic acid-Schiff staining revealed no obvious changes in the glomerular and tubulointerstitial compartments within the first 8 weeks.

Since quantitative Western blotting of glomerular protein extracts would not reveal subtle segmental changes in the expression of glomerular proteins, we performed immunohistochemistry during the course of disease. Desmin, an intermediate-sized filament expressed by mesangial cells in normal glomeruli<sup>31</sup>, is a well known marker of damaged or stressed podocytes.<sup>32</sup> At 4 weeks of age, desmin protein was found only in mesangial cells in MWF and SHR rats. At 6 and 8 weeks of



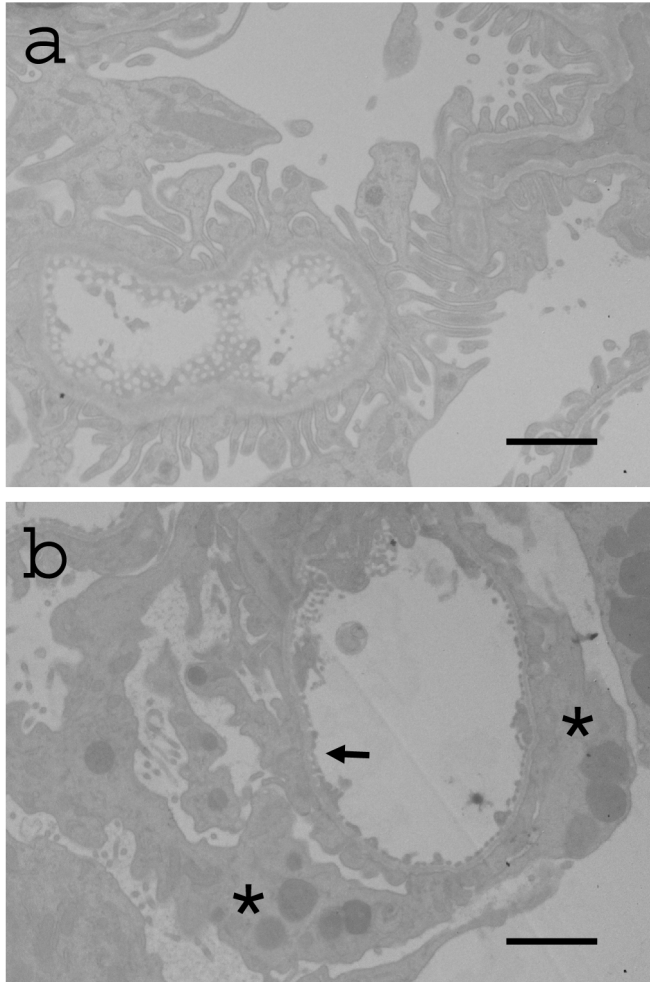
**Figure 4.** Sequential kidney sections from an 8-week-old male MWF rat showing staining for periodic acid-Schiff (a), podoplanin (b), desmin (c), and albumin (d).



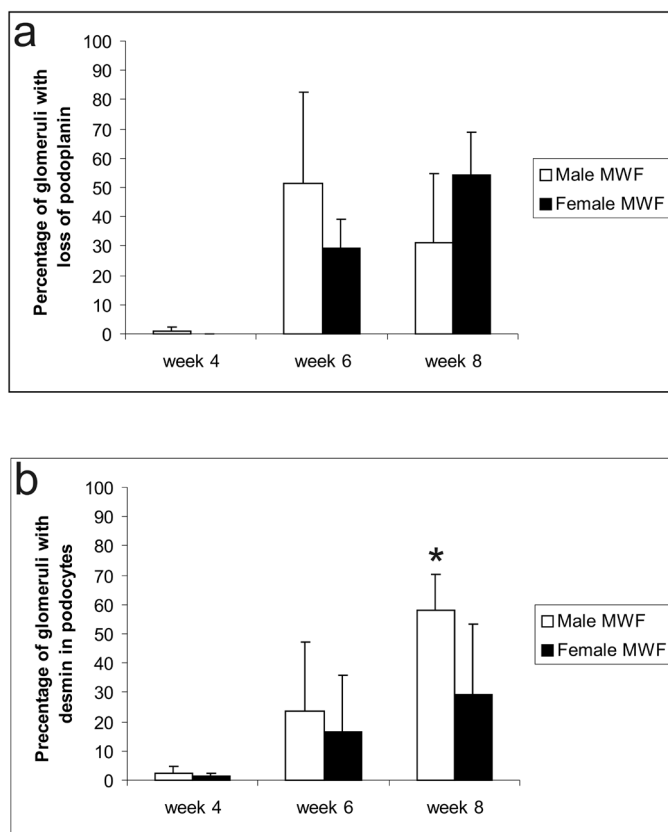
**Figure 5.** Expression of albumin protein in male and female MWF rats and male SHR. a-f: Representative photographs of albumin expression in MWF (a-c) and SHR (d-f) at 4 weeks (a and d), at 6 weeks (b and e), and 8 weeks (c and f) of age. Albumin droplets were present in podocytes of 6- and 8-week-old male and female MWF rats. g: higher magnification of a glomerulus of a male MWF rat showing albumin droplets in podocytes.

age, desmin was focally and segmentally expressed in podocytes of male MWF rats, whereas podocytes of SHR rats did not express desmin at any time point (Figure 3a-f).

Consistent with the pattern of desmin expression, there was focal and segmental loss of podoplanin protein in MWF rats at weeks 6 and 8 (Figure 3g-l). Sequential sections of glomeruli stained for podoplanin and desmin showed that desmin was expressed in podocytes in which podoplanin expression had been lost (Figure 4).



**Figure 6.** Electron microscope image of a glomerulus of an 8-week-old male MWF rat. (a) A normal capillary with fenestrated endothelium and normal foot processes. (b) The same glomerulus as in (a). This capillary is surrounded by podocytes with foot process effacement (arrow) and droplets suggestive of albumin (asterisks). Bar = 5  $\mu$ m.



**Figure 7.** Percentage of glomeruli exhibiting podocyte loss of podoplanin and desmin in male (open bars) and female (solid bars) MWF rats at 4, 6, and 8 weeks of age. (a) The percentage of glomeruli exhibiting podocyte loss of podoplanin. (b) The percentage of glomeruli with podocyte expression of desmin protein. \* $P < 0.05$  vs. other sex at the same age.

Albumin protein reabsorption droplets in proximal tubular cells were present in all groups at all ages, but were more pronounced in MWF rats at week 6 and week 8, when albuminuria was present (Figure 5). Concomitant with the development of albuminuria, albumin-positive granules were found in podocytes in male MWF rats. Staining of sequential sections for albumin, podoplanin, and desmin revealed that albumin droplets were present predominantly in desmin-positive, podoplanin-negative podocytes (Figure 4).

Immunohistochemical experiments revealed no change in expression of the podocyte-associated molecules  $\alpha$ -actinin-4,  $\alpha$ -dystroglycan, ezrin, podocalyxin, podocin, nephrin, ZO-1, and synaptopodin at any time and in either rat strain (data not shown). To investigate changes in glomerular endothelial cells, we performed staining with the monoclonal antibody Jg12.<sup>26</sup> There were no changes in the

endothelial distribution over time and no differences between MWF and SHR rats (data not shown).

### *Electron microscopy*

Electron microscopy at 8 weeks of age revealed focal and segmental foot process effacement in close proximity to morphologically normal capillaries with unaffected podocytes. Some podocytes with foot process effacement contained electron-dense granules, suggestive of albumin-containing absorption droplets (Figure 6).

Measure	Week 4		Week 6		Week 8	
	Male	Female	Male	Female	Male	Female
Kidney weight, mg	486.5±32.7	408.1±63	961.9±140.1	720.5±65	1055.6±83.5	728.8±71.1
Body weight, g	98.42±1.96	80.61±8.31	203.06±23	145.2±5.45	241.28±10	164.3±12.44
KW/BW, %	0.49±0.03	0.50±0.04	0.47±0.02	0.50±0.03	0.44±0.03	0.44±0.02
Albuminuria, mg/24 hours	0.14±0.11	0.11±0.04	18.4±10.4	11.7±10	20.07±6.7*	9.5±6.6
Number of podocytes per glomerulus	254.6±30.4	248.1±30.7	279.7±43	285.9±26.8	241.0±25.5	248.3±43.9
Glomerular volume, ×1000	992.4±177.8	869.4±82.9	1890.4±441.0	1695.6±404.8	1754.3±169.5	1689.2±302.7
Volume per podocyte, ×1000	3.9±0.6	3.5±0.3	6.7±1.2	5.9±1.3	7.4±1.1	6.8±0.7

\* $P < 0.05$  versus female MWF rats at 8 weeks BW, body weight; KW, kidney weight; SD, standard deviation.

**Table 2.** Clinical and morphological parameters for female and male MWF rats .

### ***Comparison of male and female MWF rats***

Female MWF rats, like male MWF rats, developed albuminuria starting at 6 weeks of age; levels were significantly higher in males versus females at 8 weeks of age (Figure 1). There were no significant differences between males and females in the number of podocytes, glomerular volume, and glomerular volume per podocyte (Table 2). Immunohistochemistry on renal tissue of female MWF rats also showed focal and segmental loss of podoplanin protein expression and increased expression of desmin in the same podocytes. There were no differences between males and females in the percentage of glomeruli exhibiting loss of podoplanin (Figure 7a). However, the percentage of glomeruli with desmin-positive podocytes was significantly higher

in males versus females at 8 weeks of age (Figure 7b). As in males, there were no changes in the expression of other podocyte-associated molecules.

### Correlations

To identify statistically significant relationships between variables, Pearson correlations were calculated between albuminuria and podocyte-associated characteristics in the total group of MWF rats (male and female). There was a significant, positive correlation between the level of albuminuria and the percentage of glomeruli exhibiting loss of podoplanin, the increase in desmin expression, glomerular volume, and volume per podocyte in MWF (Table 3). The percentage of glomeruli with desmin in podocytes correlated positively with the percentage of

	Albumin Uria	Loss of Podoplanin*	Desmin in Podocytes†	No. of Podocytes per Glomerulus	Mean Glomerular Volume	Volume per Podocyte
Albuminuria						
Correlation (R)	1					
P value						
Loss of podoplanin*						
Correlation (R)	0.577	1				
P value	0.001					
Desmin in podocytes†						
Correlation (R)	0.643	0.431	1			
P value	0.000	0.022				
No. of podocytes per glomerulus						
Correlation (R)	0.279	0.215	-0.026	1		
P value	0.135	0.272	0.893			
Mean glomerular volume						
Correlation (R)	0.687	0.759	0.528	0.421	1	
P value	0.000	0.000	0.003	0.021		
Volume per podocyte						
Correlation (R)	0.627	0.729	0.617	-0.034	0.886	1
P value	0.000	0.000	0.000	0.858	0.000	

\*Percentage of glomeruli with loss of podoplanin. †Percentage of glomeruli with desmin expression in podocytes.

**Table 3.** Correlations between podocyte morphology and protein expression in male and female MWF rats.



glomeruli exhibiting loss of podoplanin (Table 3). Separate correlation analyses for males and females produced the same results (data not shown).

## Discussion

To our knowledge, this is the first demonstration that glomerular hypertrophy precedes the development of albuminuria in male and female MWF rats. Most interestingly, we observed that development of albuminuria at 6 weeks of age is accompanied by focal and segmental loss of podoplanin protein expression in podocytes and *de novo* expression of desmin in the same podocytes. This occurred concomitantly with entrapment of albumin in these podocytes and focal and segmental foot process effacement at the electron microscopic level. There were no changes in other podocyte-associated molecules (Table 1).

Glomerular hypertrophy is present in biopsies of patients with secondary FSGS, and it is linked to development of proteinuria and glomerulosclerosis in humans and experimental animals (reviewed by Fogo in <sup>33</sup>). It was hypothesized that the expansion of the glomerular tuft requires adaptation of the glomerular epithelial cells to cover a wider area of the glomerular capillary wall, a process that necessitates reorganization of the actin cytoskeleton and increased podocyte workload.<sup>34</sup> This increased workload may lead to podocyte damage and eventually podocyte loss. The glomerular hypertrophy observed in the present study is most likely the result of the previously described inborn nephron deficit in MWF rats.<sup>22</sup> The resulting increased workload of podocytes was followed by loss of podoplanin protein in podocytes and development of albuminuria. This strongly suggests that glomerular hypertrophy is involved in development of podocyte damage and albuminuria in MWF rats.

Loss of podoplanin protein and *de novo* expression of desmin in podocytes occurred simultaneously. These changes seem to be causally related, as podocytes exhibiting loss of podoplanin specifically expressed desmin. However, we do not know which event occurred first; therefore, we cannot speculate about the mechanisms preceding this very early event in FSGS. There were no changes in other podocyte-associated molecules such as nephrin and ZO-1 during the development of microalbuminuria. This suggests that segmental loss of podoplanin is the primary molecular event in the development of albuminuria and that the previously described changes in nephrin and ZO1 protein <sup>24;25</sup> are secondary to albuminuria.

Breiteneder-Geleff and Matsui et al described a role for podoplanin in the development of proteinuria.<sup>27;35</sup> This 43-kd glycoprotein is expressed by lymphatic endothelial cells in the kidney and is also localized on cell membranes of podocytes, predominantly at the urinary surface but also at the base of foot processes.<sup>35;36</sup>

Podoplanin was downregulated in podocytes in puromycin aminonucleoside nephrosis, a rat model of specific podocyte damage and proteinuria.<sup>35</sup> Furthermore, treatment with divalent IgG anti-podoplanin antibodies has been shown to induce rapidly reversible proteinuria concomitant with extensive foot process effacement.<sup>27</sup> Podoplanin is upregulated in the invasive fronts of several human carcinomas, and ectopic expression of podoplanin results in the formation of cell extensions and reorganization of the cytoskeleton. These observations suggest a role for podoplanin in tumor cell migration and invasion.<sup>37-41</sup> Data obtained in experimental models of proteinuric renal disease<sup>27:35</sup> indicate that podoplanin in podocytes may also be involved in maintaining the highly specialized structure of the podocyte and its foot processes during hypertrophy, which is essential to normal functioning of the glomerular filtration barrier.<sup>27:35</sup> Thus far, it has been impossible to investigate this hypothesis in more detail because podoplanin-deficient mice exhibit lethal lymphatic abnormalities.<sup>38</sup> In addition, podocytes in mice do not highly express podoplanin. Thus, podocyte-specific downregulation of podoplanin in rats is more suitable to investigation of podoplanin function in the glomerulus.

We hypothesize that segmental loss of podoplanin protein leads to structural changes in podocytes and to a dysfunctional glomerular filtration barrier within the affected segments. This is supported by our observation that albumin accumulates in podocytes in which podoplanin protein has been lost. Furthermore, at the electron microscopic level, albumin droplets were specifically found in podocytes with foot process effacement. This may be the result of increased albumin filtration at these sites or an indication of increased reabsorption of albumin by these podocytes. We conclude from these results that increased albumin filtration occurs in glomerular segments exhibiting podoplanin loss. However, we did not find a correlation between the loss of podoplanin and mean area of albumin per glomerulus (data not shown). One explanation for this finding is that the staining for albumin is not as specific as the staining for podoplanin or desmin. Furthermore, the presence of albumin could be transient. The loss of podoplanin and increase of desmin seems more permanent, while albumin reabsorption and degradation is a dynamic process.

The present study showed loss of podoplanin on protein level. Podoplanin has been investigated on mRNA level in acquired human renal diseases before.<sup>42;43</sup> These two studies describe an increase of podoplanin mRNA level in glomeruli of patients with human renal disease, such as minimal change disease and membranous nephropathy. Although podoplanin was not investigated at protein level in these studies, in the study of Koop et al, other podocyte-associated molecules were downregulated at protein level, while the corresponding mRNA expression levels were increased. This discrepancy between mRNA and protein was explained by a

compensatory upregulation of mRNA when protein expression was decreased. Although we haven't investigated podoplanin in MWF rats at mRNA level, a compensatory upregulation of podoplanin mRNA could also be present in MWF rats.

Our results raise the question of why there are only segmental changes in the expression of podoplanin and desmin in the glomeruli of MWF rats. Although there has been thorough investigation of the role of hyperfiltration and hypertrophy in the development of podocyte damage<sup>44</sup>, no clear explanation has been found for the segmental pattern of glomerulosclerosis. Is it a stochastic process or is there a propensity for glomerulosclerosis at weak spots in the glomerular wall? Possibly, intraglomerular differences in capillary pressure or podocyte-associated adaptation processes play a role. As vascular damage is present in predictable locations and structures such as branches and bifurcations in systemic hypertension, intraglomerular differences may also render some segments of the glomerulus more prone to hyperfiltration-induced damage. In MWF rats, we did not observe podocyte damage at a single preferred location in the glomerulus. Further study of intraglomerular adaptation processes is necessary to account for the segmental changes.

Segmental glomerular changes are also present in patients with FSGS.<sup>8</sup> Although the exact mechanism underlying the development of segmental glomerulosclerosis is unknown, podocyte damage is thought to play a role. Because male MWF rats develop FSGS late in life<sup>21</sup>, it is tempting to speculate that glomerulosclerosis will develop in glomeruli with segmental loss of podoplanin.

Genetic factors are known to determine albuminuria, renal lesions, and the inborn deficit of nephrons in MWF rats. Linkage analysis of male MWF rats and contrasting reference strains with low albuminuria has revealed multiple quantitative trait loci that are involved in the development of albuminuria but are independent of blood pressure.<sup>6,45</sup> Transfer of chromosome 6 of SHR rats into male MWF rats normalizes the nephron deficit and produces a marked suppression of albuminuria and glomerulosclerosis in the resulting consomic strain.<sup>46</sup> Therefore, genes located within the quantitative trait loci on chromosome 6 may play a causal role in the inherited deficit in nephron number and the subsequent changes in glomeruli and podocytes reported here.

In addition to genetic factors, sex influences the severity and progression of renal disease in humans and experimental models.<sup>5</sup> In MWF rats, there is sexual dimorphism in the development of overt proteinuria and FSGS. Males develop overt proteinuria and FSGS later in life, whereas females are protected from proteinuria and FSGS.<sup>20</sup> Glomerular hypertrophy and loss of podoplanin are apparently not

sufficient for the development of overt proteinuria and FSGS in female MWF rats. Additional factors are required for the aggravation of albuminuria in male MWF rats. The increased percentage of glomeruli with desmin-positive podocytes in males suggests an increased podocyte workload, which could contribute to the development of FSGS. It is not yet clear what gender-specific factor contributes to the increased workload in male MWF rats late in life. However, one possibility is the relatively low number of nephrons in males versus females. Although the absolute number of nephrons is similar in male and female MWF rats, the number of nephrons corrected for body weight is lower in males.<sup>22</sup> This may cause male MWF rats to have a less favorable ratio between the number of nephrons and metabolic demand, which may lead to aggravation of hypertrophy, albuminuria, and progressive glomerulosclerosis in males.<sup>22</sup>

Other possibilities are specific sex-related differences in renal hemodynamics, alterations in the renin-angiotensin system, and direct effects of sex hormones.<sup>47-49</sup> The presence of testosterone worsens the outcome of renal disease, whereas estrogens seem to be protective in several experimental models.<sup>50-54</sup> Estrogen and androgen receptors within the glomerulus are thought to mediate the induction or prevention of glomerulosclerosis.<sup>52:55</sup> The exact influence of sex hormones on the severity of renal disease and progression to ESRD needs further investigation.

In conclusion, our data show, for the first time, that development of albuminuria in male and female MWF rats is preceded by glomerular hypertrophy and accompanied by focal and segmental loss of podoplanin protein and podocyte stress before histological signs of FSGS are present.

## **Acknowledgements**

We thank Kirsten van Beelen for her assistance with the immunohistochemistry. We also thank Dr. Kawachi for the anti-nephrin antibody, Dr. Schweikert and Dr. Beggs for the anti- $\alpha$ -actinin-4 antibody, Dr. Antignac for the anti-podocin antibody, and Dr. Miettinen for the anti-podocalyxin antibody. We thank Peter Neeskens and Frans Prins for their help with the electron microscopy studies.

---

## Reference List

1. Kitiyakara C, Kopp JB, Eggers P: Trends in the epidemiology of focal segmental glomerulosclerosis. *Semin Nephrol* 23:172-182, 2003
2. Rydel JJ, Korbet SM, Borok RZ, Schwartz MM: Focal segmental glomerular sclerosis in adults: presentation, course, and response to treatment. *Am J Kidney Dis* 25:534-542, 1995
3. Freedman BI, Beck SR, Rich SS, Heiss G, Lewis CE, Turner S, Province MA, Schwander KL, Arnett DK, Mellen BG: A genome-wide scan for urinary albumin excretion in hypertensive families. *Hypertension* 42:291-296, 2003
4. Krolewski AS, Poznik GD, Placha G, Canani L, Dunn J, Walker W, Smiles A, Krolewski B, Fogarty DG, Moczulski D, Araki S, Makita Y, Ng DP, Rogus J, Duggirala R, Rich SS, Warram JH: A genome-wide linkage scan for genes controlling variation in urinary albumin excretion in type II diabetes. *Kidney Int* 69:129-136, 2006
5. Neugarten J: Gender and the progression of renal disease. *J Am Soc Nephrol* 13:2807-2809, 2002
6. Schulz A, Litfin A, Kossmehl P, Kreutz R: Genetic dissection of increased urinary albumin excretion in the munich wistar fromter rat. *J Am Soc Nephrol* 13:2706-2714, 2002
7. D'Agati V: The many masks of focal segmental glomerulosclerosis. *Kidney Int* 46:1223-1241, 1994
8. D'Agati VD, Fogo AB, Bruijn JA, Jennette JC: Pathologic classification of focal segmental glomerulosclerosis: a working proposal. *Am J Kidney Dis* 43:368-382, 2004
9. Brenner BM: Nephron adaptation to renal injury or ablation. *Am J Physiol* 249:F324-F337, 1985
10. Kriz W: Podocyte is the major culprit accounting for the progression of chronic renal disease. *Microsc Res Tech* 57:189-195, 2002
11. Kriz W, LeHir M: Pathways to nephron loss starting from glomerular diseases-insights from animal models. *Kidney Int* 67:404-419, 2005
12. Kawachi H, Miyauchi N, Suzuki K, Han GD, Orikasa M, Shimizu F: Role of podocyte slit diaphragm as a filtration barrier. *Nephrology (Carlton)* 11:274-281, 2006
13. Tryggvason K, Patrakka J, Wartiovaara J: Hereditary proteinuria syndromes and mechanisms of proteinuria. *N Engl J Med* 354:1387-1401, 2006
14. Kerjaschki D: Caught flat-footed: podocyte damage and the molecular bases of focal glomerulosclerosis. *J Clin Invest* 108:1583-1587, 2001
15. Wiggins RC: The spectrum of podocytopathies: A unifying view of glomerular diseases. *Kidney Int* 2007
16. Wharram BL, Goyal M, Wiggins JE, Sanden SK, Hussain S, Filipiak WE, Saunders TL, Dysko RC, Kohno K, Holzman LB, Wiggins RC: Podocyte depletion causes glomerulosclerosis: diphtheria toxin-induced podocyte depletion in rats expressing human diphtheria toxin receptor transgene. *J Am Soc Nephrol* 16:2941-2952, 2005
17. Ritz E: Renal dysfunction as a novel risk factor: microalbuminuria and cardiovascular risk. *Kidney Int Suppl* S25-S28, 2005
18. de Jong PE, Curhan GC: Screening, monitoring, and treatment of albuminuria: Public health perspectives. *J Am Soc Nephrol* 17:2120-2126, 2006
19. Weir M: microalbuminuria and cardiovascular disease. *Clin J Am Soc Nephrol* 2:581-590, 2007
20. Remuzzi A, Puntorieri S, Mazzoleni A, Remuzzi G: Sex related differences in glomerular ultrafiltration and proteinuria in Munich-Wistar rats. *Kidney Int* 34:481-486, 1988
21. Remuzzi A, Gagliardini E, Sangalli F, Bonomelli M, Piccinelli M, Benigni A, Remuzzi G: ACE

- inhibition reduces glomerulosclerosis and regenerates glomerular tissue in a model of progressive renal disease. *Kidney Int* 69:1124-1130, 2006
22. Fassi A, Sangalli F, Maffi R, Colombi F, Mohamed EI, Brenner BM, Remuzzi G, Remuzzi A: Progressive glomerular injury in the MWF rat is predicted by inborn nephron deficit. *J Am Soc Nephrol* 9:1399-1406, 1998
  23. Kreuzt R, Kovacevic L, Schulz A, Rothermund L, Ketteler M, Paul M: Effect of high NaCl diet on spontaneous hypertension in a genetic rat model with reduced nephron number. *J Hypertens* 18:777-782, 2000
  24. Macconi D, Ghilardi M, Bonassi ME, Mohamed EI, Abbate M, Colombi F, Remuzzi G, Remuzzi A: Effect of angiotensin-converting enzyme inhibition on glomerular basement membrane permeability and distribution of zonula occludens-1 in MWF rats. *J Am Soc Nephrol* 11:477-489, 2000
  25. Macconi D, Bonomelli M, Benigni A, Plati T, Sangalli F, Longaretti L, Conti S, Kawachi H, Hill P, Remuzzi G, Remuzzi A: Pathophysiologic implications of reduced podocyte number in a rat model of progressive glomerular injury. *Am J Pathol* 168:42-54, 2006
  26. Matsui K, Nagy-Bojarsky K, Laakkonen P, Krieger S, Mechtler K, Uchida S, Geleff S, Kang DH, Johnson RJ, Kerjaschki D: Lymphatic microvessels in the rat remnant kidney model of renal fibrosis: aminopeptidase p and podoplanin are discriminatory markers for endothelial cells of blood and lymphatic vessels. *J Am Soc Nephrol* 14:1981-1989, 2003
  27. Matsui K, Breiteneder-Geleff S, Kerjaschki D: Epitope-specific antibodies to the 43-kD glomerular membrane protein podoplanin cause proteinuria and rapid flattening of podocytes. *J Am Soc Nephrol* 9:2013-2026, 1998
  28. Morioka Y, Koike H, Ikezumi Y, Ito Y, Oyanagi A, Gejyo F, Shimizu F, Kawachi H: Podocyte injuries exacerbate mesangial proliferative glomerulonephritis. *Kidney Int* 60:2192-2204, 2001
  29. Sanden SK, Wiggins JE, Goyal M, Riggs LK, Wiggins RC: Evaluation of a thick and thin section method for estimation of podocyte number, glomerular volume, and glomerular volume per podocyte in rat kidney with Wilms' tumor-1 protein used as a podocyte nuclear marker. *J Am Soc Nephrol* 14:2484-2493, 2003
  30. Weibel ER: Stereological methods: Practical methods for biological morphometry, 1979 ed, London academic press, 2007, pp 1-450
  31. Johnson RJ, Iida H, Alpers CE, Majesky MW, Schwartz SM, Pritzl P, Gordon K, Gown AM: Expression of smooth muscle cell phenotype by rat mesangial cells in immune complex nephritis. Alpha-smooth muscle actin is a marker of mesangial cell proliferation. *J Clin Invest* 87:847-858, 1991
  32. Floege J, Alpers CE, Sage EH, Pritzl P, Gordon K, Johnson RJ, Couser WG: Markers of complement-dependent and complement-independent glomerular visceral epithelial cell injury in vivo. Expression of antiadhesive proteins and cytoskeletal changes. *Lab Invest* 67:486-497, 1992
  33. Fogo AB: Glomerular hypertension, abnormal glomerular growth, and progression of renal diseases. *Kidney Int Suppl* 75:S15-S21, 2000
  34. Kriz W, Elger M, Mundel P, Lemley KV: Structure-stabilizing forces in the glomerular tuft. *J Am Soc Nephrol* 5:1731-1739, 1995
  35. Breiteneder-Geleff S, Matsui K, Soleiman A, Meraner P, Poczewski H, Kalt R, Schaffner G, Kerjaschki D: Podoplanin, novel 43-kD membrane protein of glomerular epithelial cells, is down-regulated in puromycin nephrosis. *Am J Pathol* 151:1141-1152, 1997
  36. Matsui K, Breiteneder-Geleff S, Soleiman A, Kowalski H, Kerjaschki D: Podoplanin, a novel 43-kDa membrane protein, controls the shape of podocytes. *Nephrol Dial Transplant* 14 Suppl 1:9-

- 11, 1999
37. Martin-Villar E, Megias D, Castel S, Yurrita MM, Vilaro S, Quintanilla M: Podoplanin binds ERM proteins to activate RhoA and promote epithelial-mesenchymal transition. *J Cell Sci* 119:4541-4553, 2006
  38. Schacht V, Ramirez MI, Hong YK, Hirakawa S, Feng D, Harvey N, Williams M, Dvorak AM, Dvorak HF, Oliver G, Detmar M: T1alpha/podoplanin deficiency disrupts normal lymphatic vasculature formation and causes lymphedema. *EMBO J* 22:3546-3556, 2003
  39. Scholl FG, Gamallo C, Vilaro S., Quintanilla M: Identification of PA2.26 antigen as a novel cell-surface mucin-type glycoprotein that induces plasma membrane extensions and increased motility in keratinocytes. *J Cell Sci* 112 ( Pt 24):4601-4613, 1999
  40. Wicki A, Lehembre F, Wick N, Hantusch B, Kerjaschki D, Christofori G: Tumor invasion in the absence of epithelial-mesenchymal transition: podoplanin-mediated remodeling of the actin cytoskeleton. *Cancer Cell* 9:261-272, 2006
  41. Wicki A, Christofori G: The potential role of podoplanin in tumour invasion. *Br J Cancer* 96:1-5, 2007
  42. Koop K, Eikmans M, Baelde HJ, Kawachi H, De Heer E, Paul LC, Bruijn JA: Expression of podocyte-associated molecules in acquired human kidney diseases. *J Am Soc Nephrol* 14:2063-2071, 2003
  43. Schmid H, Henger A, Cohen CD, Frach K, Grone HJ, Schlondorff D, Kretzler M: Gene expression profiles of podocyte-associated molecules as diagnostic markers in acquired proteinuric diseases. *J Am Soc Nephrol* 14:2958-2966, 2003
  44. Wiggins JE, Goyal M, Sanden SK, Wharram BL, Shedden KA, Misek DE, Kuick RD, Wiggins RC: Podocyte hypertrophy, "adaptation," and "decompensation" associated with glomerular enlargement and glomerulosclerosis in the aging rat: prevention by calorie restriction. *J Am Soc Nephrol* 16:2953-2966, 2005
  45. Schulz A, Standke D, Kovacevic L, Mostler M, Kossmehl P, Stoll M, Kreutz R: A major gene locus links early onset albuminuria with renal interstitial fibrosis in the MWF rat with polygenetic albuminuria. *J Am Soc Nephrol* 14:3081-3089, 2003
  46. Schulz A, Weiss J, Schlesener M, Hansch J, Wehland M, Wendt N, Kossmehl P, Sietmann A, Grimm D, Stoll M, Nyengaard JR, Kreutz R: Development of overt proteinuria in the Munich Wistar Fromter rat is suppressed by replacement of chromosome 6 in a consomic rat strain. *J Am Soc Nephrol* 18:113-121, 2007
  47. Kang DH, Yu ES, Yoon KI, Johnson R: The impact of gender on progression of renal disease: potential role of estrogen-mediated vascular endothelial growth factor regulation and vascular protection. *Am J Pathol* 164:679-688, 2004
  48. Miller JA, Cherney DZ, Duncan JA, Lai V, Burns KD, Kennedy CR, Zimpelmann J, Gao W, Cattran DC, Scholey JW: Gender differences in the renal response to renin-angiotensin system blockade. *J Am Soc Nephrol* 17:2554-2560, 2006
  49. Neugarten J, Acharya A, Silbiger SR: Effect of gender on the progression of nondiabetic renal disease: a meta-analysis. *J Am Soc Nephrol* 11:319-329, 2000
  50. Baltatu O, Cayla C, Iliescu R, Andreev D, Jordan C, Bader M: Abolition of hypertension-induced end-organ damage by androgen receptor blockade in transgenic rats harboring the mouse ren-2 gene. *J Am Soc Nephrol* 13:2681-2687, 2002
  51. Baltatu O, Cayla C, Iliescu R, Andreev D, Bader M: Abolition of end-organ damage by antiandrogen treatment in female hypertensive transgenic rats. *Hypertension* 41:830-833, 2003
  52. Elliot SJ, Berho M, Korach K, Doublier S, Lupia E, Striker GE, Karl M: Gender-specific effects of endogenous testosterone: Female alpha-estrogen receptor-deficient C57Bl/6J mice develop

- glomerulosclerosis. *Kidney Int* 2007
53. Loria AS, Reverte V, Salazar F, Saez F, Llinas MT, Salazar FJ: Gender and age differences of renal function in rat with reduced ANG II activity during the nephrogenic period. *Am J Physiol Renal Physiol* 2007
  54. Verhagen AM, Attia DM, Koomans HA, Joles JA: Male gender increases sensitivity to proteinuria induced by mild NOS inhibition in rats: role of sex hormones. *Am J Physiol Renal Physiol* 279:F664-F670, 2000
  55. Potier M, Karl M, Zheng F, Elliot SJ, Striker GE, Striker LJ: Estrogen-related abnormalities in glomerulosclerosis-prone mice: reduced mesangial cell estrogen receptor expression and pro-sclerotic response to estrogens. *Am J Pathol* 160:1877-1885, 2002
  56. Topham PS, Kawachi H, Haydar SA, Chugh S, Addona TA, Charron KB, Holzman LB, Shia M, Shimizu F, Salant DJ: Nephritogenic mAb 5-1-6 is directed at the extracellular domain of rat nephrin. *J Clin Invest* 1999, 104:1559-1566
  57. Kaplan JM, Kim SH, North KN, Rennke H, Correia LA, Tong HQ, Mathis BJ, Rodriguez-Perez JC, Allen PG, Beggs AH, Pollak MR: Mutations in ACTN4, encoding  $\alpha$ -actinin-4, cause familial focal segmental glomerulosclerosis. *Nat Genet* 2000, 24:251-256
  58. Miettinen A, Dekan G, Farquhar MG: Monoclonal antibodies against membrane proteins of the rat glomerulus. Immunochemical specificity and immunofluorescence distribution of the antigens. *Am J Pathol* 1990, 137:929-944
  59. Roselli S, Gribouval O, Boute N, Sich M, Benessy F, Attie T, Gubler MC, Antignac C: Podocin localizes in the kidney to the slit diaphragm area. *Am J Pathol* 2002, 160:131-139



