

Cover Page



Universiteit Leiden



The handle <http://hdl.handle.net/1887/22172> holds various files of this Leiden University dissertation.

**Author:** Rhee, Jasper Immanuel van der

**Title:** Clinical characteristics and management of melanoma families

**Issue Date:** 2013-11-06

# 8

## **Impact of Dermoscopy on the Management of High-risk Patients From Melanoma Families: A Prospective Study**

*Acta Dermato-Venereologica* 2011 Jun;91(4):428-31

Jasper I. van der Rhee, Wilma Bergman\*, Nicole A. Kukutsch\*.

\* Both authors contributed equally

Department of Dermatology, Leiden University Medical Center, Leiden, the Netherlands

## Abstract

Few studies have investigated the impact of dermoscopy on the management of relatives from melanoma families. The objective of this study was to assess the impact of dermoscopy on clinical diagnosis and management decisions in high-risk familial melanoma patients. In a prospective study 132 consecutive patients were recruited from the pigmented lesions clinic of a tertiary reference centre for familial melanoma. Dermatologists expert in dermoscopy identified 49 suspicious pigmented lesions and recorded pre- and post-dermoscopy diagnoses and management decisions. Dermoscopy was performed in 37% of the patients. Two melanomas were identified. Dermoscopy did not influence sensitivity (1.0), but resulted in 42% fewer excisions, increasing specificity from 0.53 to 0.74 ( $p = 0.031$ ). Dermoscopy resulted in a large reduction in the number of unnecessary excisions. These results suggest that the main effect of dermoscopy in clinical practice for this high risk population is a significant increase in specificity, rather than sensitivity.

## Introduction

Incidence and, to a smaller degree, mortality rates of melanoma have increased dramatically in recent years.<sup>1</sup> Between 6% and 14% of all primary cutaneous melanomas occur in a familial context.<sup>2</sup> The melanoma risk for relatives from families with two or more melanoma patients is greatly increased. In carriers of the melanoma susceptibility gene *CDKN2A*, which is found in approximately 20–40% of melanoma families, the lifetime melanoma risk can be as high as 70%.<sup>3</sup> Surveillance of these relatives is a challenging task. Given the mostly disappointing results of treatments for metastasized melanoma, the most effective way to prevent morbidity and improve survival is the early detection and excision of tumours. Thus, additional tools that can detect early signs of melanoma are valuable.

Dermoscopy is a non-invasive technique that enables the visualization of morphological structures of the skin, from the epidermis down to the superficial papillary dermis, which are not accessible to the naked eye. Several studies have shown that dermoscopy is better than naked eye examination (NEE) at discriminating melanoma from benign pigmented lesions.<sup>4–6</sup> However, few studies have investigated the effect of dermoscopy in everyday clinical practice by studying how it guides management decisions.<sup>7–10</sup> The beneficial effect of dermoscopy ultimately depends on how it improves the ability to determine whether lesions need to undergo biopsy.<sup>8, 11–14</sup> Dermoscopy improves sensitivity if melanomas that would not have been excised based on NEE are excised because of their dermoscopic evaluation. Specificity improves if dermoscopy results in a decrease in the number of excisions of benign lesions. A management-based evaluation might give a different picture of dermoscopy than a diagnosis-based evaluation, because management is based on the differential diagnosis rather than the preferential diagnosis (which has been the central issue in the majority of dermoscopy studies).

The aim of this study was to investigate the impact of dermoscopy on the clinical diagnosis and management of pigmented lesions of relatives from melanoma families, who had a very high personal risk of melanoma, who visit the pigmented lesion clinic (PLC) of a tertiary reference centre for familial melanoma.

## Materials and Methods

Between December 2005 and June 2007 patients from melanoma families who had a high personal melanoma risk were recruited from the PLC of a tertiary reference centre for familial melanoma (Department of Dermatology, Leiden University Medical Center) during their regular screening visits. Patients could be included if they fulfilled the following two

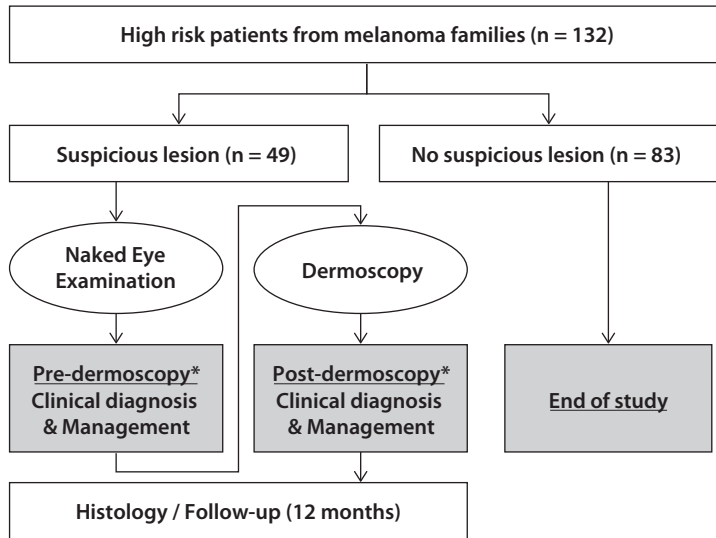
criteria: (i) they were a member of a melanoma family (defined as a family containing at least two first- or three second-degree relatives with melanoma); and (ii) they either had a personal history of melanoma, or were a CDKN2A mutation-carrier.

Dermatologists with extensive experience in dermoscopy (WB and NK) took a medical history and clinical examination, guided by the ABCDE criteria and the ugly duckling sign.<sup>15</sup> Pigmented lesions that were regarded as clinically suspicious for melanoma, and for which dermoscopy would also have been used in normal daily practice, were analysed dermoscopically. If no suspicious lesion was found the patients' next screening was scheduled, usually within one year. If more than one suspicious lesion was present, only the most suspicious was included. Prior to dermoscopic evaluation, the diagnosis and management decision based on NEE were recorded. Subsequently dermoscopy was performed and the diagnosis and management decision based on the combined NEE and dermoscopy evaluation were recorded (Fig. 1). Patients were judged in consensus by the two dermatologists (WB and NK). Dermoscopy was performed with a handheld dermatoscope on the basis of (classical) pattern analysis<sup>16</sup>, combined with more recently described (vascular) patterns and structures.<sup>17-19</sup> The decision to excise a suspicious lesion was based on the combined NEE and dermoscopic evaluation in accordance with routine clinical practice. Patients with suspicious lesions that were not excised were followed for 12 months in order to detect melanomas that were missed at the examination at the time of inclusion in the study.

## Data analysis

The proportion of high-risk patients in whom dermoscopy was performed because of a suspicious pigmented lesion was calculated. Pre- and post-dermoscopy preferential diagnoses were categorized as "melanoma" or "non-melanoma". Management strategies were also grouped into two categories: (i) "intervention": a diagnostic biopsy with the primary intention of histological verification and treatment of a possible melanoma; and (ii) "no intervention": follow-up according to the regular surveillance programme. For biopsied lesions histological diagnosis was used as the reference diagnosis. In an attempt to exclude that melanomas were missed in the case of lesions that were left un-excised, follow-up data was collected one year after inclusion in the study. If the patient had not developed a melanoma at that time, the initial suspicious lesion was regarded as being "non-melanoma".

True positives (TP) were defined as lesions that were classified as melanoma, and confirmed as melanoma on histological examination. True negatives (TN) were defined as lesions that were classified as "non-melanoma", with a subsequent diagnosis other than melanoma on histological examination or no melanoma after one year of follow-up. False positives (FP) were defined as lesions that were classified as melanoma, but not diagnosed as melanoma on histology. False negatives (FN) were defined as lesions that were classified

**Figure 1** Study design

\*Pre- and post dermoscopy clinical diagnosis and management decisions were compared.

as “non-melanoma”, but were diagnosed as melanoma on histology (on inclusion or after one year of follow-up). Sensitivity was computed as  $TP/(TP+FN)$  and specificity as  $TN/(TN+FP)$ . Sensitivity and specificity were also calculated from a management perspective, with the clinical diagnosis “non-melanoma” being exchanged for the management strategy “no intervention”, and the clinical diagnosis “melanoma” for the management strategy “intervention”. To compare sensitivity and specificity before and after dermoscopy a statistical analysis was performed, using the McNemar test (because pre- and post-dermoscopy data were not independent). Analyses were performed with SPSS 14.0, statistical significance was determined at  $\alpha = 0.05$ , and two-sided.

The impact of dermoscopy on management was analysed according to the two management categories, as defined above (“intervention” and “no intervention”), in two ways. The impact of dermoscopy on the detection of melanomas was calculated as the proportion of histologically confirmed melanomas that would not have been excised (management category: “intervention”) without the use of dermoscopy. In addition, we calculated the proportional reduction in the number of “interventions” due to dermoscopy.

## Results

### Data characteristics

In total, 132 high-risk patients from melanoma families were included, consisting of: one p14ARF mutation carrier with a personal history of melanoma, four patients with a son or daughter with melanoma (obligatory gene carriers), 13 proven CDKN2A mutation carriers with a personal history of melanoma, 27 proven CDKN2A mutation carriers without a personal history of melanoma, and 87 patients with a personal history of melanoma (20 of whom had multiple primary melanomas).

Dermoscopy was performed in 37% of the patients (49/132). Data on clinical diagnosis and management was complete for all lesions. Excision with histological examination was performed in 14 cases. Two melanomas were diagnosed; one superficial spreading melanoma (SSM, Breslow-thickness 0.86 mm) and one lentigo maligna (melanoma in situ). The 35 patients with suspicious lesions that were not biopsied were followed for 12 months. During follow-up one patient was diagnosed with a melanoma in situ 11 months after inclusion in the study. This lesion had developed in a naevus that had been changing over a period of 6 months according to the patient. Management had not been changed due to dermoscopy in this patient at the time of inclusion in the study.

### Clinical diagnosis (Fig. 2A)

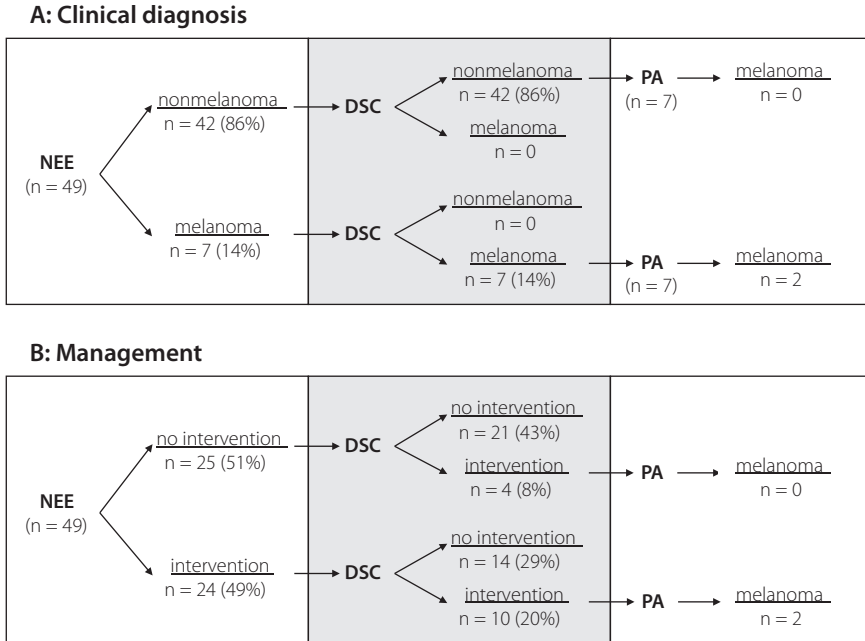
Dermoscopy did not lead to diagnosis conversions from melanoma to non-melanoma or non-melanoma to melanoma. Before and after dermoscopy the same seven lesions were considered to be melanomas. Two of these (29%) were confirmed by histology to be melanoma and the other five lesions were dysplastic naevi ( $n = 4$ ) and a common naevus. Sensitivity was 1.0 (2/2) and specificity 0.89 (42/47), both for NEE alone and for NEE combined with dermoscopy.

### Management (Fig. 2B)

After dermoscopy the management decisions changed in 37% of lesions ( $n = 18$ ). In 14 cases (29%) an excision was abandoned and in four cases (8%) an excision was decided on. These four lesions were histologically diagnosed as two dysplastic naevi and two common naevi.

Before dermoscopy an excision was intended for 49% of lesions ( $n = 24$ ), compared with 29% ( $n = 14$ ) after dermoscopy, resulting in a reduction in the total number of excisions by 42%. The malignant/benign ratio of excised lesions decreased from 1:12 (2/24) to 1:7 lesions (2/14).

Dermoscopy had no impact on the management of the two proven melanomas, as these were already intended to be excised before dermoscopy was performed. Calculations based on management decisions therefore did not show an increase in sensitivity. Specificity, however, increased significantly ( $p = 0.031$ ) from 0.53 (25/47) to 0.74 (35/47).

**Figure 2** The effect of dermoscopy on (A) the clinical diagnosis and (B) management decisions

NEE, naked eye examination; DSC, dermoscopy; PA, pathology

## Discussion

In a prospective study we investigated the impact of dermoscopy on the management of patients with a high *a priori* melanoma risk. For this purpose 132 relatives from melanoma families, who had a high personal melanoma risk, were included in a consecutive order. We recorded the proportion of patients in whom dermoscopy was performed and the impact of dermoscopy on clinical diagnoses and management decisions by comparing the evaluation of lesions by NEE with NEE followed by dermoscopy. Patients with suspicious lesions that were not biopsied were followed for one year after inclusion in order to detect false negatives.

In accordance with Carli et al.<sup>7</sup> (49%) we found that, in a large proportion of patients (63%), dermoscopy was not performed. Familial melanoma patients are known to have increased numbers of (dysplastic) naevi, but the phenotype is very variable. Some of our patients



had hardly any naevi and many had only a few. Moreover, patients were under long-term surveillance, and many (suspicious) lesions had already been removed in the past.

Dermoscopy reduced the number of excisions considerably (42%), which is in agreement with other studies.<sup>7-9</sup> In a randomized study Carli et al.<sup>7</sup> found that 38% less excisions were performed in the dermoscopy study-arm compared with the NEE arm. Two prospective studies that investigated the influence of dermoscopy on the management of lesions pre-selected for excision by NEE, found a reduction in the number of excisions of 40% and 70%.<sup>8,9</sup>

Dermoscopy had no impact on the clinical diagnosis or management of the two histologically proven melanomas and, as a consequence, did not improve sensitivity. Although specificity was not improved by dermoscopy from a clinical diagnosis perspective, it was significantly improved from a management perspective (0.53 before, 0.74 after dermoscopy), without a decrease in sensitivity, as no melanomas were missed due to the reduction in the number of excisions. This can be explained by the fact that, in accordance with other studies<sup>20,21</sup>, a considerable proportion of the lesions that were clinically judged to be benign (preferential diagnosis), were nevertheless regarded as suspicious enough to be excised (based on their differential diagnosis). For such lesions dermoscopy did not affect the clinical diagnosis, but had great influence on the selected management strategy; hence the improvement in specificity.

In a meta-analysis of studies comparing dermoscopy and NEE of suspicious pigmented lesions in a clinical setting, Vestergaard et al.<sup>6</sup> found that dermoscopy improved sensitivity significantly, but had no significant effect on specificity. Our results suggest that, from a management perspective, dermoscopy rather does the opposite: improving specificity rather than sensitivity. Of course, our study was limited by the fact that only two melanomas were diagnosed, but we recently reported similar trends in a larger study in the setting of general dermatologists working in general dermatology clinics.<sup>22</sup>

Dermatologists (specialized in) judging pigmented lesions seem to have developed considerable skills in making a final decision from patient history, clinical picture, differential-, comparative-, pattern-recognition and "gut"-feeling<sup>23</sup>, which may limit the extent to which dermoscopy contributes to identification of lesions suspicious for melanoma by this group of specialists. However, the use of dermoscopy over the past 20 years may have sharpened the NEE of pigmented lesions, and taught dermatologists to look at a pigmented lesion in a more detailed fashion.

In conclusion, dermoscopy was not performed in the majority of patients from a regularly screened, high melanoma risk patient population. Dermoscopy reduced the number of excisions considerably, and (from a management perspective) increased specificity significantly, without compromising sensitivity. However, dermoscopy did not improve

the detection of melanomas. Studies based on clinical diagnosis may overestimate the impact of dermoscopy on the ability to detect melanomas, while underestimating its ability to reduce the number of unnecessary excisions. Future studies with higher numbers of patients are needed to determine the impact of dermoscopy in daily practice, by investigating the impact of dermoscopy on management decisions.

## References

1. Lens MB, Dawes M. Global perspectives of contemporary epidemiological trends of cutaneous malignant melanoma. *Br J Dermatol* 2004; 150: 179–185.
2. Ang CG, Kelly JW, Fritschi L, Dowling JP. Characteristics of familial and non-familial melanoma in Australia. *Melanoma Res* 1998; 8: 459–464.
3. Bishop DT, Demenais F, Goldstein AM, Bergman W, Bishop JN, Bressac-de Paillerets B, et al. Geographical variation in the penetrance of CDKN2A mutations for melanoma. *J Natl Cancer Inst* 2002; 94: 894–903.
4. Bafounta ML, Beauchet A, Aegerter P, Saiag P. Is dermoscopy (epiluminescence microscopy) useful for the diagnosis of melanoma? Results of a meta-analysis using techniques adapted to the evaluation of diagnostic tests. *Arch Dermatol* 2001; 137: 1343–1350.
5. Kittler H, Pehamberger H, Wolff K, Binder M. Diagnostic accuracy of dermoscopy. *Lancet Oncol* 2002; 3: 159–165.
6. Vestergaard ME, Macaskill P, Holt PE, Menzies SW. Dermoscopy compared with naked eye examination for the diagnosis of primary melanoma: a meta-analysis of studies performed in a clinical setting. *Br J Dermatol* 2008; 159: 331–336.
7. Carli P, de G, V, Chiarugi A, Nardini P, Weinstock MA, Crocetti E, et al. Addition of dermoscopy to conventional naked-eye examination in melanoma screening: a randomized study. *J Am Acad Dermatol* 2004; 50: 683–689.
8. Argenziano G, Soyer HP, Chimenti S, Argenziano G, Ruocco V. Impact of dermoscopy on the clinical management of pigmented skin lesions. *Clin Dermatol* 2002; 20: 200–202.
9. Carli P, Mannone F, de G, V, Nardini P, Chiarugi A, Giannotti B. The problem of false-positive diagnosis in melanoma screening: the impact of dermoscopy. *Melanoma Res* 2003; 13: 179–182.
10. Argenziano G, Puig S, Zalaudek I, Sera F, Corona R, Alsina M, et al. Dermoscopy improves accuracy of primary care physicians to triage lesions suggestive of skin cancer. *J Clin Oncol* 2006; 24: 1877–1882.
11. Carli P, de G, V, Giannotti B. Dermoscopy and early diagnosis of melanoma: the light and the dark. *Arch Dermatol* 2001; 137: 1641–1644.
12. Soyer HP, Argenziano G, Talamini R, Chimenti S. Is dermoscopy useful for the diagnosis of melanoma? *Arch Dermatol* 2001; 137: 1361–1363.
13. Bystryjn JC. Epiluminescence microscopy: a reevaluation of its purpose. *Arch Dermatol* 2001; 137: 377–379.
14. de G, V, Crocetti E, Carli P. Cutaneous melanoma. *Lancet* 2005; 365: 2003–2005.
15. Bowling J, Argenziano G, Azenha A, Bandic J, Bergman R, Blum A, et al. Dermoscopy key points: recommendations from the international dermoscopy society. *Dermatology* 2007; 214: 3–5.
16. Pehamberger H, Steiner A, Wolff K. In vivo epiluminescence microscopy of pigmented skin lesions. I. Pattern analysis of pigmented skin lesions. *J Am Acad Dermatol* 1987; 17: 571–583.
17. Argenziano G, Zalaudek I, Corona R, Sera F, Cicale L, Petrillo G, et al. Vascular structures in skin tumors: a dermoscopy study. *Arch Dermatol* 2004; 140: 1485–1489.
18. Malvey J, Puig S. Dermoscopic patterns of benign volar melanocytic lesions in patients with atypical mole syndrome. *Arch Dermatol* 2004; 140: 538–544.
19. Miyazaki A, Saida T, Koga H, Oguchi S, Suzuki T, Tsuchida T. Anatomical and histopathological correlates of the dermoscopic patterns seen in melanocytic nevi on the sole: a retrospective study. *J Am Acad Dermatol* 2005; 53: 230–236.
20. Heal CF, Raasch BA, Buettner PG, Weedon D. Accuracy of clinical diagnosis of skin lesions. *Br J Dermatol* 2008; 159: 661–668.
21. Stanganelli I, Serafini M, Bucchi L. A cancer-registry-assisted evaluation of the accuracy of digital epiluminescence microscopy associated with clinical examination of pigmented skin lesions. *Dermatology* 2000; 200: 11–16.
22. van der Rhee JJ, Bergman W, Kukutsch NA. The impact of dermoscopy on the management of pigmented lesions in everyday clinical practice of general dermatologists: a prospective study. *Br J Dermatol* 2010; 162: 563–567.
23. Marghoob AA, Scope A. The complexity of diagnosing melanoma. *J Invest Dermatol* 2009; 129: 11–13.



