



Universiteit
Leiden

The Netherlands

Proteinuria and function loss in native and transplanted kidneys

Koop, K.

Citation

Koop, K. (2009, September 2). *Proteinuria and function loss in native and transplanted kidneys*. Retrieved from <https://hdl.handle.net/1887/13951>

Version: Corrected Publisher's Version

License: [Licence agreement concerning inclusion of doctoral thesis in the Institutional Repository of the University of Leiden](#)

Downloaded from: <https://hdl.handle.net/1887/13951>

Note: To cite this publication please use the final published version (if applicable).



Early Interstitial Accumulation
of Collagen Type I Discriminates
Chronic Rejection from Chronic
Cyclosporine Nephrotoxicity

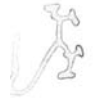Rene Bakker, Klaas Koop, Yvo Sijpkens, Michael Eikmans,
Ingeborg Bajema, Emile de Heer, Jan Anthonie Bruijn and
Leendert Paul

J Am Soc Nephrol. 2003 Aug;14(8):2142-9

6

Abstract

Little is known regarding the composition of the interstitial extracellular matrix of kidney allografts with deteriorating function. Collagen I, III, and IV, the collagen IV α 3 chain, and the laminin β 2 chain were investigated in biopsies of allografted kidneys with chronic cyclosporine A nephrotoxicity (CsAT) (n = 17), chronic rejection (CR) (n = 12), or chronic allograft nephropathy (CAN) (n = 19). α -smooth muscle actin expression was also examined. Normal native kidneys were used as control samples (n = 11). Biopsy samples were studied with routine light microscopy and immunostaining. The mean interstitial fibrosis scores were significantly higher for the CR and CAN groups, compared with the chronic CsAT group. The cortical tubulointerstitial areas of the CR and CAN groups, but not the chronic CsAT group, contained more collagen I than did normal control samples. Differences were noted even in biopsies with mild fibrosis. Accumulation of collagen III, IV, and IV α 3 was increased in all patient groups. Collagen III accumulation was greater in the CR and CAN groups than in the chronic CsAT group. Receiver-operating characteristic curve analysis demonstrated that collagen I staining had the best discriminatory value in differentiating CR from chronic CsAT, with a sensitivity of 63% and a specificity of 94% at a cutoff value of 19%. Laminin β 2 staining did not differentiate CR from CsAT. Increased α -smooth muscle actin staining did not differ among the three groups. It was concluded that, during chronic CsAT, collagen III and IV were preferentially accumulated in the tubulointerstitium. Early increases in the deposition of collagen I, with collagen III and IV, were more specific for CR. CR seems to elicit a more pronounced fibrotic response than does chronic CsAT.



Introduction

Late loss of allograft function remains a major problem in renal transplantation (1). Kidney allograft failure is usually preceded by a process of chronic transplant dysfunction, which is characterized by a relatively slow but variable rate of decline in GFR, increasing proteinuria, and increases in BP. The pathologic changes in deteriorating grafts are often less specific. The term chronic allograft nephropathy (CAN) has been adopted to classify these changes, which include chronic obliterative vascular alterations, tubular atrophy, glomerulosclerosis, and interstitial fibrosis (2).

CAN includes both chronic rejection (CR) and chronic calcineurin inhibitor toxicity (2). The nature of vascular, glomerular, and interstitial changes in CAN biopsy specimens can sometimes help to define more specifically the cause of graft dysfunction. Concentric intimal thickening of arteries and arterioles, often accompanied by a moderate degree of mononuclear cell infiltration of the vessel walls, and duplication of the glomerular basement membrane are thought to indicate CR. Smooth muscle cell necrosis and peripheral nodular medial hyalinosis of arterioles are considered hallmarks of cyclosporine A (CsA) nephrotoxicity (CsAT) (3,4).

Extracellular matrix (ECM) accumulates in the cortical interstitium regardless of the cause of chronic graft dysfunction, as observed in native kidneys with chronic diseases (4,5). Surprisingly, the ECM composition of deteriorating allografted kidneys has rarely been studied. Determination of the ECM molecules that accumulate could enhance our understanding of the pathogenesis of graft dysfunction and could potentially help define the cause, if disease-specific changes are observed. In this study, we investigated whether the ECM composition differs between allografts that lose function because of CR and allografts with chronic CsAT. We studied the cortical interstitial ECM composition of kidney allografts of three groups of patients, ie, patients with chronic CsAT, patients with CR, and patients who were receiving CsA treatment but were most likely to experience CR.

Materials and Methods

Patient Selection

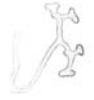All kidney allograft biopsies that were performed in our center for clinical reasons > 1 year after transplantation, in the period between March 1, 1976, and March 1, 2001, were reviewed. Cases that had available frozen-tissue samples and that met the criteria defined below were included. Patients with graft artery stenosis or diabetes mellitus were excluded. In addition, biopsy samples with histologic signs of de novo or recurrent glomerulonephritis or acute rejection were excluded.

The group designated the chronic CsAT group ($n = 17$) consisted of patients who exhibited progressive declines in allograft function only after a switch was made from a CsA formulation with a lower bioavailability (Sandimmune; Sandoz, Basel, Switzerland) to one with a higher bioavailability (Neoral; Novartis, Basel, Switzerland) (6). A brief period of acute rejection in the early post-transplantation period was allowed and occurred in eight cases. Before the switch, the patients used Sandimmune once daily, aiming at a 24 hr trough level of 100 $\mu\text{g/liter}$, and demonstrated stable graft function for a mean of 5.1 ± 3.4 year. After conversion to twice-daily Neoral therapy, a higher target 12 hr trough level of 150 $\mu\text{g/liter}$ was adopted. To reach this level, the mean CsA dose was increased from 3.2 to 3.5 mg/kg (6). Nephrotoxicity was not observed in the first months after conversion but became evident after 12 months (6). Biopsies were obtained a mean of 2.4 ± 1.2 year after switching. None of the studied biopsies in this group exhibited signs of chronic allograft glomerulopathy. No positive staining for C4d in the peritubular capillaries (see below) was observed.

The patient group designated the CR group ($n = 12$) consisted of patients who exhibited progressive declines in renal allograft function with a calcineurin inhibitor-free immunosuppressive regimen. Immunosuppressive therapy consisted of prednisone and azathioprine. All of these patients initially demonstrated good allograft function (Table 1). Thirty-three percent exhibited C4d positivity in their peritubular capillaries.

A third group of patients received CsA but their allograft biopsies suggested CR as the cause of declines in allograft function. This group, designated the CAN group, consisted of patients with progressive declines in renal allograft function and biopsy findings suggesting CR, including arterial intimal fibrosis ($n = 15$) and/or chronic allograft glomerulopathy with glomerular basement membrane duplication ($n = 4$). No temporal relationship existed between the loss of function and a switch to Neoral for any of these patients. In this group, 21% of the biopsies were positive for C4d deposits in the peritubular capillaries. The control group ($n = 11$) consisted of specimens from normal kidneys obtained in autopsies and from normal kidneys that had not been used for transplantation for anatomic reasons.

Clinical and laboratory data were obtained in chart reviews. The collected data included posttransplantation time, allograft age (donor age plus time after transplantation), systolic and diastolic blood pressure, number of antihypertensive medications used, creatinine clearance (as estimated with the Cockcroft-Gault formula), loss of allograft function, proteinuria, and CsA trough levels at the time of biopsy. The loss of allograft function was defined as the difference in the creatinine clearance measured before the worsening of allograft function, as assessed by the breakpoint in the regression lines of $1/\text{creatinine clearance}$, and the creatinine clearance measured at the time of the index biopsy (7).



Light Microscopy

After routine staining, the biopsy specimens were coded and reevaluated with light microscopy. An experienced pathologist who was blinded with respect to the instituted immunosuppressive regimen scored the histopathologic changes. The Banff 97 classification system for histopathologic scoring of allografted kidneys was used (8).

Immunostaining

The ECM components that were studied were detected with an indirect immunoperoxidase technique. Staining for each molecule was performed in one session. The primary antibodies used were polyclonal mouse anti-human collagen I, anti-human collagen III, and anti-human collagen IV (Harlan Sera-Lab, Sussex, UK) and monoclonal mouse antibodies against the collagen IV α 3 (Wieslab, Lund, Sweden) and laminin β 2 (C4) (Developmental Studies Hybridoma Bank, Iowa City, IA) chains. The secondary antibody consisted of peroxidase-coupled rabbit anti-mouse IgG (Dako, Glostrup, Denmark). Cryostat sections (4 μ m) were mounted on glass slides, dried for 1 h, and stored at -20°C until used. The tissue was fixed with 4% formalin for 10 min. After blocking of endogenous peroxidase by incubation for 30 min with 0.1% H₂O₂ in phosphate-buffered saline, the sections were incubated for 30 min with 5% normal rabbit serum. The sections were then incubated with the primary antibody for 1 h, followed by incubation with the secondary antibody for 30 min. The sections were incubated for 10 min in a filtered solution of 0.5 mg/ml diaminobenzidine and 0.02% H₂O₂ and were then incubated for 5 min with 0.05% CuSO₄ in saline solution. Counterstaining with hematoxylin was performed for 15 s. Between all steps, the slides were rinsed with phosphate-buffered saline.

Immunofluorescence staining for C4d was performed on untreated slides, as described previously (9). Mouse anti-C4d (Quidel, San Diego, CA) was used as the primary antibody (9). The secondary antibody was FITC-conjugated goat anti-mouse Ig (Sigma Chemical Co., St. Louis, MO). Staining was independently evaluated by two authors (KK and ME), who were blinded with respect to the diagnoses. A previously described scoring method was used (10).

Image Analysis

After immunostaining, the slides were coded and analyzed in a blinded manner. Digital image analysis was performed with a Zeiss microscope equipped with a full-color 3CCD camera (DXD 950p; Sony Corp., Tokyo, Japan) and KS-400 image analysis software, version 3.0 (Zeiss-Kontron, Eching, Germany). This method of digital image analysis has been validated and demonstrated to be highly reproducible (11,12). Images of the renal cortex of each biopsy specimen were obtained and analyzed with the aid of automated script protocols (macros) developed in our department. Recording and analyses of images were performed with fixed settings. The software allowed censoring of regions of noninterest. Larger vessels and glomeruli were omitted from the analyses. The deposition of each ECM component was determined in each biopsy sample by calculation of

the percentage of surface area stained by the indicator dye, relative to the total surface area. The degree of deposition was assessed by evaluation of the entire renal cortex, with a minimum of five microscopic fields per biopsy sample (at x200 magnification).

The biopsy specimens that were stained for the laminin $\beta 2$ and collagen IV $\alpha 3$ chains were also directly evaluated for interstitial or tubular expression of those molecules, by two investigators (RB and KK) who were blinded with respect to the diagnoses. In the few cases of discordant scoring, decisions were reached by consensus.

Statistical Analyses

Statistical analyses were performed with SPSS for Windows software (SPSS, Inc., Chicago, IL). One-way ANOVA was used for comparisons of continuous variables with normal distributions. Either a Bonferroni or Games-Howel post hoc procedure was used when appropriate. The Mann-Whitney U test was used to compare continuous variables that were not distributed normally. The data are expressed as mean \pm SD or mean \pm SEM, as indicated. In a general linear model, values were adjusted for differences in the loss of allograft function and creatinine clearance at the time of biopsy. Correlations between the degree of deposition of individual ECM components and the clinical characteristics of the patients were evaluated with the Pearson correlation test. $P < 0.05$ was considered statistically significant. Using a receiver-operating characteristic curve, we determined the cutoff point of the percentage of staining for the various ECM molecules that predicted the presence of CR with the best combination of sensitivity and specificity.

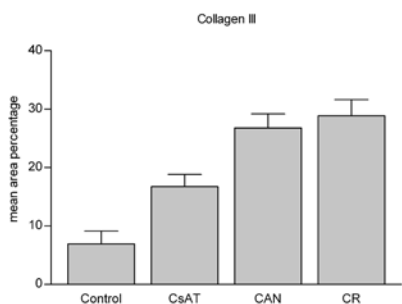
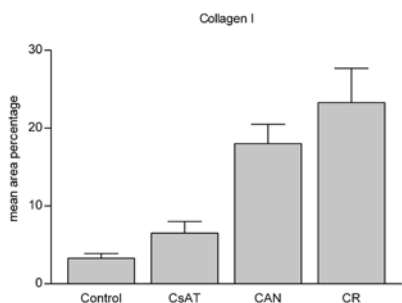
Results

Patient Data

The clinical characteristics of the patients are presented in Table 1. The mean age of the allografted kidney was lower for the patients with CR, compared with the patients with chronic CsAT or CAN. The loss of creatinine clearance was greater for the patients with CR. The time after transplantation, BP values, number of antihypertensive drugs prescribed, and creatinine clearance at the time of biopsy were similar among the groups. No difference in CsA trough levels was observed between the groups receiving CsA.

Light-Microscopic Findings

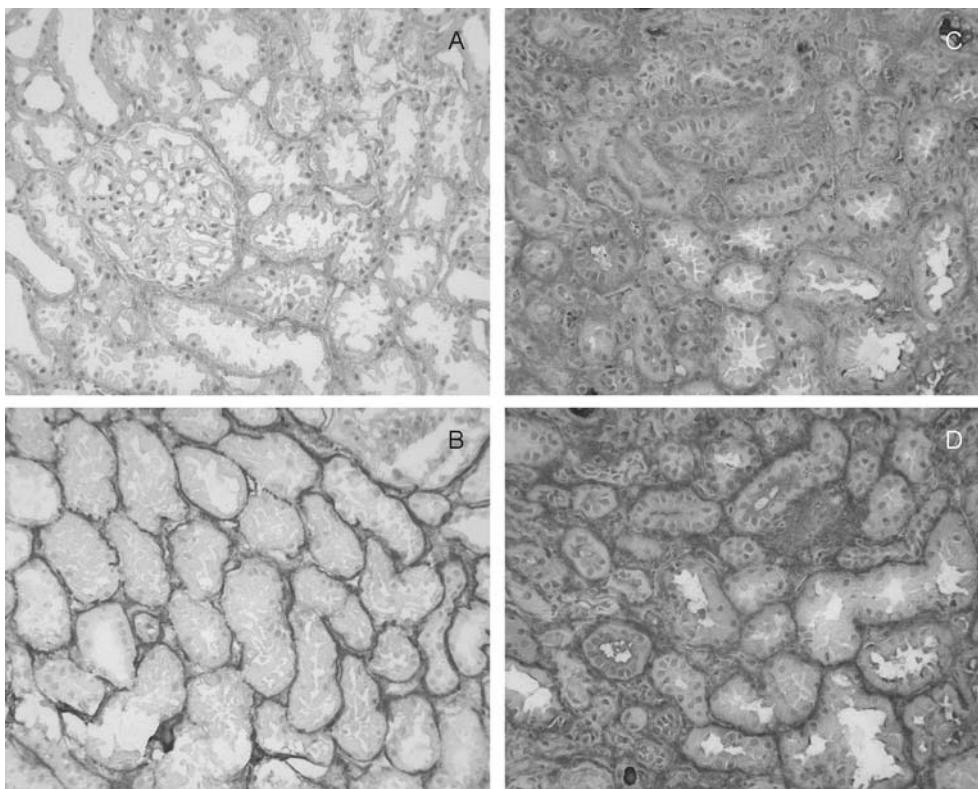
The chronic histopathologic changes that were observed in the biopsy samples in routine light-microscopic analyses are summarized in Table 2. The mean interstitial fibrosis scores for the CR and CAN groups were significantly higher than that for the chronic CsAT group (CR group versus



chronic CsAT group, $P = 0.011$; CAN group versus chronic CsAT group, $P = 0.001$). The tubular atrophy scores were higher for the CR and CAN groups, but the differences did not reach statistical significance (CR group versus chronic CsAT group, $P = 0.422$; CAN group versus chronic CsAT group, $P = 0.159$). The percentages of global glomerulosclerosis did not differ among the groups. The mean peripheral arteriolar hya-

Figure 1. Staining areas (mean \pm SEM) for collagen I (A) and collagen III (B). CsAT, cyclosporine A nephrotoxicity; CAN, chronic allograft nephropathy; CR, chronic rejection. * $P < 0.05$, ** $P < 0.01$.

Figure 2. Immunoperoxidase staining for cortical collagen I (A and C) and III (B and D). Representative images of a normal control sample (left) and a kidney allograft with CR (right) are shown.



line thickening score for the chronic CsAT group was higher than those for the CR and CAN groups, as expected from the case definitions.

ECM Components

First we studied the typical interstitial collagens, ie, collagen types I and III. The mean areas stained for these collagens are presented in Figure 1.

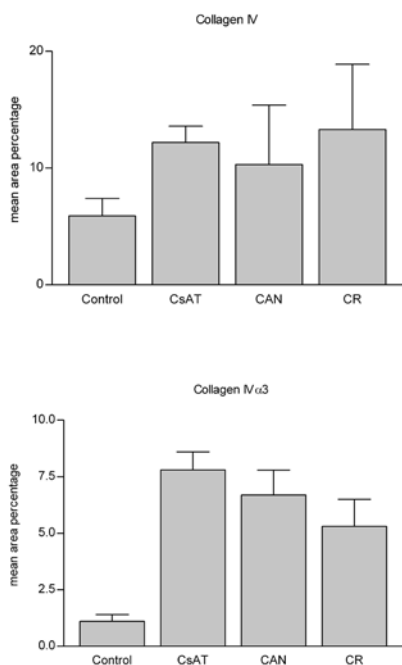


Figure 3. Staining areas (mean SEM) for collagen IV (A) and the collagen IVα3 chain (B). *P < 0.05, **P < 0.01.

The collagen I-stained areas were significantly increased in the CAN and CR groups, compared with the control group, but were not increased in the chronic CsAT group (mean area ± SEM for the CAN, CR, chronic CsAT, and control groups, 18.0 ± 2.5, 23.2 ± 4.4, 6.5 ± 1.5, and 3.3 ± 0.6%, respectively). No significant difference was observed between the CAN and CR groups.

The areas stained for collagen III were increased in all patient groups, compared with the control group (mean area ± SEM for the CAN, CR, chronic CsAT, and control groups, 26.8 ± 2.4, 28.9 ± 2.7, 16.7 ± 2.1, and 6.9 ± 2.2%, respectively). However, the areas of staining were significantly greater for the CAN and CR groups, compared with the chronic CsAT group. The staining areas did not differ significantly between the CAN and CR groups. Figure 2 presents representative

Table 1. Clinical characteristics of the patients studied

Clinical Characteristic	Patient Group		
	CsA toxicity (n = 17)	CAN (n = 19)	CR (n = 12)
Time after transplantation (yr)	7.1 ± 3.3	5.5 ± 4.1	5.1 ± 4.3
Allograft age (yr)	51 ± 9	42 ± 15	34 ± 12b
BP, systolic (mmHg)	148 ± 19	154 ± 19	157 ± 22
BP, diastolic (mmHg)	86 ± 5	88 ± 9.7	90 ± 12
No. of antihypertensive medications	1.8 ± 1.1	2 ± 1.2	1.9 ± 1.1
Creatinine clearance (ml/min)	38 ± 12	34 ± 15	32 ± 7
Loss of clearance (ml/min)	26 ± 10	39 ± 19	49 ± 23*
Proteinuria (g/24 h)	1.3 ± 1.5	1.9 ± 1.9	4.0 ± 3.3
CsA trough level (µg/ml)	114 ± 30	113 ± 31	

Values are mean ± SEM. CsA – cyclosporine A; CAN – chronic allograft nephropathy; CR – chronic rejection. * P < 0.05, compared with chronic CsA toxicity and CAN groups.

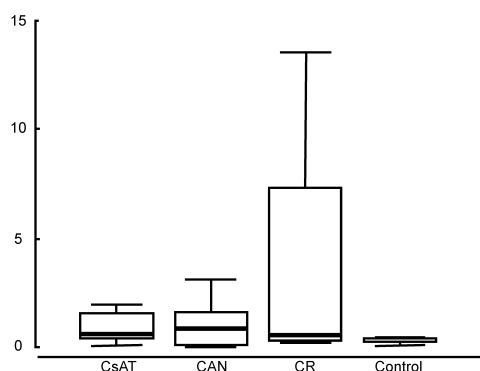


Figure 4. Box and whisker plots of the median staining areas for the laminin $\beta 2$ chain. The boxes contain 50% of the values. The upper and lower borders indicate the 25th and 75th percentiles, respectively. The upper and lower whiskers indicate the highest and lowest values, respectively. The black lines in the boxes indicate the medians. No significant differences were observed among the groups (P values from the Mann-Whitney test: CsAT group versus CAN, CR, and control groups, 0.847, 0.925 and 0.056, respectively; CAN group versus CR and control groups, 0.868 and 0.172, respectively; CR group versus control group, 0.463).

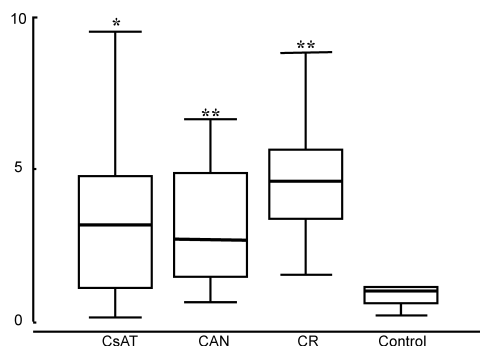


Figure 5. Box and whisker plots of the median staining areas for α -smooth muscle actin (SMA). *P < 0.05, **P < 0.01, compared with control group.

images of immunostaining for collagen I and III in an allografted kidney with CR.

Next we studied whether typical basement membrane collagen type IV expression was increased to the extent observed in native kidney disease (5). The mean areas of staining for collagen IV were significantly increased in all patient groups, compared with the control group, to the same degree (mean area \pm SEM for the CAN, CR, chronic CsAT, and control groups, 10.3 ± 5.1 , 13.3 ± 5.6 , 12.2 ± 1.4 , and $5.9 \pm 1.5\%$, respectively) (Figure 3A). We also compared the staining areas for the three types of collagen in the three groups of patients. In the CAN and CR groups, the areas staining for collagen III were greater than those staining for collagen IV (CAN group, $P < 0.001$; CR group, $P < 0.01$) but did not differ significantly from those staining for collagen I. In the CsAT group, the area staining for collagen III was greater than that staining for collagen I ($P < 0.001$), but no significant difference was observed in comparison with the area staining for collagen IV ($P = 0.07$).

When we studied biopsies with mild interstitial fibrosis (< 25% interstitial expansion), we observed a difference in collagen I staining between the CsAT group and the CR and CAN groups combined (CsAT group, $6.5 \pm 6\%$; CAN/CR group, $15.5 \pm 8.7\%$; $P < 0.05$). In this subgroup with mild fibrosis, there was no difference

in the time that had elapsed since transplantation (CAN/CR group) compared to the time that had elapsed since the Neoral switch (CsAT group). Collagen III and IV staining areas did not differ between the CsAT group and the CAN/CR subgroup. A meaningful comparison of biopsies with greater degrees of interstitial expansion was not possible because of the small numbers.

Because an earlier report suggested that immunostaining for the $\alpha 3$ chain of collagen IV and the $\beta 2$ chain of laminin could differentiate CR from chronic CsAT (13), we also evaluated these

Table 2. Light-microscopic features of the allograft biopsies studied

Histological Feature	Patient Group		
	CSA Toxicity (n = 17)	CAN (n = 19)	CR (n = 12)
Interstitial fibrosis score	0.58 ± 0.21	1.76 ± 0.19†	1.65 ± 0.25*
Tubular atrophy score	0.69 ± 0.24	1.36 ± 0.22	1.29 ± 0.29
Arterial intimal thickening score	0.77 ± 0.21	1.48 ± 0.19	1.40 ± 0.25
Allograft glomerulopathy score	0.02 ± 0.17	0.25 ± 0.15	0.33 ± 0.19
Peripheral arteriolar hyalinosis score	1.92 ± 0.12‡	0 ± 0.11	0 ± 0.15
Global glomerulosclerosis (%)	28.0 ± 7.1	32.5 ± 6.4	24.4 ± 8.4

Values are mean ± SEM; Scored according to the Banff 97 classification system; * P < 0.05, compared with chronic CsA toxicity group; † P < 0.01, compared with chronic CsA toxicity group; ‡ P < 0.01, compared with CAN or CR group

molecules. The areas stained for the collagen IV α 3 chain were increased in all patient groups, compared with the control group, to the same extent (mean area ± SEM for the CAN, CR, chronic CsAT, and control groups, 6.7 ± 1.1, 5.3 ± 1.2, 7.8 ± 0.8, and 1.1 ± 0.3%, respectively) (Figure 3B). The collagen IV α 3 chain was expressed in a normal pattern, namely, at the distal tubular basement membrane (TBM), in all three patient groups. No interstitial staining or new expression at the proximal TBM was noted. In none of the groups did the areas staining for the laminin β 2 chain change significantly, compared with the control group (Figure 4). However, we occasionally observed some new abnormal tubular expression in each of the groups (CsAT group, nine biopsy samples, 53%; CAN group, eight samples, 42%; CR group, six samples, 50%). The new expression was mostly confined to atrophic tubules or tubules surrounded by infiltrate, the proximal or distal morphologic features of which were difficult to assess. Less than 1% of tubules were affected in these samples, except for one sample in the CsAT group, three samples in the CAN group, and two samples in the CR group, in which 1 to 10% of tubules exhibited staining. No interstitial staining for the laminin β 2 chain was observed, except for faint staining in some areas of periglomerular fibrosis.

We investigated whether the observed qualitative and quantitative differences in the interstitial ECM composition in kidneys with CR or chronic CsAT were correlated with the numbers of interstitial myofibroblasts present, as assessed with immunohistologic staining for α -smooth muscle actin (SMA). Increases in SMA staining were observed for all patient groups, compared with the control group, but no differences were observed among the patient groups (Figure 5).

Correlations and Receiver-Operating Characteristic Curve Analysis

Among the three groups of patients, we observed no correlation between the areas of staining for the various molecules and the clinical variables of loss of allograft function, time after transplantation, allograft age, creatinine clearance, and proteinuria at the time of biopsy. A positive correlation ($r = 0.379$, $P = 0.008$) was observed between the interstitial fibrosis scores of all biopsy samples combined and the loss of creatinine clearance at the time of biopsy. The interstitial



fibrosis scores of all biopsy samples combined were also correlated with the areas of staining for collagen I and III ($r = 0.499$, $P = 0.001$, and $r = 0.499$, $P = 0.002$, respectively). A general linear model was used to adjust for differences in loss of function and creatinine clearance at the time of biopsy among the groups.

Receiver-operating characteristic curve analysis demonstrated that collagen I staining had the best discriminatory value in differentiating CR from chronic CsAT, with a sensitivity of 75% and a specificity of 88% at a cutoff value of 13% cortical interstitial staining and with values of 63% and 94%, respectively, at a cutoff value of 19% staining. The fraction of the area under the curve was 0.92 of the total area ($P = 0.001$). None of the ratios of the mean staining areas for the studied molecules proved to be useful for discrimination of CR from chronic CsAT.

Discussion

The aim of this study was to examine the composition of the cortical interstitial ECM of kidney allografts with either CR or chronic CsAT. We wondered whether quantitative and/or qualitative differences in ECM accumulation occur. Therefore, we quantitatively compared the deposition of several ECM molecules. We chose to study the molecules collagen I, III, and IV, because they are known to accumulate in the renal cortical interstitium during native kidney disease (5,14). The laminin $\beta 2$ and collagen IV $\alpha 3$ chains were investigated because an earlier report suggested that de novo expression of these molecules at the proximal TBM could differentiate CR from chronic CsAT (13).

In this study, we observed quantitative and qualitative differences in the ECM composition of kidney allografts with CR or chronic CsAT. Our results demonstrated that collagen I, III, and IV accumulated in the renal cortical interstitium during CR. The most prominent increases were observed for collagen I and III. A similar pattern of ECM deposition was observed in the kidneys of patients who likely had CR but were receiving CsA. In the kidneys of patients with chronic CsAT, however, only collagen III and IV accumulated significantly.

Regulation of the renal interstitial ECM composition in vivo is complex and encompasses changes in ECM biosynthesis and degradation. In normal kidneys, collagen I and III are observed in the blood vessels and the interstitium, albeit in small amounts (Figure 2) (15). Collagen IV is a natural component of the glomerular basement membrane and TBM, and its $\alpha 3$ chain is normally observed in the basement membranes of glomeruli and distal tubules (15). Laminin is observed in

vessel walls and all basement membranes. The $\beta 2$ chain, however, is observed only in glomeruli and vessel walls (16).

Quantitative data on the ECM composition of the cortical interstitium of human allografts with chronic CsAT or CR were lacking. A few studies reported increases in collagen III levels in grafts with chronic dysfunction but did not compare changes induced by CR and chronic CsAT (17,18). A number of *in vitro* studies have addressed the effects of CsA on the production of ECM molecules by renal cells. One study reported that CsA stimulated the production of pro-collagen I and IV in cultures of murine proximal tubular epithelial cells and the production of pro-collagen I in cultures of murine renal fibroblasts (19). Increases in the cortical expression of collagen I and IV were observed *in vivo* in a rat model of CsAT (20). The deposition of collagen III was not assessed in that model, however. Other data on collagen production were derived from a study on cultured human cells, which demonstrated an increase in collagen III production by renal fibroblasts when they were treated with CsA (21). Studies performed with a monkey renal fibroblast cell line (CV1) demonstrated that CsA stimulated the synthesis of type III collagen by a pathway leading to activation of the COL3A1 promoter and upregulation of COL3A1 mRNA (22). We observed the increased deposition of collagen III and IV in the interstitium of the cortex of human renal allografts as a result of chronic CsAT. In contrast to the results of the study performed in rats, we observed no significant increase in collagen I deposition. Although we did not observe a correlation between the time elapsed since the Neoral switch and the degree of collagen I deposition, we cannot exclude the possibility that, with time, collagen I would also accumulate during long-term chronic CsAT. The difference in collagen I staining between the CsAT and CAN/CR subgroups with mild fibrosis suggests that CR may stimulate collagen I accumulation earlier than does CsAT. In our study, we observed greater expansion of the interstitial space in the CR group, compared with the chronic CsAT group, as well as more deposition of collagen type III. The difference in interstitial fibrosis could not be explained on the basis of differences in clinical variables, because no correlations with those variables were observed.

We wondered whether the differences in ECM deposition between CR and chronic CsAT could be explained on the basis of a difference in the numbers of myofibroblasts present. SMA is a marker of activated myofibroblasts, which are thought to play a major role in the deposition of scar tissue (23). Two earlier reports described increases in interstitial SMA staining in deteriorating human kidney allografts (17,18). In CR, SMA-positive cell numbers were reported to increase with increases in the interstitial area fraction and collagen III deposition (18). In our study, we did not observe differences in SMA staining among the CR, CAN, and chronic CsAT groups; all samples contained more SMA-positive cells than normal. To explain the greater degree of interstitial ECM deposition during CR, compared with chronic CsAT, a higher rate of collagen production by myofibroblasts or a lower rate of ECM degradation by tissue metalloproteinases could be



hypothesized. Data derived from a primate model of chronic cardiac rejection support the latter hypothesis, because it was demonstrated that the progression of myocardial fibrosis was associated with increased expression of tissue inhibitor of metalloproteinases 1 and 2 (24).

We also examined the $\alpha 3$ chain of collagen IV and the $\beta 2$ chain of laminin. Our results are at variance with a report by Abrass et al (13), which suggested that a pattern of new expression of those molecules at the proximal TBM was specific for CR. In that study, CsAT resulted in the interstitial deposition of collagen I and III. Our study differs in the definitions of cases, the antibodies used, and the mode of analysis. The study by Abrass et al (13) examined patterns of distribution and provided no quantitative data on the investigated molecules. According to Abrass et al (13), collagen I and III are not normally observed in the cortical interstitial area and the collagen IV $\alpha 3$ and laminin $\beta 2$ chains are not expressed at the TBM. However, we and others observed that collagen I and III are normally present in the renal interstitium, albeit in small amounts (5,15,25-27). We also observed that the collagen IV $\alpha 3$ chain is normally expressed at the distal TBM, as noted earlier (16,28). This discrepancy may be related to the different antibodies used. In the study by Abrass et al (13), allografted kidneys with rejection exhibited acute rejection; although the authors stated that their results also applied to allografts with CR, they did not systematically examine that idea and no data were presented. The new expression of the collagen IV $\alpha 3$ and laminin $\beta 2$ chains at the proximal TBM observed by Abrass et al (13) might thus very well be related to tubulitis during acute rejection. In our study, we observed sporadic new expression of laminin $\beta 2$ at the TBM in a portion of the biopsy samples in each study group, especially in areas of tubular damage. Staining for this molecule did not differentiate CR from chronic CsAT. We observed increased expression of the collagen IV $\alpha 3$ chain in the CR, CAN, and chronic CsAT groups but no abnormal distribution pattern. We observed a small nonsignificant increase in collagen I staining for the chronic CsAT group, compared with normal control values. It is possible that a small increase in collagen I expression by the patients with chronic CsAT, which was below our detection limit, could have resulted in the expression pattern observed in the study by Abrass et al (13).

In conclusion, we observed a more pronounced fibrotic response in the tubulointerstitium, involving collagen I and III, in allografts with CR, compared with those with chronic CsAT. Early increases in the cortical interstitial deposition of collagen I were more specific for CR. Staining for the collagen IV $\alpha 3$ and laminin $\beta 2$ chains was not useful for the differentiation of CR from chronic CsAT.

References

1. Hariharan S, Johnson CP, Bresnahan BA, Taranto SE, McIntosh MJ, Stablein D: Improved graft survival after renal transplantation in the United States, 1988 to 1996. *N Engl J Med* 342:605-612, 2000
2. Paul LC: Chronic allograft nephropathy: An update. *Kidney Int* 56:783-793, 1999

3. Jindal RM, Hariharan S: Chronic rejection in kidney transplants. An in-depth review. *Nephron* 83:13-24, 1999
4. Andoh TF, Bennett WM: Chronic cyclosporine nephrotoxicity. *Curr Opin Nephrol Hypertens* 7:265-270, 1998
5. Vleming LJ, Baelde JJ, Westendorp RG, Daha MR, van Es LA, Bruijn JA: Progression of chronic renal disease in humans is associated with the deposition of basement membrane components and decorin in the interstitial extracellular matrix. *Clin Nephrol* 44:211-219, 1995
6. Sijkens YW, Mallat MJ, Siegert CE, Zwinderman AH, Westendorp RG, De Fijter JW, van Es LA, Paul LC: Risk factors of cyclosporine nephrotoxicity after conversion from Sandimmune to Neoral. *Clin Nephrol* 55:149-155, 2001
7. Sijkens YW, Zwinderman AH, Mallat MJ, Boom H, De Fijter JW, Paul LC: Intercept and slope analysis of risk factors in chronic renal allograft nephropathy. *Graft* 5:109-114, 2002
8. Racusen LC, Solez K, Colvin RB, Bonsib SM, Castro MC, Cavallo T, Croker BP, Demetris AJ, Drachenberg CB, Fogo AB, Furness P, Gaber LW, Gibson IW, Glotz D, Goldberg JC, Grande J, Halloran PF, Hansen HE, Hartley B, Hayry PJ, Hill CM, Hoffman EO, Hunsicker LG, Lindblad AS, Yamaguchi Y, .: The Banff 97 working classification of renal allograft pathology. *Kidney Int* 55:713-723, 1999
9. Regele H, Exner M, Watschinger B, Wenter C, Wahrmann M, Osterreicher C, Saemann MD, Mersich N, Horl WH, Zlabinger GJ, Bohmig GA: Endothelial C4d deposition is associated with inferior kidney allograft outcome independently of cellular rejection. *Nephrol Dial Transplant* 16:2058-2066, 2001
10. Regele H, Bohmig GA, Habicht A, Gollowitzer D, Schillinger M, Rockenschaub S, Watschinger B, Kerjaschki D, Exner M: Capillary Deposition of Complement Split Product C4d in Renal Allografts is Associated with Basement Membrane Injury in Peritubular and Glomerular Capillaries: A Contribution of Humoral Immunity to Chronic Allograft Rejection. *J Am Soc Nephrol* 13:2371-2380, 2002
11. Nicholson ML, Bailey E, Williams S, Harris KP, Furness PN: Computerized histomorphometric assessment of protocol renal transplant biopsy specimens for surrogate markers of chronic rejection. *Transplantation* 68:236-241, 1999
12. de Heer E, Sijkens YWJ, Verkade M, den Dulk M, Langers A, Schutrups J, Bruijn JA, van Es LA: Morphometry of interstitial fibrosis. *Nephrol Dial Transplant* 15:72-73, 2000
13. Abrass CK, Berfield AK, Stehman-Breen C, Alpers CE, Davis CL: Unique changes in interstitial extracellular matrix composition are associated with rejection and cyclosporine toxicity in human renal allograft biopsies. *Am J Kidney Dis* 33:11-20, 1999
14. Glick AD, Jacobson HR, Haralson MA: Mesangial deposition of type I collagen in human glomerulosclerosis. *Hum Pathol* 23:1373-1379, 1992
15. Costigan M, Chambers DA, Boot-Handford RP: Collagen turnover in renal disease. *Exp Nephrol* 3:114-121, 1995
16. Miner JH: Renal basement membrane components. *Kidney Int* 56:2016-2024, 1999
17. Ko YJ, Sugar L, Zaltzman J, Paul LC: alpha-smooth muscle actin and collagen deposition in dysfunctional renal transplants. *Transplantation* 63:156-158, 1997
18. Pedagogos E, Hewitson TD, Walker RG, Nicholis KM, Becker GJ: Myofibroblast involvement in chronic transplant rejection. *Transplantation* 64:1192-1197, 1997
19. Wolf G, Killen PD, Neilson EG: Cyclosporin A stimulates transcription and procollagen secretion in tubulointerstitial fibroblasts and proximal tubular cells. *J Am Soc Nephrol* 1:918-922, 1990
20. Young BA, Burdmann EA, Johnson RJ, Alpers CE, Giachelli CM, Eng E, Andoh T, Bennett WM, Couser WG: Cellular proliferation and macrophage influx precede interstitial fibrosis in cyclosporine nephrotoxicity. *Kidney Int* 48:439-448, 1995
21. Ghiggeri GM, Altieri P, Oleggini R, Valenti F, Ginevri F, Perfumo F, Gusmano R: Cyclosporine enhances the synthesis of selected extracellular matrix proteins by renal cells "in culture". Different cell responses and phenotype characterization. *Transplantation* 57:1382-1388, 1994
22. Oleggini R, Musante L, Menoni S, Botti G, Duca MD, Prudenziati M, Carrea A, Ravazzolo R, Ghiggeri GM: Characterization of a DNA binding site that mediates the stimulatory effect of cyclosporin-A on type III collagen expression in renal cells. *Nephrol Dial Transplant* 15:778-785, 2000
23. Badid C, Vincent M, Fouque D, Laville M, Desmouliere A: Myofibroblast: a prognostic marker and target cell in progressive renal disease. *Ren Fail* 23:543-549, 2001
24. Suzuki J, Isobe M, Kawauchi M, Endoh M, Amano J, Takamoto S: Altered expression of matrix metalloproteinases and tissue inhibitors of metalloproteinases in acutely rejected myocardium and coronary arteriosclerosis in cardiac allografts of nonhuman primates. *Transpl Int* 13:106-113, 2000
25. Black CM, Duance VC, Sims TJ, Light ND: An investigation of the biochemical and histological changes in the collagen of the kidney and skeletal muscle in systemic sclerosis. *Coll Relat Res* 3:231-243, 1983
26. Funabiki K, Horikoshi S, Tomino Y, Nagai Y, Koide H: Immunohistochemical analysis of extracellular components in the glomerular sclerosis of patients with glomerulonephritis. *Clin Nephrol* 34:239-246, 1990
27. Yoshioka K, Kohda M, Takemura T, Akano N, Matsubara K, Ooshima A, Maki S: Distribution of type I collagen in human kidney diseases in comparison with type III collagen. *J Pathol* 162:141-148, 1990
28. Butkowski RJ, Wieslander J, Kleppel M, Michael AF, Fish AJ: Basement membrane collagen in the kidney: regional localization of novel chains related to collagen IV. *Kidney Int* 35:1195-1202, 1989