



Universiteit  
Leiden  
The Netherlands

## Clinicopathologic and genetic features of primary cutaneous B-cell lymphoma

Hoefnagel, J.J.

### Citation

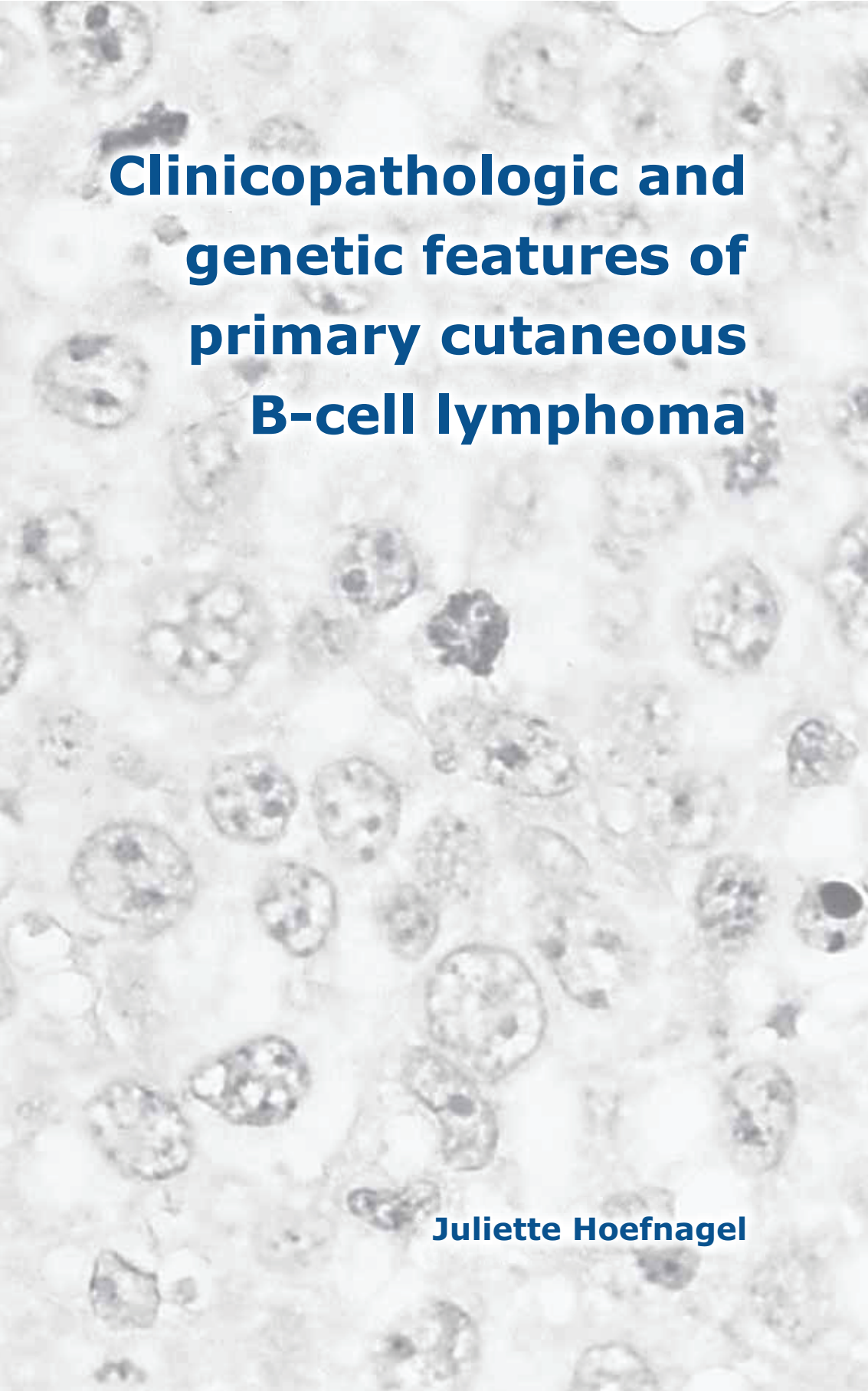
Hoefnagel, J. J. (2007, January 11). *Clinicopathologic and genetic features of primary cutaneous B-cell lymphoma*. Retrieved from <https://hdl.handle.net/1887/8769>

Version: Corrected Publisher's Version

License: [Licence agreement concerning inclusion of doctoral thesis in the Institutional Repository of the University of Leiden](#)

Downloaded from: <https://hdl.handle.net/1887/8769>

**Note:** To cite this publication please use the final published version (if applicable).

A microscopic image showing numerous large, atypical lymphoid cells with prominent nuclei and some nucleoli, characteristic of B-cell lymphoma. The cells are densely packed and show varying degrees of nuclear enlargement and irregularity. A solid blue vertical bar is positioned on the left side of the slide.

# **Clinicopathologic and genetic features of primary cutaneous B-cell lymphoma**

**Juliette Hoefnagel**