



Universiteit  
Leiden  
The Netherlands

## Novel cardiac imaging technologies : implications in clinical decision making

Delgado, V.

### Citation

Delgado, V. (2010, November 11). *Novel cardiac imaging technologies : implications in clinical decision making*. Retrieved from <https://hdl.handle.net/1887/16139>

Version: Corrected Publisher's Version

License: [Licence agreement concerning inclusion of doctoral thesis in the Institutional Repository of the University of Leiden](#)

Downloaded from: <https://hdl.handle.net/1887/16139>

**Note:** To cite this publication please use the final published version (if applicable).

# Chapter 8

## **The role of speckle tracking strain imaging in cardiac pacing**

Laurens F. Tops, MD, Victoria Delgado, MD, Jeroen J. Bax, MD, PhD

*Echocardiography. 2009;26:315-23*

## ABSTRACT

In recent years, concerns have been raised about possible harmful effects of long-term right ventricular (RV) apical pacing. These detrimental effects may be related to changes in left ventricular (LV) mechanics during RV apical pacing. As a consequence, alternative RV pacing sites have been proposed, and in selected patients an upgrade from RV to biventricular pacing may be considered. Novel two-dimensional speckle tracking strain imaging allows detailed evaluation of LV mechanics, including LV mechanical dyssynchrony, LV strain and LV torsion. In this review, the role of speckle tracking strain imaging in the evaluation of LV function in patients with RV apical pacing will be reviewed. The effects of RV apical pacing on LV mechanical dyssynchrony, LV strain and LV torsion will be discussed. In addition, the role of speckle tracking strain imaging in the selection of the optimal (alternative) RV pacing site and in the selection of patients who may benefit from an upgrade from RV apical pacing to biventricular pacing will be reviewed.

## INTRODUCTION

Cardiac pacing is the only effective treatment in patients with symptomatic sinus node dysfunction or atrioventricular block.<sup>1,2</sup> In general, the pacing lead is routinely positioned at the right ventricular (RV) apex. However, concerns have been raised about possible harmful effects of long-term RV apical pacing.<sup>3</sup> These detrimental effects may be related to the abnormal activation pattern of the left ventricle (LV) during RV apical pacing.<sup>4</sup> This abnormal activation pattern may result in changes in overall LV mechanics<sup>5</sup> and significant delays in electro-mechanical activation among the different LV segments (ventricular dyssynchrony).<sup>6</sup>

In recent years, tissue Doppler imaging (TDI) has emerged as an important means of evaluating ventricular mechanics and dyssynchrony. However, the insonation angle largely determines the ability to assess myocardial velocities and strain using TDI.<sup>7</sup> Recently, a new echocardiographic technique has been introduced: two-dimensional (2D) speckle tracking strain imaging allows angle-independent and multidirectional assessment of LV mechanics and function.<sup>8,9</sup> Using this technique, various important aspects can be assessed:

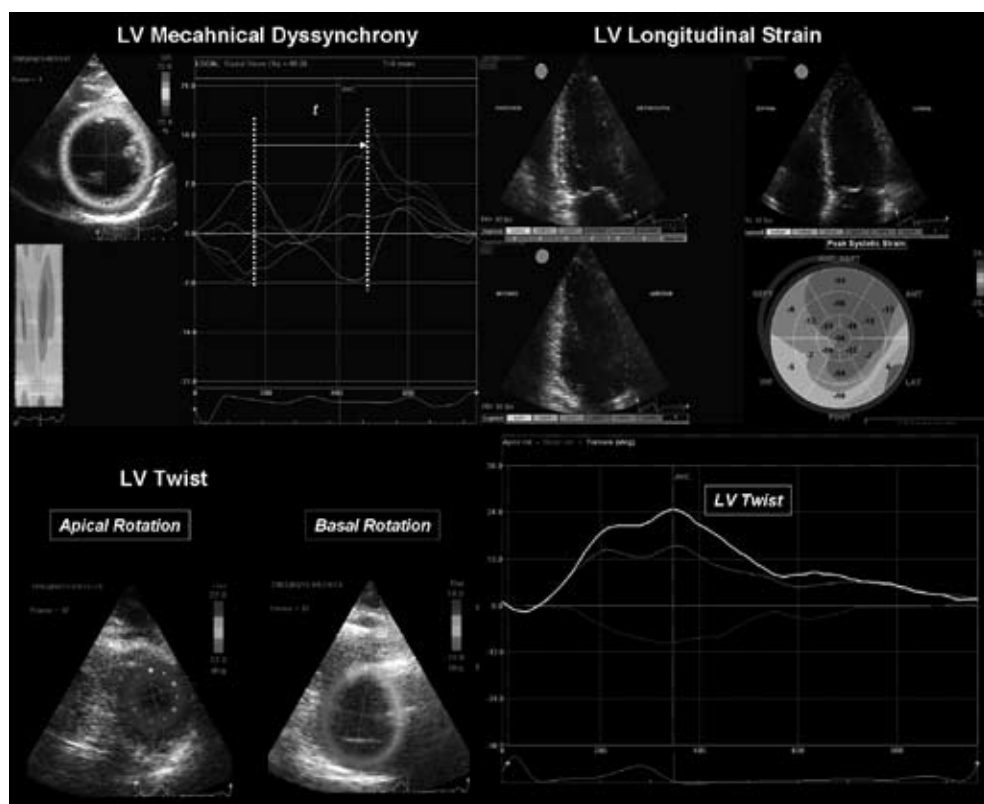
- LV mechanical dyssynchrony: calculated by measuring differences in the timing of peak systolic strain of various LV segments.
- LV strain: representing LV systolic function; may detect more subtle regional changes as compared to conventional measurements of LV systolic function.
- LV torsion: calculated by the differences in rotation of the apical and basal LV segments, as a result of the helical disposition of the myocardial fibers.

The various aspects of LV mechanics and function, as assessed with 2D speckle tracking strain imaging are shown in Figure 1.

This review will focus on the use of 2D speckle tracking strain imaging in cardiac pacing. The role of speckle tracking imaging in the assessment of the effects of RV apical pacing on LV function will be discussed. In addition, the effects of alternative RV pacing sites and upgrade from RV to biventricular pacing, assessed with 2D speckle tracking strain imaging, will be reviewed.

## RIGHT VENTRICULAR APICAL PACING

Several large, randomized clinical trials on pacing mode selection (dual-chamber vs. single chamber pacing) have demonstrated an association between RV apical pacing and an increased risk for heart failure and death. In a substudy of the MDe Selection Trial (MOST) trial, a strong association between RV apical pacing and the risk of heart failure hospitalization and atrial fibrillation was noted.<sup>10</sup> This substudy comprised 1339 patients with sinus node dysfunction who were randomized between single chamber ventricular rate modulated pacing (n=632) and dual chamber rate modulated pacing (n=707). Importantly, in both pacing mode groups, a higher cumulative percentage of pacing was associated with an increased risk of heart failure hospitalization (DDDR group hazard ratio 2.60; 95%



**Figure 1. Clinical applications of speckle tracking imaging**

Several parameters of the LV mechanics can be evaluated by 2D speckle tracking strain imaging: LV mechanical dyssynchrony, LV strain and LV torsion. Left ventricular mechanical dyssynchrony (upper left panel) is calculated by measuring the absolute difference (indicated by 't') in the timing of peak systolic radial strain of 6 standard LV segments. Left ventricular longitudinal strain (upper right panel) is assessed from the 3 standard apical views. The mean value is calculated by averaging of the peak strain values of 17 standard segments, as indicated in the bull's eye plot. Left ventricular torsion (lower panel) is assessed by calculating the differences in rotation of the apical and basal LV segments. When seen from the apex, the basal rotation is clockwise (represented by the purple curve) and the apical rotation is counter-clockwise (represented by the green curve). The net difference between these two rotational movements is LV torsion (indicated by the white curve).

CI 1.05 - 6.47;  $p < 0.05$ ; VVIR group hazard ratio 2.50; 95% CI 1.44 - 4.36;  $p < 0.05$ ). From this substudy, it was concluded that RV apical pacing increases the risk of heart failure, even when atrioventricular synchrony is preserved using physiologic DDDR pacing.<sup>10</sup>

Similarly, the Dual Chamber and VVI Implantable Defibrillator (DAVID) trial demonstrated the negative effects of RV apical pacing in patients with a standard indication for a defibrillator implantation, but without an indication for anti-bradycardia pacing.<sup>11</sup> These patients were randomized between 'physiologic pacing' (DDDR mode, lower rate of 70 bpm) or ventricular back-up pacing (VVIR mode, lower rate of 40 bpm). Interrogation of the defibrillator device revealed a significantly higher percentage of ventricular paced beats in the DDDR-70 group ( $57.9 \pm 35.8\%$  vs.  $1.5 \pm 8.0\%$ ,  $p < 0.001$ ). Importantly, at long-term follow-up, the combined primary end-point of freedom from death and

absence of hospitalization for new or worsened heart failure, was lower in the VVIR-40 group than in the DDDR-70 group (relative hazard 1.61; 95% CI 1.06 – 2.44;  $p=0.03$ ). A trend towards a worse survival at 12 months was noted in patients with a high percentage of pacing at 3 months follow-up.<sup>11</sup>

From these trials it has become apparent that a high percentage of ventricular paced beats (even when atrioventricular synchrony is maintained by dual-chamber pacing) is associated with a worse prognosis. This has been ascribed to the abnormal activation pattern of the ventricles during RV apical pacing. During RV apical pacing, the electrical impulse spreads through the slower-conducting myocardium instead of the His-Purkinje system, resulting in a dyssynchronous ventricular contraction and an impairment of LV performance.<sup>12</sup> This may result in significant changes in cardiac metabolism<sup>13</sup> and perfusion.<sup>14</sup> In addition, remodeling of the cardiac chambers may occur,<sup>15</sup> together with changes in hemodynamics and mechanical function.<sup>16</sup> Importantly, it has been demonstrated that the presence of significant LV dyssynchrony is correlated with a worse outcome in both heart failure patients<sup>17</sup> and in patients with permanent RV apical pacing.<sup>6</sup> It is therefore of critical importance to assess LV mechanics and dyssynchrony in patients with RV apical pacing.

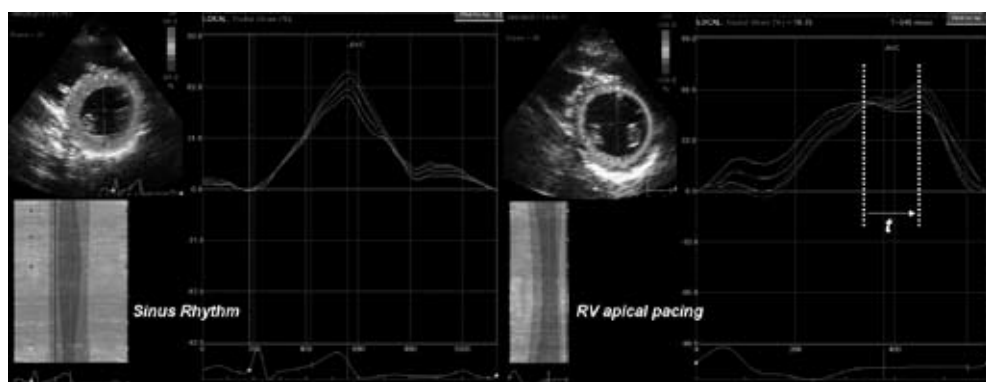
### **Evaluation of LV function during RV apical pacing with 2D speckle tracking strain**

Several dedicated echocardiographic techniques, such as TDI and real-time three-dimensional echocardiography, are available for the assessment of the effects of RV apical pacing on LV function and dyssynchrony.<sup>6,18</sup> The multi-directional evaluation of LV active contraction enabled by novel 2D speckle tracking strain imaging overcomes the limitations of the TDI techniques, highly dependent on the insonation angle.<sup>19</sup> More important, in contrast to myocardial velocity imaging, 2D speckle tracking strain imaging is not affected by the tethering effects from the contiguous myocardial regions or by translational artifacts, becoming a more robust imaging tool to evaluate time differences in myocardial contraction.<sup>19</sup> The various aspects of LV mechanics and function during RV apical pacing, assessed with 2D speckle tracking strain imaging (Figure 1) will be discussed in the following paragraphs.

#### ***Left ventricular mechanical dyssynchrony***

The ventricular activation pattern during RV apical pacing is similar to that during left bundle branch block.<sup>4</sup> It is characterized by early activation of the segments near the pacing site, and delayed activation through the myocardium of the remote sites.<sup>20</sup> This discrepancy in electro-mechanical activation within the LV may result in significant LV dyssynchrony.<sup>21</sup> Importantly, it has been demonstrated that the presence of significant LV dyssynchrony during RV apical pacing is associated with a deterioration of functional capacity and LV systolic function.<sup>22</sup>

Speckle tracking strain imaging enables assessment of the timing of mechanical events within the LV (Figure 2). By calculating the difference in timings of the various LV segments, LV dyssynchrony can be assessed.<sup>23,24</sup> Different strategies and cut-off values for the definition of LV dyssynchrony have been proposed using the absolute difference in time-to-peak radial strain of 2 segments,<sup>23</sup> or the standard deviation of time-to-peak longitudinal strain of 12 segments.<sup>24</sup>



**Figure 2. Assessment of LV mechanical dyssynchrony using 2D speckle tracking radial strain imaging**

The panel on the left illustrates a synchronous LV contraction during sinus rhythm. The radial strain-time curves show similar time-to-peak strain values for all the segments. However, during RV apical pacing (panel on the right) the LV contraction becomes dyssynchronous: the electromechanical delay or dyssynchrony is indicated by 't'. The antero-septal segments (yellow and red curves) are the earliest activated sites, whereas the posterolateral segments (green and purple curves) are the latest activated sites.

The presence of LV dyssynchrony during RV apical pacing has been demonstrated with 2D speckle tracking strain imaging in both preclinical<sup>25</sup> and clinical<sup>22</sup> studies. In a canine model of dyssynchrony and heart failure, Arita et al used 2D speckle tracking strain imaging to study the effects of RV apical pacing on LV function.<sup>25</sup> After His bundle ablation, RV apical pacing was performed for 4 weeks at either 110 bpm (no heart failure, n=12) or 170 bpm (heart failure, n=9). Left ventricular dyssynchrony was assessed by calculating the standard deviation of time-to-peak radial strain of 6 mid-ventricular segments. A significant increase in LV dyssynchrony was noted from baseline to follow-up in dogs without heart failure (from  $16.6 \pm 12.0$  ms to  $53.1 \pm 32.2$  ms,  $p < 0.05$ ). Interestingly, the increase in LV dyssynchrony was even more pronounced in dogs with heart failure (from  $27.3 \pm 16.5$  ms to  $137.5 \pm 39.7$  ms,  $p < 0.05$ ). Finally, the extent of LV dyssynchrony strongly correlated with LV ejection fraction ( $r = -0.657$ ,  $p < 0.001$ ).<sup>25</sup>

In addition, the development of LV mechanical dyssynchrony has been demonstrated after long-term RV apical pacing in patients after His bundle ablation for drug-refractory atrial fibrillation.<sup>22</sup> With the use of 2D speckle tracking strain, the absolute difference in time-to-peak radial strain between the (antero)septal and the posterolateral wall was calculated. Left ventricular dyssynchrony was defined as a time difference  $\geq 130$  ms. Importantly, after a mean follow-up of  $3.8 \pm 2.0$  years, significant LV dyssynchrony was present in 57% of the patients. These studies demonstrate that 2D speckle tracking strain may be of great value for detecting LV dyssynchrony during RV apical pacing.

### **Left ventricular strain**

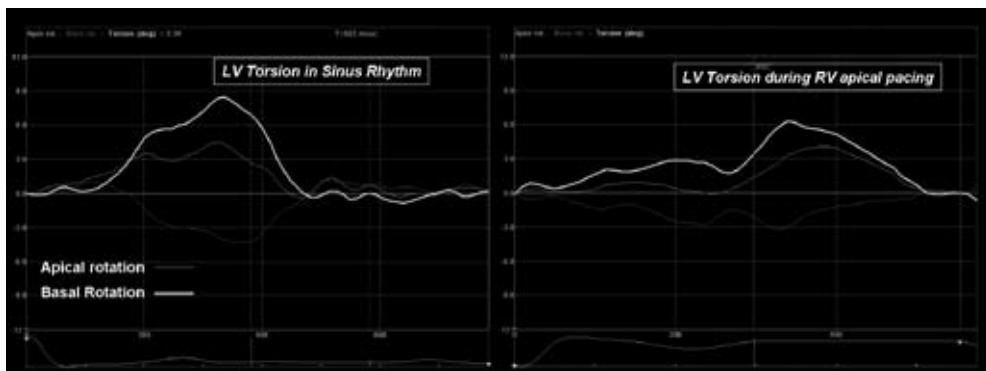
In addition to changes in timing of systolic strain, the absolute strain values may be affected by RV pacing as well. In an animal model of RV pacing, Prinzen et al using magnetic resonance imaging to study changes in regional strain between right atrial pacing (normal LV activation) and RV apical

pacing.<sup>20</sup> During RV apical pacing, a decrease in longitudinal strain was observed in the regions close to the pacing site (from  $-0.119 \pm 0.007$  to  $-0.002 \pm 0.078$ ), whereas it increased in remote regions (from  $-0.086 \pm 0.045$  to  $-0.100 \pm 0.049$ ).<sup>20</sup>

At present, no clinical studies are available that have assessed the effects of RV apical pacing on global LV longitudinal strain with 2D speckle tracking strain imaging. Using speckle tracking analysis, it has been suggested that radial strain is diminished in the (antero)septal regions and increased in the posterolateral regions during long-term RV apical pacing.<sup>22</sup> More studies are needed to fully understand the effect of RV apical pacing on LV longitudinal strain as assessed with 2D speckle tracking strain imaging.

### **Left ventricular torsion**

Left ventricular torsion results from the multidirectional deformation of the LV muscle and its measurement summarizes several mechanical aspects. The LV consists of a muscle band that shows a double-helical structure that shortens in the longitudinal and circumferential directions and thickens in the radial direction. As a result, the LV apex rotates opposite relative to the LV base, determining the typical torsional movement of the LV.<sup>26</sup> Several physiological situations, such as changes in preload, afterload or contractility, may influence the extent of LV torsion.<sup>27</sup> Similarly, changes in LV torsion during abnormal electrical activation of the LV by RV apical pacing can be also expected (Figure 3).



**Figure 3. Changes in LV torsion during RV apical pacing**

Left ventricular torsion (white curve) is the difference between the apical rotation (purple curve) and the basal rotation (green curve). The panel on the left shows the rotation-time curves during sinus rhythm. During RV apical pacing (right panel), a decrease in LV apical and basal rotation is noted and, subsequently, LV torsion decreases.

Indeed, the effects of RV apical pacing on LV torsion have been studied with the use of 2D speckle tracking strain imaging. Matsuoka et al. evaluated 30 patients after pacemaker implantation for sick sinus syndrome.<sup>28</sup> Significant changes in LV torsion were observed between intrinsic rhythm and RV apical pacing. After initiation of RV apical pacing, peak basal rotation decreased from  $-5.3 \pm 4.6^\circ$  to



$-3.2 \pm 3.4^\circ$  ( $p=0.003$ ) and peak apical rotation decreased from  $12.3 \pm 7.0^\circ$  to  $8.4 \pm 5.4^\circ$  ( $p=0.007$ ). As a result, LV torsion decreased significantly from  $16.5 \pm 9.2^\circ$  to  $10.3 \pm 6.3^\circ$  ( $p<0.001$ ).<sup>28</sup> Importantly, this decrease in LV torsion may result in less efficient LV filling and emptying, and contribute to LV systolic and diastolic dysfunction during RV apical pacing.<sup>29</sup>

## ALTERNATIVES FOR RIGHT VENTRICULAR APICAL PACING

With the increasing evidence that RV apical pacing should be kept to a minimum, alternative locations for positioning pacemaker leads have been explored (30). Various other pacing sites within the RV have been studied, and the possibility of ‘upgrading’ from RV to biventricular pacing in patients with conventional indications for cardiac pacing has been investigated. In the following paragraphs, the role of 2D speckle tracking strain imaging in alternative pacing sites will be reviewed.

### Alternative right ventricular pacing sites

Potential sites for RV pacing other than the RV apex, include the RV outflow tract and the interventricular septum, or direct pacing of the His bundle.<sup>30</sup> The rationale of these pacing sites is the more physiologic electrical activation of the ventricles, by pacing close to the His-Purkinje system. The RV outflow tract is the most extensively studied alternate site for RV pacing.<sup>31</sup> The RV outflow tract offers a good alternative for RV apical pacing, due to the stability of the current active fixation leads and the good long-term pace/sense thresholds. Several studies have demonstrated improvements in clinical status, hemodynamics and LV function during RV outflow tract pacing, as compared to RV apical pacing.<sup>32-34</sup> However, the majority of these studies involve acute, non-randomized studies. Long-term studies and randomized trials are therefore needed to confirm these results. Nonetheless, the RV outflow tract is increasingly being used for positioning the RV pacing lead.<sup>30</sup>

Similarly, short-term studies have suggested superiority of septal pacing<sup>35</sup> or direct His bundle pacing<sup>36</sup> over conventional RV apical pacing. However, these results were not confirmed in other studies.<sup>37,38</sup> In addition, technical difficulties and concerns regarding lead positioning/stability and reliable long-term capture, or the need of a preserved bundle branch conduction system limit the clinical applicability of these specific pacing sites at present.<sup>30</sup>

Because of the variation in the results of the different alternative pacing sites, a consensus on the optimal position of the RV pacing lead has not been reached yet. Importantly, 2D speckle tracking strain imaging may provide important additional information for the selection of the optimal pacing site. Several studies have assessed the effects of the different RV pacing sites on LV mechanics and function.

### **Left ventricular mechanical dyssynchrony**

The differences in LV mechanical dyssynchrony for the different RV pacing sites have been studied using various echocardiographic techniques, including tissue Doppler imaging.<sup>39-41</sup> From these studies, it has become apparent that these alternative pacing sites may better preserve the normal activation pattern, and thus induce less LV mechanical dyssynchrony.

However, data on LV mechanical dyssynchrony for the various pacing sites, as assessed with 2D speckle tracking strain imaging, is scarce. In 48 patients with normal cardiac structure, Inoue et al. studied the effects of RV pacing on LV mechanical synchrony.<sup>42</sup> In 22 patients, RV outflow tract pacing was applied, whereas in the remaining 26 patients conventional RV apical pacing was performed. The standard deviation of time-to-peak systolic longitudinal strain of 18 segments was calculated as a measure of LV dyssynchrony. The extent of LV mechanical dyssynchrony induced by RV apical pacing was significantly higher compared to RVOT pacing ( $89 \pm 37$  ms vs.  $44 \pm 18$  ms;  $p < 0.01$ ). In addition, LV dyssynchrony was strongly correlated with LV ejection fraction ( $r=0.57$ ,  $p < 0.001$ ).<sup>42</sup> These data demonstrate the value of 2D speckle tracking strain imaging in the assessment of the various RV pacing sites, and suggest that RV outflow tract pacing may be preferred over RV apical pacing.

### **Left ventricular strain**

The effects of different RV pacing sites on LV function have been studied by evaluating the changes in LV ejection fraction, cardiac output and other hemodynamic parameters such as the  $dP/dt$  ratio.<sup>16,31,32</sup> However, the direct evaluation of LV myocardial deformation may be a more accurate approach to determine the real impact of RV pacing on LV function.

Indeed, several experimental and clinical studies have assessed the effect of different RV pacing sites LV longitudinal shortening by using sonomicrometry or TDI-derived strain.<sup>43,44</sup> Liakopoulos et al. compared the effects of different pacing sites on LV longitudinal shortening in a swine-model by using sonomicrometry.<sup>43</sup> During RV pacing, LV longitudinal shortening decreased significantly, in parallel with deterioration in several hemodynamic parameters. Importantly, RV apical pacing resulted in the most pronounced decrease (from  $14.5 \pm 1.8\%$  during sinus rhythm to  $9.0 \pm 2.1\%$ ,  $9.3 \pm 1.1\%$  and  $9.1 \pm 2.0\%$  during RV apical, RV outflow tract and LV pacing respectively;  $p < 0.05$  vs. sinus rhythm).<sup>43</sup> Ten Cate et al. evaluated the changes in LV longitudinal shortening during RV apical and RV outflow tract pacing in 14 patients with normal LV ejection fraction and preserved atrioventricular and intraventricular conduction.<sup>44</sup> By using TDI-derived strain imaging, the authors observed a significant impairment of LV longitudinal strain with both pacing modalities (from  $22.1 \pm 2.1\%$  in sinus rhythm to  $17.2 \pm 2.6\%$  with RV apical pacing and  $18 \pm 1.9\%$  with RV outflow tract pacing;  $p < 0.01$  vs. sinus rhythm).<sup>44</sup>

Two-dimensional speckle tracking strain imaging, validated against sonomicrometry and tagged-magnetic resonance imaging,<sup>8,9,19</sup> can provide reliable and accurate information about the changes in LV longitudinal shortening during RV pacing. However, data based on 2D speckle tracking strain imaging comparing the effects of different RV pacing sites on the LV mechanics is unfortunately still lacking.

### ***Left ventricular torsion***

As mentioned previously, LV torsion is the net difference between the apical rotation and the basal rotation along the longitudinal axis of the LV.<sup>26</sup> Data on the effects of different RV pacing sites on LV torsion are scarce.<sup>42,45</sup>

Two clinical studies have evaluated the changes in LV torsion during RV apical and RV outflow tract pacing. Inoue et al. studied the effects of long-term RV apical and RV outflow tract pacing on LV torsion, in addition to LV dyssynchrony.<sup>42</sup> In the 26 patients with RV apical pacing, LV torsion was significantly decreased as compared with RV outflow tract pacing ( $11 \pm 4^\circ$  vs.  $17 \pm 5^\circ$ ,  $p < 0.01$ ).<sup>42</sup> In addition, Yamano et al. evaluated the acute effects of different RV pacing sites on LV torsion in 20 patients who underwent an electrophysiological study.<sup>45</sup> The values for LV torsion during both pacing modes were compared with the values during baseline sinus rhythm. No significant changes in LV apical rotation were noted ( $4.9 \pm 3.1^\circ$  in sinus rhythm,  $5.2 \pm 2.1^\circ$  during RV apical pacing, and  $5.7 \pm 3.0^\circ$  during RVOT pacing). In contrast, LV basal rotation was affected in both pacing modes. However, a more pronounced decrease in LV basal rotation was observed during RV apical pacing, as compared with RV outflow tract pacing (from  $9.9 \pm 2.1^\circ$  in sinus rhythm to  $5.4 \pm 2.0^\circ$  during RV apical pacing, and  $7.7 \pm 3.0^\circ$  during RVOT pacing). From this study, it was concluded that RV outflow tract pacing may be preferred over RV apical pacing, with regard to the effects of pacing on LV torsion.<sup>45</sup>

### ***Upgrade from RV to biventricular pacing***

In addition to alternative pacing sites within the RV, it has been suggested that LV pacing sites, or combined RV and LV pacing sites (biventricular pacing) may provide a more physiologic activation pattern of the ventricles.<sup>5</sup> Importantly, a number of studies have demonstrated that patients receiving long-term RV apical pacing may benefit from an 'upgrade' of RV pacing to biventricular pacing.<sup>46-48</sup> These studies showed improvements in LV volumes and LV ejection fraction, exercise capacity, and quality of life after the upgrade to biventricular pacing. In addition, using tissue Doppler imaging, it has been demonstrated that the upgrade to biventricular pacing may result in an increase in LV strain and a decrease in LV mechanical dyssynchrony.<sup>49,50</sup>

With the use of 2D speckle tracking strain imaging, the effect of upgrading from RV apical pacing to biventricular pacing on LV function and mechanics (LV mechanical dyssynchrony, LV strain and LV torsion) can be assessed. However, at present, data on 2D speckle tracking strain imaging in this setting is limited. In 11 patients with long-term permanent RV apical pacing after His bundle ablation, an upgrade to biventricular pacing was performed.<sup>22</sup> Using 2D speckle tracking strain imaging, a more synchronous contraction of the different LV segments was noted after the upgrade procedure. Importantly, a concomitant improvement in LV systolic function and NYHA functional class was noted.<sup>22</sup> Unfortunately, no data on LV longitudinal strain and LV torsion after upgrade from RV to biventricular pacing is available yet.

## CONCLUSIONS

Two-dimensional speckle tracking strain imaging enables detailed evaluation of LV function during cardiac pacing. The effects of RV apical pacing on LV mechanical dyssynchrony, LV strain and LV torsion can be assessed using this novel technique. Speckle tracking imaging may be helpful in the selection of the optimal RV pacing site, and in the selection of patients who may benefit from an upgrade of RV apical pacing to biventricular pacing.

## REFERENCES

- (1) Vardas PE, Auricchio A, Blanc JJ et al. Guidelines for cardiac pacing and cardiac resynchronization therapy: the task force for cardiac pacing and cardiac resynchronization therapy of the European Society of Cardiology. Developed in collaboration with the European Heart Rhythm Association. *Eur Heart J* 2007;28:2256-95.
- (2) Epstein AE, DiMarco JP, Ellenbogen KA et al. ACC/AHA/HRS 2008 Guidelines for Device-Based Therapy of Cardiac Rhythm Abnormalities: a report of the American College of Cardiology/American Heart Association Task Force on Practice Guidelines (Writing Committee to Revise the ACC/AHA/NASPE 2002 Guideline Update for Implantation of Cardiac Pacemakers and Antiarrhythmia Devices) developed in collaboration with the American Association for Thoracic Surgery and Society of Thoracic Surgeons. *J Am Coll Cardiol* 2008;51:e1-62.
- (3) Gillis AM. Redefining physiologic pacing: lessons learned from recent clinical trials. *Heart Rhythm* 2006;3:1367-72.
- (4) Vassallo JA, Cassidy DM, Miller JM, Buxton AE, Marchlinski FE, Josephson ME. Left ventricular endocardial activation during right ventricular pacing: effect of underlying heart disease. *J Am Coll Cardiol* 1986;7:1228-33.
- (5) Sweeney MO, Prinzen FW. A new paradigm for physiologic ventricular pacing. *J Am Coll Cardiol* 2006;47:282-8.
- (6) Tops LF, Schalij MJ, Holman ER, van Erven L, van der Wall EE, Bax JJ. Right ventricular pacing can induce ventricular dyssynchrony in patients with atrial fibrillation after atrioventricular node ablation. *J Am Coll Cardiol* 2006;48:1642-8.
- (7) Abraham TP, Dimaano VL, Liang HY. Role of tissue Doppler and strain echocardiography in current clinical practice. *Circulation* 2007;116:2597-609.
- (8) Leitman M, Lysyansky P, Sidenko S et al. Two-dimensional strain-a novel software for real-time quantitative echocardiographic assessment of myocardial function. *J Am Soc Echocardiogr* 2004;17:1021-9.
- (9) Reisner SA, Lysyansky P, Agmon Y, Mutlak D, Lessick J, Friedman Z. Global longitudinal strain: a novel index of left ventricular systolic function. *J Am Soc Echocardiogr* 2004;17:630-3.
- (10) Sweeney MO, Hellkamp AS, Ellenbogen KA et al. Adverse effect of ventricular pacing on heart failure and atrial fibrillation among patients with normal baseline QRS duration in a clinical trial of pacemaker therapy for sinus node dysfunction. *Circulation* 2003;107:2932-7.
- (11) Wilkoff BL, Cook JR, Epstein AE et al. Dual-chamber pacing or ventricular backup pacing in patients with an implantable defibrillator: the Dual Chamber and VVI Implantable Defibrillator (DAVID) Trial. *JAMA* 2002;288:3115-23.
- (12) Boerth RC, Covell JW. Mechanical performance and efficiency of the left ventricle during ventricular stimulation. *Am J Physiol* 1971;221:1686-91.
- (13) Preumont N, Jansens JL, Berkenboom G, van de BP, Stoupe E, Goldman S. Effects of right ventricular pacing on regional myocardial glucose metabolism. *Europace* 2005;7:584-91.
- (14) Tse HF, Lau CP. Long-term effect of right ventricular pacing on myocardial perfusion and function. *J Am Coll Cardiol* 1997;29:744-9.
- (15) Vernooij K, Dijkman B, Cheriex EC, Prinzen FW, Crijns HJ. Ventricular remodeling during long-term right ventricular pacing following His bundle ablation. *Am J Cardiol* 2006;97:1223-7.

- (16) Lieberman R, Padeletti L, Schreuder J et al. Ventricular pacing lead location alters systemic hemodynamics and left ventricular function in patients with and without reduced ejection fraction. *J Am Coll Cardiol* 2006;48:1634-41.
- (17) Bader H, Garrigue S, Lafitte S et al. Intra-left ventricular electromechanical asynchrony. A new independent predictor of severe cardiac events in heart failure patients. *J Am Coll Cardiol* 2004;43:248-56.
- (18) Liu WH, Chen MC, Chen YL et al. Right ventricular apical pacing acutely impairs left ventricular function and induces mechanical dyssynchrony in patients with sick sinus syndrome: a real-time three-dimensional echocardiographic study. *J Am Soc Echocardiogr* 2008;21:224-9.
- (19) Korinek J, Wang J, Sengupta PP et al. Two-dimensional strain—a Doppler-independent ultrasound method for quantitation of regional deformation: validation in vitro and in vivo. *J Am Soc Echocardiogr* 2005;18:1247-53.
- (20) Prinzen FW, Hunter WC, Wyman BT, McVeigh ER. Mapping of regional myocardial strain and work during ventricular pacing: experimental study using magnetic resonance imaging tagging. *J Am Coll Cardiol* 1999;33:1735-42.
- (21) Kass DA. An epidemic of dyssynchrony: but what does it mean? *J Am Coll Cardiol* 2008;51:12-7.
- (22) Tops LF, Suffoletto MS, Bleeker GB et al. Speckle-tracking radial strain reveals left ventricular dyssynchrony in patients with permanent right ventricular pacing. *J Am Coll Cardiol* 2007;50:1180-8.
- (23) Suffoletto MS, Dohi K, Cannesson M, Saba S, Gorcsan J, III. Novel speckle-tracking radial strain from routine black-and-white echocardiographic images to quantify dyssynchrony and predict response to cardiac resynchronization therapy. *Circulation* 2006;113:960-8.
- (24) Delgado V, Ypenburg C, van Bommel RJ et al. Assessment of left ventricular dyssynchrony by speckle tracking strain imaging comparison between longitudinal, circumferential, and radial strain in cardiac resynchronization therapy. *J Am Coll Cardiol* 2008;51:1944-52.
- (25) Arita T, Sorescu GP, Schuler BT et al. Speckle-tracking strain echocardiography for detecting cardiac dyssynchrony in a canine model of dyssynchrony and heart failure. *Am J Physiol Heart Circ Physiol* 2007;293:H735-H742.
- (26) Sengupta PP, Korinek J, Belohlavek M et al. Left ventricular structure and function: basic science for cardiac imaging. *J Am Coll Cardiol* 2006;48:1988-2001.
- (27) Buchalter MB, Rademakers FE, Weiss JL, Rogers WJ, Weisfeldt ML, Shapiro EP. Rotational deformation of the canine left ventricle measured by magnetic resonance tagging: effects of catecholamines, ischaemia, and pacing. *Cardiovasc Res* 1994;28:629-35.
- (28) Matsuoka K, Nishino M, Hara M et al. Right ventricular apical pacing impairs left ventricular apical and basal rotation and induces apical-basal rotation dyssynchrony. *Circulation* 2007;116:716 (Abstract).
- (29) Sorger JM, Wyman BT, Faris OP, Hunter WC, McVeigh ER. Torsion of the left ventricle during pacing with MRI tagging. *J Cardiovasc Magn Reson* 2003;5:521-30.
- (30) Manolis AS. The deleterious consequences of right ventricular apical pacing: time to seek alternate site pacing. *Pacing Clin Electrophysiol* 2006;29:298-315.
- (31) de Cock CC, Giudici MC, Twisk JW. Comparison of the haemodynamic effects of right ventricular outflow-tract pacing with right ventricular apex pacing: a quantitative review. *Europace* 2003;5:275-8.
- (32) Buckingham TA, Candinas R, Schlapfer J et al. Acute hemodynamic effects of atrioventricular pacing at differing sites in the right ventricle individually and simultaneously. *Pacing Clin Electrophysiol* 1997;20:909-15.
- (33) de Cock CC, Meyer A, Kamp O, Visser CA. Hemodynamic benefits of right ventricular outflow tract pacing: comparison with right ventricular apex pacing. *Pacing Clin Electrophysiol* 1998;21:536-41.
- (34) Giudici MC, Thornburg GA, Buck DL et al. Comparison of right ventricular outflow tract and apical lead permanent pacing on cardiac output. *Am J Cardiol* 1997;79:209-12.
- (35) Victor F, Mabo P, Mansour H et al. A randomized comparison of permanent septal versus apical right ventricular pacing: short-term results. *J Cardiovasc Electrophysiol* 2006;17:238-42.
- (36) Deshmukh P, Casavant DA, Romanyshyn M, Anderson K. Permanent, direct His-bundle pacing: a novel approach to cardiac pacing in patients with normal His-Purkinje activation. *Circulation* 2000;101:869-77.
- (37) Kypta A, Steinwender C, Kammler J, Leisch F, Hofmann R. Long-term outcomes in patients with atrioventricular block undergoing septal ventricular lead implantation compared with standard apical pacing. *Europace* 2008;10:574-9.
- (38) Padeletti L, Lieberman R, Schreuder J et al. Acute effects of His bundle pacing versus left ventricular and right ventricular pacing on left ventricular function. *Am J Cardiol* 2007;100:1556-60.

- (39) Occhetta E, Bortnik M, Magnani A et al. Prevention of ventricular desynchronization by permanent para-Hisian pacing after atrioventricular node ablation in chronic atrial fibrillation: a crossover, blinded, randomized study versus apical right ventricular pacing. *J Am Coll Cardiol* 2006;47:1938-45.
- (40) Zanon F, Bacchiega E, Rampin L et al. Direct His bundle pacing preserves coronary perfusion compared with right ventricular apical pacing: a prospective, cross-over mid-term study. *Europace* 2008;10:580-7.
- (41) Catanzariti D, Maines M, Cemin C, Broso G, Marotta T, Vergara G. Permanent direct his bundle pacing does not induce ventricular dyssynchrony unlike conventional right ventricular apical pacing. An inpatient acute comparison study. *J Interv Card Electrophysiol* 2006;16:81-92.
- (42) Inoue K, Hiasa G, Yoshii T et al. Beneficial Effect of Right Ventricular Outflow Pacing on Left Ventricular Dyssynchrony and Myocardial Torsion in Comparison with Right Ventricular Apical Pacing. *Circulation* 2007;116:331 (Abstract).
- (43) Liakopoulos OJ, Tomioka H, Buckberg GD, Tan Z, Hristov N, Trummer G. Sequential deformation and physiological considerations in unipolar right or left ventricular pacing. *Eur J Cardiothorac Surg* 2006;29 Suppl 1:S188-S197.
- (44) Ten Cate TJ, Scheffer MG, Sutherland GR, Fred VJ, van Hemel NM. Right ventricular outflow and apical pacing comparably worsen the echocardiographic normal left ventricle. *Eur J Echocardiogr* 2008, in press.
- (45) Yamano, Ueno, Takarada et al. The torsion assessed by a two-dimensional speckle tracking on different pacing sites. *Eur Heart J* 2007;28:887 (Abstract).
- (46) Baker CM, Christopher TJ, Smith PF, Langberg JJ, DeLurgio DB, Leon AR. Addition of a left ventricular lead to conventional pacing systems in patients with congestive heart failure: feasibility, safety, and early results in 60 consecutive patients. *Pacing Clin Electrophysiol* 2002;25:1166-71.
- (47) Leon AR, Greenberg JM, Kanuru N et al. Cardiac resynchronization in patients with congestive heart failure and chronic atrial fibrillation: effect of upgrading to biventricular pacing after chronic right ventricular pacing. *J Am Coll Cardiol* 2002;39:1258-63.
- (48) Leclercq C, Cazeau S, Lellouche D et al. Upgrading from single chamber right ventricular to biventricular pacing in permanently paced patients with worsening heart failure: The RD-CHF Study. *Pacing Clin Electrophysiol* 2007;30 Suppl 1:S23-S30.
- (49) Eldadah ZA, Rosen B, Hay I et al. The benefit of upgrading chronically right ventricle-paced heart failure patients to resynchronization therapy demonstrated by strain rate imaging. *Heart Rhythm* 2006;3:435-42.
- (50) Witte KK, Pipes RR, Nanthakumar K, Parker JD. Biventricular pacemaker upgrade in previously paced heart failure patients—improvements in ventricular dyssynchrony. *J Card Fail* 2006;12:199-204.

