



Universiteit  
Leiden  
The Netherlands

## Placental characteristics and complications in monochorionic twin pregnancies

Zhao, D.P.

### Citation

Zhao, D. P. (2016, November 8). *Placental characteristics and complications in monochorionic twin pregnancies*. Retrieved from <https://hdl.handle.net/1887/44230>

Version: Not Applicable (or Unknown)

License: [Licence agreement concerning inclusion of doctoral thesis in the Institutional Repository of the University of Leiden](#)

Downloaded from: <https://hdl.handle.net/1887/44230>

**Note:** To cite this publication please use the final published version (if applicable).

Cover Page



Universiteit Leiden



The handle <http://hdl.handle.net/1887/44230> holds various files of this Leiden University dissertation.

**Author:** Zhao, D.P.

**Title:** Placental characteristics and complications in monochorionic twin pregnancies

**Issue Date:** 2016-11-08

**Chorioamnionitis and early onset sepsis in TTTS after laser surgery**



**Histological Chorioamnionitis and Funisitis After Laser Surgery for Twin–Twin Transfusion  
Syndrome**

Depeng Zhao

Danielle Cohen

Johanna M Middeldorp

Erik W van Zwet

Monique E De Paepe

Dick Oepkes

Enrico Lopriore

## **Abstract**

**Objective:** To estimate the incidence of histological chorioamnionitis and funisitis after fetoscopic laser surgery for the management of twin–twin transfusion syndrome.

**Methods:** A case–control study was performed at the Leiden University Medical Center from 2013 to 2014. All twin–twin transfusion syndrome managed with laser surgery during the study period were included and compared to a control group of all monochorionic twins not treated with laser surgery. We excluded cases with fetal demise or higher-order pregnancies. Placentas were reviewed for the presence and degree of chorioamnionitis and presence or absence of fetal inflammatory response. The primary outcome was the incidence of histological chorioamnionitis and funisitis after laser surgery. Odds ratios (OR) and 95% confidence intervals (CI) for primary outcomes were calculated. A p value of <.05 was considered as statistical significance.

**Results:** Sixty-two patients managed with laser surgery were included in the study group and compared to 64 patients in the control group. The incidence of histological chorioamnionitis was 13% (8/62) in the laser group versus 5% (3/64) in controls (OR 3.0, 95% CI .8-11.9,  $P=.12$ ). Funisitis occurred in 8% (10/124) in the laser group versus 0% in controls (OR 11.1, 95% CI 1.3-96.9,  $P=.03$ ). Histological chorioamnionitis with or without funisitis after laser surgery was associated with shorter laser-to-delivery interval (median 6.6 (range 3.4-14.1) versus 13.6 (4.4-20.1) weeks,  $P<.01$ ) and lower gestational age at birth (median 28.1 (range 23.1-32.6) versus 32.7 (24.4-37.0) weeks,  $P<.01$ ).

**Conclusion:** These findings suggest twin–twin transfusion syndrome managed with laser surgery are at increased risk of funisitis.

## Introduction

Twin–twin transfusion syndrome affects around 10% of monochorionic twin pregnancies, resulting in 80% to 100% perinatal mortality if left untreated.[1] Twin–twin transfusion syndrome results from an unbalanced exchange of blood between the donor twin and recipient twin through placental vascular anastomoses, which are present in almost all monochorionic twins. Fetoscopic laser surgery is the optimal treatment for severe twin–twin transfusion syndrome and leads to an improved perinatal outcome.[2] In laser surgery the surgeon introduces a fetoscope into the amniotic cavity of the recipient twin and coagulates the connecting vessels with a laser beam. Postoperative complications include recurrent twin–twin transfusion syndrome, twin anemia–polycythemia sequence, premature rupture of membranes (PROM) and preterm birth.[3-8] The risk of intrauterine infection may be increased due to the invasive nature of laser surgery. A possible association between laser surgery and chorioamnionitis has been suggested.[3-13] Chorioamnionitis, especially concomitant with funisitis, is the main factor of preterm birth and cerebral injuries in neonates.[14] Chorioamnionitis represents the maternal inflammatory response while funisitis is the fetal inflammatory response and is secondary to severe chorioamnionitis. The occurrence of intrauterine infection may thus compromise the treatment efficacy of laser surgery. However, good-quality studies with histological evaluation are not available. The exact incidence of histological chorioamnionitis and funisitis after laser surgery remains unclear.

The primary purpose of this study was to investigate the incidence of histological chorioamnionitis and funisitis after fetoscopic laser surgery for the treatment of twin–twin transfusion syndrome.

## Materials and Methods

A case–control study was conducted at the Leiden University Medical Center from March 2013 to December 2014. All consecutive twin–twin transfusion syndrome cases treated with laser surgery at our center were included in the study group. Monochorionic twins delivered at our center but not treated with laser surgery during the same study period were included in the control group. We excluded triplet or higher order pregnancies and monochorionic twin pregnancies with single or double fetal demise. Diagnosis of twin–twin transfusion syndrome was based on the Eurofoetus criteria: presence of a deepest vertical pocket of amniotic fluid in the donor  $\leq 2$  cm and  $\geq 8$  cm in the recipient of before 20 weeks of gestation or  $\geq 10$  cm after 20 weeks.[10] Severity of twin–twin transfusion syndrome was assessed according to Quintero’s staging system.[15] If twin–twin transfusion syndrome were diagnosed, the patients were counseled regarding the following management alternatives in details: expectant management, amnioreduction and fetoscopic laser surgery. Fetoscopic laser surgery was performed in TTTS with Quintero stage 1 with clinical symptoms of polyhydramnios, or Quintero stage 2-4.

Amnioreduction was performed using an 18-gauge needle under continuous ultrasound visualization. Amniotic fluid in the sac of the recipient was reduced to a deepest pool of 5 cm. No prophylactic antibiotics were administered prior to amnioreduction given the low risk (<1%) of intrauterine infection after intervention.[16]

Solomon technique was used in all the twin–twin transfusion syndrome cases managed with laser surgery. Detailed information on the operative procedure was described previously.[17] In brief, prophylactic tocolysis using indomethacin (100 mg, one dose, rectal administration, 2 hours before operation) and antibiotics using cefuroxime (1.5 g, intravenous



administration prior to fetoscopic laser surgery) was administered perioperatively. Under continuous ultrasound guidance, a fetoscope was introduced into the amniotic sac of the recipient twin. After visualization of the vascular equator, all anastomoses were coagulated using a diode or Nd:YAG laser device (Dornier MedTech, Wessling, Germany) with power setting from 20 to 70 W. After ablation of vascular anastomoses one by one, a laser line was drawn from one edge of the placenta to the other. After each laser procedure, amnioreduction was performed to drain the excessive amniotic fluid to a deepest vertical pocket of 6 cm. The number of coagulated anastomoses, total laser energy and duration of operation were recorded. Repeated fetoscopic laser surgery was considered if recurrent or reversed twin–twin transfusion syndrome occurred at gestational age of  $\leq 26$  weeks. After fetoscopic laser surgery, patients were monitored at our center in combination the monitoring at the referring hospital. All lasered placentas were shipped to our center after delivery.

Diagnosis of twin anemia–polycythemia sequence was based on prenatal or postnatal criteria as described previously. Prenatal criteria includes Doppler ultrasound detecting an increase in middle cerebral artery peak systolic velocity  $> 1.5$  multiples of the median in the anemic fetus that coincided with a decrease in middle cerebral artery peak systolic velocity  $< 1$  multiples of the median in the polycythemic fetus. Postnatal criteria consists of hematologic tests (inter-twin Hemoglobin difference  $> 8.0\text{g/dL}$  and inter-twin reticulocyte count ratio  $> 1.7$ ) and placental injection showing only few small anastomoses present.[18] If twin anemia–polycythemia sequence developed, intrauterine blood transfusion with or without partial exchange transfusion was considered depending on clinical evaluation. Prophylactic antibiotics were not routinely administered prior to intrauterine blood

transfusion due to the low risk (from 0 to 1%) of intrauterine inflammation after procedure.[19]

Written informed consent was obtained from each patient included in the study. The study was approved by the institutional ethics committee (the Leiden University Medical Centre Medical Ethics Committee (MEC P07.261).

All monochorionic twin placentas were evaluated according to a fixed protocol. Placental tissues were collected using a minor adaptation of the method described by Burton et al.[20]

In brief, tissue-samples were collected from the umbilical cord, placenta and membrane area of each twin. Tissue-samples were collected from three sites of each umbilical cord; one close to the fetus, one at the middle of the cord and one near the placental insertion site. A membrane roll of each side was taken from the rupture site to placental margin.

Macroscopically normal placental parenchyma from the placental share of each twin was sampled and processed for histological evaluation. Histological chorioamnionitis was diagnosed as the presence neutrophilic granulocytes in the chorionic plate or the extraplacental membranes. Histological chorioamnionitis was defined as one or more of the following categories: acute subchorionitis or chorionitis, acute chorioamnionitis or necrotizing chorioamnionitis. Diagnosis of funisitis is based on the presence of neutrophilic granulocytes in the wall of the umbilical vessel(s) and Wharton's jelly. Funisitis was defined as one or more of the following items: chorionic vasculitis, umbilical phlebitis, umbilical vasculitis (inflammation in one or two umbilical arteries  $\pm$  umbilical vein) and umbilical panvasculitis (inflammation in 3 vessels).[21] Histological chorioamnionitis is recognized as the maternal host response, while funisitis suggests fetal inflammatory response secondary

to severe histological chorioamnionitis.[22] The grading and staging of maternal and fetal inflammatory response was according to the criteria proposed by Redline et al. (see Table 1, which illustrates the grading and staging of histological chorioamnionitis and funisitis).[23]

Perinatal outcomes were documented prospectively in a dedicated database. The following variables were recorded, including gestational age at laser surgery, premature rupture of membranes (PROM), gestational age at PROM, maternal fever ( $\geq 38$  °C), gestational age at birth, delivery mode, birth weight, full neonatal blood count and C-reactive protein levels (maximum value within first 72 hours after birth), severe cerebral injury, early-onset neonatal sepsis and neonatal mortality. Severe cerebral injury was defined and recorded in accordance with a standard protocol at our center[24]. Early-onset neonatal sepsis was defined as the onset of sepsis within 72 hours after birth[25] and recorded as proven or suspected sepsis. Proven early-onset sepsis was diagnosed if the blood culture was positive. Suspected early-onset neonatal sepsis was defined if antibiotic treatment was administered for 5-7 days in an infant with signs of infection though without positive blood culture. All preterm neonates born at a gestational age below 35 weeks from mothers with PROM are routinely placed on antibiotics at birth. Neonates delivered after 35 weeks are only placed on antibiotics depending on other clinical findings or risk factors for suspected perinatal infection. Neonatal mortality was defined as death within 28 days after birth.

### *Statistics*

In general population of preterm birth, the incidence of histological chorioamnionitis ranges from 30% to 70%.[26-28] We thus expected histological chorioamnionitis present in 30% of the control group of MC twins not managed with laser surgery (because we thought that this group had a low risk of histological chorioamnionitis) and in 55% of the study group of

twin–twin transfusion syndrome managed with laser surgery (based on the expected gestational age at birth in the laser group of 31-32 weeks corresponding to a incidence of 52% of histological chorioamnionitis according to the data on the gestational age-dependent frequency of chorioamnionitis reported by Mueller-Heubach et al.).[27] The clinical outcome including gestational age at birth in TTTS cases was significantly improved after the introduction of fetoscopic laser surgery. We calculated that 61 placentas in each group were required to demonstrate a 25% absolute difference in histological chorioamnionitis (i.e. 30% vs 55%), with a significance of 0.05 and a power of 80%, by two-tailed analysis. The normality of continuous variables was assessed using Shapiro-Wilk test. Unpaired t test or Mann-Whitney U test was adopted to compare continuous variables, as appropriate. Generalized estimating equation with exchangeable structure was employed to evaluate the odds ratio (OR) of laser surgery in relation to funisitis. Results of categorical variables are compared using Fisher’s exact test or Chi-square test, as appropriate. A p-value < 0.05 was considered to indicate statistical significance. Analysis was performed using SPSS version 20 (SPSS, inc., Chicago, Illinois, USA).

## **Results**

During the study period, 71 patients managed with fetoscopic laser surgery and 75 patients not managed with fetoscopic laser surgery were eligible for this study. Nine (13%) twin–twin transfusion syndrome cases managed with fetoscopic laser surgery and 8 (11%) monochorionic twin pregnancies not treated with laser surgery were excluded due to single or double fetal demise. Three triplet pregnancies not undergoing laser surgery were also excluded. The remaining 62 twin–twin transfusion syndrome cases managed with laser surgery were included in the study group and 64 monochorionic twins without laser surgery

were included in the control group. In the study group of twin–twin transfusion syndrome treated with laser surgery, 19% (12/62) cases were stage 1, 39% (24/62) stage 2, 42% (26/62) stage 3. Post–laser twin anemia–polycythemia developed in 4 cases and was treated with intrauterine transfusion and/or repeated laser surgery. In the control group, two monochorionic twin pregnancies with spontaneous twin anemia–polycythemia sequence were managed with intrauterine blood transfusions and 6 late twin–twin transfusion syndrome cases were treated with amniodrainage. Clinical baseline characteristics of two groups were displayed in Table 2.

Table 2. Baseline characteristics

Variables	TTTS treated with laser (n=62)	Control group (n=64)	P
Gestational age at birth – wk	31.8 ± 3.5	33.3 ± 3.1	<.01
Birth weight – gr	1646 ± 607	1906 ± 667	<.01
PROM – n (%)	21 (34)	4 (6)	<.01
Maternal fever (≥38 °C) – n (%)	11 (16)	5 (8)	.16
Antenatal corticosteroid treatment – n (%)	42 (68)	20 (31)	<.01
Maternal antibiotic treatment – n (%)*	21 (24)	6 (9)	<.01
Cesarean delivery – n (%)	27 (44)	31 (48)	.58

Data was shown as mean ± SD or number (%). TTTS: twin–twin transfusion syndrome; PROM: premature rupture of membrane. \* Antibiotics were administered due to clinical indications such as PROM or maternal fever, but not for prophylaxis prior to laser surgery.

**Table 1.** Grading and staging of histological chorioamnionitis and funisitis

Diagnostic categories	Histological chorioamnionitis	Funisitis	
Grading	1	≥5 clusters, ≥2 neutrophilic granulocytes each cluster per high power field	≥5 clusters, ≥2 neutrophils each cluster per high power field
	2	Presence of confluent neutrophilic granulocytes, ≥ 3 isolated foci of neutrophilic granulocytes, continuous band of neutrophilic granulocytes, or microabscesses	Presence of near confluent intramural neutrophilic granulocytes in chorionic or umbilical vessels
	1	Infiltration of neutrophilic granulocytes limited in chorion	Infiltration of neutrophilic granulocytes limited in chorionic vessels and/or umbilical vein
Staging	2	Infiltration of neutrophilic granulocytes into chorioamniotic membrane	Infiltration of neutrophilic granulocytes into umbilical artery
	3	Necrotizing (severe) chorioamnionitis, karyorrhexis of neutrophilic granulocytes, necrosis in amnion	Presence of neutrophilic granulocytes and associated debris in concentric bands-rings-halos around umbilical vessels (severe fetal inflammatory response)

We found that the incidence of histological chorioamnionitis in the study group and the control group was 13% (8/62) versus 5% (3/64), respectively (OR 3.0, 95% confidence interval (CI) .8-11.9,  $P=.12$ ). The incidence of funisitis in the study group was significantly higher compared to the control group, 8% (10/124) versus 0% (0/128), respectively (OR 11.1, 95% CI 1.3-96.9,  $P=.03$ ). In the control group, no histological chorioamnionitis nor funisitis occurred in monochorionic twins managed with amniodrainage or intrauterine transfusion. In the study group, histological chorioamnionitis without funisitis occurred in one of the four cases with post-laser twin anemia–polycythemia sequence. In this case, repeated laser surgery was planned but the intervention was cancelled due to signs of intrauterine inflammation (premature contractions and maternal fever, and delivery at 23<sup>+1</sup> weeks). In the study group, histological chorioamnionitis was detected in the placental share of both the ex–donor and ex–recipient in 50% (4/8) cases, in the placental share of the ex–recipient alone in 38% (3/8) cases and in the placental share of the ex–donor alone in 12% (1/8) cases. The ten cases with funisitis in the study group occurred in five twin pairs (both in the ex–donors and ex–recipients). All cases with funisitis also had histological chorioamnionitis. Analysis of histological findings between two groups was summarized in Table 3. An example of histological chorioamnionitis and funisitis is shown in Figure 1 and 2, respectively.

Analysis of the association of several perinatal variables with the occurrence of histological chorioamnionitis in the study group of twin–twin transfusion syndrome treated with laser surgery is shown in Table 4. Median gestational age at PROM in twin–twin transfusion syndrome cases with and without histological chorioamnionitis was 25.2 (range 25.1-28.0) and 30.6 weeks (15.9-35.1) weeks, respectively ( $p=.04$ ).

Table 3. Incidence of histological chorioamnionitis and funisitis in TTTS after fetoscopic laser surgery and control group

Variables	TTTS treated with laser (n=62 pregnancies, 124 fetuses)	Control group (n=64 pregnancies, 128 fetuses)	OR (95% CI) <sup>†</sup>	P value
Histological chorioamnionitis – n (%)	8/62 (13%)	3/64 (5%)	3.0 (.8-11.9)	.10
Grade 1 and stage 1	1/8 (13%)	1/3 (33%)		
Grade 2 and stage 1	3/8 (38%)	2/3 (67%)	NA	NA
Grade 2 and stage 2	1/8 (13%)	NA		
Grade 2 and stage 3	3/8 (38%)	N/A		
Funisitis – n (%) <sup>*</sup>	10/124 (8%)	0	11.1 (1.3-96.9)	.03
Grade 1 and stage 1	4/10 (40%)	NA		
Grade 2 and stage 1	1/10 (10%)	NA	NA	NA
Grade 1 and stage 2	5/10 (50%)	NA		

Data was displayed as number (%). TTTS: twin-twin transfusion syndrome; OR: odds ratio; CI: confidence interval. NA: not applicable.

<sup>\*</sup>Denotes funisitis present in each infant instead of pregnancies. To be able to compute odds ratios, we added one positive outcome to the control group. As a result, the estimates of the odds ratios are conservative, and their significance is underestimated.



Table 4. Comparison of risk factors between TTTS after fetoscopic laser surgery with and without histological chorioamnionitis

Risk factors	TTTS with acute chorioamnionitis (n=8 pregnancies, 16 fetuses)	TTTS without acute chorioamnionitis (n=54 pregnancies, 110 fetuses)	P value
Gestational age at operation – wk	21.7 (16.2-25.0)	19.6 (15.4-27.4)	.15
Quintero stage – n (%)			
1	3	9	
2	2	22	1.0
3	3	23	
4	0	0	
Anterior placenta – n (%)	3 (38)	18 (35)	.67
PROM – n (%)	3 (38)	18 (33)	.60
Gestational age at PROM – wk	25.2 (25.1-28.0)	30.6 (15.9-35.1)	.04
PROM-to-delivery interval – day	9 (2-15)	4 (1-126)	.49
Intraprocedural bleeding – n (%)	1 (13)	3 (6)	.43
Total amount of laser energy – J	5460 (1928-14924)	4120 (600-10100)	.06
Number of anastomoses coagulated – n	6 (3-13)	6 (3-23)	.79
Duration of operation – min	34 (24-40)	30 (12-65)	.12

Data was displayed as median (range) or number (%).TTTS: twin–twin transfusion syndrome; PROM: premature rupture of membranes

Table 5. Histological chorioamnionitis in TTTS treated with fetoscopic laser surgery in relation to perinatal outcome

Variables	TTTS with acute chorioamnionitis (n=8 pregnancies, 16 fetuses)	TTTS without acute chorioamnionitis (n=54 pregnancies, 108 fetuses)	P value
Laser-to-delivery interval – wk	6.6 (3.4-14.1)	13.6 (4.4-20.1)	<.01
Gestational age at birth – wk	28.1 (23.1-32.6)	32.7 (24.4-37.0)	<.01
C-reactive protein – mg/L	7.5 (1.0-64.0)	1.0 (1.0-54.1)	<.01
Leukocyte count – 10 <sup>9</sup> /L	13.2 (2.6-23.8)	9.2 (2.0-23.9)	.07
Early-onset neonatal sepsis – n /N (%) <sup>*</sup>	2/14 (14%) <sup>b</sup>	4/100 (4%) <sup>c</sup>	.13
Cerebral injury – n/N (%) <sup>*</sup>	4/14(29%)	13/106 (12%)	.83
Neonatal mortality – n/N (%) <sup>*</sup>	2 (13%)	6 (6%)	.30

Data was displayed as median (range) or number (%). TTTS: twin–twin transfusion syndrome; <sup>\*</sup> Refers to per infant rather pregnancy. Three infants died soon after birth and in 11 neonates were lost to follow up therefore no any test or bacterial culture was performed.

Comparison of perinatal outcome between twin–twin transfusion syndrome cases with and without histological chorioamnionitis after fetoscopic laser surgery was presented in Table 5. Median of laser-to-delivery interval in twin–twin transfusion syndrome with and without histological chorioamnionitis after fetoscopic laser surgery was 6.6 (range 3.4-14.1) versus 13.6 (range 4.4-20.1) weeks, respectively ( $p < .01$ ).

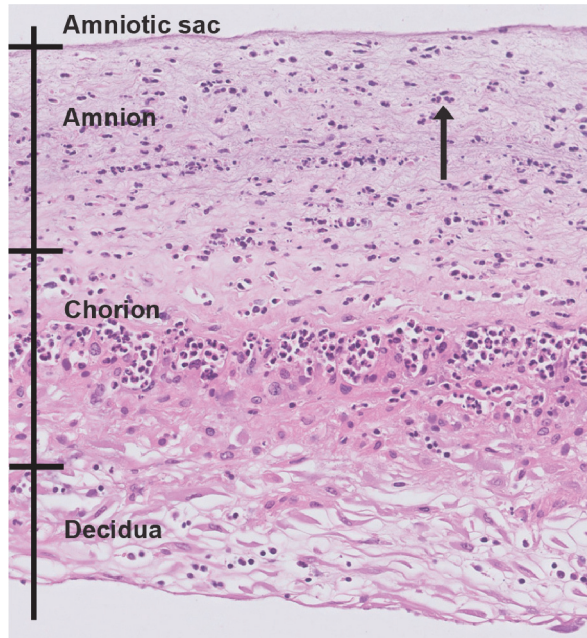


Figure 2 An example of histological chorioamnionitis in a placenta from twin–twin transfusion syndrome treated with fetoscopic laser surgery. Histological chorioamnionitis (stage 2 and grade 2) occurred with diffuse distribution of neutrophils (blue arrow).

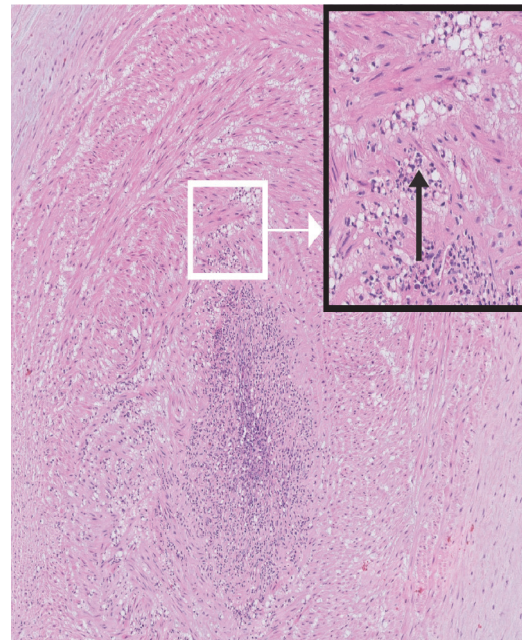


Figure 1 An example of funisitis following fetoscopic laser surgery. Umbilical arteritis (stage 2 and grade 2) occurred. The infiltrated neutrophils were nearly confluent in the transverse section of arterial wall. A close view of umbilical arteritis (white square) was shown in the enlarged picture (black square). Neutrophils were indicated by the blue arrow.

## Discussion

This study presents the histological evaluation of the maternal and fetal inflammatory response after fetoscopic laser surgery for twin–twin transfusion syndrome. We found that the risk of funisitis (8%) was significantly increased after laser. The incidence of histological chorioamnionitis was also higher in the study group compared to the control group (13%

versus 5%), but no statistical significance was found. Our data suggest that fetoscopic intervention is not only associated with an increased risk of PROM, but also with an increased risk of funisitis.

The occurrence of intrauterine inflammation after laser surgery in the literature varies from 0 to 4%. [3-13] In these studies, the diagnosis of intrauterine inflammation was defined as clinical chorioamnionitis, based on clinical indicators such as maternal fever and fetal tachycardia. However, clinical chorioamnionitis does not correspond well to histological chorioamnionitis. [29, 30] Importantly, histological chorioamnionitis is a more reliable indicator for intrauterine inflammation compared to clinical chorioamnionitis. [31]

Intrauterine inflammation in severe chorioamnionitis may extend to the umbilical cord and the fetus, resulting in funisitis (inflammation in the cord) and fetal inflammatory response. Therefore, the higher incidence of histological chorioamnionitis and funisitis detected in this study may be a more reliable indicator of the true risk and the severity of intrauterine inflammation after laser.

The cause of increased risk of funisitis after laser is not well known. The increased risk may be related to the nature of the fetal surgical intervention. The use of a relatively large fetoscope (diameter typically 3 to 4 mm), creating a membrane defect (and high risk of PROM) [32] and the use of laser energy creating iatrogenic placental necrosis may induce maternal inflammatory response ('sterile inflammation'), even with fetal involvement. [22, 33] Given that the risk factors for funisitis and histological chorioamnionitis are nearly identical [34] and that the sample size of cases with funisitis in this study is small, we evaluated the role of several perinatal risk factors only for histological chorioamnionitis. We found that lower gestational age at PROM was associated with the occurrence of

histological chorioamnionitis after laser. However, the limited number of pregnancies with histological chorioamnionitis prevented further examination of any independent association between gestational age at PROM and histological chorioamnionitis after laser.

Previous studies reported that both histological chorioamnionitis and funisitis contribute to the increased risk of short-term adversity.[14, 35, 36] In our study, we found that histological chorioamnionitis was related to shorter laser-to-delivery interval and lower gestational age at birth. Noticeably, the longer laser-to-delivery interval in cases without intrauterine inflammation may be partially iatrogenic since active management may be considered in cases with PROM at early gestational age. In a recent study, the risk of impaired long-term neurodevelopmental outcome was higher in preterm infants with funisitis than histological chorioamnionitis,[37] emphasizing the clinical consequences of funisitis. A larger study with long-term neurodevelopmental follow up is needed to compare the risk of histological chorioamnionitis with or without funisitis in infants with twin-twin transfusion syndrome treated with laser.

The main limitation of our study is the selection bias due to the exclusion of cases with fetal demise. Severe intrauterine inflammation may lead to fetal demise. Exclusion of these cases may thus lead to an underestimation of the true risk of intrauterine inflammation after laser. However, fetal death itself may also stimulate intrauterine inflammation. The cause-effect relationship between fetal death and intrauterine inflammation is difficult to ascertain. In addition, TTTS itself may be a risk factor for intrauterine inflammation. The ideal control group would have been twin-twin transfusion syndrome managed without laser. However, this is considered unethical since the optimal treatment for this condition is laser surgery. Interestingly, the incidence of histological chorioamnionitis in this study (13%) is quite low

compared to the general incidence in preterm births (30% - 70%).[26, 38] This discrepancy may be explained by the lack of consistent diagnostic criteria and methods for histological chorioamnionitis.[39] The high rate of cesarean section, preoperative use of indomethacin and prophylactic antibiotic, antibiotic treatment for PROM and corticosteroid treatment in the study group may also contribute to the lower rate of histological chorioamnionitis.[14, 22, 40] As discussed above, placental necrosis after laser may be associated with intrauterine inflammation. The occurrence of intrauterine inflammation after laser may thus be confounded by the amount of laser energy and duration of operation. Furthermore, the incidence of histological chorioamnionitis in this study (13%) is higher than that after other invasive procedures such as amniodrainage and intrauterine transfusion (less than 1%).[16, 19] Papanna et al. reported the size of operative cannula for laser surgery contributes to the occurrence of post-laser PROM, which is closely related to intrauterine inflammation.[32] Further studies are warranted to investigate whether the improvement of operation instruments (smaller diameter) could reduce the risk of intrauterine inflammation.

In conclusion, fetoscopic laser surgery appears to increase the risk of histologically determined intrauterine inflammation.

## References

- [1] Lewi L, Jani J, Blickstein I, Huber A, Gucciardo L, Van Mieghem T, Done E, Boes AS, Hecher K, Gratacos E, Lewi P and Deprest J. The outcome of monochorionic diamniotic twin gestations in the era of invasive fetal therapy: a prospective cohort study. *Am J Obstet Gynecol.* 2008;199(5).
- [2] Akkermans J, Peeters SH, Klumper FJ, Lopriore E, Middeldorp JM and Oepkes D. Twenty-Five Years of Fetoscopic Laser Coagulation in Twin-Twin Transfusion Syndrome: A Systematic Review. *Fetal Diagn Ther.* 2015.
- [3] Habli M, Bombrys A, Lewis D, Lim FY, Polzin W, Maxwell R and Crombleholme T. Incidence of complications in twin-twin transfusion syndrome after selective fetoscopic laser photocoagulation: a single-center experience. *Am J Obstet Gynecol.* 2009;201(4):417.e1-7.
- [4] Meriki N, Smoleniec J, Challis D and Welsh AW. Immediate outcome of twin-twin transfusion syndrome following selective laser photocoagulation of communicating vessels at the NSW Fetal Therapy Centre. *Aust N Z J Obstet Gynaecol.* 2010;50(2):112-9.
- [5] Merz W, Tchatcheva K, Gembruch U and Kohl T. Maternal complications of fetoscopic laser photocoagulation (FLP) for treatment of twin-twin transfusion syndrome (TTTS). *J Perinatol.* 2010;38(4):439-43.
- [6] Rossi AC, Kaufman MA, Bornick PW and Quintero RA. General vs local anesthesia for the percutaneous laser treatment of twin-twin transfusion syndrome. *Am J Obstet Gynecol.* 2008;199(2):137 e1-7.
- [7] Rustico MA, Lanna MM, Faiola S, Schena V, Dell'avanzo M, Mantegazza V, Parazzini C, Lista G, Scelsa B, Consonni D and Ferrazzi E. Fetal and maternal complications after selective fetoscopic laser surgery for twin-to-twin transfusion syndrome: a single-center experience. *Fetal Diagn Ther.* 2012;31(3):170-8.
- [8] Yamamoto M, Murr LE, Robyr R, Leleu F, Takahashi Y and Ville Y. Incidence and impact of perioperative complications in 175 fetoscopy-guided laser coagulations of chorionic plate anastomoses in fetofetal transfusion syndrome before 26 weeks of gestation. *Am J Obstet Gynecol.* 2005;193(3):1110-6.
- [9] Ville Y, Hecher K, Gagnon A, Sebire N, Hyett J and Nicolaides K. Endoscopic laser coagulation in the management of severe twin-to-twin transfusion syndrome. *Br J Obstet Gynaecol.* 1998;105(4):446-53.
- [10] Senat MV, Deprest J, Boulvain M, Paupe A, Winer N and Ville Y. Endoscopic laser surgery versus serial amnioreduction for severe twin-to-twin transfusion syndrome. *N Engl J Med.* 2004;351(2):136-44.
- [11] Fowler SF, Sydorak RM, Albanese CT, Farmer DL, Harrison MR and Lee H. Fetal endoscopic surgery: Lessons learned and trends reviewed. *Journal of pediatric surgery.* 2002;37(12):1700-2.
- [12] Valsky DV, Eixarch E, Martinez-Crespo JM, Acosta ER, Lewi L, Deprest J and Gratacos E. Fetoscopic laser surgery for twin-to-twin transfusion syndrome after 26 weeks of gestation. *Fetal Diagn Ther.* 2012;31(1):30-4.
- [13] Wu D and Ball RH. The Maternal Side of Maternal-Fetal Surgery. *Clinics in Perinatology.* 2009;36(2):247-+.
- [14] Elimian A, Verma U, Beneck D, Cipriano R, Visintainer P and Tejani N. Histologic chorioamnionitis, antenatal steroids, and perinatal outcomes. *Obstet Gynecol.* 2000;96(3):333-6.

- [15] Quintero RA, Morales WJ, Allen MH, Bornick PW, Johnson PK and Kruger M. Staging of twin-twin transfusion syndrome. *J Perinatol.* 1999;19(8 Pt 1):550-5.
- [16] Elliott JP, Urig MA and Clewell WH. Aggressive therapeutic amniocentesis for treatment of twin-twin transfusion syndrome. *Obstet Gynecol.* 1991;77(4):537-40.
- [17] Slaghekke F, Lopriore E, Lewi L, Middeldorp JM, van Zwet EW, Weingertner AS, Klumper FJ, DeKoninck P, Devlieger R, Kilby MD, Rustico MA, Deprest J, Favre R and Oepkes D. Fetoscopic laser coagulation of the vascular equator versus selective coagulation for twin-to-twin transfusion syndrome: an open-label randomised controlled trial. *Lancet.* 2014;383(9935):2144-51.
- [18] Slaghekke F, Kist WJ, Oepkes D, Pasma SA, Middeldorp JM, Klumper FJ, Walther FJ, Vandenbussche FP and Lopriore E. Twin anemia-polycythemia sequence: diagnostic criteria, classification, perinatal management and outcome. *Fetal Diagn Ther.* 2010;27(4):181-90.
- [19] Lindenburg IT, van Kamp IL and Oepkes D. Intrauterine blood transfusion: current indications and associated risks. *Fetal Diagn Ther.* 2014;36(4):263-71.
- [20] Burton GJ, Sebire NJ, Myatt L, Tannetta D, Wang YL, Sadovsky Y, Staff AC and Redman CW. Optimising sample collection for placental research. *Placenta.* 2014;35(1):9-22.
- [21] Gündoğan F and De Paepe ME. Ascending Infection. *Surgical Pathology Clinics*6(1):33-60.
- [22] Kim CJ, Romero R, Chaemsathong P, Chaiyasit N, Yoon BH and Kim YM. Acute chorioamnionitis and funisitis: definition, pathologic features, and clinical significance. *Am J Obstet Gynecol.* 2015;213(4 Suppl):S29-52.
- [23] Redline RW, Faye-Petersen O, Heller D, Qureshi F, Savell V, Vogler C and Society for Pediatric Pathology PSAFINC. Amniotic infection syndrome: nosology and reproducibility of placental reaction patterns. *Pediatr Dev Pathol.* 2003;6(5):435-48.
- [24] Lopriore E, van Wezel-Meijler G, Middeldorp JM, Sueters M, Vandenbussche FP and Walther FJ. Incidence, origin, and character of cerebral injury in twin-to-twin transfusion syndrome treated with fetoscopic laser surgery. *Am J Obstet Gynecol.* 2006;194(5):1215-20.
- [25] Polin RA. Management of neonates with suspected or proven early-onset bacterial sepsis. *Pediatrics.* 2012;129(5):1006-15.
- [26] Hillier SL, Martius J, Krohn M, Kiviat N, Holmes KK and Eschenbach DA. A case-control study of chorioamnionic infection and histologic chorioamnionitis in prematurity. *N Engl J Med.* 1988;319(15):972-8.
- [27] Mueller-Heubach E, Rubinstein DN and Schwarz SS. Histologic chorioamnionitis and preterm delivery in different patient populations. *Obstet Gynecol.* 1990;75(4):622-6.
- [28] Ehsanipoor RM, Arora N, Lagrew DC, Wing DA and Chung JH. Twin versus singleton pregnancies complicated by preterm premature rupture of membranes. *J Matern Fetal Neonatal Med.* 2012;25(6):658-61.
- [29] Smulian JC, Shen-Schwarz S, Vintzileos AM, Lake MF and Ananth CV. Clinical chorioamnionitis and histologic placental inflammation. *Obstet Gynecol.* 1999;94(6):1000-5.
- [30] Heller DS, Rimpel LH and Skurnick JH. Does histologic chorioamnionitis correspond to clinical chorioamnionitis? *J Reprod Med.* 2008;53(1):25-8.
- [31] Romero R, Salafia CM, Athanassiadis AP, Hanaoka S, Mazor M, Sepulveda W and Bracken MB. The relationship between acute inflammatory lesions of the preterm placenta and amniotic fluid microbiology. *Am J Obstet Gynecol.* 1992;166(5):1382-8.
- [32] Papanna R, Block-Abraham D, Mann LK, Buhimschi IA, Bebbington M, Garcia E, Kahlek N, Harman C, Johnson A, Baschat A and Moise KJ, Jr. Risk factors associated with preterm delivery after fetoscopic laser ablation for twin-twin transfusion syndrome. *Ultrasound Obstet Gynecol.* 2014;43(1):48-53.



- [33] De Paepe ME, Friedman RM, Poch M, Hansen K, Carr SR and Luks FI. Placental findings after laser ablation of communicating vessels in twin-to-twin transfusion syndrome. *Pediatr Dev Pathol.* 2004;7(2):159-65.
- [34] Mi Lee S, Romero R, Lee KA, Jin Yang H, Joon Oh K, Park CW and Yoon BH. The frequency and risk factors of funisitis and histologic chorioamnionitis in pregnant women at term who delivered after the spontaneous onset of labor. *J Matern Fetal Neonatal Med.* 2011;24(1):37-42.
- [35] Lau J, Magee F, Qiu Z, Hoube J, Von Dadelszen P and Lee SK. Chorioamnionitis with a fetal inflammatory response is associated with higher neonatal mortality, morbidity, and resource use than chorioamnionitis displaying a maternal inflammatory response only. *Am J Obstet Gynecol.* 2005;193(3 Pt 1):708-13.
- [36] Gisslen T, Alvarez M, Wells C, Soo MT, Lambers DS, Knox CL, Meinzen-Derr JK, Chougnet CA, Jobe AH and Kallapur SG. Fetal inflammation associated with minimal acute morbidity in moderate/late preterm infants. *Archives of disease in childhood Fetal and neonatal edition.* 2016.
- [37] Rovira N, Alarcon A, Iriondo M, Ibanez M, Poo P, Cusi V, Agut T, Pertierra A and Krauel X. Impact of histological chorioamnionitis, funisitis and clinical chorioamnionitis on neurodevelopmental outcome of preterm infants. *Early Hum Dev.* 2011;87(4):253-7.
- [38] Mazor M, Hershkovitz R, Ghezzi F, Maymon E, Horowitz S and Leiberman JR. Intraamniotic infection in patients with preterm labor and twin pregnancies. *Acta obstetrica et gynecologica Scandinavica.* 1996;75(7):624-7.
- [39] Czikk MJ, McCarthy FP and Murphy KE. Chorioamnionitis: from pathogenesis to treatment. *Clin Microbiol Infect.* 2011;17(9):1304-11.
- [40] Black LP, Hinson L and Duff P. Limited course of antibiotic treatment for chorioamnionitis. *Obstet Gynecol.* 2012;119(6):1102-5.

