



Universiteit
Leiden
The Netherlands

Experimental therapeutic strategies in restenosis and critical limb ischemia

Tongeren, B. van

Citation


Tongeren, B. van. (2010, April 22). *Experimental therapeutic strategies in restenosis and critical limb ischemia*. Retrieved from <https://hdl.handle.net/1887/15290>

Version: Corrected Publisher's Version

License: [Licence agreement concerning inclusion of doctoral thesis in the Institutional Repository of the University of Leiden](#)

Downloaded from: <https://hdl.handle.net/1887/15290>

Note: To cite this publication please use the final published version (if applicable).



Chapter

03

Endovascular brachytherapy for the prevention of restenosis after femoropopliteal angioplasty: results of the VARA trial

J Cardiovasc Surg. 2005;46:437-443

R.B.M. van Tongeren
M.R.H.M. van Sambeek
H. van Overhagen
V.L.M.A. Coen
P.I. Schmitz,
F.M. Gescher
C.H. Wittens
R.M. Vernhout
H. van Urk
P.C. Levendag
C.M.A. Bruijninx

Abstract

Objective: Endovascular brachytherapy (EBT) has been proposed as a method to prevent restenosis. We performed a study to determine its efficacy for prophylaxis of restenosis after femoropopliteal percutaneous transluminal angioplasty (PTA).

Design: Prospective randomised multicenter study.

Methods: Patients with symptomatic stenotic or totally occluding lesions in the femoropopliteal artery were randomised to be treated with PTA plus EBT or PTA alone. In case of EBT, 14 Gy was applied by an Ir¹⁹² source to the vessel wall. Clinical examination, ankle-brachial pressure index (ABPI) and duplex ultrasound were planned after six and twelve months. The primary endpoint was significant restenosis of the treated segment at duplex ultrasound after 12 months.

Results: Fifty-three of the 60 patients who eventually met the inclusion criteria could be studied. After 12 months, restenosis rates were 44% (12/27) in the PTA group versus 35% (8/23) in the PTA + EBT group (χ^2 test, $p=0.51$). There was no difference in mandatory reintervention between the two groups. Overall, EBT resulted in an absolute risk reduction of significant restenosis of 9%, yet in patients with totally occlusive disease this reduction was 32%.

Conclusions: This study suggests an effect of EBT on the occurrence of restenosis only after PTA of occluded femoropopliteal lesions. Due to a too small number of patients analysed this difference is not statistically significant.

Background

Restenosis after percutaneous transluminal angioplasty (PTA) of the femoropopliteal artery occurs in 25% to 77% of the cases within the first year and is thereby the major limitation of the long term patency of this method of treatment.^{1,2,3} The process is mediated by intimal hyperplasia, which consists of excessive proliferation and extracellular matrix synthesis by vascular smooth muscle cells that have migrated to the site of the injury.⁴ Other components are elastic recoil and negative remodeling, involving mechanical collapse and progressive reduction of the luminal area of the treated vessel.⁵

Efforts to reduce post-PTA restenosis in the femoropopliteal tract with pharmacological agents and mechanical devices, have not proved to be successful.^{4,6}

Endovascular irradiation has been proposed as a method to prevent restenosis. Experimental studies have demonstrated its inhibiting effect on intimal hyperplasia in animal models after PTA of induced stenosis.⁷⁻¹³ Recent clinical data suggested a marked decrease of restenosis rate with endovascular brachytherapy (EBT) after PTA of coronary^{14,15} and peripheral^{16,17} arteries.

We performed a randomised multi-center trial to determine the effectiveness of endovascular brachytherapy delivered through a centering catheter.

Methods

Patients

In this multicenter study named VARA (VAscular RAdiotherapy) 8 hospitals participated. The medical ethical committee of all centers approved the trial. Informed consent was obtained from each patient. Between January 1998 and August 2000, patients with symptomatic stenotic or totally occluding lesions in the femoropopliteal artery were randomised to be treated with PTA plus EBT or PTA alone. Criteria for inclusion were: (1) age between 40-80 years, (2) claudication or non-acute critical limb ischemia (Rutherford stage 2 or more), (3) lesion in the femoropopliteal artery with a maximum length of 10 cm, (4) reference diameter of the segment 4 to 8 mm, (5) no significant hemodynamic iliac stenosis, (6) written informed consent. Patients were excluded after randomisation if the revascularization procedure was unsuccessful. Furthermore, where the maximum lesion length was 10 cm, the dilatated segment should not exceed 13 cm because of the limited length of the centering device. With longer segments centering of the brachytherapy catheter and an equal dose distribution could not be guaranteed.

Randomisation and data

Because of logistic aspects we chose to randomise patients not after PTA but subsequent to informed consent. Hereby, needless reservation of the brachytherapy suite was

prevented. The allocation of treatment was computer generated using the following stratification factors: (1) stenosis or occlusion, (2) length of the lesion: < 3cm or 3-10 cm, (3) hospital. Block size was randomised between 4-6. We used the telephone service of the trial office for the assignment of the treatment. Data were recorded and transferred to a database.

Procedure

Catheterization procedures were performed in the angiosuite with digital fluoroscopic guidance. A radio-opaque tape measure was applied to the skin. Arterial access was by means of antegrade puncture of the ipsilateral common or superficial femoral artery. A 7 French vascular sheath (Cordis, Roden The Netherlands) was inserted and a dose of 5000 IU Heparin was administered intra-arterially. The stenosis or occlusion was passed with the combination of a 5 French catheter and a 0.035 inch guidewire (Terumo, Ann Arbor Michigan U.S.A.). Subsequently the guidewire was exchanged for a 0.020 inch steerable guidewire (Boston Scientific, Watertown USA) in order to prevent dislocation during catheter exchange. The stenosis or occlusion was then dilated with a 5-7 mm PTA balloon (Wanda, Boston Scientific, Watertown USA) and control angiography was performed through the 7 French sheath. Angiographically the stenosis was considered technically successful when the residual lumen was 80% or more of the reference diameter (diameter of a normal nonstenotic segment of the superficial femoral artery).

In patients who were randomised for EBT a centering EBT-catheter (Nucletron-Veenendaal, the Netherlands) was selected and introduced over a guide wire with its tip 15 mm distal to the dilated segment. Multiple balloons realized the central position in the vessel to optimize dose distribution (Figure I). The position of the catheter tip was marked on the tape measure. The sheath was fixed to the skin, the centering catheter to the sheath and the skin. After removal of the guide wire a 5 French afterloading catheter was introduced through the centering catheter. After transport of the patient to the radiotherapy suite the position of the catheter was controlled under fluoroscopy and an additional dose of 5000 IU Heparin was administered. The catheter was connected with a computerized high-dose-rate afterloader (microSelectron, Nucletron) with an Ir¹⁹² source. Dose distribution was calculated using the angiographically measured post-PTA lumen diameter at the level of the target lesion and the length of the dilated segment with an additional 1 cm at proximal and distal edges. In order to ensure a 100% isodose 1 cm beyond both edges, the actual length the source had to traverse was the length of the dilated segment plus 1,5 cm proximal and distal. The prescribed dose was applied on the adventitia. Distance from the source axis to the adventitia was defined as the radius of the dilated vessel lumen plus 2 mm. A dose of 14 Gy was delivered at the prescribed points along the length of the balloon dilated arterial segment at a previously defined distance from the source axis. Actual irradiation was applied by the Ir¹⁹² source, which was computer-guided to traverse the entire segment in 5 mm steps moving from distal to proximal. After treatment the

centering balloon was deflated and subsequently the catheter was removed. If patients were not on antiplatelet or anticoagulant medication yet, acetylsalicyl acid (ASA) 100 mg was initiated before the intervention to be continued indefinitely.

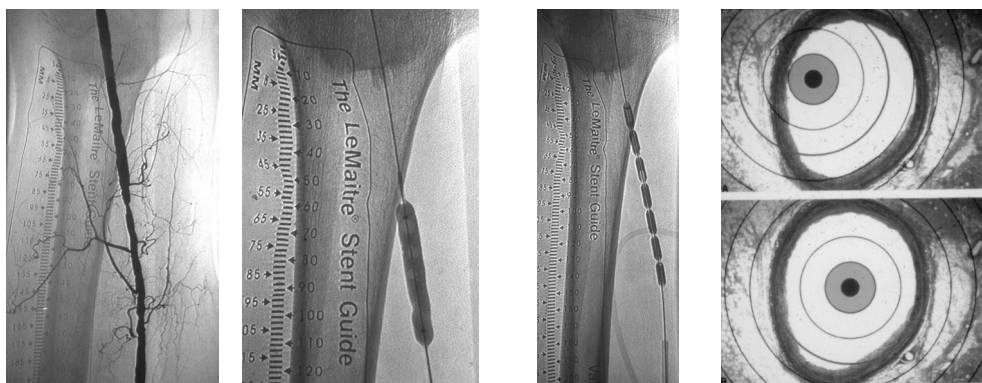


Figure 1. Pre-PTA (1), PTA (2), and positioning of centering balloon (3) to optimize dose distribution.

Follow-up

Follow-up examinations were planned after 6 and 12 months. Clinical examination, ankle-brachial pressure index (ABPI) at rest and after exercise as well as color duplex ultrasound survey of the femoropopliteal artery were performed.

Clinical conditions were determined according to the Rutherford classification. The peak systolic velocity (PSV) in the dilated segment was compared with the PSV in the normal segment above with duplex survey. Restenosis was defined as a decrease of lumen diameter of 50% or more, corresponding with a PSV-ratio of ≥ 2.5 .

Angiography was only performed on clinical indication.

Endpoints and statistical considerations

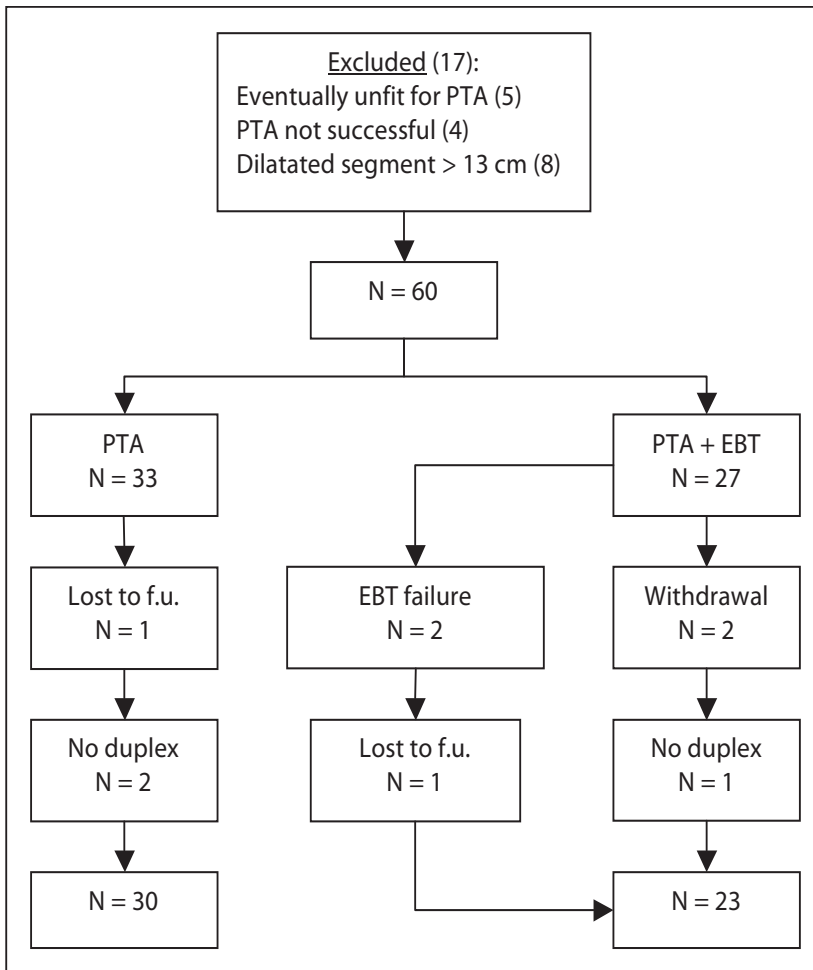
The primary endpoint was a 50% or more restenosis at duplex ultrasound of the treated segment after 12 months. Secondary effectiveness parameters included clinical patency, determined by the Rutherford classification and mandatory revascularization or (limited) amputation of the treated limb. Revascularization was defined as further PTA or bypass surgery of the target lesion. Complications of any kind were monitored together with their relation to the studied procedure.

Data were analyzed on an intention-to-radiate basis. Categorical data were compared using chi-square tests. Continuous variables were analyzed with the Mann-Whitney U-test.

With an assumed incidence of restenosis in the PTA group of 50% after 12 months and 20% in the PTA+EBT group, based on a test power of 80%, each group required 38 patients to detect a significant difference between these two restenosis percentages ($P = 0.05$, two-sided).

Figure II. Flow diagram of allocation of treatment.

42



Results

Seventeen patients were excluded for the following reasons. Five patients were eventually unfit for PTA and bypass surgery was indicated. In 4 patients PTA was technically not successful. In 8 other patients the length of the treated segment exceeded the prescribed maximum length of 13 cm and these patients were simultaneously excluded.

A total of 60 patients met the criteria for inclusion; 33 were randomised to be treated with PTA alone, 27 underwent PTA plus EBT. The irradiation procedure was technically not feasible in 2 patients because of strong kinking of the proximal part of the catheter. There were 2 withdrawals of consent. Two patients were lost to follow-up. Finally, in 3 cases only

clinical data were available, duplex survey was not performed. Eventually, information concerning the patency of the intervention could be obtained in 53 patients (Figure II).

The main reason for the limited accrual was an overestimation of the amount of suitable patients. After careful evaluation of the intake of patients well over 2½ years, without the prospect of increase, we decided to stop further recruitment. An other reason to stop the accrual was the cumbersome procedure of EBT.

All patients had a de-novo stenosis. Their baseline characteristics are listed (Table I).

Table I. Baseline clinical and radiologic characteristics.

Characteristics	PTA n=33	PTA + EBT n=27
Age	64.7 (50-85)	63.2 (43-76)
Male sex, n (%)	22 (67)	18 (63)
History of smoking, n (%)	30 (91)	24 (89)
Coexisting disease, n (%)		
Hypercholesterolemia	11 (33)	10 (37)
Diabetes mellitus	7 (21)	5 (19)
History of hypertension	14 (42)	9 (33)
Myocardial infarction	5 (15)	5 (19)
Claudication	28 (85)	24 (89)
Ischemic rest pain or tissue loss	5 (15)	3 (11)
Lesion (stenosis/occlusion), n (%)	22/11 (67/33)	19/8 (70/30)
Lesion length cm	3.2 ± 2.6	3.9 ± 3.1

Endpoints

Data produced by duplex survey regarding the 6-months patency were obtained in 52 of the 53 patients. The restenosis rate was 9/29 (31%) in the PTA group versus 5/23 (22%) in the PTA + EBT group (X^2 test, $p = 0.45$). In each group one patient died during the second follow-up period and in one case only clinical data at 12 months could be retrieved. After one year of follow-up these rates were 12/27 (44%) and 8/23 (35%) respectively in 50 patients (X^2 test, $p = 0.49$).

In addition, there was no significant difference in mandatory reintervention between the two groups. After one year 6/29 (21%) of the patients in the PTA group required revascularization of the target lesion versus 4/22 (18%) in the PTA + EBT group (X^2 test, $p = 0.82$). In the PTA group revascularization was performed by repeat PTA in 4 patients and by bypass surgery in 2 patients. In the PTA + EBT group 3 PTA and 1 bypass procedure were carried out.

The alteration of the median Rutherford scores at 6 and 12 months compared to the pre-procedural score did not differ significantly between the two groups. In the PTA group as well as the PTA+EBT group the median clinical improvement was 2 stages. (Mann-Whitney test, respectively $p = 0.75$ and $p = 0.39$). Patients who underwent a reintervention were not taken into account after 6 or 12 months of follow-up (Table II).

The impact of lesion characteristics on restenosis was compared for the PTA and the PTA+EBT group. Factors such as stenosis versus occlusion were considered. The recurrence rate in patients with stenosis did not really differ between the two treatment arms. At 12 months, the restenosis rate after PTA alone was 6/19 (32%) versus 5/16 (31%) after PTA+EBT. On the other hand, recurrence rates were 6/8 (75%) versus 3/7 (43%) respectively in patients with occlusion. No difference was found between patients with a short stenosis (< 3cm) and stenoses ranging from 3-10 cm (Table III).

It must be emphasized that the numbers of patients in both subgroups were small.

Table II. Difference in Rutherford stage, pre-procedural and at 6 months.

PTA (n)	0	1	2	3	reintervention
2 (21)	9	6	3	1	2
3 (5)	2	1	1		1
4 (2)			2		
5 (2)	1				1
Total (30)	12	7	6	1	4

PTA+EBT (n)	0	1	2	3	reintervention
2 (17)	6	7	1	1	2
3 (4)	1	1	1		1
4 (1)			1		
5 (1)			1		
Total (23)	7	8	4	1	3

Ankle-Brachial Pressure Index

The mean ABPI before PTA was 0.80 (± 0.22) in the PTA group and 0.70 (± 0.16) in the PTA+EBT group. No pressure index was performed directly after PTA. Follow-up data after 12 months demonstrated a mean increase of 0.09 (± 0.23) and 0.19 (± 0.17) respectively (Mann-Whitney test, $p = 0.13$). ABI increase after exercise did not differ significantly between the two groups either.

Peak Systolic Velocity Ratio

The same analysis was done for the PSV-ratio. The mean PSV-ratio value of the non-occluded lesions before intervention was 6.2 (± 3.7) in the PTA group and 8.2 (± 5.3) in the PTA+EBT group. At 12 months no significant difference was found. In the PTA group the mean PSV-ratio was 1.5 (± 0.91) versus 1.7 (± 0.78) in the PTA+EBT group (Mann-Whitney test, $p = 0.28$). (Values obtained after further reinterventions are excluded. In addition, in case of occlusion, a PSV-ratio cannot be assessed).

Table III. Restenosis (>50%) rate in both groups in relation to stenosis length.

	PTA (%)	PTA+EBT (%)	
<3 cm	3 (11)	3 (9)	6 (20)
3-10 cm	3 (8)	2 (7)	5 (15)
	6 (19)	5 (16)	11 (35)

Complications

In two patients allocated in the PTA + EBT group, a stent was placed because of a severe dissection with partial luminal obstruction. Both of them developed luminal narrowing at the edges of the stent. In the PTA+EBT group one patient suffered from thrombosis of the treated vessel within 24 hours. An early occlusion within days was also seen in the PTA group. We did not encounter any late thrombosis or aneurysm formation.

A clinically evident hematoma at the puncture site was noticed four times. False aneurysms were excluded by duplex survey and blood transfusion was not required. One patient suffered from neurological pain in the groin that improved spontaneously after 6 weeks. During follow-up 2 patients died. One patient died of myocardial infarction within 6 months (PTA + EBT group), another due to lung cancer after 9 months of follow-up (PTA group).

Discussion

This study does not succeed in demonstrating a significant restenosis reduction after endovascular irradiation following PTA of de novo femoropopliteal lesions. The observed absolute risk reduction was 9% after 12 months of follow-up ($p = 0.51$). Clinical parameters did not differ significantly between the two treatment arms either.

Whereas the overall effect was modest, it appeared more distinct in patients with occlusion with an absolute risk reduction of 32% in this subgroup.

At present, only two randomised controlled trials on endovascular brachytherapy in peripheral arterial disease are published. Minar et al. (Vienna-2 trial)¹⁶ reported a significant decreased overall restenosis rate after 6 months from 54% to 28% in favor of the PTA+EBT group (12 Gy) in 107 patients. Estimated restenosis rates after 12 months of 65% and 36% respectively, were also significantly different. Positive results from EBT after PTA of the superficial femoral artery were confirmed by Zehnder et al. who described a restenosis rate of 23% in the PTA + EBT group versus 42% in the PTA group after 1 year of follow-up in 100 patients.¹⁸

The differences in restenosis rates between the two treatment groups in our study were less marked. Maybe this is caused by less restenosis in the PTA group at 6 and 12 months (31% resp. 44%). Whereas the Vienna-2 trial showed an absolute risk reduction of 28% at one year, we report a reduction of only 9%. The restenosis rate after 6 months in the PTA + EBT group in our series resembles the reported 17% by Waksman.¹⁹

Several possible explanations are as follows. First, the number of patients included in our study was too little to reach significant results. Furthermore, our study contained relatively few patients with occluded lesions. The Vienna-2 study recognized this sub-group to benefit significantly of EBT, whereas patients with stenotic lesions did not. Although the numbers of patients in our sub-groups were small, the results are consistent with the results of the Vienna-2 study. In addition, another sub-group with significant profit from EBT in the Vienna-2 study were patients with treatment lengths of > 10 cm. The number of those patients in our study was small and this could be another explanation for the less distinct difference between the two treatment groups. However, the reported data about lesion length influencing the rate of restenosis after endovascular irradiation are not unequivocal. Krueger et al. did not observe any differences in diameters of vessels with irradiated lesions ≤ 2 cm or > 5 cm at 6 months in his report on the interim results of 22 patients in a randomised trial on EBT of femoropopliteal arteries.²⁰ The fact that we included only patients with a de novo lesion could also be an important factor, since EBT seems to have a stronger effect in patients with restenotic lesions.^{21,22}

Restenosis at the edge of the treated area has been described as an important late complication of intravascular irradiation, especially with the use of radioactive stents.²³ To avoid this problem, the length of the irradiated segment of the artery corresponded with the total length of PTA, with an additional 1 cm at each end as a safety margin. Nevertheless, the characteristic so called 'edge-effect' was encountered in both patients who were treated with a stent. Wolfram and Waksman reported this phenomenon in one of 33 and 35 patients respectively, after PTA followed by EBT.^{19,24} In Wolfram's study all patients underwent simultaneous stent insertion.

The major limitation of the present study is the limited number of patients. Complexity of the study and treatment design played a crucial role. Although the actual irradiation time varied from 166-577 seconds, additional brachytherapy prolonged the procedure with approximately 45 minutes due to the required transfer to a radiotherapy suite, control of the catheter position, and the dosimetry. Estimated additional costs of brachytherapy were about \$ 2500.

Regarding the recurrence rate after 12 months of 44% in the PTA group, it would have taken a restenosis rate of 10% in the PTA + EBT group to get a significant difference. The study is underpowered with the difference we found.

Even though our data might suggest a trend, where other studies demonstrated a significant positive effect, it is to be questioned whether EBT will obtain a persisting role in the treatment of vascular stenoses. As stated by Hansrani and co-workers²⁵, its practicality is as important as its effectiveness. Indeed, the technique is elaborate and the required safety measures, preferably with purpose-built suites, together with the additional devices, may result in insurmountable costs.

Moreover, data concerning the long-term safety and durability of EBT are not yet available. At present, the clinical relevance seems limited. This study suggests an effect of EBT on the occurrence of restenosis only after PTA of occluded femoropopliteal lesions.

Conclusion

This study suggests an effect of EBT on the occurrence of restenosis only after PTA of occluded femoropopliteal lesions. Due to a too small number of patients analysed this difference is not statistically significant.

Acknowledgements

VARA trial participants: *Leyenburg Hospital, The Hague*: C.M.A. Bruijninckx, F.M. Gescher, H. van Overhagen, R.B.M. van Tongeren. *Erasmus MC, Rotterdam*: V.L. Coen, P.C. Levendag, R. Kruit, M.R.H.M. van Sambeek, H. van Urk. *Isala klinieken (location Sophia), Zwolle*: P.J.G. Jörning, P.R. Timmer, B. Braakenburg. *Sint Franciscus Gasthuis, Rotterdam*: C.H. Wittens, J. van de Velde. *Jolimont Hospital, Brussels*: C. Salembier. *Academic Hospital, Vrije Universiteit Brussels*: E. Debing. *Medical Center Haaglanden (Westeinde), The Hague*: J.C.A. de Mol van Otterloo, A.C. de Vries. *Ikazia Hospital, Rotterdam*: R.U. Boelhouwer

This study was supported by a grant from the Prof. Michaël-van Vloten Fund.

References

1. Murray RR Jr, Hewes RC, White RI Jr, Mitchell SE, Auster M, Chang R, Kadir S, Kinnison ML, Kaufman SL. Long-segment femoropopliteal stenoses: is angioplasty a boon or a bust? *Radiology* 1987;162:473-476.
2. Matsi PJ, Manninen HI, Vanninen RL, Suhonen MT, Oksala I, Laakso M, Hakkarainen T, Soimakallio S. Femoropopliteal angioplasty in patients with claudication: primary and secondary patency in 140 limbs with 1-3-year follow-up. *Radiology* 1994;191:727-733.
3. Johnston KW. Femoral and popliteal arteries: reanalysis of results of balloon angioplasty. *Radiology* 1993;186:207-212.
4. Davies MG, Hagen PO. Pathobiology of intimal hyperplasia. *Br J Surg* 1994;81:1254-1269.
5. Post MJ, Borst C, Pasterkamp G, Haudenschild CC. Arterial remodeling in atherosclerosis and restenosis: a vague concept of a distinct phenomenon. *Atherosclerosis* 1995;118:(Suppl.) 115-123.
6. Herrman JP, Hermans WR, Vos J, Serruys PW. Pharmacological approaches to the prevention of restenosis following angioplasty. The search for the Holy Grail? *Drugs* 1993;46:18-52.
7. Waksman R, Robinson KA, Crocker IR, Gravanis MB, Cipolla GD, King SB. Endovascular low-dose irradiation inhibits neointima formation after coronary artery balloon injury in swine. A possible role for radiation therapy in restenosis prevention. *Circulation* 1995;91:1533-1539.
8. Wiedermann JG, Marboe C, Amols H, Schwartz A, Weinberger J. Intracoronary irradiation markedly reduces restenosis after balloon angioplasty in a porcine model. *J Am Coll Cardiol* 1994; 23:1491-1498. Wiedermann JG, Marboe C, Amols H, Schwartz A, Weinberger J. Intracoronary irradiation markedly reduces neointimal proliferation after balloon angioplasty in swine: persistent benefit at 6-month follow-up. *J Am Coll Cardiol* 1995;25:1451-1456.
9. Mazur W, Ali MN, Khan MM, Dabaghi SF, DeFelice CA, Paradis P Jr, Butler EB, Wright AE, Fajardo LF, French BA, Raizner AE. High dose rate intracoronary radiation for inhibition of neointimal formation in the stented and balloon-injured porcine models of restenosis: angiographic, morphometric, and histopathologic analyses. *Int J Radiat Oncol Biol Phys* 1996;36:777-788.
10. Hehrlein C, Gollan C, Dönges K, Metz J, Riessen R, Fehsenfeld P, von Hodenberg E, Kübler W. Low-dose radioactive endovascular tents prevent smooth muscle cell proliferation and neointimal hyperplasia in rabbits. *Circulation* 1995;92:1570-1575.
11. Laird JR, Carter AJ, Kufs WM, Hoopes TG, Farb A, Nott SH, Fischell RE, Fischell DR, Virmani R, Fischell TA. Inhibition of Neointimal Proliferation with Low-Dose Irradiation from a Beta-Particle-Emitting Stent. *Circulation* 1996; 93:529-536.
12. Verin V, Popowski Y, Urban P, Belenger J, Redard M, Costa M, Widmer MC, Rouzaud M, Nouet P, Grob E, Schwager M, Kurtz JM, Rutishauser W. Intra-arterial beta irradiation prevents neointimal hyperplasia in a hypercholesterolemic rabbit restenosis model. *Circulation* 1995;92:2284-2290.
13. Teirstein PS, Massullo V, Jani S, Popma JJ, Mintz GS, Russo RJ, Schatz RA, Guarneri EM, Steuterman S, Morris NB, Leon MB, Tripuraneni P. Catheter-based radiotherapy to inhibit restenosis after coronary stenting. *New Engl J Med* 1997;336:1697-1703.
14. King SB 3rd, Williams DO, Chougule P, Klein JL, Waksman R, Hilstead R, Macdonald J, Anderberg K, Crocker IR. Endovascular beta-irradiation to reduce restenosis after coronary balloon angioplasty. Results of the beta energy restenosis trial (BERT). *Circulation* 1998;97:2025-2030.
15. Minar E, Pokrajac B, Maca T, Ahmadi R, Fellner C, Mittlböck M, Seitz W, Wolfram R, Pötter R. Endovascular brachytherapy for prophylaxis of restenosis after femoropopliteal angioplasty. *Circulation* 2000; 102:2694-2699.
16. Schopohl B, Leirmann D, Pohlitz LJ, Heyd R, Strassmann G, Bauersachs R, Schulte-Huermann D, Rahl CG, Manegold KH, Kollath J, Bottcher HD. 192Ir endovascular brachytherapy for avoidance of intimal hyperplasia after percutaneous transluminal angioplasty and stent implantation in peripheral vessels: Years of experience. *Int J Radiat Oncol Biol Phys* 1996;36:835-840.
17. Zehnder T, von Briel C, Baumgartner I, Triller J, Greiner R, Mahler F, Do DD. Endovascular brachytherapy after percutaneous transluminal angioplasty of recurrent femoropopliteal obstructions. *J Endovasc Ther* 2003;10:304-311.
18. Waksman R, Laird JR, Jurkovitz CT, Lansky AJ, Gerrits F, Kosinski AS, Murrain N, Weintraub WS; Peripheral Artery Radiation Investigational Study (PARIS) Investigators. Intravascular radiation therapy after balloon angioplasty of narrowed femoropopliteal arteries to prevent restenosis: results of the PARIS feasibility clinical trial. *J Vasc Interv Radiol* 2001;12:915-921.

19. Krueger K, Landwehr P, Bendel M, Nolte M, Stuetzer H, Bongartz R, Zaehring M, Winnekendonk G, Gossmann A, Mueller RP, Lackner K. Endovascular gamma irradiation of femoropopliteal de novo stenoses immediately after PTA: interim results of prospective randomized controlled trial. *Radiology* 2002;224:519-528.
20. Pokrajac B, Pötter R, Maca T, Fellner C, Mittlböck M, Ahmadi R, Seitz W, Minar E. Intraarterial (192)Ir high-dose-rate brachytherapy for prophylaxis of restenosis after femoropopliteal percutaneous transluminal angioplasty: the prospective randomized Vienna-2-trial radiotherapy parameters and risk factors analysis. *Int J Radiat Oncol Biol Phys* 2000;48:923-931.
21. Hansrani M, Overbeck K, Smout J, Stansby G. Intravascular brachytherapy for peripheral vascular disease (Cochrane Review). In: *The Cochrane Library*, Issue 1, 2004. Chichester, UK: John Wiley & Sons.
22. Albiero R, Nishida T, Adamian M, Amato A, Vagheti M, Corvaja N, Di Mario C, Colombo A. Edge restenosis after implantation of high activity (32)P radioactive beta-emitting stents. *Circulation* 2000;101:2454-2457.
23. Wolfram RM, Pokrajac B, Ahmadi R, Fellner C, Gyöngyösi M, Haumer M, Bucek R, Pötter R, Minar E. Endovascular brachytherapy for prophylaxis against restenosis after long-segment femoropopliteal placement of stents: initial results. *Radiology* 2001;220:724-729.
24. Hansrani M, Overbeck K, Smout J, Stansby G. Intravascular brachytherapy: a systematic review of its role in reducing restenosis after endovascular treatment in peripheral arterial disease. *Eur J Vasc Endovasc Surg* 2002;24:377-382.