



Universiteit  
Leiden  
The Netherlands

## Pathogenic role of (S)IgA in IgA nephropathy

Oortwijn, B.D.

### Citation

Oortwijn, B. D. (2007, January 17). *Pathogenic role of (S)IgA in IgA nephropathy*. Retrieved from <https://hdl.handle.net/1887/8783>

Version: Corrected Publisher's Version

License: [Licence agreement concerning inclusion of doctoral thesis in the Institutional Repository of the University of Leiden](#)

Downloaded from: <https://hdl.handle.net/1887/8783>

**Note:** To cite this publication please use the final published version (if applicable).

## Demonstration of secretory IgA in kidneys of patients with IgA nephropathy

Beatrijs D. Oortwijn<sup>1</sup>, Maria Pia Rastaldi<sup>3</sup>, Anja Roos<sup>1,2</sup>, Deborah Mattinzoli<sup>3</sup>, Mohamed R. Daha<sup>1</sup>, Cees van Kooten<sup>1</sup>

<sup>1</sup>Department of Nephrology and <sup>2</sup>Clinical Chemistry, Leiden University Medical Center, Leiden, The Netherlands <sup>3</sup>Renal Immunopathology Laboratory. Fondazione D'Amico per la Ricerca sulle Malattie Renali, Associazione Nuova Nefrologia, c/o San Carlo Borromeo Hospital, Milano, Italy

### Summary

Recently we reported a possible role for secretory IgA (SIgA) in IgA nephropathy (IgAN), as suggested by increased serum levels in patients with active disease and accumulation of SIgA in a glomerular eluate. Therefore, we attempted to find support for these findings by analysis of the presence of SIgA in biopsies of IgAN patients. Renal biopsies of 26 patients with biopsy-proven IgAN were analyzed for the presence of SIgA. In 15 % clear deposition of SIgA was demonstrable. The presence of SIgA in these biopsies showed a strong correlation with deposition of MBL and C4d. It has been previously documented that patients with MBL deposits have more severe renal injury. Therefore, these data provide additional evidence for a pathogenic role for SIgA in IgA nephropathy.

*Submitted*

## INTRODUCTION

Primary IgA nephropathy (IgAN) is the most common form of primary glomerulonephritis worldwide. The hallmark of this disease is deposition of IgA in the glomerular mesangium, together with markers of complement activation (1-3). It is generally thought that deposits of IgA consist of IgA1 which is mostly polymeric (4). The composition of polymeric IgA in serum is highly diverse and may include CD89/IgA complexes, dimeric IgA, IgA immune complexes and secretory IgA (SIgA) (5-7).

SIgA is the dominant immunoglobulin in external mucosal secretions like oral, respiratory and intestinal cavities, and is often characterized as a component of the immune systems' first line defense against pathogens (8). Next to its presence in mucosal secretions, small amounts of SIgA can also be found in human serum (7,9,10). Noteworthy, increased serum levels of SIgA have been reported in various diseases (11-13), and are associated with more hematuria in IgAN patients (7). Moreover, polymeric serum IgA of patients with IgAN contains higher SIgA concentrations as compared to healthy controls (14).

Glomerular IgA deposition is associated with activation of the complement system (15), involving the alternative pathway and the lectin pathway of complement (16). Recent studies indicate that deposition of MBL, one of the recognition molecules of the lectin pathway of complement, in a subpopulation of IgAN patients is associated with a more severe renal injury (16,17), compatible with the observation that MBL bind to polymeric IgA (18).

The aim of the present study was to investigate whether SIgA can be demonstrated in biopsies from patients with IgA nephropathy. The results show that SIgA can be found in a subpopulation of IgAN patients, and that presence of SIgA is associated with the presence of MBL and C4d.

## MATERIAL AND METHODS

### Patients and biopsies

Renal biopsies were selected from patients with IgA nephropathy of whom a renal biopsy was taken between January 2001 and December 2003. Patients were selected when adequate tissue was obtained for diagnostics (at least 8 glomeruli in light microscopy sections; complete immunohistology and electron microscopy examination), and when sufficient frozen material was available for additional staining after immunodiagnosis (at least 6 glomeruli in at least 15 (5µm thick) tissue sections). Cases with Henoch-Schönlein purpura, systemic lupus erythematosus, liver cirrhosis or other systemic diseases were excluded. In total, 26 biopsies were selected for evaluation.

Among selected patients, 77 % were male and 23 % females. Creatinine clearance was calculated according to the Cockcroft formula (range 16-130 ml/min).

### Immunofluorescence

For immunofluorescence stainings, unfixed renal tissue was embedded in OCT compound (Sakura Tissue-tek, Bayer), snap-frozen in a mixture of isopentane and dry-ice and stored at -80°C. Subsequently, 5µm sections were placed on slides and stored at -20°C until

immunostaining.

We used mouse monoclonal antibodies directed against the following molecules: MBL (mAb 3E7, kindly provided by Prof. Fujita, Fukushima, Japan (27)), and secretory component (SC) (mAb NI194-4 from Nordic (7)). Rabbit polyclonal antibodies were applied for detection of IgA (FITC-labeled anti-human IgA, Dako), C3 (FITC-labeled anti-human C3c, Dako) and C4d (Biomedica (28)). For indirect immunofluorescence, after fixation in cold acetone, tissues were incubated sequentially with the primary antibody and the proper fluorescently labeled secondary antibody (Alexa Fluor 488-conjugated goat anti-mouse Ig or Alexa Fluor 546-conjugated goat anti-mouse Ig, Molecular probes). Slides were finally mounted with anti-fading aqueous mounting medium (Fluorsave, Calbiochem).

### Statistical analysis

Data were compared between IgAN patients showing positive and negative glomerular staining of SIgA, respectively. Frequency analysis was performed using the Fisher exact test. Other comparisons were evaluated using the Mann Whitney U test. Differences were considered statistically significant when P was below 0.05.

**Table 1: Histological data from IgA nephropathy patients**

Parameter	SIgA neg (N= 22)	SIgA pos (N= 4)	P
Intense mesangial proliferation (% of cases)	32	75	0.264
Extracapillary proliferation present (% of cases)	27	50	0.543
Global sclerosis (% of glomeruli ; median)	13	23	0.943
Segmental sclerosis (% of glomeruli ; median)	3.5	8	0.972
Interstitial infiltration (0-3 scale scoring: median)	1	2	0.319
Interstitial fibrosis (0-3 scale scoring: median)	1	1	0.831
Vessel lesions present (% of cases)	45	25	0.614
C3 present (% of cases)	91	50	0.0987
C4d present (% of cases)	4.5	100	0.0003
Glomerular MBL staining present (% of cases)	4.5	100	0.0003

SIgA-negative cases and SIgA-positive cases are defined on basis of glomerular staining.

## RESULTS

Immunofluorescence staining for SIgA was performed in renal biopsies from 26 IgAN patients. Glomerular SIgA positivity was observed in a mesangial pattern in 4 biopsies (15 %, Figure 1), whereas glomeruli in 22 biopsies were negative.

Next we examined the presence of molecules of the complement system (Table 1). In line with our previous study we observed that 19 % were positive for MBL and C4d (16). We observed a strong association between the presence of SIgA and the presence of MBL (P = 0.0003) and C4d, respectively (P = 0.0003).

Based on the presence (15 %) or absence (85 %) of glomerular SIgA Two IgAN

patient groups were defined and further characterized. SIgA-positive and negative cases had a similar male/female distribution and no difference in renal function (Table 2). There was a clear trend towards a younger age at time of renal biopsy for patients with positive glomerular SIgA staining as compared to negative SIgA staining ( $p=0.0596$ , Table 2). There was also a trend towards more severe mesangial proliferation in SIgA-positive biopsies as compared to SIgA-negative biopsies (Table 1). This is in line with our previous observation that deposition of MBL is associated with more severe renal injury, characterized by more intense mesangial and extracapillary proliferation, glomerular sclerosis and interstitial damage (16).

**Table 2: Clinical and laboratory data from IgA nephropathy patients**

Parameter	SIgA neg (N= 22)	SIgA pos (N= 4)	P
Age at renal biopsy (Years; median)(range)	33 (21-57)	26.5 (24-31)	
Female gender (%)	27	0	0.5425
Proteinuria (gram/24hr; median)	1.4	2.1	0.2864
Macroscopic hematuria present (% of cases)	37	25	0.6603
Serum creatinine ( $\mu$ mol/l; median)	1.3	1.4	0.4553
Creatinine clearance (ml/min; median)	53	71.5	0.9151
Serum IgA (mg/ml)	2.4	2.49	0.6698

SIgA-negative cases and SIgA-positive cases are defined on basis of glomerular staining. All data were obtained at the time of renal biopsy

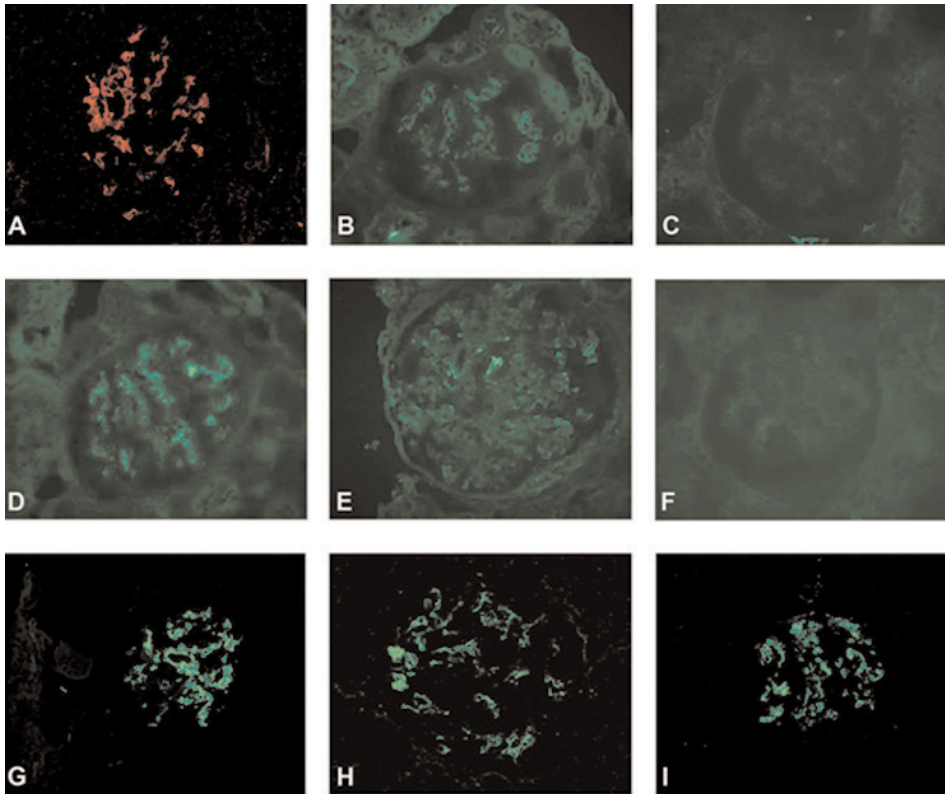
## DISCUSSION

The present study provides further evidence for a possible pathogenic role for SIgA in IgAN. We demonstrate glomerular deposition of SIgA in biopsies of a sub-population of IgAN patients. Furthermore, there was a strong association between glomerular SIgA staining and the presence of MBL and C4d, suggesting activation of the lectin pathway of complement in cases with SIgA deposition.

Deposition of IgA in the mesangial area is the hallmark of patients with IgAN and it is generally thought that this deposition drives a local inflammatory response. Previous research has concentrated on quantitative and qualitative differences of IgA deposited in the kidney. It has been proposed that IgA in renal deposits is mostly high MW of nature and might contain differences in glycosylation which might affect receptor interaction or effector functions. We now show that in a subset of patients SIgA can be demonstrated in the renal biopsies, in line with our previous investigation of a renal eluate (7). Deposition of SIgA in patients with IgAN has not been widely documented, although it was observed in a recent study (19).

Generation of secretory IgA (SIgA) is a specific process taking place at mucosal surfaces (20). It has been reported that SIgA adheres selectively to microfold (M) cells irrespective of their antigen-binding specificity (21,22), followed by its transport across the epithelium and targeting of dendritic cells (DC) (23,24). In vitro it has been demonstrated that DC can bind and endocytose SIgA (25). Probably not all

SIgA is internalized by DC and this SIgA may end up in the circulation. Indeed, small amounts of SIgA have also been found in human serum (9,10). Moreover, increased serum levels of SIgA have been reported in various diseases (11-13) indicating that SIgA may be a marker of clinical interest. We hypothesize that after mucosal challenge the production of SIgA at mucosal sites is increased. This could potentially lead to increased serum SIgA concentrations (7) and thereby, via a presently undefined mechanism, lead to glomerular deposition of SIgA.



**Figure 1. Glomerular SIgA deposition in IgAN patients.**

Renal tissue from patients with IgAN was stained for the presence of SIgA (A, B and C), MBL (D, E and F), IgA (G), C4d (H) and C3 (I). Representative images are shown. Renal tissues are derived from different patients who showed positive (A and B) and negative staining (C) for SIgA and positive (D and E) and negative staining (F) for MBL. All patients were positive for IgA (G). A subpopulation of patients was positive for C4d (H) and C3 (I).

Earlier studies have shown that the carbohydrate moieties on SIgA are different as compared to serum IgA (26). Furthermore, it was shown that MBL can interact with SIgA upon conformational change under acid conditions. This suggests that disruption of the non-covalent interactions between secretory component and the IgA heavy chain can lead to MBL binding and subsequently complement activation via the lectin pathway. The data from the present study suggest that in the glomeruli of a subpopulation of IgAN patients, the deposition of SIgA may lead to unmasking

the heavy chain of IgA of SIgA leading to MBL binding and complement activation.

Recently, it has been described that MBL deposition in glomeruli is associated with more severe renal disease (16). In the present study we show a strong co-deposition of SIgA and MBL, suggesting SIgA as a strong cofactor. Furthermore, more hematuria was observed in patients with higher concentrations of SIgA in serum (7). Moreover, after elution of isolated glomeruli from a patient with IgAN a 120-fold accumulation of SIgA in the glomeruli was observed. In the present study we provide additional evidence for a pathogenic role of SIgA in a subpopulation of patients with IgA nephropathy.

### Acknowledgements

The authors thank Prof. Fujita (Fukushima, Japan) for the supply of valuable reagents. This work was financially supported by the Dutch Kidney Foundation (BDO: C99.1822; AR: PC95).

### REFERENCES

1. Berger J, Hinglais N: Les depots intercapillaires d'IgA-IgG. *J Urol Nephrol (Paris)* 74:694-695, 1968
2. Donadio JV, Grande JP: IgA nephropathy. *N Engl J Med* 347:738-748, 2002
3. Feehally J: IgA nephropathy--a disorder of IgA production? *QJM* 90:387-390, 1997
4. Tomino Y, Sakai H, Miura M et al.: Detection of polymeric IgA in glomeruli from patients with IgA nephropathy. *Clin Exp Immunol* 49:419-425, 1982
5. Novak J, Julian BA, Tomana M et al.: Progress in molecular and genetic studies of IgA nephropathy. *J Clin Immunol* 21:310-327, 2001
6. van der Boog PJ, van Kooten C, de Fijter JW et al.: Role of macromolecular IgA in IgA nephropathy. *Kidney Int* 67:813-821, 2005
7. Oortwijn BD, van der Boog PJ, Roos A et al.: A pathogenic role for secretory IgA in IgA nephropathy. *Kidney Int* 69:1131-1138, 2006
8. Kerr MA: The structure and function of human IgA. *Biochem J* 271:285-296, 1990
9. Thompson RA, Asquith P, Cooke WT: Secretory IgA in the serum. *Lancet* 2:517-519, 1969
10. Delacroix DL, Vaerman JP: A solid phase, direct competition, radioimmunoassay for quantitation of secretory IgA in human serum. *J Immunol Methods* 40:345-358, 1981
11. Mole CM, Renoult E, Bene MC et al.: Serum secretory IgA and IgM and free secretory component in IgA nephropathy. *Nephron* 71:75-78, 1995
12. Seilles E, Rossel M, Vuitton DA et al.: Serum secretory IgA and secretory component in patients with non-cirrhotic alcoholic liver diseases. *J Hepatol* 22:278-285, 1995
13. Rostoker G, Terzidis H, Petit-Phar M et al.: Secretory IgA are elevated in both saliva and serum of patients with various types of primary glomerulonephritis. *Clin Exp Immunol* 90:305-311, 1992
14. Oortwijn BD, Roos A, Royle L et al. Differential glycosylation of polymeric and monomeric IgA: a possible role in glomerular inflammation in IgA nephropathy. *J Am Soc Nephrol* . 2006 in press
15. Floege J, Feehally J: IgA nephropathy: recent developments. *J Am Soc Nephrol* 11:2395-2403, 2000
16. Roos A, Rastaldi MP, Calvaresi N et al.: Glomerular activation of the lectin pathway of comple

- 
- ment in IgA nephropathy is associated with more severe renal disease. *J Am Soc Nephrol* 17:1724-1734, 2006
17. Matsuda M, Shikata K, Wada J et al.: Deposition of mannan binding protein and mannan binding protein-mediated complement activation in the glomeruli of patients with IgA nephropathy. *Nephron* 80:408-413, 1998
  18. Roos A, Bouwman LH, Gijlswijk-Janssen DJ et al.: Human IgA activates the complement system via the mannan-binding lectin pathway. *J Immunol* 167:2861-2868, 2001
  19. Obara W, Iida A, Suzuki Y et al.: Association of single-nucleotide polymorphisms in the polymeric immunoglobulin receptor gene with immunoglobulin A nephropathy (IgAN) in Japanese patients. *J Hum Genet* 48:293-299, 2003
  20. Mostov KE: Transepithelial transport of immunoglobulins. *Annu Rev Immunol* 12:63-84, 1994
  21. Mantis NJ, Cheung MC, Chintalacheruvu KR et al.: Selective adherence of IgA to murine Peyer's patch M cells: evidence for a novel IgA receptor. *J Immunol* 169:1844-1851, 2002
  22. Weltzin R, Lucia-Jandris P, Michetti P et al.: Binding and transepithelial transport of immunoglobulins by intestinal M cells: demonstration using monoclonal IgA antibodies against enteric viral proteins. *J Cell Biol* 108:1673-1685, 1989
  23. Neutra MR: Current concepts in mucosal immunity. V Role of M cells in transepithelial transport of antigens and pathogens to the mucosal immune system. *Am J Physiol* 274:G785-G791, 1998
  24. Favre L, Spertini F, Corthesy B: Secretory IgA possesses intrinsic modulatory properties stimulating mucosal and systemic immune responses. *J Immunol* 175:2793-2800, 2005
  25. Heystek HC, Moulon C, Woltman AM et al.: Human immature dendritic cells efficiently bind and take up secretory IgA without the induction of maturation. *J Immunol* 168:102-107, 2002
  26. Royle L, Roos A, Harvey DJ et al.: Secretory IgA N- and O-Glycans Provide a Link between the Innate and Adaptive Immune Systems. *J Biol Chem* 278:20140-20153, 2003
  27. Matsushita M, Takahashi A, Hatsuse H et al.: Human mannose-binding protein is identical to a component of Ra-reactive factor. *Biochem Biophys Res Commun* 183:645-651, 1992
  28. Bohmig GA, Exner M, Habicht A et al.: Capillary C4d deposition in kidney allografts: a specific marker of alloantibody-dependent graft injury. *J Am Soc Nephrol* 13:1091-1099, 2002
-



