



Universiteit
Leiden
The Netherlands

Optimal timing of pulmonary valve replacement in tetralogy of Fallot

Straten, A. van

Citation

Straten, A. van. (2008, December 17). *Optimal timing of pulmonary valve replacement in tetralogy of Fallot*. Retrieved from <https://hdl.handle.net/1887/13393>

Version: Corrected Publisher's Version

License: [Licence agreement concerning inclusion of doctoral thesis in the Institutional Repository of the University of Leiden](#)

Downloaded from: <https://hdl.handle.net/1887/13393>

Note: To cite this publication please use the final published version (if applicable).

Magnetic Resonance Imaging to Assess the Hemodynamic Effects of Pulmonary Valve Replacement in Adults Late after Repair of Tetralogy of Fallot

HW Vliegen

A van Straten

A de Roos

AA Roest

PH Schoof

AH Zwinderman

J Ottenkamp

EE van der Wall

MG Hazekamp

Circulation. 2002;106:1703-7

Abstract

Background

Pulmonary regurgitation (PR) late after total correction for tetralogy of Fallot may lead to progressive right ventricular (RV) dilatation and an increased incidence of severe arrhythmias and sudden death. Timing of pulmonary valve replacement (PVR) is subject to discussion since the effect of PVR on RV function in adults is unclear.

In this study, MRI was used to assess the effect of PVR on RV function and PR. Clinical improvement was established by means of the NYHA classification

Methods

26 Adult patients were included. Cardiac MRI was performed at a median of 5.1 ± 3.4 months before and 7.4 ± 2.4 months after PVR. Mean preoperative PR was $46 \pm 10\%$ (range 25-64%).

Results

After PVR, 20 out of 26 patients (77%) showed no residual PR, 5 patients mild residual PR and one patient moderate. RV end-diastolic volume (RV-EDV) decreased from 305 ± 87 ml to 210 ± 62 ml ($p < 0.001$) and RV end-systolic volume (RV-ESV) decreased from 181 ± 67 ml to 121 ± 58 ml ($p < 0.001$). No significant change was found in RV-EF (42 vs. 42%). However, RV-EF corrected for regurgitations and shunting increased from $25.2 \pm 8.0\%$ to $43.3 \pm 13.7\%$ ($p < 0.001$). Mean New-York Heart Association (NYHA) functional class improved from 2.0 to 1.3 ($p < 0.001$).

Conclusion

In adult patients with PR and RV dilatation, late after total correction of tetralogy of Fallot, MRI measurements show remarkable haemodynamic improvement of RV function after PVR and improvement of functional class. We therefore advocate a less restrictive management concerning PVR in these patients.

Introduction

Tetralogy of Fallot (TOF) is the most common form of cyanotic congenital heart disease¹, with a prevalence between 0.26 and 0.8 per 1000 live births². Total repair for tetralogy of Fallot (TOF) has been available for fifty years³, with a favorable outcome in most patients. Now we are faced with an increasing number of patients who present with symptomatic right ventricular (RV) failure and/or (supra)ventricular arrhythmias. In these patients, there is a risk for sudden death^{4,5}. Usually, These long-term adverse effects are the result of long-standing pulmonary regurgitation (PR)⁶. In the past it was thought that PR in Fallot patients was rather unharmed. However, precise measurements of RV volumes using magnetic resonance imaging (MRI) have visualized the important enlargement of the RV in patients with severe PR⁷.

Pulmonary valve replacement (PVR) can be performed electively with little risk and may improve symptoms of RV failure and provides excellent mid-term survival⁸⁻¹⁰. Previous echocardiographic measurements of RV dimensions in children and adolescents showed a decrease in end-diastolic volume (EDV) and end-systolic volume (ESV) after PVR¹¹⁻¹³. However, in adults, radionuclide angiography (RNA) measurements showed no effects of PVR on RV volumes and ejection fraction (EF)¹⁴.

To date, MRI is the gold standard for evaluation of RV volumes, and quantification of degree of pulmonary and tricuspid regurgitation (TR)¹⁵⁻¹⁸. The purpose of this study was to determine the haemodynamic and clinical effects of PVR on RV function in adults late after repair of tetralogy of Fallot.

Methods

Study Group

Between 1993 and 2002 a total of 65 patients underwent PVR for PR late after correction of TOF. Since 1997, 26 consecutive adult patients late after repair of TOF, who underwent PVR and had been evaluated preoperatively with MRI, were included. All patients were re-evaluated with MRI 6-12 months after the operation, according to our clinical protocol.

Table 5.1. Demographic and surgical characteristics: total cohort of patients (n=26).

| Variable | (n=26) |
|---|----------|
| Male sex | 15 (58) |
| Previous palliative shunt | |
| Blalock Taussig | 7 (27) |
| Waterston | 3 (12) |
| Potts | 1 (4) |
| Median age at initial repair, y | 5.0±4.2 |
| Type of repair | |
| No patch | 10 (38) |
| RV patch | 6 (23) |
| Transannular path | 10 (38) |
| Median age at PVR, y | 29.2±9.0 |
| Median duration of follow-up, mo | 7.4±2.4 |
| Indications for PVR | |
| Moderate PR (20% to 40%) | 11 (42) |
| Severe PR (>40%) | 15 (58) |
| Severe RV dilatation (RV/LV>2) | 13 (50) |
| Poor validity | 10 (38) |
| Co-indications for PVR | |
| Supraventricular arrhythmias | 2 (8) |
| Ventricular arrhythmias | 1 (4) |
| Prolonged QRS complex (>180 msec) | 7 (27) |
| Residual VSD | 3 (12) |
| Additional procedure | |
| Resection of infundibulum | 2 (8) |
| Tricuspid valve repair | 4 (15) |
| Closure of VSD | 3 (12) |
| Closure of atrial septal defect (type II) | 1 (4) |

Values are median±SD or n (%).

Patient characteristics

Patients characteristics are shown in table 5.1. Median age at total repair was 5.0 ± 4.2 years (mean 5.7, range 0.4 to 21.0 years). Eleven patients (42%) underwent a palliative procedure prior to repair. A trans-annular patch had been used in 10 patients. In 20 patients RV end-diastolic volumes could be measured both before and after PVR, and PR could be measured in 25 patients. Ventricular volumes were corrected for body surface

area (BSA). Left ventricular volumes and flow through the tricuspid valve were also measured. Furthermore, functional class was assessed before and after PVR.

Indication for PVR

Patients with residual lesions after repair of TOF were considered for PVR when objective evidence of important right ventricular dilatation was found, with or without deterioration of functional class and/or the presence of tricuspid regurgitation (TR) or (supra)ventricular arrhythmias^{9,19}. All patients had moderate, or severe pulmonary regurgitation and 13 (50%) had severe RV dilatation, defined as RV-EDV more than double the LV-EDV. A history of (supra)ventricular arrhythmias was present in 3 (12%) patients before PVR.

Diminished functional class, assessed by the NYHA classification, was part of the indication in 10 (38%) patients (NYHA class II or more). Two patients without reduced functional class had moderate PR in combination with severe RV dilatation of more than 120 ml/m², a residual VSD and QRS duration of more than 180 msec.

Co-indications included the presence of (supra)ventricular arrhythmias, prolonged QRS-duration (>180 msec) and a residual ventricular septal defect (VSD).

Surgical Procedures

PVR was performed at a median age of 29.2 ± 9.0 years (range 17.0 to 45.6 years). Additional procedures performed at the time of PVR are listed in Table 5.1. All patients were operated with normothermic or moderately hypothermic cardiopulmonary bypass. The majority of pulmonary valve insertions were performed on beating heart. Aortic cross-clamping was dependent on the surgeon's preference or on concomitant procedures. Residual VSDs were closed in 3 patients. De Vega tricuspid annuloplasty was performed in 4 patients. Cryopreserved pulmonary homografts were used in all patients. Homografts were inserted in the orthotopic pulmonary position with one proximal and one distal end-to-end running suture after longitudinally opening the proximal pulmonary artery and slightly extending this incision if necessary across the former pulmonary annulus. Calcified outflow tract patch material was resected as much as possible.

Magnetic Resonance Imaging

MRI studies were performed with a 1.5 Tesla system (NT15 Gyroscan, Philips Medical Systems, Best, The Netherlands).

Short axis gradient echo images

A multiphase, ECG triggered, multishot echoplanar gradient echo (GRE) technique was used to acquire short axis images. Images were acquired during breath holds, each lasting 10 to 15 seconds. The scout images were used to acquire 10-12 sections that covered both ventricles in the transverse plane; slice thickness was 10 mm with a 0.8-1.0-mm section gap. The flip angle was 30°, and the echo time was 5-10 msec. Eighteen to 25 frames resulted in a temporal resolution of 22-35 msec. A field of view of 350 to 400 mm was used depending on the size of the patient.

Quantitative flow measurements

Velocity mapping was performed with the use of a velocity-encoded phase contrast sequence. A section thickness of 8 mm and a field of view of 300 x 300 mm were used. The flip angle was 20°, and the echo time was 12 msec. For velocity mapping of the pulmonary artery, sagittal and coronal spin-echo scout images were used to construct a double oblique plane perpendicular to the vessel. Pulmonary flow measurements were performed halfway between the pulmonary valve and the bifurcation or approximately 2 cm proximal to the bifurcation when no pulmonary valve was present. For velocity mapping of the flow through the tricuspid valve, 2- and 4-chamber (GRE) images were used to construct a parallel plane through the valve. The sequence was encoded for through-plane velocities up to 200 cm/s. With the use of retrospective gating, 30 to 40 time frames evenly distributed over the cardiac cycle were constructed, resulting in a temporal resolution of 25-35 msec. A 128 x 128 matrix was interpolated to a display matrix of 256 x 256.

Post-processing

All images were quantitatively analyzed on an IPC workstation (SUN Microsystems Inc., Mountain View, California, USA) using two software packages, which were developed at our institution. Velocity maps were analyzed using the FLOW analytical software package²⁰⁻²².

Flow curves were obtained for flow in the main pulmonary artery and just distal from the tricuspid valve. Regurgitation fraction was calculated by the formula: regurgitant flow / systolic forward flow * 100. The transverse GRE sequences of the ventricles were analyzed using the MASS software (20-22). The EDV was assessed at the phase with the

largest ventricular diameters and the ESV was assessed at the phase with the smallest ventricular diameters. Endocardial contours of both right and left ventricles were drawn for all slices within these two phases. RV Stroke volume (SV) was calculated by deducting the ESV from the EDV and RV-EF was defined as $(RV-SV * 100) / RV-EDV$. RV-EF was then corrected for regurgitation of the tricuspid and pulmonary valves, as well as intracardiac shunts by dividing the net pulmonary flow by the RV-EDV: $RV-EF_{cor} = \text{net pulmonary flow (pulmonary forward flow – regurgitant flow)} / RV-EDV$.

Statistical Analysis

The data was analyzed using SPSS for Windows (version 10.0, SPSS, Chicago, Illinois). The paired t-test was used to evaluate pre- and postoperative data.

Table 5.2. *Clinical and MRI data before and after pulmonary valve replacement.*

| Variables | Before PVR | After PVR | P |
|---------------------------------|------------|------------|--------|
| MRI | | | |
| PR, % (n=25) | 45.5±10.2 | 4.0±7.8 | <0.001 |
| PR, mL (n=25) | 59.9±26.4 | 3.7±6.6 | <0.001 |
| TR, % (n=22) | 4.2±6.9 | 2.6±3.9 | 0.23 |
| RV-EDV, mL (n=20) | 305.4±87.0 | 210.1±62.0 | <0.001 |
| RV-EDV-I, mL/m ² | 166.8±40.3 | 114.3±35.0 | <0.001 |
| RV-ESV, mL (n=19) | 181.0±67.4 | 121.0±58.3 | <0.001 |
| RV-ESV-I, mL/m ² | 99.0±35.9 | 66.3±35.2 | <0.001 |
| LV-EDV, mL (n=20) | 156.7±52.8 | 160.2±36.2 | 0.69 |
| LV-EDV-I, mL/m ² | 86.4±28.6 | 86.6±17.0 | 0.98 |
| LV-ESV, mL (n=20) | 70.4±31.4 | 71.1±20.2 | 0.90 |
| LV-ESV-I, mL/m ² | 38.8±16.8 | 38.6±10.3 | 0.82 |
| RV-EF, % (n=19) | 41.7±9.7 | 42.1±11.1 | 0.81 |
| RV-EF _{cor} , % (n=18) | 25.2±8.0 | 43.3±13.7 | <0.001 |
| Clinical | | | |
| NYHA (n=26) | 2.0±0.6 | 1.3±0.5 | <0.001 |

Values are mean±SD.

Results

PVR was performed successfully in 26 consecutive patients, with no perioperative mortality. One patient died suddenly 18 months after uncomplicated pulmonary valve replacement. No autopsy was performed.

Cardiac MRI was performed in all patients with a median of 5.1 ± 3.4 months before PVR and repeated at a median of 7.4 ± 2.4 months after the operation. Table 5.2 shows MRI and clinical data before and after PVR. Before PVR, all patients had at least moderate PR. PR decreased from a mean of $46 \pm 10\%$ to $4 \pm 8\%$ ($p < 0.001$). Twenty patients had no residual PR; mild residual PR was seen in 5 patients, while one patient had moderate residual PR, this patient did not show reduction of right ventricular volumes after operation. Before PVR, mean indexed RV-EDV (RV-EDV-I) was 167 ± 40 ml/m² (range 113 to 289 ml/m²). After the operation mean RV-EDV-I was 114 ± 35 ml/m² (range 58 to 243 ml/m²). Mean RV-ESV-I decreased from 99 ± 36 ml/m² (range 52 to 192 ml/m²) to 66 ± 35 ml/m² (range 25 to 210 ml/m²) resulting in an average of both volumes around 30% ($p < 0.001$). Left ventricular volumes did not change significantly after operation, indicating the relative reliability of the measurements (figure 5.1).

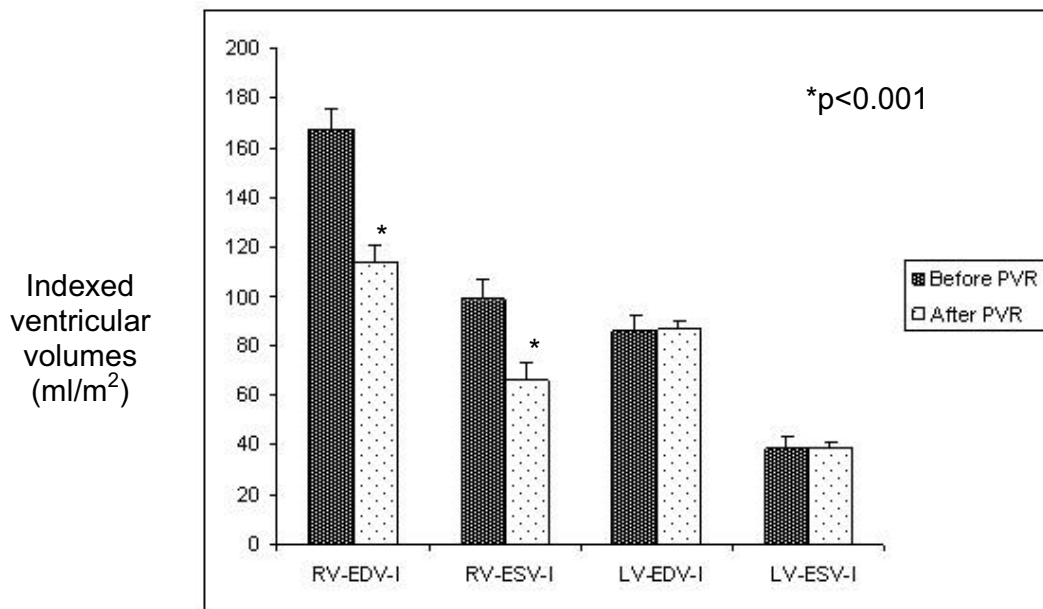


Figure 5.1. Ventricular volumes before and after pulmonary valve replacement in 26 patients. Note the significant decrease of right ventricular volumes in contrast to the unchanged left ventricular volumes.

Following PVR, RV-EF did not change significantly, 42 vs. 42%, while RV-EF_{cor} increased dramatically from 25 ± 8% to 43 ± 14% (p<0.001). Average functional class was calculated before and after PVR according to the NYHA class. Before PVR the average functional class was 2.0 ± 0.6 while after PVR functional class improved to 1.3 ± 0.5 (p<0.001) (figure 5.2). Fourteen patients had functional class I after operation. In 12 patients no normalization of functional class was observed. In the latter group, the mean preoperative functional class was 2.3 ± 0.7 compared to a mean functional class of 1.8 ± 0.5 in the group with normalization of functional class (p=0.01). Normalization of functional class was not obtained in patients with preoperative functional class III.

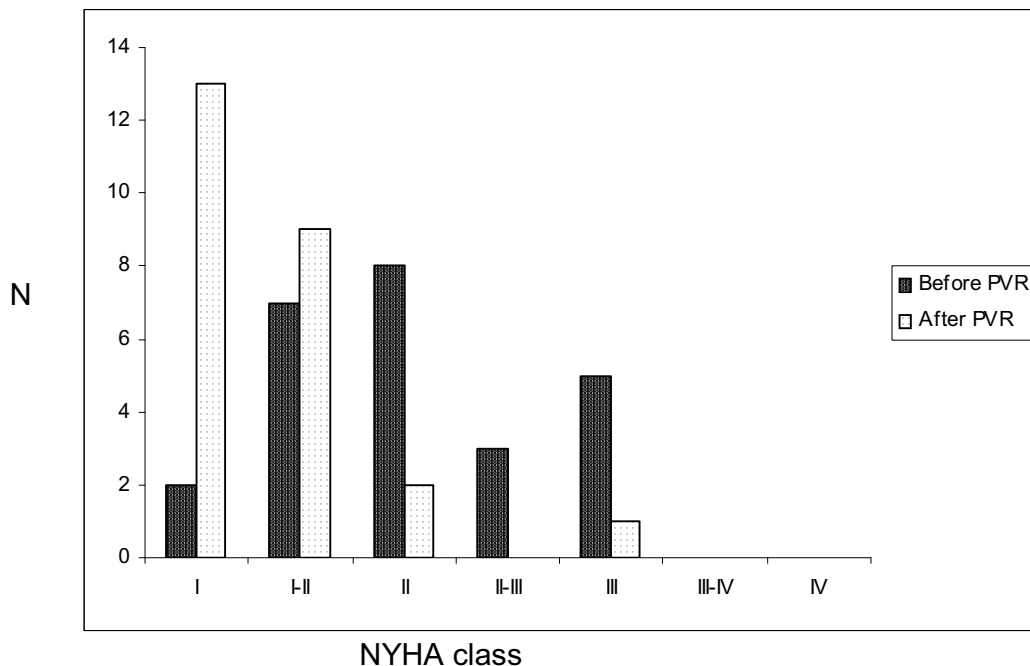


Figure 5.2. Distribution of functional class before and after pulmonary valve replacement. Note that after PVR, 13 of 26 patients had a normal functional class (NYHA class I).

Discussion

To our knowledge this is the first study using MRI to show improvement of RV function after PVR late after total repair for Tetralogy of Fallot, in patients with moderate to

severe pulmonary regurgitation and right ventricular dilatation. In our study, 25 out of 26 patients (96%) had no or mild residual PR and a reduction of RV volumes of 30% was observed. Furthermore an improvement of functional class was reached; most patients with symptoms before surgery were symptom free after PVR. We also found a dramatic improvement of RV function as expressed by the right ventricular ejection fraction corrected for regurgitation, and the right ventricular end-systolic volume.

The reduction of the volume of the dilated right ventricle is in accordance with the results of a number of previous studies that investigated the effect of PVR in children and adolescents. Bove et al.¹³, found after PVR in a group of patients with a mean age of 14.6 years, a reduction in RV volume (measured with M-mode Echo). Warner et al.¹² studied a group of patients with a mean age of 12 years. Their M-mode echo measurements also showed a decrease in RV volume after PVR. d'Udekem et al.¹¹ who investigated PVR at a median age of 13 years, using echocardiography, showed a significant decrease in the mean ratio between the end diastolic diameter of RV and LV. Therrien et al.¹⁴ found, in contrast to our results, no reduction in right ventricular volumes after PVR, using Radionuclide angiography, in a group of adults with a mean age of 33.9 years, and therefore similar to our population (median age 29.2 years).

RV-EF did not improve significantly; the reduction in RV-EDV was compensated by reduction in SV after correction of PR. Since SV is greatly determined by the volume of regurgitant flow, this method is not useful in load-dependent conditions, e.g. before and after PVR. We corrected RV-EF for PR and TR as well as residual intracardiac shunts by using the net pulmonary flow, instead of the SV based on ED and ES volumes. Using this method, a dramatic increase in RV-EF_{cor} was seen from 25 to 43%. However, RV-EDV is also load-dependent and therefore RV-ESV might be the best parameter for systolic function of the RV. This parameter showed a decrease of 30%.

Symptomatic improvement in clinical symptoms was striking. After 6 months, functional class had improved significantly, and most patients with symptoms before surgery were

now symptom free. This is in accordance with previous studies^{8,14,23}. Normalization of functional class was dependent on preoperative functional class.

The differences between our results and those of Therrien et al.¹⁴ are remarkable. In both studies, mean age at PVR was around thirty. Nonetheless, our patients underwent total correction at earlier age than those of Therrien¹⁴ (our group 5.7 vs. 12.1 years). Additionally, in their group 40% underwent concomitant relief of infundibular stenosis whereas only 2 (8%) of our patients underwent such a procedure. Another, more likely, explanation is the measurement technique. In a later report by Therrien et al.²⁴ about patients with a median age of 28.2 years, transthoracic echocardiographic measurements showed a decrease in the number of patients with moderate-to-severe right ventricular dilatation after PVR, as compared to preoperatively. This is in accordance with our findings.

A regurgitant pulmonary valve is usually replaced by a pulmonary homograft. However, bioprosthetic conduits and mechanical valve prostheses have been reported as alternatives²³. We used homografts as they are excellent pulmonary valve substitutes with very low gradients. Pulmonary homografts are preferred over aortic homografts in the pulmonary position because of their better durability²⁵. Pulmonary homografts may suffer from calcific degeneration and may need later replacement²⁵. Some surgeons use mechanical valves in the pulmonary position, but since the patients are usually young, and females may develop a pregnancy wish, we prefer to avoid life-long anticoagulation. The lifetime of a pulmonary homograft remains unclear. Possibly, the durability of cryopreserved pulmonary homografts used for late PVR following Fallot repair is similar to that of pulmonary homografts which are orthotopically used to reconstruct the right ventricular outflow tract in the Ross procedure. In the International Ross Registry report of 2610 documented Ross operations freedom from reoperation on the right ventricular outflow tract was 91% at 10 years and 84% at 25 years²⁶.

Optimal timing of pulmonary valve replacement is still a subject of debate. The amelioration of right ventricular function has to be weighed against the risk of later

reoperation for homograft failure. Even in symptom free patients with right ventricular dilatation as a result of moderate-to-severe pulmonary regurgitation, we advocate pulmonary valve replacement to prevent and reduce right ventricular dilatation. Further arguments for this strategy are the predisposition of moderate-to-severe pulmonary regurgitation for ventricular dysrhythmias²⁷, and the beneficial effect of pulmonary valve replacement on electrical instability and the incidence of tachyarrhythmias²⁴.

This study has some limitations, such as the fact that we were not able to acquire full MRI data in all patients. A common problem, especially in patients with complex cardiac malformations, is the inability to get sufficient cardiac triggering. At present, this problem is minimised by using vector ECG triggering and improved imaging sequences such as balanced FFE. However, in our patients, the occurrence of triggering problems did not correlate with larger RV volumes as seen on spin echo.

Motion and metal artefacts (e.g. sternal clips) are other well-known problems.

In conclusion, in adult patients late after total correction for Tetralogy of Fallot who undergo PVR for moderate-to-severe pulmonary regurgitation and right ventricular dilatation, MRI measurements showed remarkable haemodynamic improvement. Furthermore, normalization of functional class is more likely in patients with preoperative functional class II to III or better, than in patients with worse functional class. We therefore advocate a less restrictive strategy concerning pulmonary valve replacement in patients with moderate to severe PR and RV dilatation late after total repair for Tetralogy of Fallot.

References

- 1 Nollert G, Fischlein T, Bouterwek S, et al. Long-term results of total repair of tetralogy of Fallot in adulthood: 35 years follow-up in 104 patients corrected at the age of 18 or older. *Thorac Cardiovasc Surg* 1997;45:178-81.
- 2 Allen HD, Gutgesell HP, Clark EB. Moss and Adams' Heart diseases in infants, children, and adolescents: including the fetus and the young adult. 6th edition: Lippincott Williams & Wilkins Publishers;2001:880-902
- 3 Lillehei CW, Varco RL, Cohen M, et al. The first open heart corrections of tetralogy of Fallot. A 26-31 year follow-up of 106 patients. *Ann Surg* 1986;204:490-502.
- 4 Horneffer PJ, Zahka KG, Rowe SA, et al. Long-term results of total repair of tetralogy of Fallot in childhood. *Ann Thorac Surg* 1990;50:179-83.
- 5 Gatzoulis MA, Till JA, Somerville J, et al. Mechanoelectrical interaction in tetralogy of Fallot. QRS prolongation relates to right ventricular size and predicts malignant ventricular arrhythmias and sudden death. *Circulation* 1995;92:231-7.
- 6 Gatzoulis MA, Balaji S, Webber SA, et al. Risk factors for arrhythmia and sudden cardiac death late after repair of tetralogy of Fallot: a multicentre study. *Lancet* 2000;356:975-81
- 7 Rebergen SA, Chin JG, Ottenkamp J, et al. Pulmonary regurgitation in the late postoperative follow-up of tetralogy of Fallot. Volumetric quantitation by nuclear magnetic resonance velocity mapping. *Circulation* 1993;88:2257-66.
- 8 Yemets IM, Williams WG, Webb GD, et al. Pulmonary valve replacement late after repair of tetralogy of Fallot. *Ann Thorac Surg* 1997;64:526-30.

- 9 Oechslin EN, Harrison DA, Harris L, et al. Reoperation in adults with repair of tetralogy of Fallot: indications and outcomes. *J Thorac Cardiovasc Surg* 1999;118:245-51.
- 10 MG Hazekamp, MM Kurvers, PH Schoof, et al. Pulmonary valve insertion late after repair of tetralogy of Fallot. *Eur J CardioThorac Surg* 2001;19:667-70.
- 11 d'Udekem Y, Rubay J, Shango-Lody P, et al. Late homograft valve insertion after transannular patch repair of tetralogy of Fallot. *J Heart Valve Dis* 1998;7:450-4.
- 12 Warner KG, Anderson JE, Fulton DR, et al. Restoration of the pulmonary valve reduces right ventricular volume overload after previous repair of tetralogy of Fallot. *Circulation* 1993;88:189-97.
- 13 Bove EL, Kavey RE, Byrum CJ, et al. Improved right ventricular function following late pulmonary valve replacement for residual pulmonary insufficiency or stenosis. *J Thorac Cardiovasc Surg* 1985;90:50-5.
- 14 Therrien J, Siu SC, McLaughlin PR, et al. Pulmonary valve replacement in adults late after repair of tetralogy of Fallot: are we operating too late? *J Am Coll Cardiol* 2000;36:1670-5.
- 15 de Roos A, Roest AA. Evaluation of congenital heart disease by magnetic resonance imaging. *Eur Radiol* 2000;10:2-6.
- 16 Niezen RA, Helbing WA, van der Wall EE, et al. Biventricular systolic function and mass studied with MR imaging in children with pulmonary regurgitation after repair for tetralogy of Fallot. *Radiology* 1996;201:135-40.
- 17 Helbing WA, de Roos A. Optimal imaging in assessment of right ventricular function in tetralogy of Fallot with pulmonary regurgitation. *Am J Cardiol* 1998;82:1561-2.

- 18 Helbing WA, Niezen RA, Le Cessie S, et al. Right ventricular diastolic function in children with pulmonary regurgitation after repair of tetralogy of Fallot: volumetric evaluation by magnetic resonance velocity mapping. *J Am Coll Cardiol* 1996;28:1827-35.
- 19 Connelly MS, Webb GD, Somerville J, et al. Canadian Consensus Conference on Adult Congenital Heart Disease 1996. *Can J Cardiol* 1998;14:395-452.
- 20 van der Geest RJ, Niezen RA, van der Wall EE, et al. Automated measurement of volume flow in the ascending aorta using MR velocity maps: evaluation of inter- and intraobserver variability in healthy volunteers. *J Comput Assist Tomogr* 1998;22:904-11.
- 21 van der Geest RJ, de Roos A, van der Wall EE, et al. Quantitative analysis of cardiovascular MR images. *Int J Card Imaging* 1997;13:247-58.
- 22 van der Geest RJ, Reiber JH. Quantification in cardiac MRI. *J Magn Reson Imaging* 1999;10:602-8.
- 23 Discigil B, Dearani JA, Puga FJ, et al. Late pulmonary valve replacement after repair of tetralogy of Fallot. *J Thorac Cardiovasc Surg* 2001;121:344-51.
- 24 Therrien J, Siu SC, Harris L, et al. Impact of pulmonary valve replacement on arrhythmia propensity late after repair of tetralogy of Fallot. *Circulation* 2001;103:2489-94.
- 25 Rosti L, Murzi B, Colli AM, et al. Pulmonary valve replacement: a role for mechanical prostheses? *Ann Thorac Surg* 1998;65:889-90.
- 26 Oury J. Ross Registry International Summary Report, 1999.
- 27 Niwaya K, Knott-Craig CJ, Lane MM, et al. Cryopreserved homograft valves in the pulmonary position: risk analysis for intermediate-term failure. *J Thorac Cardiovasc Surg* 1999;117:141-6.

