



**Universiteit
Leiden**
The Netherlands

Local recurrence in rectal cancer : mechanisms of development, patterns of relapse and treatment options

Kusters, M.

Citation

Kusters, M. (2009, September 17). *Local recurrence in rectal cancer : mechanisms of development, patterns of relapse and treatment options*. Retrieved from <https://hdl.handle.net/1887/14002>

Version: Corrected Publisher's Version

License: [Licence agreement concerning inclusion of doctoral thesis in the Institutional Repository of the University of Leiden](#)

Downloaded from: <https://hdl.handle.net/1887/14002>

Note: To cite this publication please use the final published version (if applicable).

Chapter



Summary and Discussion

Summary

The first chapter discussed the epidemiology and multi-disciplinary treatment strategy of rectal cancer.

In the second chapter the history, operation techniques and nerve-sparing procedures of rectal cancer surgery were discussed. In the past century the surgical treatment has undergone major developments, following different directions in the West and the East. In the West, total mesorectal excision has become the standard, often combined with neoadjuvant or adjuvant treatment. In the East, initiated by surgeons in Japan, the lateral lymph node dissection has become the gold standard in cases of advanced rectal cancer, often without the use of (neo)adjuvant treatment regimens. Both surgical techniques were discussed and factors that make comparison of East and West difficult were clarified.

The third chapter investigated the patterns of local recurrence in the TME trial, aiming at reconstructing the influence of suboptimal surgery and suboptimal selection on local recurrence, and to relate this to the effect of short-term preoperative radiotherapy. Suboptimal selection and inclusion of many 'advanced tumours' was likely to be a factor in more recurrences than suboptimal surgery. Presacral local recurrences are the most common type of local recurrence and had a poor prognosis in general. Anastomotic and anterior recurrences had a relatively good prognosis. Radiotherapy could reduce local recurrence in all subsites, but significantly in the anastomotic subsite. In contrast, for the more biologically aggressive tumors the number of local recurrences remained unacceptably high after short-term preoperative radiotherapy.

In the fourth chapter the patterns of local recurrence of a cohort of patients operated at the National Cancer Center Hospital in Tokyo. To reduce morbidity, about twenty percent of the patients received a unilateral lymph node dissection instead of a bilateral lymph node dissection if the tumor was located laterally in the pelvis. However, especially in lymph node positive tumors, unilateral lymph node dissection resulted in more local recurrences than bilateral lymph node dissection. It could be suggested that a bilateral dissection is able to prevent residual tumor cells from developing into local recurrence. Further, as most of the recurrences after unilateral lymph node dissection were not lateral local recurrences, it was hypothesized that maybe resection of the lateral lymph nodes in advanced disease removes microscopic tumor cells in transit in the lateral lymph flow routes. These could otherwise leak back into the surgical wound and cause local recurrences in other subsites, mainly presacral.

Subsequently, in the fifth chapter, patients from the TME trial were compared to a similar group of Japanese patients. Because in Japan lateral lymph node dissections are only performed in low rectal tumors, also only patients with low rectal cancer were selected from the TME trial. Studying the patterns of local recurrence in both groups, it was striking that presacral local recurrences were more common in the Dutch group. This was ascribed to possible tumor spill from positive margins, mainly after abdominoperineal

resection. A wider technique, as performed in Japan, could possibly prevent these recurrences. Further, lateral local recurrences were significantly fewer in the Dutch radiotherapy group, compared to the Dutch total mesorectal excision group, suggesting that lateral extra-mesorectal tumor particles can be sterilized by radiotherapy.

Turning to the treatment of advanced disease in the Netherlands in the sixth chapter, patterns of local recurrence were analyzed in patients operated in the Catharina Hospital in Eindhoven. In this national referral center for locally advanced rectal carcinoma, intra-operative radiotherapy containing multimodality treatment is practiced. The most prominent subsite of local recurrence was the presacral subsite. Interestingly, the more the tumor was located dorsally, the higher the chance for local recurrence was. Obtaining a free circumferential margin was the most important factor for local control. Forty-seven percent of the local recurrences developed outside the intra-operative radiotherapy field. As this was less than the literature described when intra-operative radiotherapy was administered on the presacral space, application of the boost to the area most at risk seemed to be more effective to prevent local recurrence development.

In the seventh chapter the patients from four European treatment centers for non-metastasized locally advanced rectal carcinoma were pooled. The basic treatment principle was preoperative (chemo)radiotherapy, intended radical surgery and intra-operative radiotherapy. Adjuvant chemotherapy was administered to a substantial part of the patients, independent of TNM-stage or radicality of the resection. Overall oncologic results after multimodality treatment were good. This study showed that downstaging was more often achieved after chemoradiotherapy than after radiotherapy, justifying the switch to chemoradiotherapy in the four treatment centers. Radicality of the resection was not influenced by downstaging. Further, adjuvant chemotherapy prevented local recurrence rather than distant recurrence.

The eighth chapter focused on the radiological evaluation of locally recurrent rectal carcinoma in patients of the Catharina Hospital. Exact preoperative information on localization and extent of growth is crucial for successful salvage surgery. The role of magnetic resonance imaging was investigated in the prediction of these factors, using pathological data after surgery as the reference standard. Magnetic resonance imaging showed to be highly accurate for the prediction of tumor invasion and threatening of pelvic structures, although there was inter-observer variation. The main reason for misinterpretation was diffuse fibrosis, which often could not be differentiated from residual tumor.

Finally, in the ninth chapter the results of intra-operative radiotherapy containing multimodality treatment for locally recurrent rectal cancer were evaluated in the Catharina Hospital. The oncologic results, in terms of radicality, local re-recurrence, metastasis rate and cancer-specific survival, were related to the subsite of local recurrence. The subsite of recurrence showed to influence radicality majorly. Anastomotic local recurrences resulted in the most favorable outcomes, with the most complete

resections and the best prognosis. On the contrary, worst outcomes were observed in presacral local recurrences. It was concluded that classification of the subsite of locally recurrent rectal carcinoma is a very good predictor of potentially resectable and consequently curable disease.

Discussion

I truly believe that local recurrence results from tumor cells that have been left behind in the pelvis. Saying 'Oh, it is just the consequence of the advanced stage of the primary disease' as the causing mechanism, is too simple for an answer. It is a challenge to reconstruct for each individual case with local recurrence what went wrong exactly, in order to learn how to prevent it in the next case. But still there are boundaries; probably not all local recurrences can be prevented...

The chapters of this thesis emphasize the fact that rectal cancer requires a multidisciplinary approach to reach optimal treatment outcomes. The past century has shown that the treatment of rectal cancer has generally shifted away from a solely surgical approach, although the extent to which this has happened differs between the East and the West. In the treatment of primary rectal cancer and local recurrence efforts of radiological, oncological, radiotherapeutical, surgical and pathological disciplines join hands.

Imaging

In the last decade preoperative imaging has become increasingly important in the staging of rectal cancer. In the nineties, the time when the Dutch TME trial was conducted, routine imaging was not mandatory. This suboptimal selection resulted in the inclusion of many tumors which, looking back, were too advanced to be treated by a short course of preoperative radiotherapy and total mesorectal excision (**Chapter 3**). Nowadays, with good imaging and preoperative discussion in a multidisciplinary team, these advanced tumors would rather be subjected to a long course preoperative (chemo)radiotherapy and if necessary, more extended surgery. Thus, if the TME trial were to be conducted today, local recurrence rates would probably have been lower than the 4.6% in the RT+TME group and the 11.0% in the TME group.

In the preoperative evaluation of locally advanced rectal carcinoma several points have to be addressed. First, as the relation of the tumor to the mesorectal fascia is a more powerful predictor of local recurrence than the T-stage¹, distinction between a T3+ tumor and a T3 tumor with a wide circumferential resection margin is important^{2;3}. In **Chapter 6 and 7** of these two only T3+ tumors were subjected to a long course of preoperative (chemo)radiotherapy. Further, although massive lymph node involvement can possibly be recognized preoperatively (as suggested in **Chapter 3**), differentiation between N0 or N1 disease is still difficult. Special contrast agents can play a role in the identification of metastasized lymph nodes in the future⁴, making it plausible that not only a close relation to the mesorectal fascia, but also N+ disease can be defined as locally advanced rectal carcinoma.

In locally recurrent rectal cancer MRI has shown to accurately predict tumor invasion into the pelvic structures (**Chapter 8**) and the location of the recurrence is practically inherent to the consequent radicality of the resection (**Chapter 9**), opening new doors to more tailor-made treatment for local recurrence. Anastomotic and anterior recurrences have a relatively good prognosis (**Chapter 3 and 9**). In patients with posterior relapse

however, only in few a radical resection was achieved and 5-year cancer specific survival was around 20%. In the future a PET SUV scan before and after two courses of chemotherapy can differentiate between responders and non-responders. Responders should then be offered aggressive multimodality treatment, while in non-responders the chance of cure is low and optimal palliative treatment could be considered instead.

Neoadjuvant treatment

In primary rectal cancer a short course of preoperative radiotherapy can reduce local recurrence rates significantly^{5,6}. Analyzing the patterns of local recurrence in the Dutch TME trial, it has shown to reduce local recurrence rates in all subsites (**Chapter 3**). Radiotherapy can probably prevent lateral local recurrences, as the difference in the radiotherapy and the surgery group was significant in a selection of patients with low rectal cancer (**Chapter 5**). To a certain extent, radiotherapy can also prevent anastomotic recurrences when the distal margin is too short, but it can not compensate for shorter margins than 5 mm (**Chapter 3**). Further, radiotherapy can not compensate for insufficient lateral mesorectal resection margins⁷.

The question is however, whether all patients with primary rectal cancer need preoperative radiotherapy. In the analyses of Japanese patients, in the group staged as TNM-stage I in the preoperative work-up, local recurrence rate was only 0.8% without (neo)adjuvant treatment (**Chapter 4**). Although results of trials show good results after preoperative radiotherapy, we must seriously question ourselves whether a part of the patients was not over-treated, since radiotherapy worsens urogenital and defecation function⁸⁻¹¹.

In the search for the balance between optimal treatment and prevention of morbidity new modalities have been developed. In intensity modulated radiation therapy (IMRT) smaller areas receive a higher dose of local radiotherapy compared to the standard target area used in the TME trial. In the TME trial the lateral areas were always included, probably preventing lateral local recurrences from developing (**Chapter 5**). A problem could however arise with IMRT, if positive lateral lymph nodes are not suspected to be involved, and thus not irradiated.

In locally advanced carcinoma chemoradiotherapy is the best preoperative treatment regimen¹²⁻¹⁵. In **Chapter 7** it showed to result in downstaging more often than long-term radiotherapy alone; even in complete remission in 11% of the patients. In patients with completely downstaged tumors organ-sparing surgery, by means of a local excision, has been proposed by some authors¹⁶. This interesting treatment method, preventing the risk of anastomotic leakage and other surgery-related morbidities, however requires careful selection and intensive follow-up.

Surgery

The introduction of total mesorectal excision surgery in combination with neoadjuvant treatment has reduced the local recurrence rate considerably^{5,6}. On a population level it seems that even survival of rectal cancer patients is improving steadily¹⁷. Radicality of the resection is the major factor for local control¹. In the TME trial circumferential resection margin (CRM) positivity was 17% and even as much as 30% after an abdominoperineal

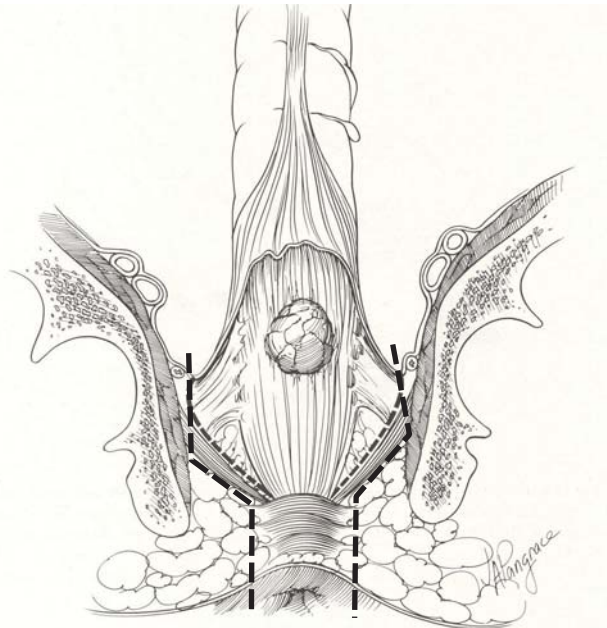
resection¹⁸. Almost 90% of CRM-positivity occurred in T3 or T4 tumors (**Chapter 3**), indicating that it is mainly attributable to adverse tumor factors and not so much to bad surgery. But nowadays, with good imaging and preoperative discussion in a multidisciplinary team, a positive margin is probably more a sign of inadequate surgical technique rather than unrecognized advanced disease¹⁹. Therefore, patients with locally advanced rectal carcinoma should be referred to specialized high volume clinics to reach optimal treatment outcomes.

The fact that preoperative radiotherapy can prevent local recurrences in distal margins of only 5 mm (**Chapter 3**), leaves more room for sphincter-saving procedures. However, the surgical treatment of low rectal cancers must be improved. The abdominoperineal resection technique during the period of the TME trial, did not remove the complete levator ani muscle (**Chapter 5**). The past few years a wider technique²⁰, resecting the complete levator ani muscle, has been proposed to prevent circumferential resection margin involvement. This technique however, without coning in much at all, removes a substantial part of the ischiorectal fat and perineal skin. This can be associated with complications as wound dehiscence, infections, fistula's and perineal hernia's. A technique that adheres to the plane as depicted in the Figure 10.1 does not compromise radicality and minimises the chance of complications.

Also concerning the treatment of low rectal cancer, there is still major variation between surgeons who operate in different surgical planes and there is no consensus about the best preoperative treatment regimen. In low T1 or T2 rectal cancer, a low anterior resection or inter-sphincteric resection can be sufficient^{21;22}. In case of T3 or T4 stage and lymph node positive disease, chemoradiotherapy is indicated to downstage the tumor^{14;23}. Downstaged tumors can possibly be treated by sphincter-saving surgery more often^{24;25}, although this is not confirmed in the literature²⁶. (Randomized) clinical studies and detailed anatomical studies are needed to make the treatment of low rectal cancers more tailor-made, adapted to the tumor stage, physiological age of the patient and cultural preferences.

Comparing Eastern and Western treatment results in low rectal cancer (**Chapter 5**), Japanese extended surgery resulted in similar local recurrence rates (6.9% 5-years percentage) as a neoadjuvant short-course of radiotherapy combined with total mesorectal excision in the TME trial (5.8%). Therefore, the Japanese concept of removing the lateral basins of lymph nodes spread can be considered successful. Further, a bilateral lymph node dissection showed better local control than unilateral lymph node dissection (**Chapter 4**), suggesting that a lymph node dissection is able to prevent residual tumor cells from developing into local relapse.

Unfortunately the surgical treatment of rectal cancer, both in the East and the West, results in a relative high morbidity rate (**Chapter 2**). Urinary, sexual and defecation dysfunctions compromise quality of life and probably they are mainly the result of surgical factors²⁷. Careful visualization of the inferior hypogastric plexus and cautious dissection of the fibres crossing to the rectum in the lateral ligament can prevent damage to the autonomic nerves²⁸. As a respected colleague²⁹ often cited Walsh's words: 'We only see what we look for, but we only look for what we know', nerve-sparing techniques can only be conducted with exact anatomic knowledge of the autonomic nervous system.

Figure 10.1 Abdominoperineal resection technique

Abdominoperineal resection technique in levator plane (black line), leaving most of the ischioanal fat in situ. Modified from picture: Wanebo et al. 1993.

Intra-operative radiotherapy

Intra-operative radiotherapy (IORT) is an entity of which the quantity of the effect on the prevention of local recurrence was unclear. In our experience with intra-operative radiotherapy during locally advanced rectal carcinoma and local recurrence surgery in the Catharina Hospital (**Chapter 6 and 9**), it however seems that a part of the residual tumor cells left behind can be fully sterilized by this regimen. In locally advanced rectal carcinoma 5-Year local recurrence rate was 13%, while this was 38% after R+ resections. In locally recurrent rectal cancer these figures were 46% and 71% after 5 years, respectively. Thus, 62% in locally advanced and 29% in locally recurrent rectal cancer patients did not develop local recurrence after an irradiated resection.

Relating the patterns of local recurrence to the IORT-target in locally advanced rectal cancer (**Chapter 6**), 47% of the local recurrences developed outside the IORT-field. This is less than the 57 - 100% in the few studies reporting on this subject, in which the boost of IORT was given only on the presacral area^{30,31}. Consequently it might be suggested that an IORT-boost specifically to the area at risk is more effective in the prevention of local recurrence, possibly because the area that causes tumor spill is sterilized.

IORT equipment is expensive and the logistics are complex. Furthermore, non-metastasized locally advanced rectal carcinoma and local recurrence are not very common. Therefore, for optimal treatment of these advanced cancers, surgery in high-volume referral centers specialized in multimodality treatment is essential (**Chapter 7**).

Pathology

Pathological quality control of the surgical specimen is essential in the multi-disciplinary approach of rectal carcinoma (**Chapter 2**). The method of Quirke³², in which the tumor and mesorectum are sliced in the transverse plane, evaluates the completeness of the mesorectum and the tumor distance from the lateral margins. After neoadjuvant therapy the predictive value of the circumferential resection margin for local recurrence is significantly higher than when no preoperative therapy has been applied. Furthermore, involvement of the circumferential resection margin is a powerful predictor of both development of distant metastases and survival¹.

Surprisingly, in Japan lymph nodes are harvested from the fresh specimen by the surgeons, directly after surgery (**Chapter 2 and 5**). This immediate harvesting of lymph nodes precludes assessment of the circumferential resection margin at a later stage. As assessment of this margin is a great predictor of oncologic results, adoption of the method of Quirke in the Japanese pathologic evaluation system should be considered seriously. But still, a sufficient lymph node harvest is essential for adequate staging. A problem with Western pathologic techniques is that, contrary to Japan (**Chapter 2**), often not enough lymph nodes are harvested. As the role of adjuvant chemotherapy in rectal cancer is gaining interest, adequate assessment of lymph node status is important to base postoperative treatment decisions on. In the Catharina hospital injection of dye in the removed specimen has shown to increase lymph node harvest (to be published).

Adjuvant treatment

In stage II and III rectal cancer preoperative (chemo)radiotherapy is preferred over postoperative therapy, due to improved adherence to the therapy, local control, toxicity profile and sphincter preservation rate^{15;24;33;34}. The role of adjuvant chemotherapy following preoperative (chemo)radiotherapy however is a subject of debate and research. The pooled analysis on the treatment of locally advanced rectal carcinoma in four European centers is strongly in favour of the use of adjuvant chemotherapy (**Chapter 7**). It effectively seemed to reduce the development of local recurrences, even when surgical margins were positive. Gradually evidence is increasing that adjuvant chemotherapy can improve overall survival³⁵⁻³⁷ and local recurrence rates³⁸, at least in a selected group of rectal cancer patients. However, in some studies it did have no additional effect³⁸. This questions the old adagium that chemotherapy does not penetrate into fibrotic tissue in the operation field. This phenomenon may cast a new light on the multimodality treatment with IORT, which is a high dose local radiotherapy, followed by chemotherapy. One could contemplate that maybe this high dose local radiotherapy was a sensibiliser of the operation field for subsequent chemotherapy.

More evidence is needed to specify the extent to which adjuvant chemotherapy can prevent local recurrence and which selection of patients benefits most from this treatment. The CHRONICLE, SCRIPT and PROCTOR studies can possibly answer these questions in the coming few years. Also interesting would be to know which types of local recurrences can be prevented by adjuvant chemotherapy, by studying the patterns of local recurrence. As especially the presacral local recurrence is very therapy-resistant, methods to prevent it from developing should be explored.

Surprisingly, in **Chapter 7** the development of distant metastases was not prevented by adjuvant chemotherapy. An explanation may be the late administration of chemotherapy, as the start of adjuvant chemotherapy is after the waiting time between diagnosis and preoperative (chemo)radiotherapy (3 weeks), (chemo)radiotherapy (6 weeks), waiting for surgery (8 weeks) and surgery and recovery (8 weeks). This is altogether a minimum of 6 months after the diagnosis of rectal cancer, if no complications occur. Alternatives might be to start with two or three courses of chemotherapy before surgery. Then after the (chemo)radiotherapy again two or three courses of chemotherapy are administered, followed by 3 weeks of recovery before surgery. These modalities however have to be explored in future studies.

Remaining questions:

What is the origin of the presacral local recurrence?

The presacral subsite is the most prominent site of local recurrence in both early and advanced rectal cancer (**Chapter 3 and 6**). The genesis of the presacral local recurrence is puzzling, as it is the easiest plane of resection during surgery and it is mostly included in the radiation volume. Several hypotheses can be made speculating on the possible etiology.

The first hypothesis is that positive margins cause tumor spill, which accumulate in the presacral space through force of gravity and develop into presacral local recurrence (**Chapter 5**). In the TME trial 75% of the presacral local recurrences occurred after abdominoperineal resection (APR) surgery and 29% of the APR-specimens had positive margins, suggesting a strong relation between positive margins and presacral local recurrence. In the locally advanced rectal carcinomas operated in the Catharina Hospital (**Chapter 6**) margin positivity was significantly associated with presacral local recurrence, making this theory plausible. However even after exclusion of margin positive patients in this study, presacral local recurrences were still prominent. Tumor cells must have been left behind or have recurred despite the negative margins.

The second hypothesis is that in transit tumor cells, which are pushed into the lateral lymph flow routes during surgical manipulation, leak back into the surgical field. This is supported by the finding that Japanese patients had more local recurrences when the lateral lymph nodes on one side in the pelvis were left behind, than when a bilateral lymph node dissection was performed (**Chapter 4**). This would explain why presacral local recurrence is more common in advanced disease than in limited disease, as lateral spread occurs mostly in high stage tumors. Further, since presacral recurrences develop despite presacral intra-operative radiotherapy makes postoperative migration of tumor cells to the presacral subsite more plausible.

Both of these hypothetical mechanisms, thus spill from positive margins and leakage from lateral lymph flow routes, might occur simultaneously. Further studies have to be conducted to elucidate the mechanisms of presacral local recurrence genesis. Currently, in the Catharina Hospital a pilot study is conducted in patients operated for locally advanced and recurrent rectal cancer. Seroma is collected from a drain in the presacral

space and examined for tumor cells. If these can be isolated a few days post-operatively from patients who in principle have undergone a radical resection, these residual tumor cells can only descend in a retrograde fashion from draining lateral lymph flow routes. Also, more detailed anatomical studies are conducted to make 3D-reconstructions of the lymph routes in the pelvis to analyze the exact connections between the mesorectal and extra-mesorectal routes (cover of this thesis). This can also lead to a better understanding of the exact pathogenesis of locally recurrent disease. As especially the presacral local recurrence results in disastrous outcomes, understanding of the mechanism of genesis hopefully can help to find options to prevent it from developing.

Possibly the development of presacral local recurrence may have a relationship with anastomotic leakage. Anastomotic leakage is reported to be associated with worse oncologic results of rectal cancer surgery; local recurrence rates are higher in patients with anastomotic leakage³⁹⁻⁴¹, although this is not confirmed in all studies⁴². There are some theories explaining the mechanisms by which anastomotic leakage may adversely affect oncologic results. First, there is some evidence that local tumor recurrence after anastomotic leakage can be caused by a 'wash-out' of exfoliated tumor cells from the bowel lumen into the wound cavity^{43;44}. Secondly, the inflammatory response to anastomotic leakage may play a role. The release of proinflammatory cytokines and growth factors as part of the systemic inflammatory response secondary to intra-abdominal sepsis, and the associated immunosuppression, may have a direct effect on the growth of residual tumor cells^{45;46}. Thirdly, there is a possibility that leaks occur as a consequence of other conditions, which themselves lead to local recurrence and reduced survival. Maybe the leaking lymph fluid with tumor cells from the lateral lymph flow routes, collected presacrally in a seroma, induce an inflammatory reaction which also affects the anastomosis. This theory would suggest that anastomotic leakage is not only affecting tumor progression, but that tumor cells themselves indirectly cause anastomotic leakage and local recurrence.

Locally advanced disease – (chemo)radiation or a lateral lymph node dissection (LLND)?

There are no randomized studies yet comparing preoperative (chemo)radiotherapy and TME with LLND in similar patients, making it difficult to state about which regimen is to be preferred in advanced rectal carcinoma. In a few non-randomized studies an attempt has been made to compare (neo)adjuvant treatment with LLND.

Watanabe et al.⁴⁷ divided 115 patients into four subgroups; Rad+LLND-, Rad+LLND+, Rad-LLND+ and Rad-LLND-. Local recurrence rates, disease-free survival and overall survival were not significantly different between Rad+LLND- and Rad-LLND+. The authors suggested that preoperative radiotherapy could be an alternative for LLND in patients with low rectal carcinoma.

Kim et al.⁴⁸ compared 176 patients with TME and post-operative chemoradiotherapy or TME combined with a LLND. The 5-year overall survival and disease-free survival rates did not differ significantly. In patients in the LLND-group with stage III low rectal cancer, local recurrence rate was 16.7%, higher than the 7.5% rate in the post-operative chemoradiotherapy group ($p = 0.044$). However, some bias in the sense that the LLND group consisted of 'very low' rectal cancer can not be ruled out⁴⁹.

We analyzed the differences between Japan and the Netherlands in the treatment of low rectal cancer, with the focus on the patterns of local recurrence (**Chapter 5**). The Dutch and Japanese patients were matched as closely as possible, by selecting only tumors up to 7 cm from the anal verge, which was considered the level of the peritoneal reflection. 5-Year local recurrence rates were 6.9% for the Japanese NCCN group, 5.8% in the Dutch RT+TME group and 12.1% in the Dutch TME group. It could be concluded that Japanese extended surgery and RT+TME result in equally good local control, as compared to TME alone.

Because of the differences in the patient groups mentioned in **Chapter 2**, it remains difficult to compare Japanese and Western series. Since 2003 the National Cancer Center Hospital in Tokyo coordinates a national multi-center randomized clinical trial comparing total mesorectal excision with or without lateral lymph node dissection, with autonomic nerve preservation. The preoperative work-up consists of endoscopic ultrasonography and MRI-imaging. Patients with histologically confirmed adenocarcinoma below the peritoneal reflection and clinical stage II or III disease are included. When lymph nodes are larger than 10mm or there is invasion into other organs, the patients are not included in the trial. The inclusion of 600 patients is estimated to be completed in 2009. The trial has to demonstrate whether a lateral lymph node dissection can truly prevent local recurrence. The trial is designed to study the effect of a 'preventive' lateral lymph node dissection, as patients with definite lateral metastases are not included. But still if the trial shows a beneficial effect of the lateral lymph node dissection, it is doubtful whether this finding will affect the treatment of Western patients.

Whether or not the lateral lymph node dissection will come to a more widespread use in the West also depends on the results of the studies proposed in the previous section. If a lateral lymph node dissection can not only prevent lateral local recurrences, but also presacral and other types of recurrences, it should be given serious consideration in selected patients. Although a lateral lymph node dissection in obese Western patients probably results in more morbidity, patients should be confronted with the option that a local recurrence with its accompanying serious morbidity and short prognosis could possibly be prevented.

With present day MRI sometimes patients are identified with clearly involved or suspected lateral lymph nodes. In these cases, it is doubtful whether the nodal metastases can be fully sterilized by preoperative chemoradiotherapy. The risk for disseminated disease is high and prognosis is unfavorable for lateral lymph node positive patients. For these patients it may be wise to consider a combination of treatments: neoadjuvant chemoradiotherapy, a lateral lymph node dissection and systemic therapy. Other alternatives, like intra-operative radiotherapy on the lateral lymph node basins, could also be an option.

Finally, it is essential to mention that not all local recurrences can be explained by surgical and other treatment factors. Some primary tumors seem to behave very aggressively and are difficult to control despite 'adequate' treatment, while others can be easily downstaged by chemoradiation and excised locally, without recurring in the long term. Many tumor-biological characteristics are still unknown, but there are promising

studies about gene-expression profiles which can predict local and distant tumor behaviour⁵⁰. In the future, in biopsy-proven rectal cancers, tailor-made treatment can then also be adapted to tumor-biological factors.

In conclusion, in the treatment of rectal cancer, local recurrence with associated serious morbidity and shortened life expectancy is still relatively common. This thesis aimed at reconstructing the mechanisms of local recurrence genesis and the analyzing the treatment options for local recurrence, through studying the patterns of local recurrence. Multi-disciplinary treatment of both primary and recurrent rectal cancer is necessary to reduce local recurrence rates. Further studies, concerning tumor-biological factors, lymph node specific contrast agents, the relation of patterns of local recurrence to target volumes, the technique of the abdominoperineal resection, the effect of adjuvant chemotherapy on local recurrence and studies about the role of the lateral lymph basins in local recurrence, are awaited with anticipation.

Reference List

1. Nagtegaal ID, Quirke P. What is the role for the circumferential margin in the modern treatment of rectal cancer? *J Clin Oncol* 2008; 26(2):303-312.
2. Beets-Tan RG, Beets GL, Vliegen RF, Kessels AG, Van Boven H, De Bruine A et al. Accuracy of magnetic resonance imaging in prediction of tumour-free resection margin in rectal cancer surgery. *Lancet* 2001; 357(9255):497-504.
3. Brown G. Thin section MRI in multidisciplinary pre-operative decision making for patients with rectal cancer. *Br J Radiol* 2005; 78 Spec No 2:S117-S127.
4. Lahaye MJ, Engelen SM, Kessels AG, de Bruine AP, von Meyenfeldt MF, van Engelshoven JM et al. USPIO-enhanced MR imaging for nodal staging in patients with primary rectal cancer: predictive criteria. *Radiology* 2008; 246(3):804-811.
5. Peeters KC, Marijnen CA, Nagtegaal ID, Kranenbarg EK, Putter H, Wiggers T et al. The TME trial after a median follow-up of 6 years: increased local control but no survival benefit in irradiated patients with resectable rectal carcinoma. *Ann Surg* 2007; 246(5):693-701.
6. Bosset JF, Collette L, Calais G, Mineur L, Maingon P, Radosevic-Jelic L et al. Chemotherapy with preoperative radiotherapy in rectal cancer. *N Engl J Med* 2006; 355(11):1114-1123.
7. Marijnen CA, Nagtegaal ID, Kapiteijn E, Kranenbarg EK, Noordijk EM, van Krieken JH et al. Radiotherapy does not compensate for positive resection margins in rectal cancer patients: report of a multicenter randomized trial. *Int J Radiat Oncol Biol Phys* 2003; 55(5):1311-1320.
8. Marijnen CA, van de Velde CJ, Putter H, van den BM, Maas CP, Martijn H et al. Impact of short-term preoperative radiotherapy on health-related quality of life and sexual functioning in primary rectal cancer: report of a multicenter randomized trial. *J Clin Oncol* 2005; 23(9):1847-1858.
9. Peeters KC, van d, V, Leer JW, Martijn H, Junggeburst JM, Kranenbarg EK et al. Late side effects of short-course preoperative radiotherapy combined with total mesorectal excision for rectal cancer: increased bowel dysfunction in irradiated patients—a Dutch colorectal cancer group study. *J Clin Oncol* 2005; 23(25):6199-6206.
10. Dahlberg M, Glimelius B, Graf W, Pahlman L. Preoperative irradiation affects functional results after surgery for rectal cancer: results from a randomized study. *Dis Colon Rectum* 1998; 41(5):543-549.
11. Welsh FK, McFall M, Mitchell G, Miles WF, Woods WG. Pre-operative short-course radiotherapy is associated with faecal incontinence after anterior resection. *Colorectal Dis* 2003; 5(6):563-568.
12. Gerard JP, Conroy T, Bonnetain F, Bouche O, Chapet O, Closon-Dejardin MT et al. Preoperative radiotherapy with or without concurrent fluorouracil and leucovorin in T3-4 rectal cancers: results of FFC9203. *J Clin Oncol* 2006; 24(28):4620-4625.
13. Bosset JF, Calais G, Mineur L, Maingon P, Radosevic-Jelic L, Daban A et al. Enhanced tumorocidal effect of chemotherapy with preoperative radiotherapy for rectal cancer: preliminary results—EORTC 22921. *J Clin Oncol* 2005; 23(24):5620-5627.
14. Braendengen M, Tveit KM, Berglund A, Birkemeyer E, Frykholm G, Pahlman L et al. Randomized phase III study comparing preoperative radiotherapy with chemoradiotherapy in nonresectable rectal cancer. *J Clin Oncol* 2008; 26(22):3687-3694.
15. Sauer R, Becker H, Hohenberger W, Rodel C, Wittekind C, Fietkau R et al. Preoperative versus postoperative chemoradiotherapy for rectal cancer. *N Engl J Med* 2004; 351(17):1731-1740.
16. Habr-Gama A, Perez RO, Nadalin W, Sabbaga J, Ribeiro U, Jr, Silva e Sousa AH Jr et al. Operative versus nonoperative treatment for stage 0 distal rectal cancer following chemoradiation therapy: long-term results. *Ann Surg* 2004; 240(4):711-717.
17. Den Dulk M, Krijnen P, Marijnen CA, Rutten HJ, van de Poll-Franse LV, Putter H et al. Improved overall survival for patients with rectal cancer since 1990: the effects of TME surgery and pre-operative radiotherapy. *Eur J Cancer* 2008; 44(12):1710-1716.
18. Nagtegaal ID, van de Velde CJ, Marijnen CA, van Krieken JH, Quirke P. Low rectal cancer: a call for a change of approach in abdominoperineal resection. *J Clin Oncol* 2005; 23(36):9257-9264.
19. Burton S, Brown G, Daniels IR, Norman AR, Mason B, Cunningham D. MRI directed multidisciplinary team preoperative treatment strategy: the way to eliminate positive circumferential margins? *Br J Cancer* 2006; 94(3):351-357.

20. Holm T, Ljung A, Haggmark T, Jurell G, Lagergren J. Extended abdominoperineal resection with gluteus maximus flap reconstruction of the pelvic floor for rectal cancer. *Br J Surg* 2007; 94(2):232-238.
21. Akasu T, Takawa M, Yamamoto S, Fujita S, Moriya Y. Incidence and patterns of recurrence after intersphincteric resection for very low rectal adenocarcinoma. *J Am Coll Surg* 2007; 205(5):642-647.
22. Shihab OC, Moran BJ, Heald RJ, Quirke P, Brown G. MRI staging of low rectal cancer. *Eur Radiol* 2008.
23. Bosset JF, Collette L, Calais G, Mineur L, Maingon P, Radosevic-Jelic L et al. Chemotherapy with preoperative radiotherapy in rectal cancer. *N Engl J Med* 2006; 355(11):1114-1123.
24. Bujko K, Kepka L, Michalski W, Nowacki MP. Does rectal cancer shrinkage induced by preoperative radio(chemo)therapy increase the likelihood of anterior resection? A systematic review of randomised trials. *Radiother Oncol* 2006; 80(1):4-12.
25. Pahlman L. When should chemoradiotherapy for rectal cancer be done? *Nat Clin Pract Gastroenterol Hepatol* 2005; 2(2):80-81.
26. Glimelius B, Gronberg H, Jarhult J, Wallgren A, Cavallin-Stahl E. A systematic overview of radiation therapy effects in rectal cancer. *Acta Oncol* 2003; 42(5-6):476-492.
27. Lange MM, Maas CP, Marijnen CA, Wiggers T, Rutten HJ, Kranenburg EK et al. Urinary dysfunction after rectal cancer treatment is mainly caused by surgery. *Br J Surg* 2008; 95(8):1020-1028.
28. Maas CP, Moriya Y, Steup WH, Klein KE, van de Velde CJ. A prospective study on radical and nerve-preserving surgery for rectal cancer in the Netherlands. *Eur J Surg Oncol* 2000; 26(8):751-757.
29. Maas CP, Moriya Y, Steup WH, Kiebert GM, Kranenburg WM, van de Velde CJ. Radical and nerve-preserving surgery for rectal cancer in The Netherlands: a prospective study on morbidity and functional outcome. *Br J Surg* 1998; 85(1):92-97.
30. Calvo FA, Gomez-Espi M, az-Gonzalez JA, Alvarado A, Cantalapiedra R, Marcos P et al. Intraoperative presacral electron boost following preoperative chemoradiation in T3-4N0 rectal cancer: initial local effects and clinical outcome analysis. *Radiother Oncol* 2002; 62(2):201-206.
31. Roeder F, Treiber M, Oertel S, Dinkel J, Timke C, Funk A et al. Patterns of failure and local control after intraoperative electron boost radiotherapy to the presacral space in combination with total mesorectal excision in patients with locally advanced rectal cancer. *Int J Radiat Oncol Biol Phys* 2007; 67(5):1381-1388.
32. Quirke P, Durdey P, Dixon MF, Williams NS. Local recurrence of rectal adenocarcinoma due to inadequate surgical resection. Histopathological study of lateral tumour spread and surgical excision. *Lancet* 1986; 2(8514):996-999.
33. Sebag-Montefiore D, Stephens RJ, Steele R, Monson J, Grieve R, Khanna S et al. Preoperative radiotherapy versus selective postoperative chemoradiotherapy in patients with rectal cancer (MRC CR07 and NCIC-CTG C016): a multicentre, randomised trial. *Lancet* 2009; 373(9666):811-820.
34. Amenos M, Navarro GM, Marti RJ, Pareja FL, Pera FJ. Preoperative radio-chemotherapy (RT-CT) in rectal cancer. Prospective study with postoperative RT-CT control group. *Clin Transl Oncol* 2007; 9(3):183-191.
35. Akasu T, Moriya Y, Ohashi Y, Yoshida S, Shirao K, Kodaira S. Adjuvant chemotherapy with uracil-tegafur for pathological stage III rectal cancer after mesorectal excision with selective lateral pelvic lymphadenectomy: a multicenter randomized controlled trial. *Jpn J Clin Oncol* 2006; 36(4):237-244.
36. Quasar Collaborative Group, Gray R, Barnwell J, McConkey C, Hills RK, Williams NS et al. Adjuvant chemotherapy versus observation in patients with colorectal cancer: a randomised study. *Lancet* 2007; 370(9604):2020-2029.
37. Mathis KL, Nelson H, Pemberton JH, Haddock MG, Gunderson LL. Unresectable colorectal cancer can be cured with multimodality therapy. *Ann Surg* 2008; 248(4):592-598.
38. Collette L, Bosset JF, den Dulk M, Nguyen F, Mineur L, Maingon P et al. Patients with curative resection of cT3-4 rectal cancer after preoperative radiotherapy or radiochemotherapy: does anybody benefit from adjuvant fluorouracil-based chemotherapy? A trial of the European Organisation for Research and Treatment of Cancer Radiation Oncology Group. *J Clin Oncol* 2007; 25(28):4379-4386.
39. Petersen S, Freitag M, Hellmich G, Ludwig K. Anastomotic leakage: impact on local recurrence and survival in surgery of colorectal cancer. *Int J Colorectal Dis* 1998; 13(4):160-163.
40. Branagan G, Finnis D. Prognosis after anastomotic leakage in colorectal surgery. *Dis Colon Rectum* 2005; 48(5):1021-1026.

41. Law WL, Choi HK, Lee YM, Ho JW, Seto CL. Anastomotic leakage is associated with poor long-term outcome in patients after curative colorectal resection for malignancy. *J Gastrointest Surg* 2007; 11(1):8-15.
42. Den Dulk M, Marijnen CA, Colette L, Putter H, Pahlman L, Folkesson J et al. Anastomotic leakage associated with long-term reduced overall survival: the results of a pooled analysis of five European randomized clinical trials on rectal cancer. Submitted 2008.
43. Umpleby HC, Fermor B, Symes MO, Williamson RC. Viability of exfoliated colorectal carcinoma cells. *Br J Surg* 1984; 71(9):659-663.
44. Skipper D, Cooper AJ, Marston JE, Taylor I. Exfoliated cells and in vitro growth in colorectal cancer. *Br J Surg* 1987; 74(11):1049-1052.
45. Abramovitch R, Marikovsky M, Meir G, Neeman M. Stimulation of tumour growth by wound-derived growth factors. *Br J Cancer* 1999; 79(9-10):1392-1398.
46. Balkwill F, Mantovani A. Inflammation and cancer: back to Virchow? *Lancet* 2001; 357(9255):539-545.
47. Watanabe T, Tsurita G, Muto T, Sawada T, Sunouchi K, Higuchi Y et al. Extended lymphadenectomy and preoperative radiotherapy for lower rectal cancers. *Surgery* 2002; 132(1):27-33.
48. Kim JC, Takahashi K, Yu CS, Kim HC, Kim TW, Ryu MH et al. Comparative outcome between chemoradiotherapy and lateral pelvic lymph node dissection following total mesorectal excision in rectal cancer. *Ann Surg* 2007; 246(5):754-762.
49. Watanabe T, Matsuda K, Nozawa K, Kobunai T. Lateral pelvic lymph node dissection or chemoradiotherapy: which is the procedure of choice to reduce local recurrence rate in lower rectal cancer? *Ann Surg* 2008; 248(2):342-343.
50. De Heer P, de Bruin EC, Klein-Kranenbarg E, Aalbers RI, Marijnen CA, Putter H et al. Caspase-3 activity predicts local recurrence in rectal cancer. *Clin Cancer Res* 2007; 13(19):5810-5815.