



Universiteit
Leiden
The Netherlands

Quality of life, functional ability and physical activity in children and adolescents after lower extremity bone tumour surgery

Bekkering, W.P.

Citation

Bekkering, W. P. (2011, December 14). *Quality of life, functional ability and physical activity in children and adolescents after lower extremity bone tumour surgery*. Retrieved from <https://hdl.handle.net/1887/18243>

Version: Corrected Publisher's Version

License: [Licence agreement concerning inclusion of doctoral thesis in the Institutional Repository of the University of Leiden](#)

Downloaded from: <https://hdl.handle.net/1887/18243>

Note: To cite this publication please use the final published version (if applicable).



Chapter 1

GENERAL INTRODUCTION

INTRODUCTION

Survival rates following all childhood cancers have increased significantly over the past decades [1,2]. This improvement has also been observed in children with malignant bone tumours, although overall survival rates remain lower than those for child cancer generally [2]. The improved survival is due to a number of factors, including better imaging methods for defining tumour extent and responses on pre-operative treatment, the introduction of multi-agent chemotherapy since the 1970s, and new surgical techniques concerning both limb-salvage and limb ablation surgery [3]. In addition, aggressive surgical approaches for metastatic disease contribute to the better survival.

The contemporary highly intensive treatment approaches and the better survival after malignant bone tumours in children and adolescents have stressed the need to further investigate the patients' quality of life (QoL) [3,4]. This does not only pertain to QoL during the intensive treatment periods, but also to the longer term. The ultimate aim of the treatment will not only be the instantaneous cure but also long term survival, including the side effects related to the treatment.

Epidemiology of malignant bone tumours in children and adolescents

In Europe, primary malignant bone tumours account for approximately 3-5% of all cancers in children younger than 15 years and 7-8% of those in adolescents aged 15-19 years [1,2]. This is equivalent to an average annual incidence of 8-9 per million children under the age of 20. The great majority of malignant bone tumours occurring in young people under the age of 20 years are osteosarcoma and Ewing's sarcoma [2].

Osteosarcoma is the most frequent primary malignant bone tumour, accounting for 52% of all cases. Ewing's sarcoma is the second group of primary malignant bone tumours, which accounts for 34% of all malignant bone tumours in the younger age group, whereas chondrosarcoma is very rare (6% of all bone malignancies) in patients younger than 18 years. Other specified and unspecified bone tumours account for 4% each of all primary malignant bone tumours in children and adolescents.

The incidence of osteosarcoma and Ewing's sarcoma reaches a peak in late childhood and adolescence, around the age of 15, followed by a decline until the age of 30, after which age the incidence remains relatively low and similar in all age groups. Ewing's sarcoma is more frequent than osteosarcoma in children under 10 years of age. Although the highest incidence of primary malignant bone tumours occurs at the growth spurt, no explanation has been found yet for the remarkable distribution of incidence of these malignancies.

The largest proportion of each of these bone tumours occurs in the long bones of the lower extremity, although this site shows a much greater proportion for osteosarcoma (58%) than for Ewing's sarcoma (31%). For osteosarcoma, the next most common general sites are the long bones of the upper extremity (12%) and pelvic bone (10%). For Ewing's sarcoma, the next most common sites are the pelvic bone (25%), the long bones of the upper extremity (13%) followed by the rib/sternum/clavicle (11%) and the vertebral column (9%). All other sites of sarcoma occurrence represent less than 10% of each type of sarcoma cases [5]. Similar to developments in other forms of paediatric cancer the 1975-84 5 year survival rate of 49% increased to 63% during the years 1985-94 [6].

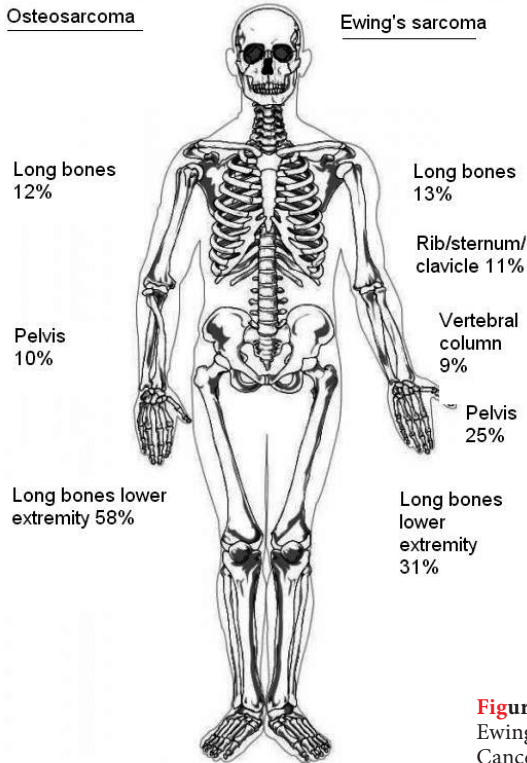


Figure 1. Distribution of osteosarcoma and Ewing's sarcoma (Based on Damron TA: National Cancer Data Base Report) [5]

Management of malignant bone tumours in children and adolescents

The current model of care for children with bone cancer includes chemotherapy in combination with surgery [3,7-10], and for Ewing's sarcoma often in combination with radiotherapy. Treatment with these modalities is dependent of tumour type and extension of the malignant disease. Contemporary protocols include chemotherapy before surgery in order to reduce micro-metastatic disease. This has the advantage of reducing the extent of the primary tumour. After surgery the patients will continue chemotherapy, depending on the histological response of the tumour. This so-called neo-adjuvant approach has enabled limb-salvage surgery, because marginal excision of the primary tumour is possible with less risk of local recurrences. With this combined treatment of chemotherapy and surgery complete excision of the tumour is absolutely required for cure of patients. The chances of curing patients with irresectable tumours are low, particularly in osteosarcoma. In patients with Ewing's sarcoma additional radiotherapy may be of value. The reason for this is that Ewing sarcoma is sensitive to radiotherapy, whereas osteosarcoma is not. However, radiotherapy for bone tumours in young children is a problem, because of the potential serious side effects on the immature skeletal and muscle tissues. Treatment of metastatic or recurrent bone tumours is a problem because the wide-spread tumour deposits can seldom all be surgically removed and the other treatment modalities, chemotherapy or radiotherapy, are of limited value [9].

In addition, given the severity of the disease and the intensive and radical medical treatment and any possible complications, patients and their parents need support by a multidisciplinary team, consisting of: medical specialists such as the oncologist, orthopaedic surgeon, pathologist and rehabilitation specialist. Moreover, they often require care from other professionals such as a specialist nurse, psychologist, social worker, play therapist or physical therapist.

Chemotherapy

It was not until the 1970s and 1980s that effective multimodal treatment altered the prognosis of osteosarcoma and Ewing's sarcoma, which historically had been between 10-20% after surgery only. Currently, the chemotherapeutic treatment consists of a combination of several chemotherapeutic agents following international treatment protocols like: the EURAMOS-1 protocol (European and American Osteosarcoma Study Group) with high-dose methotrexate, adriamycin, cisplatin with or without ifosfamide in patients with osteosarcoma [7] (www.euramos.org). Patients with Ewing's sarcoma are treated according to the EURO-Ewing-99 (European Ewing tumour Working Initiative of National Groups) protocol, using vincristine, ifosfamide, doxorubicin, etoposide and actinomycin as cytostatic drugs [8,10-12].

Surgical intervention

Before the 70s surgery was the only treatment available. At that time, the surgical intervention in patients without pulmonary metastases consisted of amputation of the affected extremity. In parallel with the availability of chemotherapy and supported by novel imaging methods for defining tumour extent, new surgical techniques for preserving the extremity were developed [3-13,14]. These surgical techniques can be divided into ablative and limb-sparing surgery.

Ablative surgery

Amputation

Amputations are now generally applied in patients who have tumours for which achieving a wide excision is not possible without essentially creating an amputation or tumours for which a reconstruction with a prosthesis or allograft will give too fragile results. There are four main types of amputation for the treatment of lower-extremity malignant bone tumours: hip disarticulation, transfemoral amputation (above-the-knee amputation), knee disarticulation and transtibial amputation (below-the-knee amputation). The majority of amputations are transfemoral, given the predilection of bone tumours for the distal femur.

Rotationplasty

Rotationplasty is considered a method of amputation because it involves ablation of the tumour and surrounding tissue without reconstruction to fill the skeletal defect created [15-16]. Rotationplasty can be particularly useful in patients with remaining growth potential whose tumours are located in the proximal or distal femur or proximal tibia. In this procedure, the tumour is removed while the neurovascular bundle and the distal

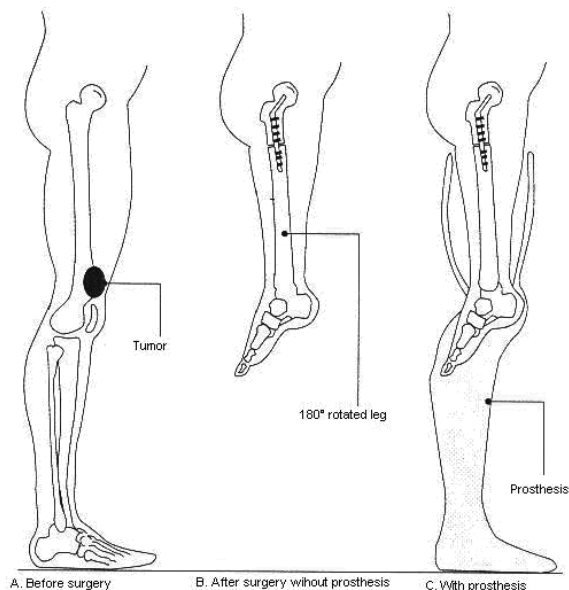


Figure 2. Rotationplasty

portion of the tibia and foot are maintained. The tibia and foot are rotated 180 degrees, and then attached to the remaining proximal femur so that the ankle is at the height of the contra-lateral knee. To accomplish this in a skeletally immature child, the proximal femur and distal tibia's lengths are adjusted thus at the end of skeletal growth, the ankle is at the appropriate level with the contra-lateral knee [16].

Rotationplasty has many benefits, including a functional “knee” joint, **stable** reconstruction, an almost normal gait pattern [17], less energy consumption, and potentially fewer future surgeries. The major disadvantage is the appearance of the resulting reconstruction, which can be cosmetically unappealing, especially to adolescents and females. These negative aspects can be overshadowed by the improved function provided by rotationplasty, but they should not be taken lightly [13].

Limb-salvage surgery

There are two key goals that must be accomplished by limb-sparing surgical resection and reconstruction: (1) limb salvage must still provide a satisfactorily wide excision of the bone tumour, and (2) the reconstructed extremity must be at least as functional as an ablative procedure and prosthesis. Surgical techniques used to repair skeletal defects that follow limb-sparing tumour resections include intercalary allografting, endoprosthetic arthroplasty, and composite allograft/prosthesis arthroplasty [13,18-20].

As with amputations, special consideration must be given to children [21,22]. Children are more active and have an expected life span that is greater than the life span of most adult patients who receive an endoprosthetic implants or bone graft. These factors can lead to further surgeries in the future. Children who are skeletally immature with at least 4 to 5 cm of growth potential (corresponding to a bone age of 12 in boys and 10 in girls) may

require a prosthetic device capable of expanding in length to avoid serious limb-length discrepancies.

The descriptions in the following paragraphs include a general overview of the types of limb-sparing reconstructions available for the lower extremity. The type used depends on the site of the tumour, age of the patient, prognosis, and the orthopaedic surgeon's skills and preferences.

Intercalary allograft bone

When malignancies involve segments of the long bone without the involvement of the joint, this segment of bone can be replaced by either autogeneous bone (hip or fibula) or allograft bone (from deceased donors) [13,18-20]. The grafted intercalary bone is then incorporated over time within the adjacent native bone. Immediately after surgery, the limb is protected for at least 2 to 3 months. Protracted periods of non-weight bearing and bracing or casting may be needed to achieve bone healing (engraftment). Major complications associated with the use of large segment allografts include non-union, infection, and fracture [18]. Infection has been the most serious complication and may require removal of the allograft and prolonged use of antibiotics. Non-union refers to the absence of osseous healing, generally after a period of 1 year. This can be treated by additional grafting of autogeneous bone (or vascularised fibula) to the site of non-union. Although there seems to be a high incidence of complications, the overall allograft survival is good (60% to 80%) and can be **stable** for a prolonged period of time.

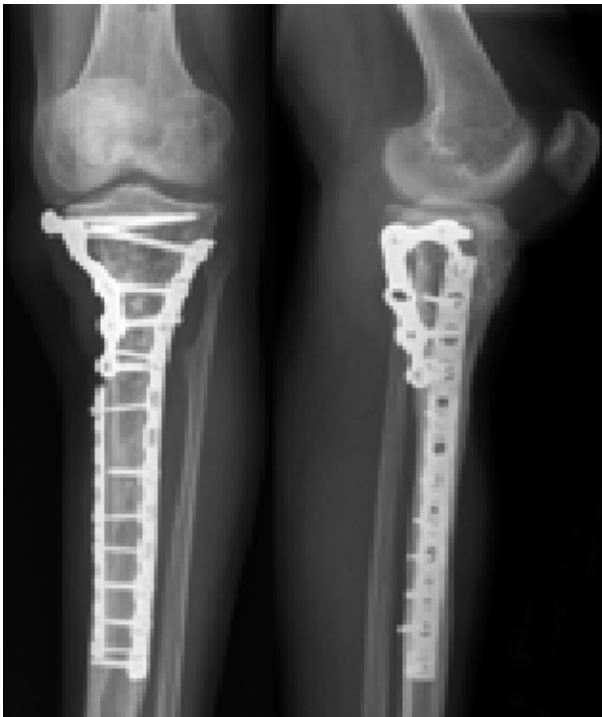

Figure 3. Intercalary allograft

Endoprosthetic implants

Endoprosthetic arthroplasty involves resection of the entire segment of bone involving the tumour and placement of a metallic implant that is used to replace both the bone and joint. It is most commonly used to treat tumours of the distal femur. The major benefits of an endoprosthetic implant include ease of postoperative rehabilitation, a **stable** joint, immediate weight bearing, and rapid functional use of the extremity. Common causes of prosthesis failure include infection, aseptic loosening, and bone resorption and periprosthetic fracturing. The survival of the prosthesis progressively decreases over time to approximately 50% to 80% at 5 to 10 years and is related to the length of time since surgery, site of reconstruction, and amount of bone resection.

Children with considerable growth potential (> 4 to 5cm) are difficult to treat with traditional limb-sparing techniques because of continued growth of the unaffected limb and resulting limb-length discrepancy. They were historically treated with either amputation or a rotationplasty. However, with the growing population of survivors of paediatric lower-extremity tumours, the development of expanding endoprosthetic implants became necessary [22-24].

The implant has a mechanism for “active growth” to accommodate for growth of the unaffected leg. The goal of an expandable implant is lengthening and providing growth of the supporting structures of the affected limb while providing ambulation for the child until the implant requires replacement, which would occur hopefully after the child has reached adult height.

Rehabilitation

The goal of cancer rehabilitation is to improve quality of life by minimizing the limitations in daily activities and participation caused by the disease and its associated treatments [26,27]. Rehabilitation for individuals with bone tumours depends on the localization

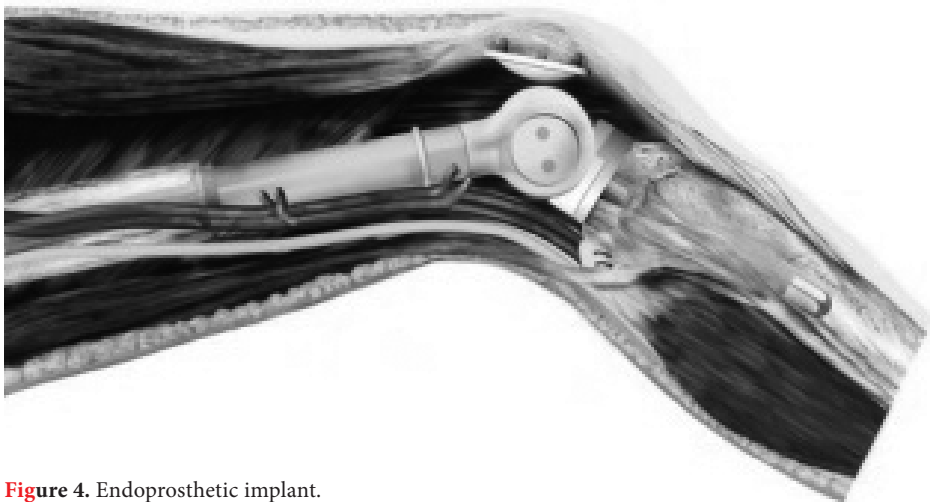


Figure 4. Endoprosthetic implant.

of the tumour and whether limb-salvage or ablative surgery is done. If limb-salvage surgery has been performed, rehabilitation includes physical therapy aimed to maintain or recover range of motion, strength, weight bearing and functional mobility. After ablative surgery, therapeutic actions to improve range of motion, muscular function and stability of the remaining joints, fitting of prosthesis and training of daily activities with and without the assistance of an artificial limb have the priority (www.mdguidelines.com/bone-tumors-benign-and-malignant).

In general, the aim of rehabilitation is to achieve these goals as soon as possible after the intervention. However, especially after limb-salvage surgery with reconstruction of the extremity with allograft or autograft, the extremity remains fragile for a prolonged period.

In addition, due to the surgical and chemotherapeutical treatment, patients are at risk of numerous secondary complications such as decreased joint range of motion, decreased muscle strength, poor motor control, limb-length discrepancy, and musculoskeletal/neuropathic pain and infection, all of which may affect daily activities as well as quality of life [26,28].

Ideally, each patient and his or her parents are accompanied by an multidisciplinary team consisting of an (orthopaedic) surgeon, oncologist, paediatrician, rehabilitation specialist, nursing staff, physical therapist, social worker and psychologist [29]. Cooperation,

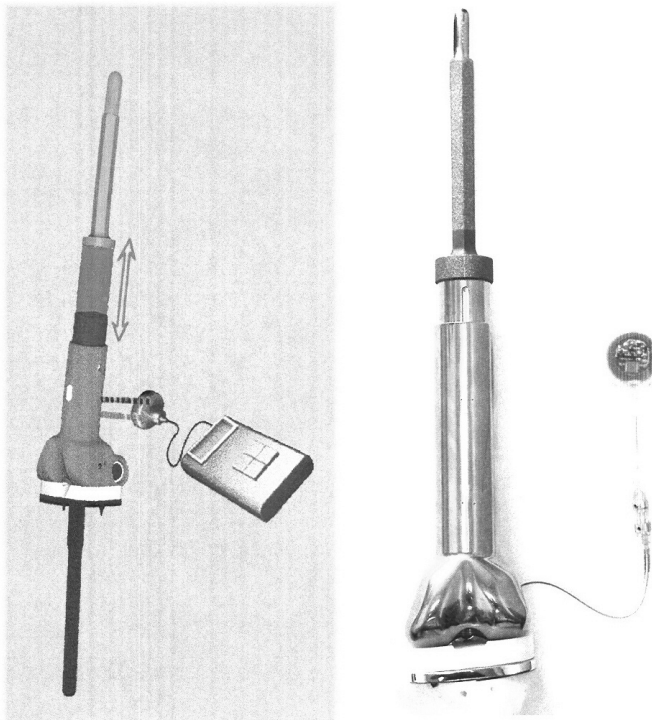


Figure 5. Expanding endoprosthetic implant.

teamwork and communication among members of the team are necessary to the success of postoperative rehabilitation of paediatric/adolescent and young adult patients [30].

An important professional in this rehabilitation process is the physical therapist. The physical therapist is closely involved in the preoperative preparation, treatment of the consequences of the surgical intervention and the physical and functional rehabilitation. A physical therapist involved in the rehabilitation of children and adolescents after bone tumour surgery has experience in care for cancer patients and needs a special empathy for this group of patients and their parents. Furthermore, the physical therapist should have thorough knowledge about the various surgical interventions in patients with bone cancer, and must be capable to plan a custom made rehabilitation plan for the patient. Finally he or she should be able to transfer knowledge and experience and communicate the results of the multidisciplinary outpatient visits to the physical therapy colleagues who treat the patients in their home environments or other health care professionals like the occupational therapist, rehabilitation specialist and orthotist or prothetist.

Outcomes of treatment for malignant bone tumours in children and adolescents

Perhaps the most complicated and potentially life-altering decision that patients with lower-extremity malignant bone tumours and their parents have to make along with their physicians involves choosing the type of surgical procedure that will balance maximum potential for cure with an acceptable aesthetic outcome, long-term mobility, and quality of life [31]. As described above, there are a number of surgical options (limb-sparing surgery, amputation or rotationplasty) available to the orthopaedic oncology surgeon to address the issue of local control. The debate whether limb-salvage or ablative surgery is advantageous to the individual patient is centred on three outcome domains: quality of life (QoL), functional ability and physical activity. Thus, it is important to provide the surgeons and physicians as well as the patients and their parents with clear information about the outcomes of the different surgical interventions.

Quality of Life

In the last decades, several studies on QoL in patients with malignant tumours of the leg after surgery have been published. The results of these studies have been summarized into four reviews [3, 32-34]. After malignant bone tumour surgery of the leg patients reported consistently lower QoL scores within domains associated with physical functioning as compared to healthy peers, whereas mental functioning did not differ significantly [35-37]. Regarding the comparison of QoL after limb-salvage and ablative procedures, no significant differences were reported [3,32-34].

Furthermore, large-scale population-based studies among survivors of childhood cancer, reported consistently lower QoL scores in bone cancer patients compared with the general population or survivors of other cancers [36,38].

Functional Ability

Functional ability (ability to perform activities of daily living) is an important outcome measure in children and young adults after surgery for a malignant tumour of the lower

extremity. Over the last decade, several studies have been published comparing functional ability between limb-salvage and ablative surgery [39-43]. Some of these studies report significantly better functional scores in patients who had limb-salvage surgery [40], whilst other studies report no significant differences or even significant better functional scores in amputation patients [43].

Physical Activity Levels

Physical activity can be defined as any bodily movement resulting in energy expenditure [44]. Overall, knowledge on physical activity of malignant bone tumour patients is scarce. Paediatric cancer patients (leukaemia and bone tumour) were reported to be significantly less physically active than their healthy peers as evaluated with an activity monitor [45]. Moreover, patients with bone tumours were also significantly less active in comparison with leukaemia patients, either during hospitalizations or at home [45]. In addition, no statistically significant differences in physical activity levels between limb-salvage and amputation patients were reported [39,42].

Limitations

Although the literature on the outcomes after lower extremity malignant bone tumour surgery in child, adolescent and adult patients is substantial, the currently available literature has a number of limitations.

An important limitation is the common relatively small sample size. The small sample sizes are both due to the small incidence of the disease as well as the high rate of patients who died during follow-up or are lost to follow-up due to oncological and orthopaedic complications.

Another limitation is the use of generic measures to evaluate QoL whilst malignant bone tumours and their treatment may have specific consequences that are not covered by currently available measures of QoL.

Moreover, although many patients are diagnosed and treated before the age of 20, the average age at evaluation in most studies is 20 years or older. In other cases, some young children and adolescents were included, but analyses include all patients, regardless of age, as a homogenous group. This approach fails to address the specific issues that affect children and young people following amputation or limb salvage surgery.

Finally, without exception research has included mainly patients several years after their diagnosis and initial treatment. This means that little is known about the impact of surgery and drug treatment as well as complications of the disease and its treatment on the course of functional ability and QoL over time, in particular in the period immediately after chemotherapy and surgical therapy.

AIM OF THIS THESIS

Given the limitations of previous studies the aims of the thesis were:

- a. To describe quality of life, functional ability and physical activity after different surgical interventions for malignant tumours of the leg in children and adolescents.
- b. To develop and validate a disease specific instrument to measure quality of life in this patient group.

OUTLINE OF THE THESIS

The results of these studies are presented in the following chapters:

Chapter 2 describes the results of a systematic review of the literature on QoL, functional ability and physical levels after different surgical interventions for bone cancer of the leg.

In *Chapter 3* the results of a prospective, observational, multi-centre study on QoL, functional ability and physical activity levels during the first two years after malignant bone cancer surgery around the knee joint are presented.

Chapter 4 describes the results of a cross-sectional, multi-centre study on quality of life of young patients after surgery for a malignant bone tumour around the knee joint in comparison to healthy controls.

Chapter 5 includes the results of a cross-sectional, multi-centre study on functional ability and the level of physical activity in children and young adults who had different types of surgical procedures for a malignant tumour around the knee joint.

In *Chapter 6* the development of the Bone tumour (Bt)-DUX, a disease-specific instrument for health related quality of life in patients who underwent surgery for a lower extremity malignant bone tumour is presented.

Chapter 7 describes the results of a cross-cultural translation and validation of the British version of the Bt-DUX.

Finally, a summary of the results and a general discussion are given in *Chapter 8*.

REFERENCES

1. Steliarova-Foucher E, Stiller C, Kaatsch P, Berrino F, Coebergh JW, Lacour B, Parkin M. Geographical patterns and time trends of cancer incidence and survival among children and adolescents in Europe since the 1970s (the ACCIS project): an epidemiological study. *Lancet* 2004;364:2097-2105
2. Stiller CA, Bielsack SS, Jundt G, Steliarova-Foucher E. Bone tumours in European children and adolescents, 1978-1977. Report from the Automated Childhood Cancer Information System project. *Eur J Cancer* 2006;42:2124-2135
3. Nagarajan R, Neglia JP, Clohisy DR, Robison LL. Limb salvage and amputation in survivors of pediatric lower-extremity bone tumors: what are the long-term implications? *J Clin Oncol* 2002;20:4493-4501
4. Eiser C. Assessment of health-related quality of life after bone cancer in young people: Easier said than done. *Eur J Cancer* 2009;45:1744-1747
5. Damron TA, Ward WG, Stewart A. Osteosarcoma, chondrosarcoma, and Ewing's sarcoma: National Cancer Data Base Report. *Clin Orthop Relat Res* 2007;459:40-47
6. Gurney JG, Swensen AR, Bulters M (1999). Malignant bone tumors. In: Ries LAG, Smith MA e.a. (editors). *Cancer incidence and survival among children and adolescents: United States SEER program 1975-1995* (National Cancer

- Institute, NIH Publication No 99-4649, p. 99-110
7. Bielack S, Carrle D, Casali PG; ESMO Guidelines Working Group. Osteosarcoma: ESMO clinical recommendations for diagnosis, treatment and follow-up. *Ann Oncol* 2009;20:137-139
 8. Paulussen M, Bielack S, Jürgens H, Casali PG; ESMO Guidelines Working Group. Ewing's sarcoma of the bone: ESMO clinical recommendations for diagnosis, treatment and follow-up. *Ann Oncol* 2009;20 Suppl 4:140-142
 9. Bielack SS, Kempf-Biealck B, Delling G, Exner GU, Flege S, Helmke K, Kotz R, Salzer-Kuntschik M, Werner M, Winkelmann W, Zoubek A, Jürgens H, Winkler K. Prognostic factors in high-grade osteosarcoma of the extremities of trunk: an analysis of 1,702 patients treated on neoadjuvant cooperative osteosarcoma study group protocols. *J Clin Oncol* 2002;20:776-790
 10. Juergens C, Weston C, Lewis I, Whelan J, Paulussen M, Oberlin O, Michon J, Zoubek A, Juergens H, Craft A. Safety assessment of intensive induction with vincristine, ifosfamide, doxorubicin, and etoposide (VIDE) in the treatment of Ewing tumors in the EURO-E.W.I.N.G. 99 clinical trial. *Pediatr Blood Cancer* 2006;47:22-9
 11. Ladenstein R, Pötschger U, Le Deley MC, Whelan J, Paulussen M, Oberlin O, van den Berg H, Dirksen U, Hjorth L, Michon J, Lewis I, Craft A, Jürgens H. Primary disseminated multifocal Ewing sarcoma: results of the Euro-EWING 99 trial. *J Clin Oncol*. 2010;28:3284-91
 12. Bernstein M, Kovar H, Paulussen M, Randall L, Schuck A, Teof LA, Juergens H. "Ewing sarcoma family of tumors: current management". *Oncologist* 2006;11:503-19
 13. Grimer RJ. Surgical options for children with osteosarcoma. *Lancet oncol* 2005;6:85-92
 14. Wilkins RM, Camozzi AB, Gitelis SB. Reconstruction options for pediatric bone tumors about the knee. *J Knee Surg* 2005;18:305-309
 15. Fuchs B, Sim FH. Rotationplasty about the knee: surgical technique and anatomical considerations. *Clin Anat* 2004;17:345-353
 16. Merkel KD, Gebhardt M, Springfield DS. Rotationplasty as a reconstructive operation after tumor resection. *Clin Orthop Relat Res* 1991;270:231-236
 17. Steenhoff JR, Daanen HA, Taminiau AH. Functional analysis of patients who have had a modified Van Nes rotationplasty. *J Bone Joint Surg (Am)* 1993;75(10):1451-1456
 18. Deijkers RL, Bloem RM, Kroon HM, Van Lent JB, Brand R, Taminiau AH. Epidiaphyseal versus other intercalary allografts for tumors of the lower limb. *Clin Orthop Relat Res* 2005;439:151-160
 19. Muscolo DL, Ayerza MA, Aponte-Tinao LA. Massive allograft use in orthopedic oncology. *Orthop Clin North Am* 2006;37:65-74
 20. Fuchs B, Ossendorf C, Leerapun T, Sim FH. Intercalary segmental reconstruction after bone tumor resection. *Eur J Surg Oncol* 2008;34:1271-1276
 21. Ramseier LE, Malinin TI, Temple HT, Mnamyneh WA, Exner GU. Allograft reconstruction for bone sarcoma of the tibia in the growing child. *Bone Joint Surg (Br)* 2006;88-B:95-99
 22. Cara JA, Cañadell J. Limb salvage for malignant bone tumors in young children. *J Pediatr Orthop* 1994;14:112-118
 23. Eckardt JJ, Safran MR, Eilber FR, Rosen G, Kabo JM. Expandable endoprosthesis reconstruction of the skeletally immature after malignant bone tumor resection. *Clin Orthop Relat Res* 1993;297:188-202
 24. Kenan S, Bloom N, Lewis MM. Limb-sparing surgery in skeletally immature patients with osteosarcoma. The use of an expandable prosthesis. *Clin Orthop Relat Res* 1991;270:223-230
 25. Gudas SA. Rehabilitation of pediatric and adult sarcomas. *Rehabilitation Oncology* 2000;18:10-13
 26. Lane JM, Christ GH, Khan SN, Backus SI. Rehabilitation for limb salvage patients: Kinesiological parameters and psychologic assessment. *Cancer* 2001;92:1013-1019.
 27. Yadav R. Rehabilitation of surgical cancer patients at university of Texas M.D. Anderson cancer center. *J Surg Oncol* 2007;95:361-369
 28. Marchese VG, Spearing E, Callaway L, Rai SN, Zhang L, Hinds PS, Carlson CA, Neel MD, Rao BN, Ginsberg J. Relationships among range of motion, functional mobility, and quality of life in children and adolescents after limb-sparing surgery for lower-extremity sarcoma. *Pediatr Phys Ther* 2006;18:238-244
 29. Lietman SA, Joyce MJ. Bone sarcomas: overview of management, with a focus on surgical treatment considerations. *Cleveland Clinic Journal of Medicine* 2010;77:8-12
 30. Puzalan M, Hyden G. The role of physical therapy and occupational therapy in the rehabilitation of pediatric and adolescent patients with osteosarcoma. *Cancer Treat Res* 200;152:367-384

31. Ginsberg JP, Rai SN, Carlson CA, Meadows AT, Hinds PS, Spearing EM, Zhang L, Callaway L, Neel MD, Rao BN, Marchese VG. A comparative analysis of functional outcomes in adolescents and young adults with lower-extremity bone sarcoma. *Pediatr Blood Cancer* 2007;49:964-969
32. Eiser C, Grimer RJ. Quality of life in survivors of a primary bone tumour: a systematic review. *Sarcoma* 1999;4:183-90
33. Ottaviani G, Robert RS, Huh WW, Jaffe N. Functional, psychosocial and professional outcomes in long-term survivors of lower-extremity osteosarcomas: amputation versus limb salvage. *Cancer Treat Res* 2009;152:421-436
34. Paul SJ. Long Term Quality-of-Life Outcomes in Pediatric Bone Cancer: A Systematic Review. *J Nurs Stud Res* 2008;1:6-12
35. Eiser C, Cool P, Grimer RJ, Carter SR, Cotter IM, Ellis AJ, Kopel S. Quality of Life in Children Following Treatment for a Malignant Primary Bone Tumor Around the Knee. *Sarcoma* 1997;1:39-45
36. Reulen RC, Winter DL, Lancashire ER, Zeegers MP, Jenney ME, Walters SJ, Jenkinson C, Hawkins MM. Health-status of adult survivors of childhood cancer: a large-scale population-based study from the British Childhood Cancer Survivor Study. *Int J Cancer* 2007;121:633-40
37. Koopman HM, Koetsier JA, Taminiau AH, Hijnen KE, Bresters D, Egeler RM. Health-related quality of life and coping strategies of children after treatment of a malignant bone tumor: a 5-year follow-up study. *Pediatr Blood Cancer* 2005;45:694-699
38. Langeveld NE, Stam H, Grootenhuis MA, Last BF. Quality of life in young adult survivors of childhood cancer. *Support Care Cancer* 2002;10:579-600
39. Dam MS van, Kok GJ, Munneke M, Vogelaar FJ, Vliet Vlieland TP and Taminiau AHM. Measuring physical activity in patients after surgery for a malignant tumour in the leg. The reliability and validity of a continuous ambulatory activity monitor. *J Bone Joint Surg (Br)* 2001;83:1015-1019
40. Aksnes LH, Bauer HCF, Jebsen NL, Follerås, Allert C, Haugen GS, Hall KS. Limb-sparing surgery preserves more function than amputation. *J Bone Joint Surg (Br)* 2008;90:786-794
41. Nagarajan R, Clohisy DR, Neglia JP, et al. Function and quality-of-life of survivors of pelvic and lower extremity osteosarcoma and Ewing's sarcoma: The Childhood Cancer Survivor Study. *Br J Cancer* 2004;91:1858-1865
42. Hopyan S, Tan JW, Graham K, Torode IP. Function an upright time following limb salvage, amputation and rotationplasty for pediatric sarcoma of bone. *J Pediatr Orthop* 2006;26:405-408
43. Saraiva D, Camargo B de, Davis AM. Cultural adaptaptation, translation and validation of a functional outcome questionnaire (TESS) to Portugese with application to patients with lower extremity osteosarcoma. *Pediatr Blood Cancer* 2008;50:1093-1042
44. Caspersen CJ, Powell KE, Christenson GM. Physical activity, exercise, and physical fitness: definitions and distinctions for health-related research. *Public Health Rep* 1985;100:126-131
45. Winter C, Müller C, Hoffmann C, Boos J, Rosenbaum D. Physical activity and childhood cancer. *Pediatr Blood Cancer* 2009;53:438-443

