



**Universiteit  
Leiden**  
The Netherlands

## **Vestibular schwannoma treatment : patients' perceptions and outcomes**

Godefroy, W.P.

### **Citation**

Godefroy, W. P. (2010, February 18). *Vestibular schwannoma treatment : patients' perceptions and outcomes*. Retrieved from <https://hdl.handle.net/1887/14754>

Version: Corrected Publisher's Version

License: [Licence agreement concerning inclusion of doctoral thesis in the Institutional Repository of the University of Leiden](#)

Downloaded from: <https://hdl.handle.net/1887/14754>

**Note:** To cite this publication please use the final published version (if applicable).

# Chapter 6

## **Intratemporal facial nerve transfer with direct coaptation to the hypoglossal nerve**

Willem P. Godefroy  
Martijn J.A. Malessy  
Aimee A.M. Tromp  
Andel G.L. van der Mey

*Otology & Neurotology 2007;28:546-550*

## Abstract

**Objective:** To evaluate functional recovery after facial-hypoglossal nerve transfer with direct coaptation of the intratemporal part of the facial nerve.

**Study Design:** Retrospective study.

**Setting:** University-based tertiary referral center.

**Patients:** Nine patients who underwent facial-hypoglossal transfer surgery between 2001 and 2006 to treat unilateral complete facial nerve palsy.

**Intervention:** The facial nerve is mobilized in the temporal bone, transected at the second genu, transferred and directly coaptated to a partially incised hypoglossal nerve.

**Main Outcome Measures:** The House-Brackmann grading system was used to evaluate facial nerve reinnervation. Tongue atrophy and movements were documented. Quality of life related to facial function was assessed using the validated Facial Disability Index.

**Results:** A House-Brackmann Grade III (86%) was achieved in six patients, and Grade IV (14%) in one patient with an average follow-up of 22 months (range, 12-48 mo). Two patients had a follow-up of less than 12 months after surgery, and reinnervation was still in progress. In none of the patients who were operated on was tongue atrophy or impaired movement observed. Postoperative Facial Disability Index scores (mean,  $71.8 \pm (SD) 10.6$ ) for physical functioning and social functioning (mean,  $85.7 \pm 9.8$ ) were increased for all patients when compared with preoperative scores (mean,  $28.6 \pm 9.0$ ; mean,  $37.7 \pm 14.4$ , respectively).

**Conclusion:** The facial-hypoglossal nerve transfer with direct coaptation of the intratemporal part of the facial nerve offers good functional results with low lingual morbidity and improved quality of life. The technique is straightforward, relatively simple, and should be considered as first option for reanimation of traumatic facial nerve lesions.

## Introduction

Traumatic facial nerve lesions may potentially cause lifelong functional, cosmetic, and emotional problems (1,2). When facial nerve continuity is lost, preferably, immediate nerve repair through primary neurorrhaphy with direct coaptation or grafting should be attempted. When continuity is intact, but spontaneous recovery does not occur, delayed repair through hypoglossal-facial nerve transfer is a treatment option. The classic hypoglossal-facial end-to-end nerve transfer (classic HFT) has long been advocated as the primary choice (3,4). In this technique, the hypoglossal nerve is completely transected and transferred to the facial nerve, which is transected at the stylomastoid foramen level, to obtain direct coaptation. Classic HFT inevitably results in hemiglossal paralysis and hemitongue atrophy, which in turn affects speech, mastication, and swallowing in 45% to 59% (5,6). Additional disadvantage of the classic HFT is hypertonia, spasm, and synkinesis in the facial musculature due to massive reinnervation (5).

In an effort to reduce the adverse effects of HFT, a number of technical modifications have been applied (Table 1). For instance, only a part of the hypoglossal nerve is transected and transferred by longitudinally splitting (split HFT) (7,8). Functional results of facial reanimation are good (100% House-Brackmann Grade III), but all patients experienced some degree of hemiglossal atrophy. Another modification of the HFT was introduced by May et al. (9) using a “jump” interposition graft between a partially incised hypoglossal nerve and the facial nerve. Results showed preservation of tongue function in 87% of patients. However, a longer recovery time was observed, and facial muscle reanimation is less than after the classic technique. The latter is likely caused by the use of a graft, which causes loss of regenerating axons at two coaptation sides. In addition, morbidity related to harvesting of a nerve graft has been reported (10). To avoid the use of a graft, Atlas and Lowinger (11) described the transfer of the intratemporal facial nerve to gain facial nerve length and obtain a direct coaptation to the hypoglossal nerve. Since the initial report of this technique, few studies have reported about the outcome of this technique, and only small patient cohorts are described (12-15). Results of facial function are claimed to be as good as those in patients who underwent classic HFT, however, without additional deficits. The purpose of this study was to present this relatively new modification and evaluate surgical outcome.

**Table 1.** Overview of hypoglossal-facial nerve modifications.

First author	Coaptation technique	N	Interval from FP to RFS (mo)	H-B grade in %						Tongue atrophy (n)		
				II	III	IV	V	VI	M	MO	S	
Conley and Baker (3)	classic	137	2-55	65	18	17			1	70	37	
Magliulo et al. (19)	classic	10	1-23	40	50	10			2	5	3	
Kunihiro et al. (20)	classic	42	3 - 33	2	38	52	7		27	7	8	
May et al. (9)	graft	20	0 - 48		80	15	5		21	1	0	
Manni et al. (21)	graft	29	4 - > 24	21	45	24	7	3	0	0	0	
Arai et al. (8)	split	8	1 - 6		100				3	5	0	
Atlas and Lowinger (11)	direct	3	2-6			100			0	0	0	
Donzelli et al. (14)	direct	3	12-14		33	67			3	0	0	
Sawamura and Abe (12)	direct	4	20-37		75	25			0	0	0	
Darrouzet et al. (13)	direct	6	0-110		83	17			2	0	0	
Rebol et al. (15)	direct	5	8-13		40	20	20	20	0	0	0	

FP, facial paralysis; RFS, rehabilitative facial surgery; H-B, House-Brackmann; M, minimal; MO, moderate; S, severe; classic, end-to-end HFT; graft, hypoglossal-facial nerve interposition jump graft; split, HFT with a split hypoglossal nerve; direct, HFT with direct coaptation of the intratemporal facial nerve.

## Materials and Methods

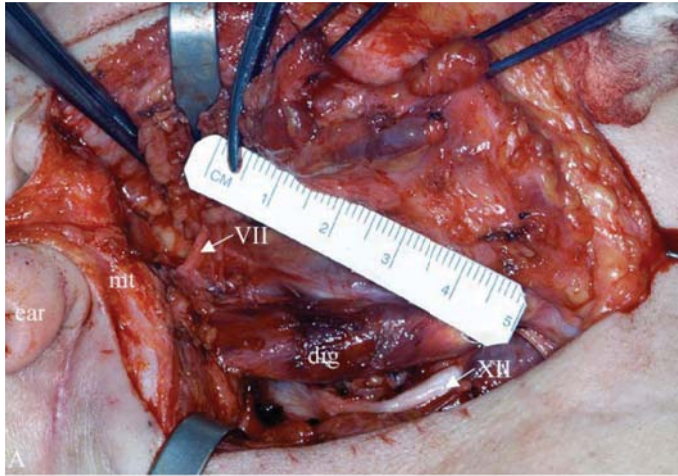
### Patients

A total of nine patients underwent facial-hypoglossal nerve transfer with direct coaptation (FHT) between August 2001 and May 2006 and were retrospectively examined. These patients presented with a unilateral complete facial nerve paralysis after surgery for vestibular schwannoma (n = 5), cerebellar pilocytic astrocytoma (n = 1), cholesteatoma (n = 1), and facial nerve schwannoma (n = 1). One patient had progressive facial paralysis (H-B Grade V) due to progression of a jugulotympanic glomus tumor. The average time interval between facial paralysis and reconstructive surgery was 7.8 months (range, 0-15 mo). Facial nerve function was recorded at a minimum of 12 months after surgery and using the House-Brackmann (H-B Grades I-VI) classification (16). Tongue atrophy was photographically documented and separately quantified by two observers (one of the senior authors and the first author) as severe, moderate, low, or absent. Tongue movements were scored as

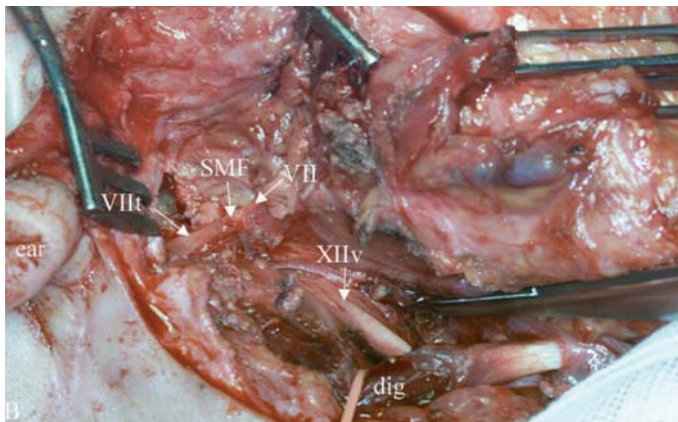
normal or abnormal. Patients reported both their preoperative and postoperative facial function using the Dutch translated version of the Facial Disability Index (FDI) questionnaire at the end stage of reinnervation. The FDI is a disease-specific, self-report instrument for the assessment of disabilities of patients with facial nerve disorders as perceived from the patients' perspective. It consists of 10 questions that indicate the level of social handicap (FDI-social) and physical disability (FDI-physical) from facial nerve dysfunction. Both indices use a 100-point scale with higher scores indicating less handicap or less disability (17,18).

### **Surgical technique**

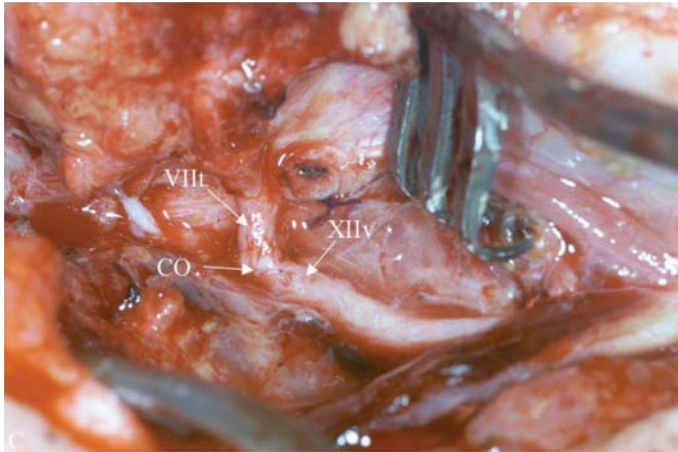
A lazy S-shaped parotid incision was made toward the mastoid tip and then extended along the anterior edge of the sternocleidomastoid muscle to the hyoid bone. Identification of the extratemporal part of the facial nerve was performed using the tragal pointer and posterior belly of the digastric muscle. The facial nerve was mobilized in its distal part as far as the trifurcation in the parotid gland. The sternocleidomastoid muscle was retracted posteriorly for maximal exposure of the mastoid process, and the proximal portion of the facial nerve was dissected free up to the stylomastoid foramen (Figure 1A). The mastoid was drilled until the facial nerve was exposed from the level of the stylomastoid foramen to the external facial nerve genu, transected at the external genu and transferred (Figure 1B). In this way, additional facial nerve length of 1.5 to 2 cm was obtained, allowing for a tensionless coaptation to the hypoglossal nerve. The hypoglossal nerve was found at the level of the carotid bifurcation and dissected as proximally as possible. A tailor-made partial transection of the hypoglossal nerve was subsequently performed at the site where the transferred distal facial nerve would be coapted, which was equal to the cross-sectional diameter of the facial nerve. Usually this was less than half of the hypoglossal nerve diameter. A tensionless coaptation between the two nerve endings, the proximal "hemi"-transected hypoglossal nerve and the distal part of the facial nerve, was made (Figure 1C). The epineurium and perineurium of the two endings were sutured using three Ethilon (Ethicon, Amersfoort, The Netherlands) 10.0 nylon sutures and Tissucol (Immuno AG, Vienna, Austria) fibrin glue was applied.



**Figure 1.** Intraoperative photographs of FHT. A: The 7th (VII) and 12th (XII) nerves are dissected, respectively (mt: mastoid tip; dig: digastric muscle).



**Figure 1.** B: The stylomastoid foramen (SMF) is dissected and the intratemporal part (VIIIt) of the 7th nerve is exposed after drilling the mastoid tip (XIIv: vertical part of the 12th nerve).



**Figure 1. C:** The intratemporal 7th nerve is transferred (VIIIt) to the vertical part of the 12th nerve (XIIv) in an end-to-side coaptation (CO).

## Results

The study comprised 7 female and 2 male patients with mean age of 35.4 years (range, 9-61 yr). The patients' facial muscle tonus showed first signs of recovery at 6 months postoperatively and with movements recorded around the mouth. In 2 patients, follow-up was less than 6 months, and this is too short a period for the reinnervation process. Results of facial nerve function in the remaining 7 patients showed H-B Grade III (86%) in 6 patients and H-B Grade IV (14%) in 1 at an average follow-up of 22 months after surgery (range, 12-48 mo) (Table 2; Figures 2A, B). The follow-up time in the patient with H-B Grade IV was relatively short (13 mo). Tongue atrophy was absent in all patients, and tongue function was normal (Figure 2C). Preoperative and postoperative FDI subscores are provided in Table 3. There was a significant difference between preoperative and postoperative FDI-physical and FDI-social subscores (Wilcoxon signed rank test,  $p < 0.05$ ). Average FDI physical scores were 28.6 points (SD  $\pm 9.0$ ) preoperatively and 71.8 points (SD  $\pm 10.6$ ) postoperatively. Average FDI social scores were preoperatively 37.7 points (SD  $\pm 14.4$ ) and 85.7 points (SD  $\pm 9.8$ ) postoperatively. All 7 patients reported improved FDI scores on both subscales. There were no surgical complications in the patients who were operated on.



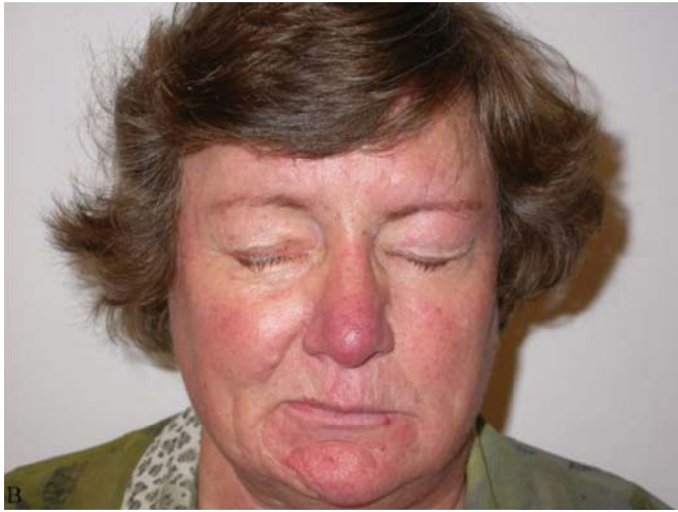**Table 2.** Results and characteristics of the patients who were operated on.

Patient no.	Age (yr)	Sex	Cause of facial paralysis	Preoperative (H-B)	Postoperative (H-B)	Interval lesion -surgery (mo)	Follow-up (mo)
1.	28	M	vestibular schwannoma	VI	III	5	12
2.	54	F	astrocytoma	VI	III	12	17
3.	19	F	vestibular schwannoma	VI	III	15	48
4.	16	F	glomus tumor	V	III	7	12
5.	61	F	vestibular schwannoma	VI	III	3	32
6.	52	F	vestibular schwannoma	VI	III	3	20
7.	38	F	vestibular schwannoma	VI	*	11	3
8.	9	M	cholesteatoma	VI	IV	14	13
9.	38	F	facial nerve schwannoma	VI	*		6

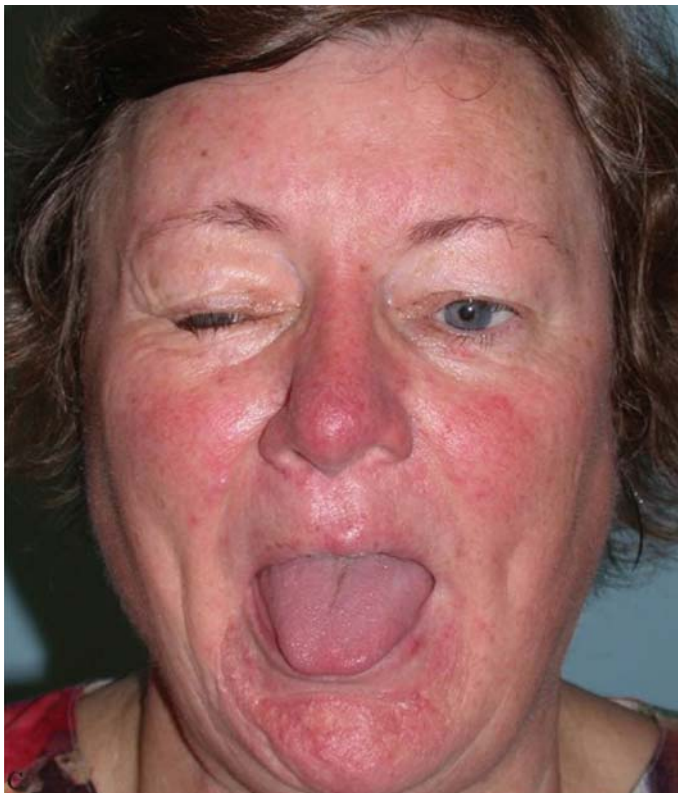H-B, House-Brackmann; M, male; F, female; \* : incomplete follow up, no grading performed.



**Figure 2.** Case 6. Postoperative outcome 12 months after this patient underwent FHT on the right side. A: Patients' face at rest.



**Figure 2. B:** Patient closing both eyes.



**Figure 2. C:** Patient closing her right eye firmly by using her tongue and no tongue atrophy or lingual hemiparesis is observed.

**Table 3.** Mean preoperative and postoperative FDI scores.

<b>FDI</b>	<b>Preoperative</b>	<b>SD</b>	<b>Postoperative</b>	<b>SD</b>
FDI-physical	28.6	9.0	71.8 *	10.6
FDI-social	37.7	14.4	85.7 *	9.8

FDI indicates Facial Disability Index; \*  $p < 0.05$ ; SD, standard deviation.

## Discussion

The hypoglossal nerve can be used for dynamic rehabilitation of facial nerve function. Indications are when the proximal stump of the facial nerve is unavailable or when after neurotologic surgery, an anatomically intact facial nerve, does not recover in time. Several modifications to the classic HFT have been proposed to improve facial function and minimize tongue function deficits (7-9). In this study, we have used a relatively new technique in which 1.5 to 2 cm of facial nerve is freed from its canal in the mastoid bone to perform a direct coaptation to a restricted part of the hypoglossal nerve. Using this technique, in 86% of our patients, we achieved the main goals of rehabilitative facial surgery: functional oral sphincter musculature and sufficient eye closure to prevent any eye problems. In addition, tongue function was preserved in all patients, and no tongue atrophy was observed. Our results confirm those of FHT published by other authors (11-13). The FHT is a relatively straightforward and easy technique as compared with modifications with the application of nerve grafts. It is also a safer procedure because there is only one nerve coaptation site. This factor reduces the potential risk of failure of the reconstructive procedure caused by dehiscence.

After facial nerve rehabilitation, patients experience some mass movement and often a nonfunctional frontal muscle. In practice, functional recovery is rarely better than H-B Grade III. The House-Brackmann grading system is widely used by surgeons to grade facial nerve function and rate their surgical success, but it does not reflect the patients' perception of their surgical results. Therefore, we also evaluated outcome using a quality of life (QoL) assessment related to facial nerve function (17). In this study, significantly higher FDI scores on physical functioning and social functioning were found after surgery as compared with preoperative FDI scores. Patients reported functional improvement while eating, drinking, or closing the eye,

and less social limitations related to their facial function. However, one should be cautious while interpreting QoL test results. The patient sample is small, and the preoperative facial function FDI was scored at the same time as the postoperative FDI score and therefore may be biased. Functional nerve recovery is inversely related to the interval between nerve lesion and nerve repair (22, 23). The timing of hypoglossal nerve transfer is difficult, especially after removal of tumor in the cerebellopontine angle when facial nerve continuity is anatomically spared, but postoperative facial muscle reinnervation does not take place. In such instance, we currently perform electromyography examination of the facial musculature at 6 months. If there are no signs of reinnervation in any of the three facial nerve branches, facial-hypoglossal nerve transfer is performed soon after.

## Conclusion

The facial-hypoglossal nerve transfer with direct coaptation of the intratemporal part of the facial nerve offers comparable facial nerve function results without lingual morbidity. The FHT is relatively simple and straightforward and is now our first option. Our results are comparable to those of alternative techniques.

## References

1. Coulson SE, O' Dwyer NJ, Adams RD, Croxson GR. Expression of emotion and quality of life after facial nerve paralysis. *Otol Neurotol* 2004;25:1014-1019.
2. de Swart BJ, Verheij JC, Beurskens CH. Problems with eating and drinking in patients with unilateral peripheral facial paralysis. *Dysphagia* 2003;18:267-273.
3. Conley J, Baker DC. Hypoglossal-facial nerve anastomosis for reinnervation of the paralyzed face. *Plast Reconstr Surg* 1979;63:63-72.
4. Gavron JP, Clemis JD. Hypoglossal facial nerve anastomosis: a review of forty cases caused by facial nerve injuries in the posterior fossa. *Laryngoscope* 1984;94:1447-1450.
5. Hammerschlag PE. Facial reanimation with jump interpositional graft hypoglossal facial anastomosis and hypoglossal facial anastomosis: evolution in management of facial paralysis. *Laryngoscope* 1999;109:1-23.
6. Schaitkin BM, Young T III, Robertson JS. Facial reanimation after acoustic neuroma excision: the patient's perspective. *Laryngoscope* 1991;101:889-894.
7. Cusimano MD, Sekhar L. Partial hypoglossal to facial nerve anastomosis for reinnervation of the paralyzed face in patients with lower cranial nerve palsies: technical note. *Neurosurgery* 1994;35:532-534.
8. Arai H, Sato K, Yanai A. Hemihypoglossal-facial nerve anastomosis in treating unilateral facial palsy after acoustic neurinoma resection. *J Neurosurg* 1995;82:51-54.
9. May M, Sobol SM, Mester SJ. Hypoglossal-facial nerve interpositional jump graft for facial reanimation without tongue atrophy. *Otolaryngol Head Neck Surg* 1991;104:818-825.
10. Miloro M, Stoner JA. Subjective outcomes following sural nerve harvest. *J Oral Maxillofac Surg* 2005;63:1150-1154.
11. Atlas MD, Lowinger DS. A new technique for hypoglossal-facial nerve repair. *Laryngoscope* 1997;107:984-991.
12. Sawamura Y, Abe H. Hypoglossal facial nerve side-to-end anastomosis for preservation of hypoglossal function: results of delayed treatment with a new technique. *J Neurosurg* 1997;86:203-206.
13. Darrouzet V, Guerin J, Bebear JP. New technique of side-to-end hypoglossal-facial nerve attachment with translocation of the infratemporal facial nerve. *J Neurosurg* 1999;90:27-34.
14. Donzelli R, Motta G, Cavallo LM, Maiuri F, De Divitiis E. One stage removal of residual intracanalicular acoustic neuroma and hemi-hypoglossal intratemporal facial nerve anastomosis: technical note. *Neurosurg* 2003;53:1444-1447.
15. Rebol J, Milojkovic V, Didanovic V. Side-to-end hypoglossalfacial anastomosis via transposition of the intratemporal facial nerve. *Acta Neurochir* 2006;148:653-657.
16. House JW, Brackmann DE. Facial nerve grading system. *Otolaryngol Head Neck Surg* 1985;93:146-147.
17. Van Swearingen JM, Brach JS. The Facial Disability Index: reliability and validity of a disability assessment instrument for disorders of the facial neuromuscular system. *Phys Ther* 1996;76:1288-1298.
18. Brach JS, Van Swearingen JM, Delitto A, Johnson PC. Impairment and disability in patients with facial neuromuscular dysfunction. *Otolaryngol Head Neck Surg* 1997;117:315-321.
19. Magliulo G, D' Amico R, Forino M. Results and complications of facial reanimation following cerebellopontine angle surgery. *Eur Arch Otorhinolaryngol* 2001;258:45-48.

20. Kunihiro T, Higashino K, Kanzaki J. Classic hypoglossal-facial nerve anastomosis after acoustic neuroma resection. A review of 46 cases. *ORL J Otorhinolaryngol Relat Spec* 2003;65:1-6.
21. Manni JJ, Beurskens CH, van de Velde C, Stokroos RJ. Reanimation of the paralyzed face by indirect hypoglossal-facial nerve anastomosis. *Am J Surg* 2001;182:268-273.
22. Fu SY, Gordon T. Contributing factors to poor functional recovery after delayed nerve repair: prolonged denervation. *J Neurosci* 1995;15:3886-3895.
23. Fu SY, Gordon T. Contributing factors to poor functional recovery after delayed nerve repair: prolonged axotomy. *J Neurosci* 1995;15:3876-3885.

