



Universiteit
Leiden
The Netherlands

Ultrasound studies in monochorionic twin pregnancies : results of TULIPS: Twins and ultrasound in pregnancy studies

Sueters, M.

Citation

Sueters, M. (2007, June 5). *Ultrasound studies in monochorionic twin pregnancies : results of TULIPS: Twins and ultrasound in pregnancy studies*. Retrieved from <https://hdl.handle.net/1887/12084>

Version: Corrected Publisher's Version

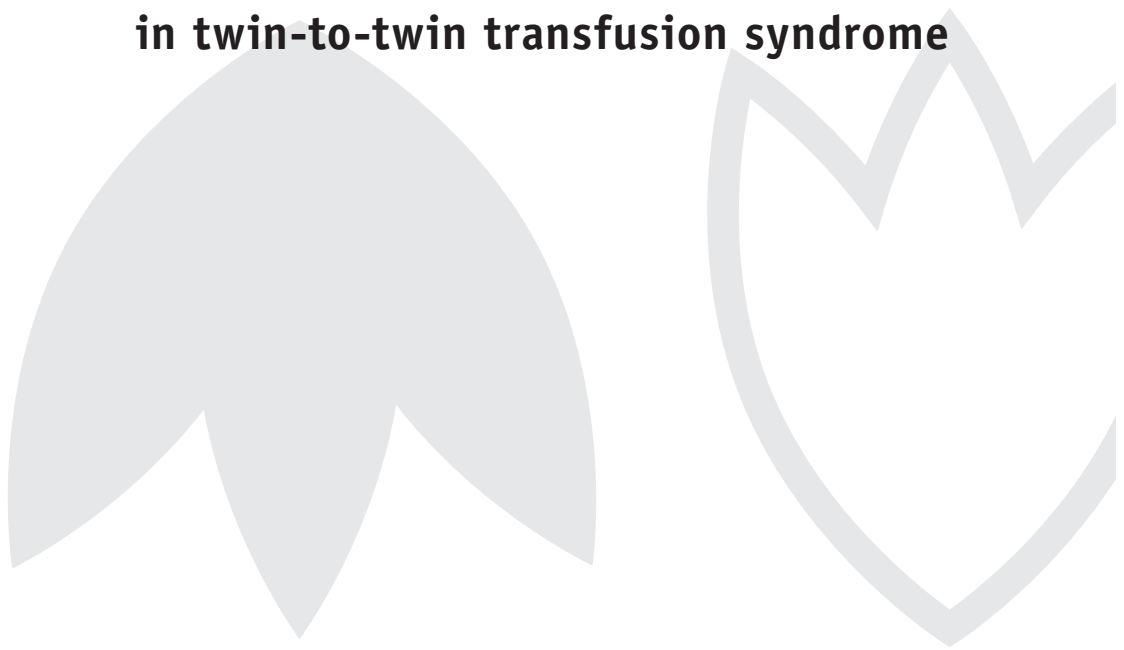
License: [Licence agreement concerning inclusion of doctoral thesis in the Institutional Repository of the University of Leiden](#)

Downloaded from: <https://hdl.handle.net/1887/12084>

Note: To cite this publication please use the final published version (if applicable).

Chapter 6

The effect of fetoscopic laser therapy on fetal cardiac size in twin-to-twin transfusion syndrome



Marieke Sueters
Johanna M. Middeldorp
Frank P.H.A. Vandenbussche
Katinka A. Teunissen
Enrico Lopriore
Humphrey H.H. Kanhai
Saskia Le Cessie
Dick Oepkes

Ultrasound Obstet Gynecol 2007, accepted for publication

Abstract

Objective To evaluate the influence of fetoscopic laser therapy on fetal cardiac size in monochorionic twins complicated by twin-to-twin transfusion syndrome (TTTS).

Methods In a longitudinal, prospective study, we assessed sonographically the fetal cardiac size in monochorionic diamniotic twins with TTTS treated with laser therapy and in monochorionic twins without TTTS. The fetal cardiothoracic ratio (cardiac circumference divided by thoracic circumference) of TTTS twins was determined within 24 h before, 12 to 24 h after and 1 week after laser treatment, and from then on every 2 to 4 weeks until birth. TTTS twins were classified at Quintero Stage 1-2 (n=18) and Stage 3-4 (n=16) and measurements were compared to biweekly measurements of non-TTTS monochorionic twins matched for gestational age (n=38). Cardiomegaly was defined as a cardiothoracic ratio above the 97.5th percentile.

Results Before laser treatment, cardiomegaly was observed in 44% (8/18) and in 50% (8/16) of recipients at Quintero Stage 1-2 and Stage 3-4, respectively. Cardiomegaly occurred in none of the donors before treatment. After laser treatment, cardiomegaly was observed in 76% (13/17) and 50% (7/14) of recipients at Stage 1-2 and Stage 3-4, respectively. Cardiomegaly was found in 17% (3/18) and 13% (2/15) of donors at Stage 1-2 and Stage 3-4, respectively. Non-TTTS monochorionic twins and singletons showed cardiomegaly in 18% (7/38) and 8% (2/25).

After laser therapy, cardiothoracic ratios of recipients at Stage 1-2 and Stage 3-4 were not significantly changed (p=0.34 and 0.67, respectively). Cardiothoracic ratios of donors in Stage 1-2 and Stage 3-4 were increased compared to their cardiothoracic ratios before laser therapy (p-values 0.0002 and 0.005, respectively). Cardiothoracic ratios of non-TTTS monochorionic twins were not significantly different from our reference range in singletons throughout gestation, and were smaller as compared to both recipients and donors after laser therapy.

Conclusion Recipients show cardiomegaly both before as well as after fetoscopic laser therapy for TTTS. Donors develop cardiomegaly only after laser treatment for TTTS. Our findings emphasize the significant effect of TTTS and fetoscopic laser therapy on the fetal hearts of both recipient and donor twins.

Introduction

Twin-to-twin transfusion syndrome (TTTS) is a severe complication that occurs in 15% of monochorionic diamniotic twin pregnancies during the second trimester¹. TTTS originates from unbalanced blood transfusion through placental vascular anastomoses from one twin (donor) to the other (recipient) and is diagnosed sonographically by the presence of an oligo/polyhydramnios sequence². If left untreated, TTTS is associated with extremely high mortality and morbidity rates³⁻⁵. Nowadays, fetoscopic laser coagulation of vascular anastomoses is the treatment of choice in severe second-trimester TTTS⁶.

When TTTS occurs, recipient twins present in 55 to 100% with signs of cardiac compromise, including biventricular hypertrophy, tricuspid regurgitation, and right ventricular outflow tract obstruction (RVOTO), that may continue to progress despite adequate therapy⁷⁻¹⁵. Although less frequently documented, fetal donor hearts may also suffer from hemodynamic changes caused by TTTS or its therapy¹⁵. One of the parameters to obtain useful information on impending cardiac failure, is the assessment of the degree of cardiomegaly¹⁶.

Fetoscopic laser therapy for TTTS aims at interrupting the intertwin transfusion process and is associated with important changes in the hemodynamic situation of both donor and recipient. Abnormal Doppler flow profiles, in both recipients and donors, have been shown to improve after laser treatment¹⁷⁻¹⁹. The objective of this study was to evaluate the influence of TTTS and fetoscopic laser therapy on fetal cardiac size.

Methods

Population

Leiden University Medical Center (LUMC) is the national referral center for fetoscopic laser treatment for TTTS in the Netherlands. During a two-year period (September 2002 - September 2004), a consecutive cohort of monochorionic diamniotic twin pregnancies with TTTS referred to the LUMC and a cohort of monochorionic diamniotic twin pregnancies without TTTS from our own region were followed in a longitudinal, prospective approach. Monochorionicity was diagnosed by a first-trimester scan showing twins with absent lambda- and present "T" sign, and was confirmed by postpartum placental studies. Pregnancies with fetal congenital anomalies (n=1) were excluded.

TTTS was diagnosed by the presence of oligo/polyhydramnios sequence in the absence of other causes between 15 and 26 weeks of gestation. Polyhydramnios and oligohydramnios were defined as a deepest vertical pocket of amniotic fluid of >8 cm at ≤ 20 weeks (or >10 cm at >20 weeks) and <2 cm, respectively. TTTS severity was assessed according to Quintero's established criteria²: Stage 1, isolated oligo/polyhydramnios sequence; Stage 2, absent visible bladder of the donor twin; Stage 3, critically abnormal Doppler studies (absent/reversed end-

Table 1 Pregnancy data for donors and recipients at Quintero Stage 1-2 and Stage 3-4 and non-TTTS monochorionic twins

	Donors at Quintero Stage 1-2 (n=18)	Recipients at Quintero Stage 1-2 (n=18)	Donors at Quintero Stage 3-4 (n=16)	Recipients at Quintero Stage 3-4 (n=16)	Non-TTTS monochorionic twins (n=38)	p-value
Gestational age in weeks* at						
- laser treatment	19.5 (15.6-24.7)	19.5 (15.6-24.7)	19.9 (16.1-23.9)	19.9 (16.1-23.9)		0.76
- delivery	35.7 (22.6-39.0)	35.7 (22.6-39.0)	30.8 (18.3-38.0)	30.8 (18.3-38.0)	36.1 (19.1-38.7)	0.006
Perinatal survival ^a	94% (17/18)	78% (14/18)	63% (10/16)	50% (8/16)	95% (36/38)	0.002

^a Values are reported as percentages (numbers); *values are reported as medians (range). TTTS, twin-to-twin transfusion syndrome.

diastolic flow of the umbilical artery, absent/reversal of flow during atrial contraction in the ductus venosus, or pulsatile flow pattern of the intrahepatic part of the umbilical vein; Stage 4, hydrops in either fetus; Stage 5, demise of one or both twins. Pregnancies complicated by TTTS \geq Quintero Stage 2 or Quintero Stage 1 with clinically important polyhydramnios were treated using laser ablation of the communicating placental vessels combined with a single amniodrainage at the end of the laser procedure^{6,20}. Patients with unreliable identification of former donor and recipient at post-laser treatment ultrasonography due to iatrogenic intertwin membrane perforation during laser treatment were excluded (n=2).

Fifty-three twin pairs remained available for analysis. In total, 1002 ultrasound examinations of 106 twin fetuses were performed. In 19 pregnancies, no signs of TTTS developed. TTTS was diagnosed and treated with fetoscopic laser therapy in 34 pregnancies. The fetuses were divided into five groups: donors at Quintero Stage 1-2 (n=18) and Stage 3-4 (n=16), recipients at Quintero Stage 1-2 (n=18) and Stage 3-4 (n=16), and non-TTTS monochorionic twins (n=38). Clinical details of donors, recipients, and non-TTTS monochorionic twins are listed in Table 1.

The hospital's institutional review board approved the study. All patients gave informed consent.

Echocardiography

TTTS twins were scanned within 24 h before, 12 to 24 h after and 1 week after laser treatment, and from then on at least every 2 to 4 weeks until birth. In non-TTTS monochorionic twins, ultrasound examinations were performed biweekly from 12-16 weeks' gestation onwards until birth. Measurements were obtained in the absence of fetal breathing or movements by one of two experienced operators (MS, KAT) using an Acuson Sequoia (Acuson, Mountain View, CA) ultrasound machine with a 4.0 to 6.0 MHz probe. B-mode cardiothoracic ratio was determined from a frozen image of a transverse scan of the fetal thorax with the four-chamber view of

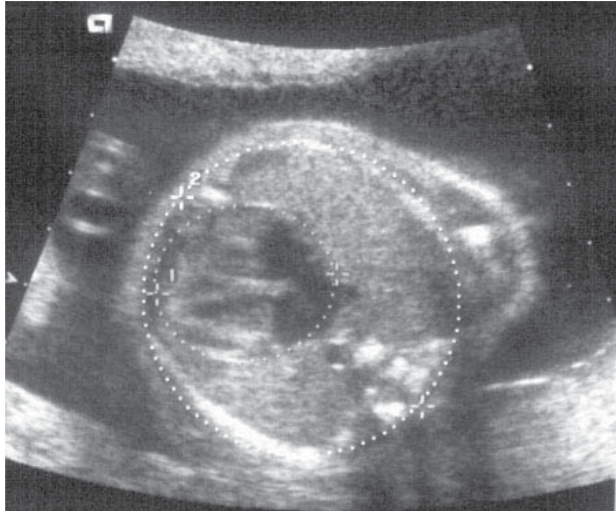


Figure 1 Cardiothoracic ratio

the heart in diastole¹⁶. Images were considered appropriate if two complete ribs could be visualized without fetal abdominal organs present in the same view. The cardiac circumference was measured on the outer border of the pericardium and the thoracic circumference was measured on the outer border of the ribs (Figure 1), and the ratio between the two circumferences was calculated. Cardiothoracic ratio measurements were plotted on a reference range recently established at our own institution using the same method in a normal singleton population (submitted for publication). Cardiomegaly was defined as a cardiothoracic ratio above the 97.5th percentile for gestation.

Statistical Analyses

Differences in gestational age at laser treatment and at delivery between TTTS twin pairs and non-TTTS monochorionic twin pairs were analyzed with a one-way anova. Percentage of perinatal (fetal and early neonatal, until 7 days postpartum) survival was defined as 100x the number of live born children divided by the number of fetuses in each group. Differences in perinatal survival between donors, recipients, and non-TTTS monochorionic twins were analyzed using a logistic regression model with a random twin effect.

To study the relation between the cardiothoracic ratio and gestational age and to study differences between the subgroups (donors at Quintero Stage 1-2 and Stage 3-4, recipients at Quintero Stage 1-2 and Stage 3-4, and non-TTTS monochorionic twins), linear regression models were used with gestational age and group as independent variables. Parameters in the regression models were estimated using Generalized Estimation Equations (GEE)²¹ to take into account that repeated measurements on the same fetus were taken and that dependency between the outcomes within a twin pair could exist.

Results

Figure 2 shows the cardiothoracic ratios of donors and recipients during gestation plotted on our reference range for cardiothoracic ratio in normal singletons.

Figure 3 shows the estimated mean (p50) cardiothoracic ratios of donors, recipients and singletons during gestation.

Table 2 demonstrates the cardiothoracic ratios of donors and recipients at Quintero Stages 1-2 and Stages 3-4 before laser therapy compared to each other, to non-TTTS monochorionic twins, and to our reference range for cardiothoracic ratios in normal singletons.

Before laser treatment, cardiomegaly was observed in 44% (8/18) and in 50% (8/16) of recipients at Quintero Stage 1-2 and Stage 3-4, respectively. Cardiomegaly occurred in none of the donors at Stage 1-2 and Stage 3-4. After laser treatment, cardiomegaly was observed in 76% (13/17) and 50% (7/14) of recipients at Stage 1-2 and Stage 3-4, respectively. Cardiomegaly was found in 17% (3/18) and 13% (2/15) of donors at Stage 1-2 and Stage 3-4, respectively. Non-TTTS monochorionic twins and singletons showed cardiomegaly in 18% (7/38) and 8% (2/25).

Table 3 demonstrates the cardiothoracic ratios of donors and recipients at Quintero Stages 1-2 and Stages 3-4 after laser therapy compared to their cardiothoracic ratios before laser treatment, to each other, to non-TTTS monochorionic twins, and to our reference range for cardiothoracic ratios in normal singletons.

Figure 4 shows the mean differences of cardiothoracic ratios of donors and recipients at Quintero Stage 1-2 and Stage 3-4 compared to normal singletons, as function of weeks post-laser therapy.

Table 2 Cardiothoracic ratios of donors and recipients at Quintero Stage 1-2 and Stage 3-4 before fetoscopic laser therapy compared to each other, to non-TTTS monochorionic twins, and to our reference range for cardiothoracic ratios in normal singletons

	Mean difference (increase (+) or decrease (-)) of cardiothoracic ratios for Quintero Stage 1-2	p-value	Mean difference (increase (+) or decrease (-)) of cardiothoracic ratios for Quintero Stage 3-4	p-value
Donors compared to recipients	-0.051	<0.0001	-0.090	<0.0001
Donors compared to non-TTTS monochorionic twins	-0.011	0.21	-0.017	0.11
Donors compared to singletons	-0.017	0.04	-0.023	0.03
Recipients compared to non-TTTS monochorionic twins	+0.040	<0.0001	+0.072	<0.0001
Recipients compared to singletons	+0.034	0.0007	+0.066	<0.0001
Non-TTTS monochorionic twins compared to singletons	-0.007	0.15	-0.007	0.15

TTTS, twin-to-twin transfusion syndrome.

Table 3 Cardiothoracic ratios of donors and recipients at Quintero Stage 1-2 and Stage 3-4 after fetoscopic laser therapy for TTTS compared to their cardiothoracic ratios before laser treatment, to each other, to non-TTTS monochorionic twins, and to our reference range for cardiothoracic ratios in normal singletons

	Mean difference (increase (+) or decrease (-)) of cardiothoracic ratios for Quintero Stage 1-2	p-value	Mean difference (increase (+) or decrease (-)) of cardiothoracic ratios for Quintero Stage 3-4	p-value
Donors after laser therapy compared to donors before laser therapy	+0.029	0.0002	+0.031	0.005
Donors after laser therapy compared to recipients after laser therapy	-0.032	<0.0001	-0.054	0.0001
Donors after laser therapy compared to non-TTTS monochorionic twins	+0.015	0.02	+0.010	0.13
Donors after laser therapy compared to singletons	+0.006	0.31	+0.002	0.74
Recipients after laser therapy compared to recipients before laser therapy	+0.010	0.34	-0.005	0.67
Recipients after laser therapy compared to non-TTTS monochorionic twins	+0.056	<0.0001	+0.065	<0.0001
Recipients after laser therapy compared to singletons	+0.038	<0.0001	+0.056	0.0001
Non-TTTS monochorionic twins compared to singletons	-0.007	0.15	-0.007	0.15

TTTS, twin-to-twin transfusion syndrome.

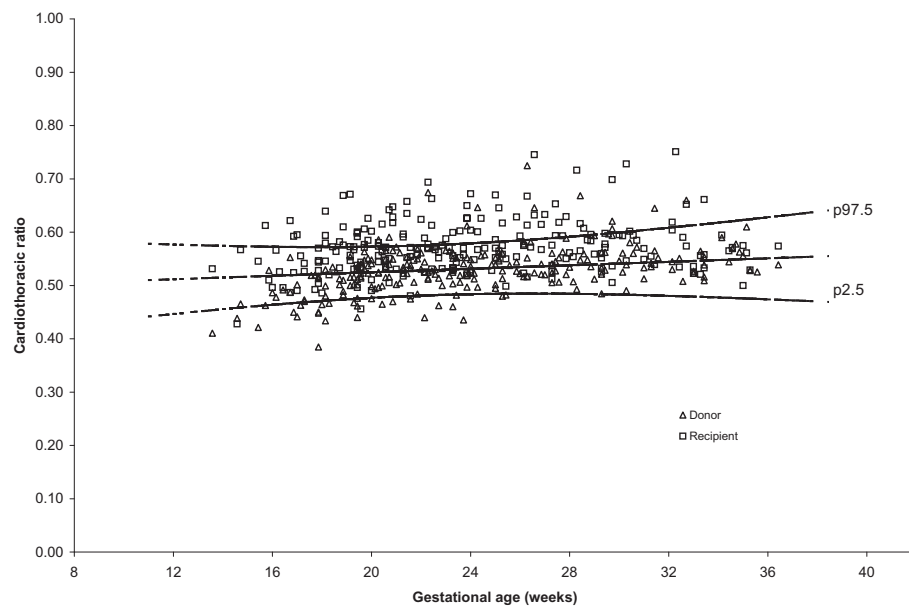


Figure 2 Cardiothoracic ratios of donors and recipients during gestation plotted on our reference range for cardiothoracic ratios in normal singletons

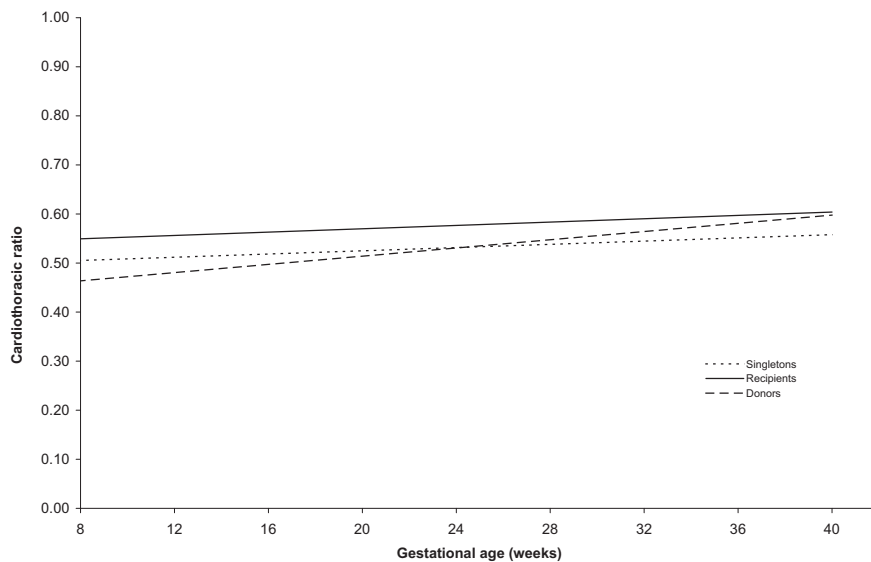


Figure 3 Estimated mean (p50) cardiothoracic ratios of donors, recipients and singletons during gestation

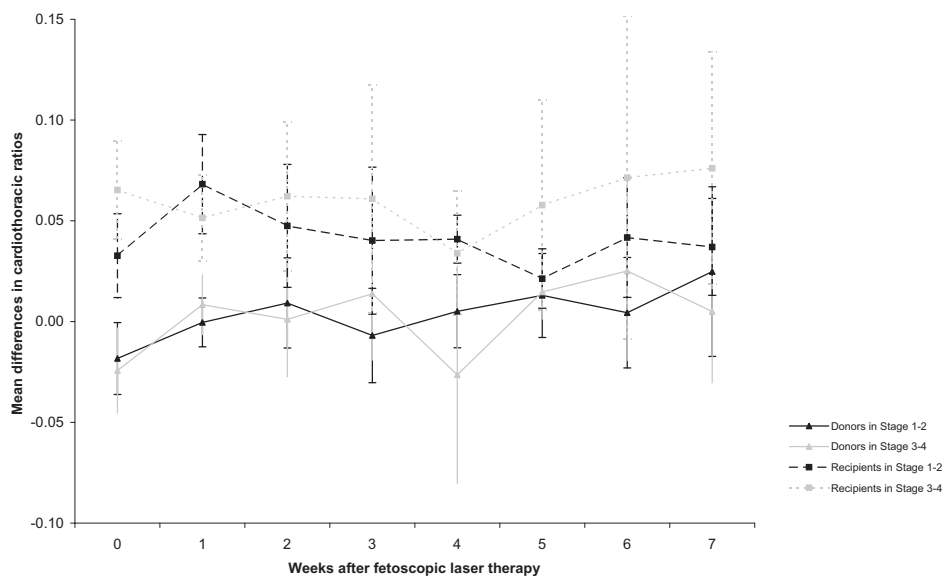


Figure 4 Mean differences (SE) of cardiothoracic ratios of donors and recipients at Quintero Stage 1-2 and Stage 3-4 compared to normal singletons, as function of weeks post-laser therapy

Discussion

In this study, recipient twins in pregnancies complicated by TTTS Quintero Stage 1-2 and Stage 3-4 had enlarged hearts compared to donor twins and to non-TTTS monochorionic twins, both before and in the weeks following fetoscopic laser therapy. The cardiothoracic ratios of donor twins at Quintero Stage 1-2 and Stage 3-4 showed a trend to be smaller as compared to non-TTTS monochorionic twins before laser treatment. After laser therapy, the cardiothoracic ratios of donors at all Quintero stages increased significantly and became larger than those of non-TTTS monochorionic twins. For Quintero Stage 1-2, the difference between donors and non-TTTS monochorionic twins was statistically significant, for Stage 3-4 it was not, which could be due to relatively small sample sizes and become significant in larger series. This is the first longitudinal study demonstrating these findings. These data confirm that TTTS is a complex disease that has cardiovascular consequences for both donor and recipient twins. Fetoscopic laser coagulation of the vascular anastomoses did not result in normalization of cardiac size of recipients during the study period.

Before fetoscopic laser therapy, we found significantly increased cardiac size in TTTS recipients compared to donors and non-TTTS monochorionic twins. This is in line with previous studies^{7,8,10,11,13,14}. Barrea *et al.*¹⁴ showed that cardiomegaly in TTTS results from myocardial hypertrophy rather than ventricular dilatation. Since we did not measure ventricular wall thickness, we were not able to confirm their findings.

In the literature, the etiology of cardiac failure in TTTS recipients is associated with increased preload and afterload^{7,8,10,11,13,14}. Apart from the volume overload due to the intertwin blood transfusion from donor to recipient, which poses a significant burden for the recipient's heart, cardiac hypertrophy could also result from the release of vasoactive peptides stimulated by the cardiac overload. Concentrations of fetal atrial natriuretic peptide as well as brain natriuretic peptide are significantly higher in recipients compared to donors²²⁻²⁵. In addition, the donor responds to hypovolemia and decreased renal perfusion by upregulation of its fetal renin-angiotensin system²⁶⁻²⁹. Through the vascular anastomoses, the donor's renin and angiotensin II can be transfused to the recipient. Due to the vasoconstrictive effect and increase of blood pressure, this process may deteriorate the recipient's cardiac function even further. Cardiac hypertrophy in recipients may be induced this way, as shown by the significant increased cardiothoracic ratios of recipients before laser therapy in our study. In some cases, this process may even lead to progressive ventricular dysfunction, tricuspid regurgitation, and RVOTO.

Before fetoscopic laser therapy, fetal cardiothoracic ratios of donor twins were comparable to those of non-TTTS monochorionic twins, and significantly smaller compared to recipients. Cardiomegaly was not found in donors before treatment. In the literature, donors in TTTS show no or little cardiac pathology in the absence of structural heart abnormalities^{8,10,11,13,30}. Since donors are thought to experience hypovolemia, their hearts are not exposed to increased volume loading and therefore not likely to show signs of cardiac decompensation or hypertrophy and

consequently increased cardiothoracic ratios. Therefore, we think our results are representative of the hemodynamic situation of donors in TTTS before treatment.

After fetoscopic laser coagulation of the communicating vessels, the intertwin transfusion process is stopped and volume loading is expected to normalize. Others have demonstrated re-appearance of forward flow during atrial contraction in the ductus venosus^{17,31} and a significant reduction in ductus venosus pulsatility index^{17,18} in recipient twins after treatment. Our findings however demonstrate a sustained cardiomegaly in recipient twins despite laser therapy. One explanation for this finding may be the residual anastomoses that are seen in one third of the monochorionic placentas treated with fetoscopic laser surgery at our institution³², subsequently causing ongoing intertwin transfusion. Another explanation for the maintenance of enlarged fetal hearts after laser therapy may be that laser treatment is not able to alter the process of cardiovascular remodeling in recipients. A recent follow-up study by Herberg *et al.*¹⁵ showed pulmonary stenosis in almost 8% of recipients that were treated with laser compared to a prevalence of 0.04% in the general population.

Our finding of significantly increased cardiothoracic ratios in donor twins after fetoscopic laser therapy can be explained by several mechanisms. First, as demonstrated by Ishii *et al.*³¹ and Gratacos *et al.*¹⁸, donors experience a state of volume overload after laser coagulation. Although this situation is stated to be transient, a process of cardiovascular remodeling may then be initiated that cannot be reversed. Since RVOTO seems to be a typical feature of recipient twins, remodeling is probably less pronounced in donors. A second cause for increased cardiothoracic ratios in donors after laser therapy may be intrauterine growth restriction that often affects donors as pregnancy progresses³³. In the literature, cardiac sizes of growth-restricted fetuses are reported in an inconsistent way: smaller³⁴, not significantly different³⁵, or larger³⁶ than normally grown fetuses of similar gestational age. Cardiothoracic ratio measurements in a growth-restricted fetus with a proportionally small chest size, or even a mild subclinical degree of thoracic hypoplasia due to its growth restriction, however with a normal heart circumference, will consequently be increased. This may falsely be labeled as cardiomegaly. Moreover, growth restriction is often accompanied by decreased amounts of amniotic fluid, leading to compression of the fetal lungs and consequently increased cardiothoracic ratio. Third, in our experience, some donor twins demonstrate cardiac hypertrophy a few weeks after laser treatment, which increases the cardiothoracic ratio of small-sized donors even further. This might be associated with increased impedance to flow in the placental vessels. Fourth, after complete coagulation of placental anastomoses, the vasoactive factors that were initially released by donors and transported to recipients before treatment may now remain present in the donor's own circulation leading to cardiac hypertrophy. Fifth, residual anastomoses after laser therapy may initiate reversal of TTTS³⁷ and transform former recipients into donors and vice versa. Cardiomegaly may then consequently be seen in the new recipients that used to be donors. Lastly, fetal anemia is also linked with fetal cardiomegaly, however this is not a likely mechanism to be involved in donors that are disconnected from their co-twin³⁸.

We realize that the cardiothoracic ratio measurement is only one of the tools to evaluate fetal cardiomegaly. Ultrasonographic detection of cardiomegaly, however, is a relatively simple and reproducible measurement, which should alert the clinician to suspect impending hemodynamic complications. If possible, more complex arterial and venous Doppler assessment of fetal cardiac function might then be employed for further evaluation.

In conclusion, our study shows that TTTS has an impact on the fetal cardiovascular system of both donors and recipients, even after causal treatment with fetoscopic laser therapy. The increase of the cardiothoracic ratio in donors after laser treatment is of special interest, since cardiac involvement of donors has not been reported that often. In the literature, the hostile *in utero* environment has been suggested to cause increased vascular stiffness and raised cardiac afterload in the surviving donor, which has been associated with adult onset of cardiovascular disease such as hypertension and ischemic heart disease^{39,40}. Our study may also show that labeling donors that are treated with fetoscopic laser therapy for TTTS as not being at risk for cardiac involvement and disease is not necessarily true.

References

1. Sebire NJ, Souka A, Skentou H, Geerts L, Nicolaides KH. Early prediction of severe twin-to-twin transfusion syndrome. *Hum Reprod* 2000; 15: 2008-2010.
2. Quintero RA, Morales WJ, Allen MH, Bornick PW, Johnson PK, Kruger M. Staging of twin-twin transfusion syndrome. *J Perinatol* 1999; 19: 550-555.
3. Patten RM, Mack LA, Harvey D, Cyr DR, Pretorius DH. Disparity of amniotic fluid volume and fetal size: problem of the stuck twin--US studies. *Radiology* 1989; 172: 153-157.
4. Berghella V, Kaufmann M. Natural history of twin-twin transfusion syndrome. *J Reprod Med* 2001; 46: 480-484.
5. Gul A, Aslan H, Polat I, Cebeci A, Bulut H, Sahin O, Ceylan Y. Natural history of 11 cases of twin-twin transfusion syndrome without intervention. *Twin Res* 2003; 6: 263-266.
6. Senat MV, Deprest J, Boulvain M, Paupe A, Winer N, Ville Y. Endoscopic laser surgery versus serial amnioreduction for severe twin-to-twin transfusion syndrome. *N Engl J Med* 2004; 351: 136-144.
7. Zosmer N, Bajoria R, Weiner E, Rigby M, Vaughan J, Fisk NM. Clinical and echographic features of in utero cardiac dysfunction in the recipient twin in twin-twin transfusion syndrome. *Br Heart J* 1994; 72: 74-79.
8. Cincotta R, Oldham J, Sampson A. Antepartum and postpartum complications of twin-twin transfusion. *Aust N Z J Obstet Gynaecol* 1996; 36: 303-308.
9. Lachapelle MF, Leduc L, Cote JM, Grignon A, Fouron JC. Potential value of fetal echocardiography in the differential diagnosis of twin pregnancy with presence of polyhydramnios-oligohydramnios syndrome. *Am J Obstet Gynecol* 1997; 177: 388-394.
10. Simpson LL, Marx GR, Elkadry EA, D'Alton ME. Cardiac dysfunction in twin-twin transfusion syndrome: a prospective, longitudinal study. *Obstet Gynecol* 1998; 92: 557-562.
11. Fesslova V, Villa L, Nava S, Mosca F, Nicolini U. Fetal and neonatal echocardiographic findings in twin-twin transfusion syndrome. *Am J Obstet Gynecol* 1998; 179: 1056-1062.
12. Loughheed J, Sinclair BG, Fung Kee FK, Bigras JL, Ryan G, Smallhorn JF, Hornberger LK. Acquired right ventricular outflow tract obstruction in the recipient twin in twin-twin transfusion syndrome. *J Am Coll Cardiol* 2001; 38: 1533-1538.
13. Karatza AA, Wolfenden JL, Taylor MJ, Wee L, Fisk NM, Gardiner HM. Influence of twin-twin transfusion syndrome on fetal cardiovascular structure and function: prospective case-control study of 136 monochorionic twin pregnancies. *Heart* 2002; 88: 271-277.
14. Barrea A, Alkazaleh F, Ryan G, McCrindle BW, Roberts A, Bigras JL, Barrett J, Seaward GP, Smallhorn JF, Hornberger LK. Prenatal cardiovascular manifestations in the twin-to-twin transfusion syndrome recipients and the impact of therapeutic amnioreduction. *Am J Obstet Gynecol* 2005; 192: 892-902.
15. Herberg U, Gross W, Bartmann P, Banek CS, Hecher K, Breuer J. Long-term cardiac follow-up of severe twin-to-twin transfusion syndrome after intrauterine laser coagulation. *Heart* 2006; 92: 95-100.
16. Paladini D, Chita SK, Allan LD. Prenatal measurement of cardiothoracic ratio in evaluation of heart disease. *Arch Dis Child* 1990; 65: 20-23.
17. Zikulnig L, Hecher K, Bregenzer T, Baz E, Hackeloer BJ. Prognostic factors in severe twin-twin transfusion syndrome treated by endoscopic laser surgery. *Ultrasound Obstet Gynecol* 1999; 14: 380-387.
18. Gratacos E, Van Schoubroeck D, Carreras E, Devlieger R, Roma E, Cabero L, Deprest J. Impact of laser coagulation in severe twin-twin transfusion syndrome on fetal Doppler indices and venous blood flow volume. *Ultrasound Obstet Gynecol* 2002; 20: 125-130.
19. Martinez JM, Bermudez C, Becerra C, Lopez J, Morales WJ, Quintero RA. The role of Doppler studies in predicting individual intrauterine fetal demise after laser therapy for twin-twin transfusion syndrome. *Ultrasound Obstet Gynecol* 2003; 22: 246-251.
20. Middeldorp JM, Klumper FJ, Oepkes D, Lopriore E, Kanhai HH, Vandenbussche FP. [The initial results of fetoscopic laser treatment for severe second trimester twin-to-twin transfusion syndrome in the Netherlands are comparable to international results]. *Ned Tijdschr Geneesk* 2004; 148: 1203-1208.
21. Zeger SL, Liang KY, Albert PS. Models for longitudinal data: a generalized estimating equation approach. *Biometrics* 1988; 44: 1049-1060.
22. Nageotte MP, Hurwitz SR, Kaupke CJ, Vaziri ND, Pandian MR. Atriopeptin in the twin transfusion syndrome. *Obstet Gynecol* 1989; 73: 867-870.

23. Bajoria R, Ward S, Sooranna SR. Atrial natriuretic peptide mediated polyuria: pathogenesis of polyhydramnios in the recipient twin of twin-twin transfusion syndrome. *Placenta* 2001; 22: 716-724.
24. Wieacker P, Wilhelm C, Prompeler H, Petersen KG, Schillinger H, Breckwoldt M. Pathophysiology of polyhydramnios in twin transfusion syndrome. *Fetal Diagn Ther* 1992; 7: 87-92.
25. Bajoria R, Ward S, Chatterjee R. Natriuretic peptides in the pathogenesis of cardiac dysfunction in the recipient fetus of twin-twin transfusion syndrome. *Am J Obstet Gynecol* 2002; 186: 121-127.
26. Mahieu-Caputo D, Muller F, Joly D, Gubler MC, Lebidois J, Fermont L, Dumez Y, Dommergues M. Pathogenesis of twin-twin transfusion syndrome: the renin-angiotensin system hypothesis. *Fetal Diagn Ther* 2001; 16: 241-244.
27. Mahieu-Caputo D, Meulemans A, Martinovic J, Gubler MC, Delezoide AL, Muller F, Madelenat P, Fisk NM, Dommergues M. Paradoxical activation of the renin-angiotensin system in twin-twin transfusion syndrome: an explanation for cardiovascular disturbances in the recipient. *Pediatr Res* 2005; 58: 685-688.
28. Mahieu-Caputo D, Dommergues M, Delezoide AL, Lacoste M, Cai Y, Narcy F, Jolly D, Gonzales M, Dumez Y, Gubler MC. Twin-to-twin transfusion syndrome. Role of the fetal renin-angiotensin system. *Am J Pathol* 2000; 156: 629-636.
29. Kilby MD, Platt C, Whittle MJ, Oxley J, Lindop GB. Renin gene expression in fetal kidneys of pregnancies complicated by twin-twin transfusion syndrome. *Pediatr Dev Pathol* 2001; 4: 175-179.
30. Reisner DP, Mahony BS, Petty CN, Nyberg DA, Porter TF, Zingheim RW, Williams MA, Luthy DA. Stuck twin syndrome: outcome in thirty-seven consecutive cases. *Am J Obstet Gynecol* 1993; 169: 991-995.
31. Ishii K, Chmait RH, Martinez JM, Nakata M, Quintero RA. Ultrasound assessment of venous blood flow before and after laser therapy: approach to understanding the pathophysiology of twin-twin transfusion syndrome. *Ultrasound Obstet Gynecol* 2004; 24: 164-168.
32. Lopriore E, Middeldorp JM, Oepkes D, Klumper FJ, Walther FJ, Vandenbussche FP. Residual anastomoses after fetoscopic laser surgery in twin-to-twin transfusion syndrome: frequency, associated risks and outcome. *Placenta* 2007; 28: 204-208.
33. Lopriore E, Sueters M, Middeldorp JM, Oepkes D, Vandenbussche FP, Walther FJ. Neonatal outcome in twin-to-twin transfusion syndrome treated with fetoscopic laser occlusion of vascular anastomoses. *J Pediatr* 2005; 147: 597-602.
34. Veille JC, Hanson R, Sivakoff M, Hoen H, Ben Ami M. Fetal cardiac size in normal, intrauterine growth retarded, and diabetic pregnancies. *Am J Perinatol* 1993; 10: 275-279.
35. Hill LM, Guzik D, Peterson C, DiNofrio D, Maloney J, Nedzeksy P. Fetal heart circumference as a predictor of menstrual age in fetuses affected by disturbances in growth. *Am J Obstet Gynecol* 1993; 169: 347-351.
36. DeVore GR. Examination of the fetal heart in the fetus with intrauterine growth retardation using M-mode echocardiography. *Semin Perinatol* 1988; 12: 66-79.
37. Wee LY, Taylor MJ, Vanderheyden T, Wimalasundera R, Gardiner HM, Fisk NM. Reversal of twin-twin transfusion syndrome: frequency, vascular anatomy, associated anomalies and outcome. *Prenat Diagn* 2004; 24: 104-110.
38. Ouzounian JG, Monteiro HA, Alsulyman OM, Songster GS. Ultrasonographic fetal cardiac measurement in isoimmunized pregnancies. *J Reprod Med* 1997; 42: 342-346.
39. Cheung YF, Taylor MJ, Fisk NM, Redington AN, Gardiner HM. Fetal origins of reduced arterial distensibility in the donor twin in twin-twin transfusion syndrome. *Lancet* 2000; 355: 1157-1158.
40. Gardiner HM, Taylor MJ, Karatza A, Vanderheyden T, Huber A, Greenwald SE, Fisk NM, Hecher K. Twin-twin transfusion syndrome: the influence of intrauterine laser photocoagulation on arterial distensibility in childhood. *Circulation* 2003; 107: 1906-1911.

