

Cover Page



Universiteit Leiden



The handle <http://hdl.handle.net/1887/36504> holds various files of this Leiden University dissertation

Author: Esch, Edith van

Title: Clinical implications of immune cell infiltration in vulvar intraepithelial neoplasia

Issue Date: 2015-12-01



CHAPTER 3

CLINICAL CHARACTERISTICS ASSOCIATED WITH DEVELOPMENT OF RECURRENCE AND PROGRESSION IN USUAL-TYPE VULVAR INTRAEPITHELIAL NEOPLASIA

Edith M.G. van Esch

Maija C.I. Dam

Michelle E.M. Osse

Hein Putter

J. Baptist M.Z. Trimbos

Gertjan Fleuren

Sjoerd. H. van der Burg

Mariette I.E. van Poelgeest

Int J Gynecol Cancer 2013 Oct;23(8):1476-83

Abstract

Objective

To identify clinical characteristics associated with recurrence and progression in patients with uVIN which may function as prognostic factors and aid the treatment of patients with HPV-related disease of the genital tract.

Methods

A retrospective chart review was performed in 73 patients with uVIN treated in the LUMC between 1990 and 2012. All medical records were reviewed for demographics, treatment type, pathology reports and recurrence and progression rates.

Results

Mean age of diagnosis was 43 years and uVIN was symptomatic in 60.1% of patients. Median follow up time was 49 months. High risk HPV was found in 86.3% of patients. Smoking was reported in 76.8% of patients. 11 of 73 patients were immune compromised. Multicentric HPV-related disease of the cervix or vagina was reported in 75.3% of patients. Recurrences were diagnosed in 50.7% of patients after first treatment type that consisted of excision (45.2%), laser (34.2%), imiquimod (8.2%) and combination of excision and laser (12.3%). Higher recurrence rates were only correlated with multifocality of uVIN lesions. Excision, imiquimod therapy, and unifocal lesions showed an increased recurrence free survival. HPV type, smoking, multicentric disease, use of topical steroids and positive surgical borders were not related to a shorter recurrence free survival. Progression into vulvar carcinoma occurred in 11 (15.1%) of patients, 4 of whom were immune compromised. These patients showed a shorter progression free survival of 54 months vs. 71.5 months.

Conclusion

There are no clinical characteristics that form prognostic factors in uVIN, except for multifocality of lesions, that is correlated with a higher recurrence rate. Furthermore, progression of uVIN to carcinoma was accelerated and increased in immune compromised patients, suggesting that studies of local immunity in uVIN may reveal potential prognostic factors, as well as aid the development of new treatment modalities.

Introduction

Vulvar intraepithelial neoplasia (VIN) is a chronic premalignant skin disease that can be classified into usual type VIN (uVIN), (old nomenclature VIN 2 /3), and differentiated type VIN (dVIN)¹. dVIN occurs in postmenopausal women and is associated with lichen sclerosis whereas uVIN, accounting for 90% of VIN cases, is caused by a persistent human papilloma virus (HPV) infection, mainly high risk HPV type 16^{2,3}. uVIN has an increasing incidence worldwide in young women possibly due to the increase of HPV infections^{4,5}. HPV is among the most common sexually transmitted diseases, with a lifetime risk of infection of 80%⁵. HPV-induced disease of the lower genital tract and its outcome are influenced by the host immune response, smoking, and immunosuppression⁶⁻⁸. It has been known for long that cellular immune responses against HPV protect against the development and progression of HPV-induced disease^{9,10}. In the majority of uVIN patients HPV specific responses are either weak or absent^{11,12}. Spontaneous regression is low and estimated at 1.5% of cases^{2,13,14}. uVIN has a malignant potential in 3% of treated and 9% of untreated patients in 1-8 years^{2,13,15}. The malignant potential of uVIN in immune compromised patients is 50-fold higher in comparison to the general population¹⁶.

Patients with uVIN often suffer from severe and often long-lasting complaints of pruritis, pain and sexual dysfunction. Standard treatment for uVIN has been for a long time surgical (local excision and laser treatment). The aim of treatment is relief of symptoms, exclusion and reduction of the risk on invasive disease, and restoration of normal anatomy. If symptoms lack, expectative management of uVIN by close follow up visits can be advocated¹⁷. Conventional treatments are well known to be complicated by high recurrence rates, disfigurement of vulvar anatomy and impact on psychosexual function^{18,19}. At present, a shift from conventional surgical therapies towards (experimental) immunotherapies such as the topical agent imiquimod (Aldara®, 3M Pharmaceuticals, St Paul, MN), photodynamic therapy, and therapeutic vaccination is visible with the aim to induce clearance of HPV, preserve vulvar anatomy and reduce psychosexual morbidity². Responsiveness to imiquimod treatment is associated with pre-existing HPV specific T-cell responses^{11,20,21}. Reinforcement of the HPV-specific T-cell response by therapeutic vaccination has shown promising clinical responses of established HPV induced anogenital neoplasia, especially when vaccination was combined with imiquimod^{20,22,23}. Despite these promising clinical results a notable number of patients are not able to respond to these immunotherapies^{20,22,24}. There is a need to identify factors associated with patients who are at risk of non-responsiveness to (immuno)therapy, developing recurrences and progression into vulvar carcinoma. These predictors may assist in choice of therapy alternative to the complexity and limited possibilities of surgery²⁵. We therefore performed a retrospective study in a single centre cohort to determine possible risk factors associated with the development of recurrences and progression into invasive carcinoma in patients with uVIN.

Materials and Methods

A retrospective chart review was performed of 136 patients with uVIN who were treated in our institution between 1990 and July 2012. This study was approved by the medical ethic committee of the Leiden University Medical Center. Patients participating in our vaccination trials were excluded from this study²². Patients with micro- (n=9) or macroinvasive vulvar carcinoma (n=16) at first diagnosis and missing demographic baseline information (n=38) were also excluded from analysis which revealed a group of 73 patients with uVIN. Demographic information, treatment type, pathology reports and clinical outcomes were reported. Recurrent disease was defined as diagnosis of uVIN after successful treatment without residual disease. Residual disease was defined as the presence of visible lesions immediately after therapy. Histological examination of margins of excision specimens were analyzed by an experienced pathologist. History of concomitant disease defined as abnormal cervical cytology, CIN, VAIN or cervical cancer was documented. Progressive disease was defined as the development of a (micro-) invasive carcinoma and consists of both occult carcinomas in a persistent lesion as well as development of a carcinoma in the follow up after therapy.

All uVIN samples included in this study were typed for HPV on the first lesion of uVIN by HPV16 PCR with a HPV16 specific primer set followed by HPV genotyping using the INNO-LiPA HPV genotyping *Extra* line probe assay (Innogenetics, Ghent, Belgium) in case of HPV16 negativity^{26,27}.

In data analysis the statistical software package SPSS 20.0 (SPSS Inc., Chicago, IL) was used. Group comparisons of demographic characteristics were performed by Pearson's Chi-square test or Mann-Whitney test. Univariate analysis by Cox-regression was used for comparison of recurrence-free survival analysis (RFS) and progression free survival (PFS). RFS thereafter was analyzed by Cox proportional hazards regression in respect of smoking status, lesion type, age, treatment modality and concomitant disease. RFS was measured from date of first treatment until the date of recurrence or last follow up whereas PFS was measured from date of diagnosis until date of invasive disease.

Results

The mean age at diagnosis of uVIN was 43 years (range 19-84 years) with a median FU time of 49 months. All patient characteristics are shown in (table 1). The majority of patients (60.3%) presented with complaints of pruritis, pain or discomfort at time of diagnosis. Lesions were multifocal in 43.8% and unifocal in 52.1% of the patients. Of the included patients, 65.8% were current smokers at diagnosis of uVIN, 11% former smokers, 13.7% non-smokers and from 4.1% patients smoking state was unknown. Eleven patients used immunosuppressive medication; 4 with autoimmune disease (Crohn's disease, rheumatic arthritis and systemic lupus erythematosus), 6 allograft recipients and 1 HIV positive patient. Topical corticosteroids were used by 40.9% of patients during one or more periods in the follow up. Multicentric disease, determined by cytological or histological diagnosed cervical or vaginal dysplasia (CIN and/or VAIN), was present in 75.3% of patients during follow up and most patients (83.6%) developed uVIN after diagnosis of cervical dysplasia in a median time of 65 months (range -51 to 335 months) whereas only a small number of patients developed CIN after uVIN (table 1).

First therapy in the treatment of uVIN (table 2) was surgical excision in 33 patients (45.2%), laser therapy in 25 patients (34.2%), laser and excision in 9 (12.3%) and imiquimod in 6 (8.2%) of patients after a median time of 2 months after diagnosis in a range of 0-158 months. More unifocal lesions were treated with excision (21 vs. 10, *ns*) whereas patients treated with combination of laser and excision often had multifocal lesions (2 vs. 6, *ns*) (table 2). A total of 70 excisions were performed in 50 patients of which 71.4% had histological positive margins. Similarly, in 61.5% of the combined laser and excision therapies (n=13) the excisions borders were considered positive for uVIN. Residual disease was found in 34 patients (46.6%) which resulted in the use of adjuvant therapy in 30 patients. Residual lesions occurred in 15.7% after excision, in 22.9% after laser therapies, in 57.1% after imiquimod treatment, and in 30.8% of 13 combined laser and excision interventions.

Table 1: Patient Characteristics (N=73)

Characteristic	Value (n)
Lesion histology	
VIN 2	17 (23.3%)
VIN 3	56 (76.7%)
Age at diagnosis (years)	
Mean	44.78
Median	43.0
SD	14.92
Range	19-84
Body mass index (kg/m²)	
<18.5	5 (6.8%)
18.5-25	31 (42.5%)
>25	29 (39.7%)
Unknown	7 (9.6%)
Lesion type	
Unifocal	38 (52.1%)
Multifocal	30 (43.8%)
Complaints at diagnosis	
None	44 (60.1%)
Pruritis	17 (23.3%)
Pruritis and pain/discomfort	14 (19.2%)
Pain/discomfort	6 (8.2%)
Pruritis and pain/discomfort	23 (31.5%)
Dyspareunia	1 (1.4%)
Unknown	12 (16.4%)
Smoking status	
Current	48 (65.8%)
Former	8 (11%)
Never	10 (13.7%)
Unknown	3 (4.1%)
HPV type	
Negative	
16	5 (6.8%)
48	48 (65.8%)
33	7 (9.6%)
16 + 33	1 (1.4%)
Multiple hrHPV (e.g. 33,31,51,44)	3 (4.1%)
18	1 (1.4%)
6	2 (2.7%)
73	1 (1.4%)
Not tested	5 (6.8%)
Topical use corticosteroids	
Yes	28 (38.4%)
No	45 (61.6%)
Immunosuppressive medication	
11	11 (15.1%)
HIV	1 (1.5%)
Allograft recipient	6 (8.2%)
Autoimmune disease	4 (5.4%)

Concomitant disease	55 (75.3%)
None	7 (9.6%)
Abnormal cervical cytology (pap 2/3a)	18 (24.7%)
CIN	31 (42.5%)
CIN + VAIN	4 (5.5%)
Cervical Carcinoma	2 (2.7%)
Follow-up time (months)	
Median	49.0
Mean	77.1
SD	79.5
Range	0-307

Table 2: Primary treatment and lesion type (N=)

	Excision	Laser	Aldara	Laser and Excision	Chi²
Unifocal	21 (67.7%)	13 (52%)	2 (33.3%)	2 (25%)	
Multifocal	10 (32.2%)	12 (48%)	4 (66.7%)	6 (75%)	
Total	31	25	6	8	0.105

Recurrences

After first therapy, 37 patients (50.7%) developed recurrent lesions in just more than one year (median 14 months; range 1-168) (*table 3*). Twelve patients had 1 recurrence (16.4%), 16 patients had 2 recurrences (21.9%), 4 patients 3 recurrences (5.5%), and in 5 patients (6.8%) 4 or more recurrences of uVIN were diagnosed. At time of diagnosis 76.5% of patients presented with symptoms, 11% had no complaints and of 5 patients it was not known. Of the patients with recurrent disease, 16 had prior excision (47%), 14 laser therapy (41.1%), 1 was treated with imiquimod (2.9%) and 6 patients were treated with laser and excision (17.6%). Recurrent disease was associated with multifocal lesions ($p=0.008$) in a univariate analysis irrespective of time to recurrence (*table 3*). Median time to recurrence was not significantly longer in patients with negative borders ($n=2$) compared to patients with positive borders ($n=12$) (79 vs. 30 months, $p=0.189$). Patients who were treated by excision however, had a significant longer median time until recurrence of 41.5 months, laser therapy of 7.5 months, imiquimod of 13 months, and laser and excision of 6 months ($p=0.032$).

Table 3: Factors associated with recurrence and progression

	Recurrence (N (%))		No recurrence (N (%))	Chi ² (p=)	Cox (p=)	Progression (N (%))	No progression (N (%))	Chi ² (p=)	Cox (p=)
	0.320		0.019			0.302		0.200	
First treatment modality (n=73)									
Excision	16 (48.8%)	17 (51.5%)				4 (12.1%)	29 (87.9%)		
Laser ablation	14 (56%)	11 (44%)				4 (16%)	21 (84%)		
Imiquimod	5 (83.3%)	1 (16.7%)				0	6 (100%)		
Excision + Laser	6 (66.7%)	3 (33.3%)				3 (33.3%)	6 (66.7%)		
Surgical borders (n=63)									
Positive	12 (41.3%)	17 (58.6%)				5 (17.2%)	24 (82.8%)	0.083	0.326
Negative	2 (50%)	2 (50%)				0	4 (100%)		
Not applicable (laser/imiquimod)	16 (53.3%)	14 (46.7%)				4 (13.3%)	26 (86.7%)		
Unknown	7 (70%)	3 (30%)				2 (20%)	8 (80%)		
Age (years) (n=73)									
Mean (SD)	41.41 (13.04)	48.25 (16.08)		0.049	0.682	41.82 (15.02)	45.31 (14.97)	0.479	0.100
Smoking (n=69)									
Yes	25 (52.4%)	23 (47.9%)		0.468	0.083	9 (18.8%)	39 (81.2%)	0.281	0.142
No	10 (47.6%)	11 (52.4%)				2 (9.5%)	19 (90.5%)		
Lesion type (n=70)									
Unifocal	13 (34.2%)	25 (65.8%)		0.008	0.006	3 (7.9%)	35 (92.1%)	0.093	0.950
Multifocal	21 (65.6%)	11 (34.4%)				7 (21.9%)	25 (78.1%)		
Lesion size cm² (n=33)									
Mean	6.41 (7.49)	7.02 (11.11)		0.875	0.546	13.18 (18.35)	5.96 (8.50)	0.181	0.492
Complaints at diagnosis (n=61)									
Yes	20 (45.5%)	24 (54.5%)		0.567	0.877	8 (18.2%)	36 (81.8%)	0.215	0.823
No	8 (47.1%)	9 (52.9%)				1 (5.9%)	17 (94.1%)		
BMI (n=65)									
<= 25	20 (57.1%)	16 (53.3%)		0.806	0.286	5 (45.5%)	31 (57.4%)	0.520	0.814
>25	15 (42.9%)	14 (46.7%)				6 (54.5%)	23 (42.6%)		
Immunocompromised (n=73)									
Yes	5 (45.5%)	6 (54.5%)		0.480	0.490	3 (27.3%)	8 (72.7%)	0.211	0.091
No	32 (51.6%)	30 (48.4%)				8 (12.9%)	54 (87.1%)		
Concomitant disease (n=62)									
Yes	30 (54.5%)	25 (45.5%)		0.610	0.319	8 (14.5%)	47 (85.5%)	0.734	0.621
No	4 (57.1%)	3 (42.9%)				1 (14.3%)	6 (85.7%)		
HPV type (n=58)									
16	27 (56.2%)	21 (43.8%)		0.492	0.752	8 (16.7%)	40 (83.3%)	0.553	0.300
33	5 (50%)	5 (50%)				2 (20%)	8 (80%)		

Considering time to recurrence, a univariate Cox regression analysis of recurrence free survival was performed. RFS after diagnosis was associated with multifocal disease ($p=0.006$, HR 2.77, 95% CI 1.30-5.89). RFS after first therapy in univariate Cox regression analysis revealed a longer recurrence free survival between different treatment modalities in favor of excision and imiquimod therapy ($p=0.010$, HR 5.5, 95% CI 1.94-15.63 (laser and excision compared to excision)). RFS was not associated with immunosuppressive medication ($p=0.490$), smoking ($p=0.083$), positive margins ($p=0.383$), concomitant disease ($p=0.319$), local corticosteroid use ($p=0.613$), or HPV type ($p=0.752$). Multifocal disease remained an independent prognostic factor for a decreased RFS in multivariate Cox analysis corrected for multifocal disease, smoking, HPV state, immune compromised patients and BMI ($p=0.027$) whereas excision as first therapy was no longer associated with a longer recurrence free survival ($p=0.142$) (figure 1A+1B).

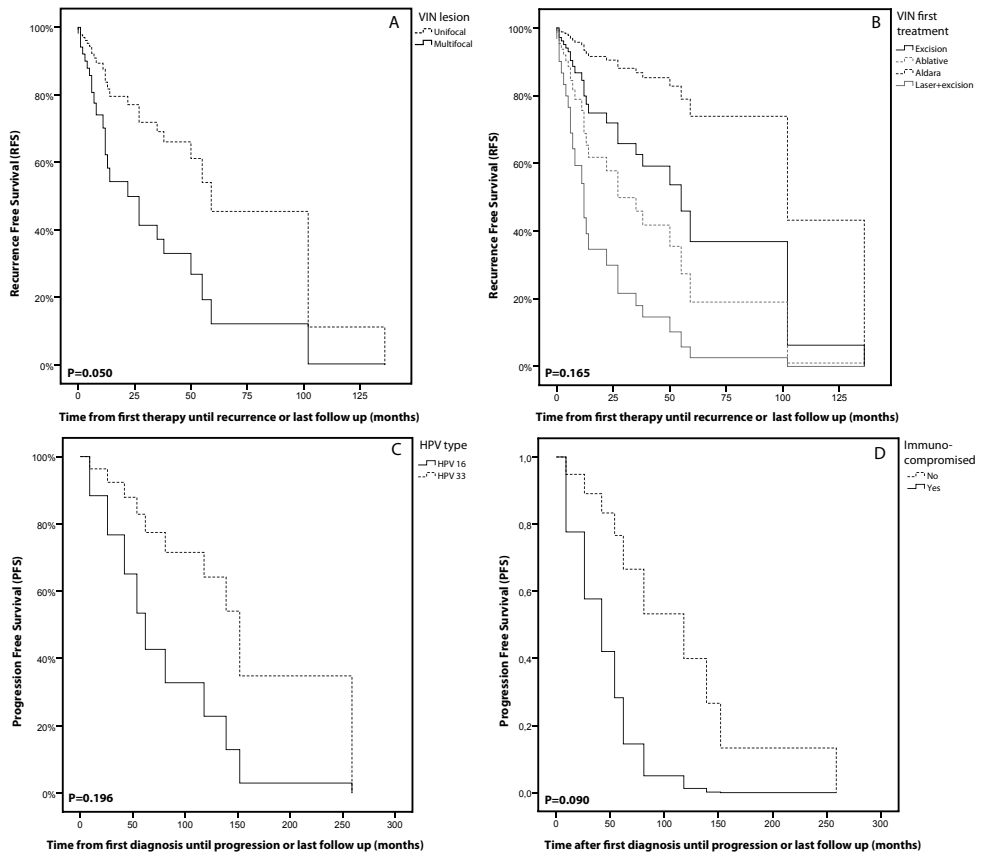


Figure 1

A+B Multivariate Cox-based adjusted curves of recurrence free survival (RFS) of multifocal VIN lesions and first treatment type corrected for smoking, HPV type, first treatment modality, BMI, immunocompromised patients and uVIN lesion type **C+D**: Univariate Cox regression progression free survival curves (PFS) for HPV type and immunocompromised patients

Progressive disease

In 11 patients (15.1%) an invasive carcinoma developed during follow up with a median of 71.5 months after first diagnosis (range 9-259 months) (*table 3*). Progression of uVIN into carcinoma of a persistent lesion occurred in 2 patients (2.7%), in 9 patients a carcinoma was diagnosed after successful therapy of uVIN without residual lesions. In 7 patients a micro invasive carcinoma (≤ 1 mm invasion) and in 4 patients a macro invasive carcinoma (> 1 mm invasion) was diagnosed. 4 of 11 patients were immune compromised with a median time of progression of 54 months (range 9-62 months). Type of first treatment showed no differences in progression free survival in univariate Cox analysis ($p=0.200$). HPV type 16 compared to 33 was not associated with progression of uVIN into invasive carcinoma ($p=0.300$) and despite the shorter time to progression in immune compromised patients this resulted not in a significant shorter PFS ($p=0.091$, HR 4.744, 95% CI 0.78-28.85) in univariate Cox analyses (*figure 1C+1D*).

Discussion

In this study, higher recurrence rates for uVIN were only correlated with multifocality of lesions. First treatment by excision or imiquimod therapy as well as unifocal lesions were associated with increased recurrence free survival. Immune compromised patients showed a trend towards a shorter progression free survival. HPV type, smoking, multicentric disease, use of topical steroids, and positive surgical borders were not associated with a shorter recurrence free survival.

After standard treatment, recurrence rates for uVIN are high, and most recurrences occur within 3 years of follow-up^{13,15,28-30}. This was confirmed in our study. Higher recurrences rates have previously been associated with positive surgical margins and multifocal disease; although other studies showed that positive surgical margins were not associated with recurrent disease^{13,15,29,30}. In addition, the margin status of resected uVIN lesions has not shown to be associated with progression to invasive cancer^{13,31}. In our study, positive surgical margins were not associated with recurrent disease: 12 of 29 patients with positive margins developed recurrent disease, whereas 17 patients did not (41.3% vs. 58.6%, respectively) (*table 3*). Histological positive margins can be regarded as minimal residual disease, a condition where the immune system might be more effective in comparison to situations with large tumor burden. For example, results from our vaccination trial in patients with HPV16-positive uVIN have shown that smaller lesions were more likely to regress in response to vaccine-induced HPV16-specific immunity^{22,32}. In addition, surgical removal of primary tumors was shown to restore cell-mediated immune responses even in the presence of metastatic disease³³. These data suggest that in some patients, surgical

removal of lesions or reduction of lesion size can lead to the restoration of adaptive immune responses which may prevent recurrent disease.

Patients treated with excision were found to have lower recurrence rates compared to patients treated with laser or combined laser and excision in our cohort. This finding might be explained by the fact that patients with large lesions and/ or multifocal disease were selected for combination therapy with excision and laser (our study: 2 unifocal vs. 6 multifocal lesions). Recently, the same observation was done by Wallbillich et al., who showed an association between a decreased RFS and treatment of excision and laser³⁰. Another study by Brown et al showed that after local excision followed by laser treatment of the excision margins, the recurrence rate was decreased in patients with uVIN³⁴. When interpreting these findings, it should be kept in mind that a simple comparison for efficacy between different treatments is very difficult because the choice of treatment depends on several factors, for example uni- or multifocality of lesions and patient related factors.

Treatment with the immune response modifier imiquimod is more and more used since the publication of a large randomized controlled trial in patients with uVIN in 2008²⁴. In this study, a reduction of >25% in lesion diameter was observed in 80% of the treated patients, with a complete disappearance of the lesions in 35% of the patients. HPV clearance occurred in 60% of patients²⁴. Recurrences after imiquimod are established at approximately 20.5% vs. 53.5% after surgical therapies^{35,36}. The small number of patients treated with imiquimod in our group, however show comparable results to excision regarding RFS in univariate analyses (*figure 1*). In this small cohort a complete response was achieved in one of six (16.7%) of patients primarily treated with imiquimod, the other patients with residual lesions were secondarily treated with laser therapy. Interestingly, clinical responses after imiquimod treatment in uVIN have been shown to be associated with normalization of immune cells in the lesions, and also with the presence of circulating HPV-specific T cells^{11,24,35}.

Other factors which have been associated with recurrence are smoking³⁰, HIV infection³⁷, use of immunosuppressive drugs²⁸ and p53 gene mutation^{2,38}. We found no association between smoking and increased risk for recurrences in contrast to Wallbillich et al.³⁰ This may be related to the high number of smokers in our cohort, since only 8 patients never smoked or by longer median time of follow up in our group (21 months vs. 49 months). Other studies found no association of smoking and recurrences of uVIN either^{28,29}. Smoking is however clearly associated with the development of uVIN and we feel that patients should be counseled to stop smoking during follow up visits since it is well known that smoking results in a decreased local immune response which makes it easier for the HPV virus to invade and persist^{6,7,15}.

In our cohort the number of progressive disease is 15.1% of which 60% are micro-invasive carcinomas ($\leq 1\text{mm}$), that are known to have excellent survival after wide local excision without lymph node dissection. Of the 11 patients with progression into invasive cancer,

4 were immune compromised. These patients are known to have an increased risk of multiple HPV induced anogenital lesions: over 80% of immune compromised uVIN patients were shown to have a history of CIN or developed CIN during follow-up in one study^{8,39,40}. Importantly the immune compromised patients had an increased risk (27.3% vs. 12.9%) of progression into vulvar carcinoma and displayed a relatively faster (54 vs. 71.5 months) development of cancer compared to non immune compromised patients. A 50-fold increase in the risk to develop vulvar carcinoma in immune compromised patients was demonstrated before, and yearly cervical screening in combination with vulvar, vaginal and anal inspection is advised¹⁶. We could not detect an increased risk for recurrences; however, patient numbers were small.

Multicentric HPV-associated disease has been described in patients with cervical intraepithelial neoplasia (CIN) and uVIN^{41,42}. Other studies have shown that 71% of uVIN patients had previous, concurrent or subsequent vaginal intraepithelial neoplasia (VAIN), (peri-)anal intraepithelial neoplasia ((P)AIN), CIN or cervical carcinoma^{41,42}. This was confirmed in our study, in which 75% of patients were diagnosed previously or concurrent with cervical dysplasia or VAIN. Other studies showed that multicentric disease was associated with a higher risk of progression compared to isolated uVIN⁴³. We could not confirm these data although 7 of 11 patients with progressive disease displayed multicentric HPV lesions. Multicentric disease may be a reflection of a higher susceptibility for HPV infections and not able to clear the infections which are able to induce transformation (e.g. HPV type 16)^{40,42}. HPV testing of multicentric anogenital HPV induced neoplasias revealed an identical HPV infection in 46% of cases (most often HPV 16 in 69%, followed by HPV 33 in 13%). Most uVIN lesions are induced by HPV16 and HPV33, the types most often found in multicentric disease, explaining why these patients are at risk for HPV-induced disease affecting the cervix, vagina, and/or the anus. From these data it follows that patients with uVIN must be carefully screened for cervical dysplasia, in particular when they are immune compromised.

An important limitation of our study, and also from other studies on clinical characteristics in VIN patients, is that patient numbers are relatively small because of the rarity of the disease. This means that non-significant results, for example for the surgical margin status or type of treatment may relate to small patient numbers rather than being no clinical difference. Therefore, for the translation into clinical practice, larger prospective, eventually multicenter studies are needed in patients with uVIN.

In summary, our data indicate that multicentric disease is highly common in patients with uVIN. Recurrences after treatment are high and are only associated with multifocal lesions. No other clinical characteristics are correlated with a higher recurrence- or progression rate. Immune compromised patients show a trend towards a shorter progression free interval.

From this study and data from others it is clear that the immune system plays a crucial role in the development of and course of disease in patients with HPV-induced lesions. Future research should be aimed at a detailed analysis of the local immune environment in relation to the clinical outcomes of disease in patients with uVIN. Furthermore, the strengthening of the systemic and local immune immunity to HPV by (adjuvant) immunotherapies may assist in the improvement of the treatment for patients with uVIN and other HPV-induced disease.

References

1. Sideri M, Jones RW, Wilkinson EJ et al. Squamous vulvar intraepithelial neoplasia: 2004 modified terminology, ISSVD Vulvar Oncology Subcommittee. *J Reprod Med* 2005; 50(11):807-810.
2. van de Nieuwenhof HP, van der Avoort IA, de Hullu JA. Review of squamous premalignant vulvar lesions. *Crit Rev Oncol Hematol* 2008; 68(2):131-156.
3. Garland SM, Insinga RP, Singa HL et al. Human papillomavirus infections and vulvar disease development. *Cancer Epidemiol Biomarkers Prev* 2009; 18(6):1777-1784.
4. Judson PL, Habermann EB, Baxter NN et al. Trends in the incidence of invasive and in situ vulvar carcinoma. *Obstet Gynecol* 2006; 107(5):1018-1022.
5. Baseman JG, Koutsky LA. The epidemiology of human papillomavirus infections. *J Clin Virol* 2005; 32 Suppl 1:S16-S24.
6. Kjellberg L, Hallmans G, Ahren AM et al. Smoking, diet, pregnancy and oral contraceptive use as risk factors for cervical intra-epithelial neoplasia in relation to human papillomavirus infection. *Br J Cancer* 2000; 82(7):1332-1338.
7. Khan AM, Freeman-Wang T, Pisal N et al. Smoking and multicentric vulval intraepithelial neoplasia. *J Obstet Gynaecol* 2009; 29(2):123-125.
8. Petry KU, Kochel H, Bode U et al. Human papillomavirus is associated with the frequent detection of warty and basaloid high-grade neoplasia of the vulva and cervical neoplasia among immunocompromised women. *Gynecol Oncol* 1996; 60(1):30-34.
9. de Jong A, van der Burg SH, Kwappenberg KM et al. Frequent detection of human papillomavirus 16 E2-specific T-helper immunity in healthy subjects. *Cancer Res* 2002; 62(2):472-479.
10. Welters MJ, de Jong A, van den Eeden SJ et al. Frequent display of human papillomavirus type 16 E6-specific memory t-Helper cells in the healthy population as witness of previous viral encounter. *Cancer Res* 2003; 63(3):636-641.
11. van Poelgeest MI, Van Seters M, Van Beurden M et al. Detection of human papillomavirus (HPV) 16-specific CD4+ T-cell immunity in patients with persistent HPV16-induced vulvar intraepithelial neoplasia in relation to clinical impact of imiquimod treatment. *Clin Cancer Res* 2005; 11(14):5273-5280.
12. Bourgault V, I, Moyal BM, Berville S et al. Human papillomavirus 16-specific T cell responses in classic HPV-related vulvar intra-epithelial neoplasia. Determination of strongly immunogenic regions from E6 and E7 proteins. *Clin Exp Immunol* 2010; 159(1):45-56.
13. Van Seters M, Van Beurden M, de Craen AJ. Is the assumed natural history of vulvar intraepithelial neoplasia III based on enough evidence? A systematic review of 3322 published patients. *Gynecol Oncol* 2005; 97(2):645-651.
14. Bourgault Villada, I, Moyal BM, Ziol M et al. Spontaneous regression of grade 3 vulvar intraepithelial neoplasia associated with human papillomavirus-16-specific CD4(+) and CD8(+) T-cell responses. *Cancer Res* 2004; 64(23):8761-8766.
15. Jones RW, Rowan DM, Stewart AW. Vulvar intraepithelial neoplasia: aspects of the natural history and outcome in 405 women. *Obstet Gynecol* 2005; 106(6):1319-1326.
16. Meeuwis KA, van Rossum MM, van de Kerkhof PC et al. Skin cancer and (pre)malignancies of the female genital tract in renal transplant recipients. *Transpl Int* 2010; 23(2):191-199.
17. Van Beurden M, van der Vange N, ten Kate FJ et al. Restricted surgical management of vulvar intraepithelial neoplasia 3: Focus on exclusion of invasion and on relief of symptoms. *Int J Gynecol Cancer* 1998; 8(1):73-77.
18. Hillemanns P, Wang X, Staehle S et al. Evaluation of different treatment modalities for vulvar intraepithelial neoplasia (VIN): CO(2) laser vaporization, photodynamic therapy, excision and vulvectomy. *Gynecol Oncol* 2006; 100(2):271-275.
19. Likes WM, Stegbauer C, Tillmanns T et al. Correlates of sexual function following vulvar excision. *Gynecol Oncol* 2007; 105(3):600-603.
20. Daayana S, Elkord E, Winters U et al. Phase II trial of imiquimod and HPV therapeutic vaccination in patients with vulvar intraepithelial neoplasia. *Br J Cancer* 2010; 102(7):1129-1136.

21. Winters U, Daayana S, Lear JT et al. Clinical and immunologic results of a phase II trial of sequential imiquimod and photodynamic therapy for vulvar intraepithelial neoplasia. *Clin Cancer Res* 2008; 14(16):5292-5299.
22. Kenter GG, Welters MJ, Valentijn AR et al. Vaccination against HPV-16 oncoproteins for vulvar intraepithelial neoplasia. *N Engl J Med* 2009; 361(19):1838-1847.
23. Davidson EJ, Boswell CM, Sehr P et al. Immunological and clinical responses in women with vulvar intraepithelial neoplasia vaccinated with a vaccinia virus encoding human papillomavirus 16/18 oncoproteins. *Cancer Res* 2003; 63(18):6032-6041.
24. Van Seters M, Van Beurden M, ten Kate FJ et al. Treatment of vulvar intraepithelial neoplasia with topical imiquimod. *N Engl J Med* 2008; 358(14):1465-1473.
25. van Esch EM, Welters MJ, Jordanova ES et al. Treatment failure in patients with HPV 16-induced vulvar intraepithelial neoplasia: understanding different clinical responses to immunotherapy. *Expert Rev Vaccines* 2012; 11(7):821-840.
26. van den Brule AJ, Pol R, Franssen-Daalmeijer N et al. GP5+/6+ PCR followed by reverse line blot analysis enables rapid and high-throughput identification of human papillomavirus genotypes. *J Clin Microbiol* 2002; 40(3):779-787.
27. Kleter B, van Doorn LJ, Schrauwen L et al. Development and clinical evaluation of a highly sensitive PCR-reverse hybridization line probe assay for detection and identification of anogenital human papillomavirus. *J Clin Microbiol* 1999; 37(8):2508-2517.
28. Kupperts V, Stiller M, Somville T et al. Risk factors for recurrent VIN. Role of multifocality and grade of disease. *J Reprod Med* 1997; 42(3):140-144.
29. Modesitt SC, Waters AB, Walton L et al. Vulvar intraepithelial neoplasia III: occult cancer and the impact of margin status on recurrence. *Obstet Gynecol* 1998; 92(6):962-966.
30. Wallbillich JJ, Rhodes HE, Milbourne AM et al. Vulvar intraepithelial neoplasia (VIN 2/3): comparing clinical outcomes and evaluating risk factors for recurrence. *Gynecol Oncol* 2012; 127(2):312-315.
31. McNally OM, Mulvany NJ, Pagano R et al. VIN 3: a clinicopathologic review. *Int J Gynecol Cancer* 2002; 12(5):490-495.
32. Welters MJ, Kenter GG, de Vos van Steenwijk PJ et al. Success or failure of vaccination for HPV16-positive vulvar lesions correlates with kinetics and phenotype of induced T-cell responses. *Proc Natl Acad Sci U S A* 2010; 107(26):11895-11899.
33. Danna EA, Sinha P, Gilbert M et al. Surgical removal of primary tumor reverses tumor-induced immunosuppression despite the presence of metastatic disease. *Cancer Res* 2004; 64(6):2205-2211.
34. Brown JV, Goldstein BH, Rettenmaier MA, et al. Laser ablation of surgical margins after excisional partial vulvectomy for VIN: Effect on recurrence. *J Reprod Med* 2005; 50(5):345-350.
35. Terlou A, Van Seters M, Ewing PC et al. Treatment of vulvar intraepithelial neoplasia with topical imiquimod: seven years median follow-up of a randomized clinical trial. *Gynecol Oncol* 2011; 121(1):157-162.
36. Iavazzo C, Pitsouni E, Athanasiou S, et al. Imiquimod for treatment of vulvar and vaginal intraepithelial neoplasia. *Int J Gynaecol Obstet* 2008; 101(1):3-10.
37. Ahr A, Rody A, Kissler S, et al. Risk factors for recurrence of vulvar intraepithelial neoplasia III (VIN III). *Zentralbl Gynakol* 2006; 128(6):347-351.
38. Chulvis do Val IC, Almeida Filho GL, Valiante PM et al. Vulvar intraepithelial neoplasia p53 expression, p53 gene mutation and HPV in recurrent/progressive cases. *J Reprod Med* 2004; 49(11):868-874.
39. Jamieson DJ, Paramsothy P, Cu-Uvin S et al. Vulvar, vaginal, and perianal intraepithelial neoplasia in women with or at risk for human immunodeficiency virus. *Obstet Gynecol* 2006; 107(5):1023-1028.
40. Hampf M, Wentzensen N, Vinokurova S et al. Comprehensive analysis of 130 multicentric intraepithelial female lower genital tract lesions by HPV typing and p16 expression profile. *J Cancer Res Clin Oncol* 2007; 133(4):235-245.
41. Goffin F, Mayrand MH, Gauthier P et al. High-risk human papillomavirus infection of the genital tract of women with a previous history or current high-grade vulvar intraepithelial neoplasia. *J Med Virol* 2006; 78(6):814-819.
42. Vinokurova S, Wentzensen N, Eienkel J et al. Clonal history of papillomavirus-induced dysplasia in the female lower genital tract. *J Natl Cancer Inst* 2005; 97(24):1816-1821.
43. Hording U, Junge J, Poulsen H et al. Vulvar intraepithelial neoplasia III: a viral disease of undetermined progressive potential. *Gynecol Oncol* 1995; 56(2):276-279.

