



Universiteit  
Leiden  
The Netherlands

## **Muscle and joint sequelae in brachial plexus injury**

Duijnisveld, B.J.

### **Citation**

Duijnisveld, B. J. (2016, August 31). *Muscle and joint sequelae in brachial plexus injury*. Retrieved from <https://hdl.handle.net/1887/42617>

Version: Not Applicable (or Unknown)

License: [Licence agreement concerning inclusion of doctoral thesis in the Institutional Repository of the University of Leiden](#)

Downloaded from: <https://hdl.handle.net/1887/42617>

**Note:** To cite this publication please use the final published version (if applicable).

Cover Page



Universiteit Leiden

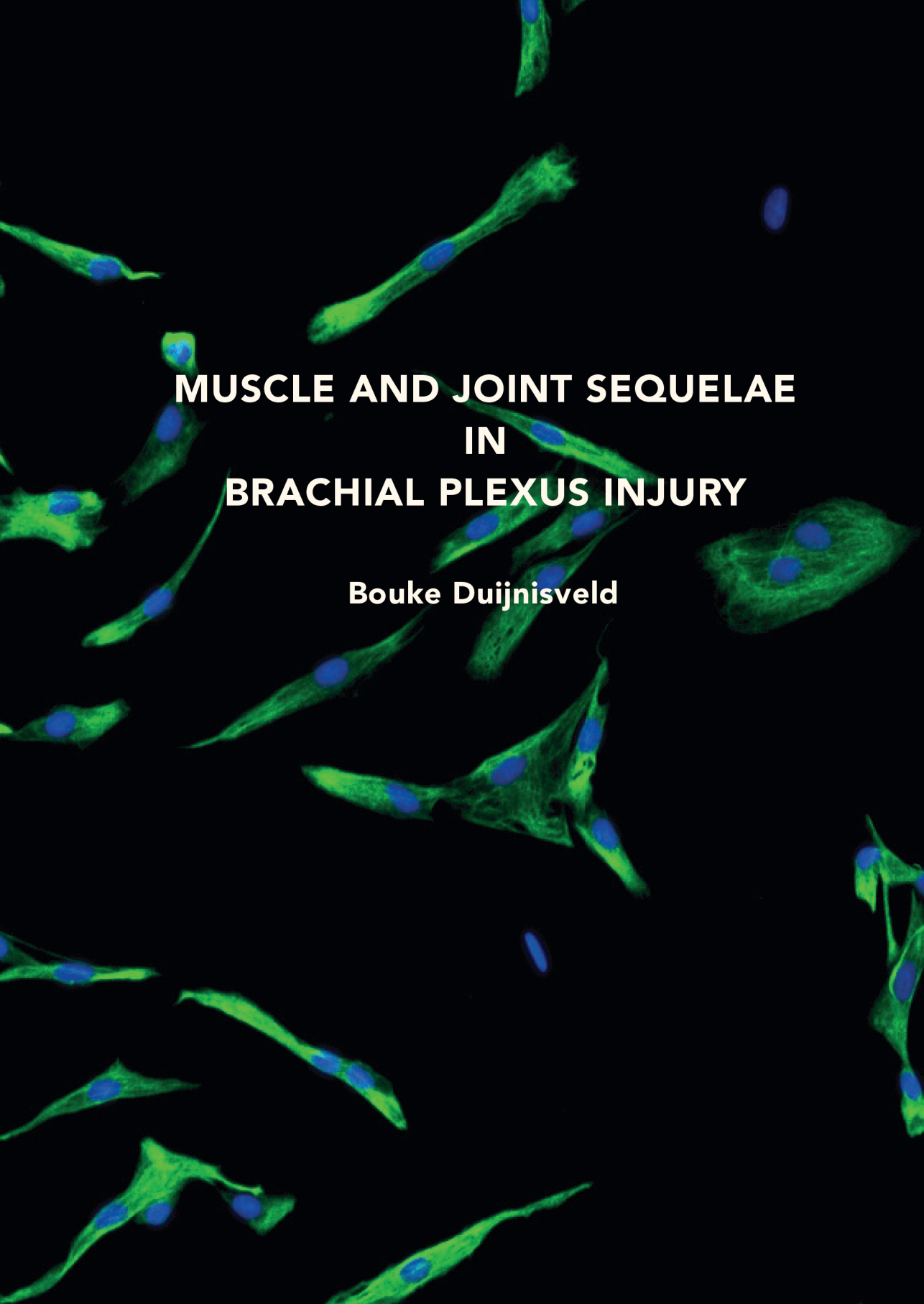


The handle <http://hdl.handle.net/1887/42617> holds various files of this Leiden University dissertation.

**Author:** Duijnisveld, B.J.

**Title:** Muscle and joint sequelae in brachial plexus injury

**Issue Date:** 2016-08-31

The background of the cover is a fluorescence microscopy image of muscle cells. The cells are stained with a green fluorescent marker, likely highlighting the cytoplasm or myofibrils, and a blue fluorescent marker, likely highlighting the nuclei. The cells are elongated and spindle-shaped, with some showing multiple nuclei. The overall appearance is that of a muscle tissue sample under a fluorescence microscope.

**MUSCLE AND JOINT SEQUELAE  
IN  
BRACHIAL PLEXUS INJURY**

**Bouke Duijnsveld**